

# Successful correction of stenotic nares using combined Alar Fold Lift-Up and Sulcus Pull-Down Techniques in brachycephalic cats: 8 cases (2017–2022)

Michael M. Pavletic, DVM, DACVS,\* and Nicholas J. Trout, Vet MB, DACVS, DECVS

Department of Surgery, Angell Animal Medical Center, Boston, MA

\*Corresponding author: Dr. Pavletic (mpavletic@angell.org)

Received February 3, 2023

Accepted April 4, 2023

doi.org/10.2460/javma.23.01.0054

## OBJECTIVE

Describe surgical guidelines for a new technique to correct stenotic nares in brachycephalic cats.

## ANIMALS

8 client-owned brachycephalic cats with stenotic nares between April 2017 and July 2022.

## PROCEDURES

8 brachycephalic cats with severe stenotic nares presented to the Angell Animal Medical Center with the patient age ranging from 2 years to 9 years of age. Surgical correction was performed on each cat with the combined use of the “Alar Fold Lift-Up” and “Sulcus Pull-Down” techniques.

## RESULTS

Successful correction of the stenotic nares was achieved, enabling each cat to breathe normally.

## CLINICAL RELEVANCE

The combined use of the “Alar Fold Lift-Up” and “Sulcus Pull-Down” techniques is simple to perform on an outpatient basis. Surgery is restricted to the adjacent skin and does not require the surgical alteration of the external nose or nares. Long-term follow-up indicates the procedure is effective in improving nasal breathing in each cat.

Stenotic nares in the cat is almost exclusively noted in the brachycephalic breeds, including the Persian, Himalayan, Exotic Shorthair, Scottish Fold, and Burmese cats.<sup>1</sup> These cats have smaller nostrils and a flattened facial profile when compared to other feline breeds (**Figure 1**). In some brachycephalic cats, the small nasal opening can increase their respiratory effort to breathe.<sup>2–4</sup> Any nasal discharge more easily obstructs the nares of these cats, further compromising air excursion through each nostril.

Surgical procedures used to treat stenotic nares in brachycephalic cats include punch resection alaplasty,<sup>5</sup> the use of a single advancement flap,<sup>6</sup> ala vestibuloplasty (resection of the ala nasi or alar wings),<sup>2,7</sup> small wedge resection,<sup>8</sup> and the use of the carbon dioxide laser to remove the lower portion of each alar fold.<sup>9</sup> All these techniques were reported to improve nasal breathing.

The authors had previously noted that the upward curvature of the skin, rostral to the nasal sulcus of brachycephalic cats, partially obstructs the nasal opening. This, combined with the downward or partially collapsed position of the alar folds contrib-

ute to nasal stenosis. The small, lower alar folds in brachycephalic cats, have the flexibility to be easily elevated in a dorsolateral direction with thumb forceps. Based on these clinical observations, this study describes the use of small elliptical or punch resections of skin dorsolateral to the alar folds (Alar Fold Lift-Up) and small elliptical or punch skin resection rostral to the sulcus (Sulcus Pull-Down) for treating nasal stenosis in brachycephalic cats. Used in combination, both techniques were used to enlarge the nostrils of brachycephalic cats with the expectation of facilitating nasal breathing postoperatively.

## Materials and Methods

### Cases

Client-owned brachycephalic cats with severe nasal stenosis and a history of progressive difficulty with nasal breathing with increased inspiratory effort that were presented to the Angell Animal Medical Center between April 11, 2017, and July 11, 2022, were eligible for inclusion. Owner consent was obtained for treatment.

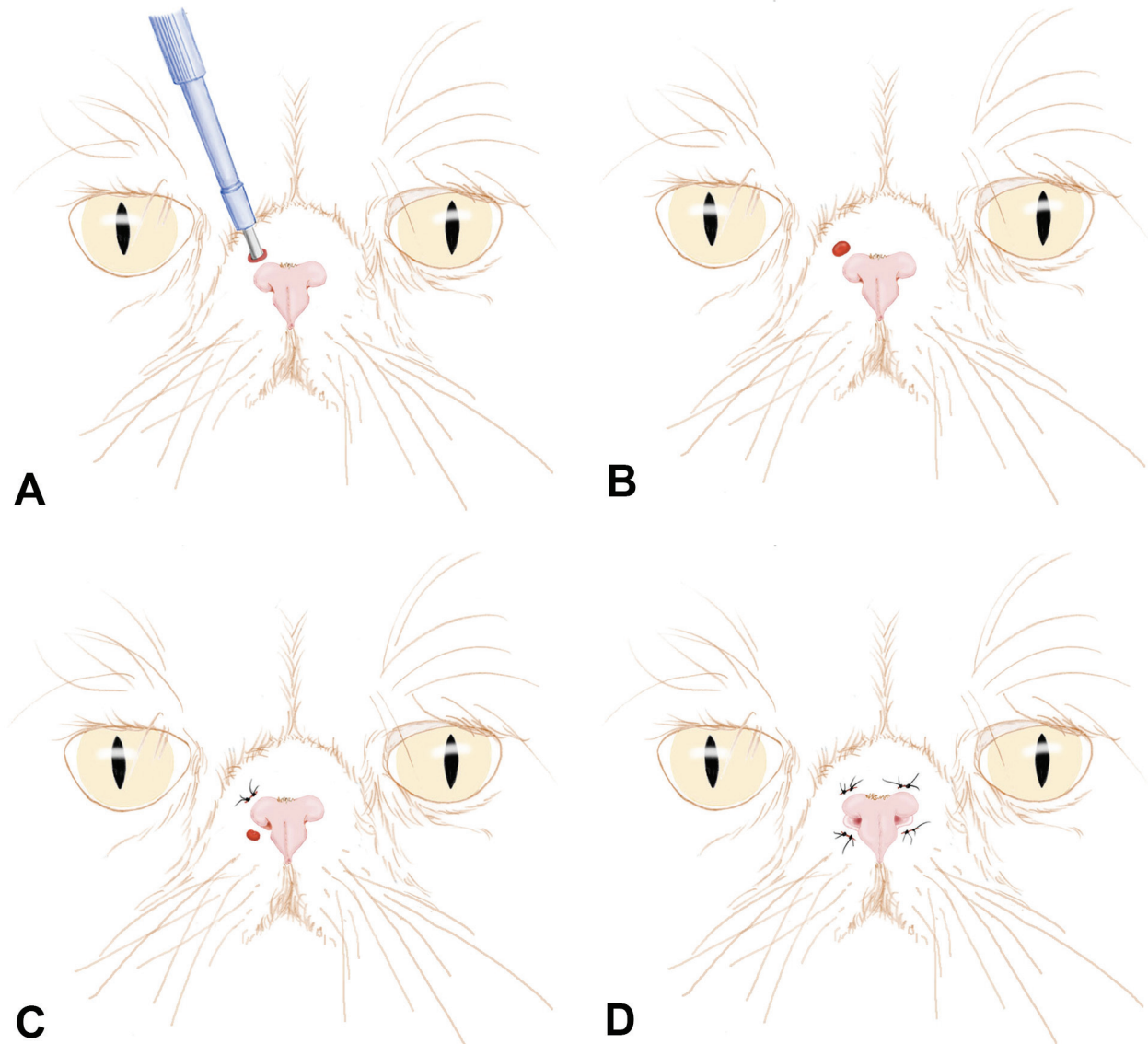


**Figure 1**—Illustration of the facial profile of a brachycephalic cat (left) in comparison to a domestic shorthair cat (right). Along with the flattened facial silhouette of brachycephalic cats the external nose also is smaller than other cat breeds’.

### Combined “Alar Fold Lift” and “Sulcus Pull Down” surgical procedures

Each cat was screened preoperatively with a CBC and serum biochemical profile. All cats underwent general anesthesia for stenotic nares correction and the anesthetic protocols were individualized for patient needs as determined by the clinical anesthesiology service. Each cat received perioperative ceftazolin sodium (10 mg/kg, IV) and ondansetron (0.2 mg/kg, IV). Lactated Ringer solution (5 mg/kg/h, IV) was administered through the duration of the surgical procedure.

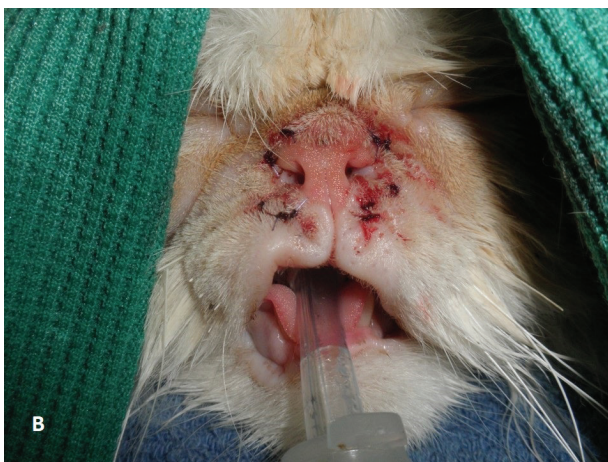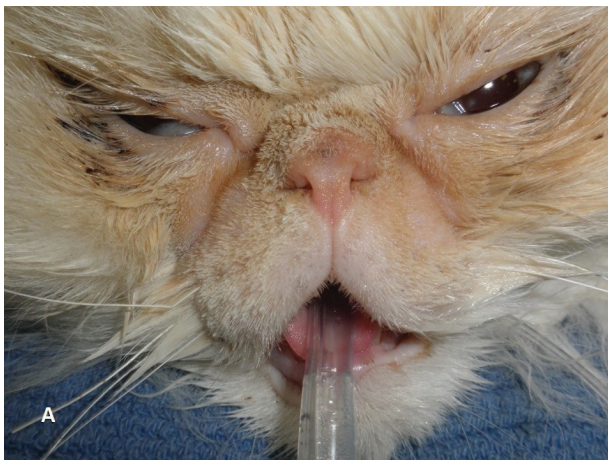
During anesthetic induction, the soft palate and larynx were examined in each cat. The skin around the perimeter of the nares was clipped of fur. The cats were placed in sternal recumbency with the



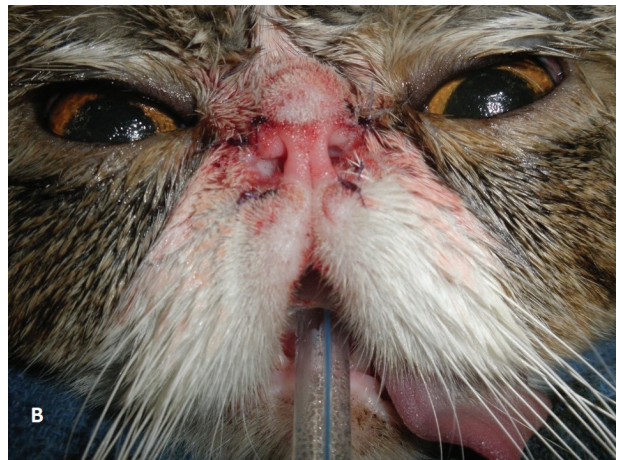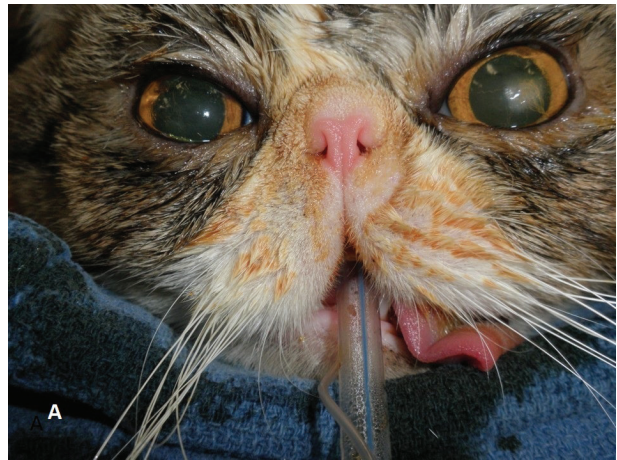**Figure 2**—Sequential illustrations of the “Alar Fold Lift-Up” and “Sulcus Pull-Down” procedures performed between April 2017 and July 2022 to improve nasal breathing for 8 client-owned brachycephalic cats with stenotic nares. A 4-mm punch is used to resect a skin segment dorsolateral to the adjacent alar fold (A), followed by removal of the cutaneous plug (B). The dorsolateral punch defect is closed with 4-0 absorbable interrupted poliglecaprone sutures (C). This is followed by skin punch placement in the slight downward curvature of the skin rostral to each nasal sulcus. The procedures are performed bilaterally for completion (D) of the “Alar Fold Lift-Up” and “Sulcus Pull-Down” procedures.

head elevated on folded cloth surgical towels placed along the end of the surgical table. Following surgical preparation of the skin, the facial area was draped.

A surgical pen was used to mark the intended areas for skin resection in all 4 locations based on the assessment of skin tension in relation to the alar folds. An ellipse of skin, 5 to 6 mm long by 4 to 5 mm wide was created in the skin dorsolateral to the adjacent alar fold margins using a No. 11 scalpel blade in 6 cats. In 2 cats, a 4-mm biopsy punch was used to facilitate skin resection. 4-0 absorbable interrupted polyglactone sutures were used to close each incision. Following the “Alar Fold Lift-Up” procedure, similar skin incisions were made rostral to each nasal sulcus, over the curvature of the skin partially obstructing each nostril. Resection of the skin was followed by closure in an identical fashion. Surgical closure was normally performed in sets: the left or right side was initially completed followed by the remaining side (**Figure 2**). Photographs were taken prior to and following completion of each procedure (**Figures 3 and 4**).



**Figure 3**—Perioperative images of a Himalayan cat from the case series described in Figure 2 before (A) and after (B) corrective surgery. In this cat, the right rostral upper margin of the lip was slightly lifted following closure of the lower punch incision; this had no clinical consequence.



**Figure 4**—Perioperative images of a Persian cat from the case series described in Figure 2 before (A) and after (B) corrective surgery. Note the enlargement of each nostril opening with this simple technique.

Elizabethan collars were placed on each cat during anesthetic recovery. All cats recovered from anesthesia uneventfully and were discharged later in the afternoon with instructions to keep the collars on each cat for a minimum of 1 week. Each cat was discharged with a prescription of buprenorphine (0.02 mg/kg, PO) every 12 hours for 5 days.

### Follow-up

Two weeks after surgery, owners were called and asked about their cats' breathing characteristics. Long-term follow-up conversations by telephone were made a minimum of 6 months postoperatively.

## Results

### Signalment, clinical signs, preoperative findings

Client-owned brachycephalic cats, with severe nasal stenosis and a history of progressive difficulty breathing, were presented to the Angell Animal Medical Center between April 2017 to July 2022 for a total of 8 consecutive cases. Feline breeds included 4 Persian, 3 Himalayan, and 1 Scottish Fold. Five cats were

neutered males, whereas 2 cats were spayed females. Cats ranged from 2 years to 9 years of age and had a mean body weight of 4.3 kg (range, 2.4 to 5.7 kg).

## **Surgery and postoperative period**

The soft palate and laryngeal examination were within normal limits. No postoperative complications were noted. Elizabethan collars were removed 1 week after surgery. The absorbable poliglecaprone sutures degraded and fell out of the skin within 4 weeks following surgery.

## **Follow-up**

Owners reported their cats were breathing well at the initial follow-up call 2 weeks postoperatively. Long-term follow-up conversations by telephone were made a minimum of 6 months postoperatively. Three cats were followed over a 3- to 5-year period with 1 cat for over 18 months. All owners reported that their cats were breathing well with their nostrils maintaining their patency over the length of the follow-up reports.

## **Discussion**

Stenotic nares is an uncommon cause of respiratory distress in cats, occurring primarily in Persian and other exotic brachycephalic cat breeds.<sup>1-4</sup> Unlike dogs, stenotic nares in cats is not usually associated with concurrent soft palate, laryngeal, or tracheal abnormalities and appears to be the predominant primary abnormality causing clinical respiratory signs.<sup>2,4,7</sup> None of the cats in this present study had elongation of the soft palate; each had normal laryngeal function on oral examination.

The smaller anatomic features of the feline nares make brachycephalic cats particularly vulnerable to upper airway distress due to Poiseuille's law, that defines a 16-fold increase to air flow resistance with a 50% reduction in airway radius.<sup>10,11</sup> There are notable anatomic differences of the skull and nasal cavity of brachycephalic cats compared to the general cat population.<sup>12</sup> One study on brachycephalic cats utilized CT and endoscopic examination to assess the nares, nasal vestibule, and the turbinates.<sup>7</sup> Narrowing of the nares and nasal vestibule were noted. Computed tomography noted radiologic evidence of aberrant turbinates rostrally, but without rhinoscopic evidence of visibly obstructive rostral aberrant nasal turbinates (obstruction of the rostral nasal passages). Only 1 of 19 cats had caudal aberrant nasal turbinates both on CT and rostral/caudal rhinoscopic examination.<sup>7</sup> This latter finding was in contrast to a study reporting a 21% prevalence in another feline brachycephalic report.<sup>13</sup> This present paper also reports on our clinical finding that the elevated skin, rostral to the sulcus, is a contributing factor in feline brachycephalic stenotic nares: the "Labial Pull-Down" portion of the procedure eliminates this cutaneous prominence.

Other respiratory signs may be associated with brachycephalic cats including sneezing, coughing, nasal discharge, open mouth breathing, snoring, upper respiratory noise, and severe dyspnea. Changes of the upper respiratory tract in brachycephalic cats can

contribute to problematic sleeping and activity intolerance.<sup>7</sup> Brachycephaly in the cat can also be associated with other gastrointestinal disorders including hypersalivation, halitosis, difficulty chewing, and messy eating/drinking.<sup>14</sup> In our study, except for increased inspiratory difficulties and occasional sniffing, there were no other signs reported by the owners.

Despite the intranasal changes reported in brachycephalic cats, surgical correction of stenotic nares does provide notable improvement in breathing for brachycephalic cats as well as their cardiopulmonary and activity-related parameters.<sup>5-8</sup> Following ala vestibuloplasty in one series of brachycephalic cats, visual improvement of the nares and nasal vestibule was evident: this was also noted in our present study.<sup>7</sup> Single pedicle advancement of the nasal mucosa also was reported to provide a good outcome in brachycephalic cats.<sup>6</sup> However, the flaps are small and delicate: surgical loupes, ophthalmic instrumentation, and fine 5-0 suture material are required. Other ala vestibuloplasty procedures include the partial resection of the axial alar wing (ala nasi) and alar fold (vestibulum nasi) using a cutting instrument or laser. The cutaneous punches used to enlarge the nares in this study avoid the need to incise the sensitive vascular tissue of the nares, altering the appearance of the cat's external nose.

The width of the cutaneous surgical defects created may vary slightly, based on the size of the cat and its facial conformation. In general, a 4- to 5-mm-wide skin resection allows for sufficient skin tension to elevate the elastic alar folds and depress the skin rostral to the sulcus. The 4-mm biopsy punch option is technically easier to perform than the use of a No. 11 scalpel blade, especially in smaller cats. The firmer underlying tissue support facilitates the insertion and cutting action of the biopsy punch. Wider resection is possible if 2 skin punches are performed immediately adjacent to, or slightly overlap one another; this was not necessary in these cats.

The skin dorsolateral to the alar folds is relatively inelastic and is attached to the underlying fascia. As a result, the possibility of the skin stretching over time, negating the surgical gains in alar elevation, was not noted in the long-term follow-up of each cat. The owners were pleased with the results of the surgery, noting that nasal breathing was notably improved without no alteration in the size of the nares postoperatively.

The combined use of the "Alar Fold Lift-Up" and "Sulcus Pull Down" Techniques in this study simultaneously addresses both anatomic areas that compromise the opening of each nostril. As noted, the skin is easily assessable and the surgery is simple to execute with minimal instrumentation while avoiding the need to incise the sensitive vascular tissue of the nares. Cats can be discharged the same day of this minor skin procedure.

## **Acknowledgments**

No internal or external funding was received in conjunction with this publication. The authors declare that there were no conflicts of interest.

The authors thank Ms. Sandra Durant for the artwork included in this report.

## References

1. Anagrius KL, Dimopoulou M, Moe AN, Petterson A, Ljungvall I. Facial conformation characteristics in Persian and Exotic Shorthair cats. *J Feline Med Surg*. 2021;23(12):1089–1097. doi:10.1177/1098612X21997631
2. Phillips H. Updates in upper respiratory surgery. *Vet Clin North Am Small Anim Pract*. 2022;52(2):339–368. doi:10.1016/j.cvsm.2021.12.002
3. Farnworth MJ, Chen R, Packer RMA, Caney SMA, Gunn-Moore DA. Flat feline faces: is brachycephaly associated with respiratory abnormalities in the domestic cat (*Felis catus*)? *PLoS One*. 2016;11(8):e0161777. doi:10.1371/journal.pone.0161777
4. Henderson SM, Bradley K, Day MJ, et al. Investigation of nasal disease in the cat—a retrospective study of 77 cases. *J Feline Med Surg*. 2004;6(4):245–257. doi:10.1016/j.jfms.2003.08.005
5. Trostel CT, Frankel DJ. Punch resection alarplasty technique in dogs and cats with stenotic nares: 14 cases. *J Am Anim Hosp Assoc*. 2010;46(1):5–11. doi:10.5326/0460005
6. Berns CN, Schmiedt CW, Dickerson VM, Murphy SM. Single pedicle advancement flap for treatment of feline stenotic nares: technique and results in five cases. *J Feline Med Surg*. 2020;22(12):1238–1242. doi:10.1177/1098612X20910539
7. Gleason HE, Phillips H, Fries R, Keating S, Hamel P, McCoy A. Ala vestibuloplasty improves cardiopulmonary and activity-related parameters in brachycephalic cats. *Vet Surg*. 2023;vsu.13948; Epub ahead of print. doi:10.1111/vsu.13948
8. Harvey CE. Surgical correction of stenotic nares in a cat. *J Am Anim Hosp Assoc*. 1986;22:31–32.
9. Norsworthy GD. CO2 laser can treat many feline ailments. *Vet Scalpel Case Studies*. <https://www.vetscalpel.com/case-studies/>
10. Fernández-Parra R, Pey P, Zilberstein L, Malvè M. Use of computational fluid dynamics to compare upper airway pressures and airflow resistance in brachycephalic, mesocephalic, and dolichocephalic dogs. *Vet J*. 2019;253:105392. doi:10.1016/j.tvjl.2019.105392
11. Hostnik ET, Scansen BA, Zielinski R, Ghadiali SN. Quantification of nasal airflow resistance in English bulldogs using computed tomography and computational fluid dynamics. *Vet Radiol Ultrasound*. 2017;58(5):542–551. doi:10.1111/vru.12531
12. Künzel W, Breit S, Oppel M. Morphometric investigations of breed-specific features in feline skulls and considerations on their functional implications. *Anat Histol Embryol*. 2003;32(4):218–223. doi:10.1046/j.1439-0264.2003.00448.x
13. Ginn JA, Kumar MSA, McKiernan BC, Powers BE. Nasopharyngeal turbinates in brachycephalic dogs and cats. *J Am Anim Hosp Assoc*. 2008;44(5):243–249. doi:10.5326/0440243
14. Gleason HE, Phillips H, McCoy AM. Influence of feline brachycephaly on respiratory, gastrointestinal, sleep, and activity abnormalities. *Vet Surg*. 2023;52(3):435–445. doi:10.1111/vsu.13931