

## What Is Your Diagnosis?

In collaboration with the American College of Veterinary Radiology

### History

A 7-day-old 40-kg mixed-breed beef heifer calf was presented for recheck evaluation because of persistent signs of inspiratory dyspnea. Four days earlier, the calf had been examined because of labored breathing with marked abdominal effort that developed after the calf (unwitnessed birth) had been kicked and appeared rejected by its dam; was deemed to have had a clinically normal body temperature, pulse, and behavior and no obvious signs of dysmaturity or congenital defects; and then tube fed 2 L of colostrum harvested from its dam. During the initial examination 4 days earlier, the calf was febrile (rectal temperature unknown), had a respiratory rate of 60 breaths/min (reference range, 30 to 60 breaths/min), and exhibited increased inspiratory effort. During that initial examination, laryngeal sounds were mildly increased, coughing was repeatedly elicited on laryngeal palpation, and lung sounds were absent in the right lung field; however, no sign of pain was elicited on palpation of the thoracic wall, and no broken ribs were detected. Based on the 72-hour history of assisted feedings and the findings on examination, calf diphtheria (laryngeal necrobacillosis) subsequent to trauma during esophageal feeding was considered most likely. Treatment was initiated with a single dose each of dexamethasone (0.1 mg/kg, IM) and florfenicol (40 mg/kg, SC), and the supervising herdsman was advised to continue to monitor the calf for nursing.

On recheck examination, the calf had a tucked abdomen and marked abdominal respiratory effort but was ambulatory and appeared to have an improved at-

Maisie E. Dawes, DVM, PhD<sup>1\*</sup>; Lisa G. Britt, DVM, MS<sup>2</sup>; Bradley T. Jones, DVM, MS<sup>3</sup>; Karen K. Shuck<sup>4</sup>; Curtis L. Eng, DVM<sup>1</sup>; Amanda Memarzadeh, DVM<sup>1</sup>; Jeff D. Ondrak, DVM, MS<sup>4</sup>

<sup>1</sup>College of Veterinary Medicine, Western University of Health Sciences, Pomona, CA

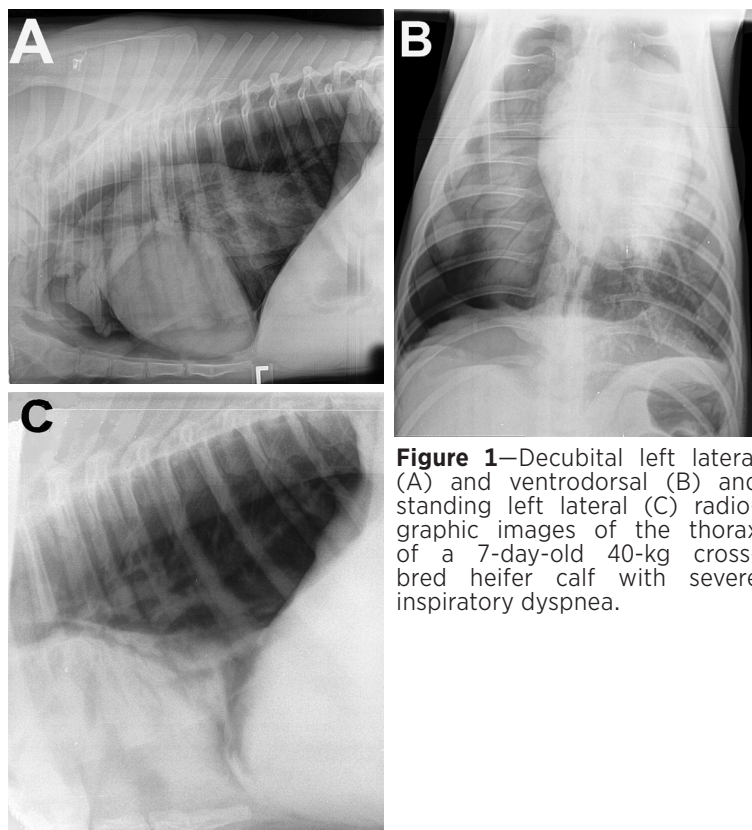
<sup>2</sup>All Creatures Teleradiology LLC, Columbia, MO

<sup>3</sup>US Meat Animal Research Center, Agricultural Research Service, USDA, Clay Center, NE

<sup>4</sup>Great Plains Veterinary Educational Center, University of Nebraska-Lincoln, Clay Center, NE

\*Corresponding author: Dr. Dawes (MDawes@westernu.edu)

<https://doi.org/10.2460/javma.20.11.0631>



**Figure 1**—Decubital left lateral (A) and ventrodorsal (B) and standing left lateral (C) radiographic images of the thorax of a 7-day-old 40-kg cross-bred heifer calf with severe inspiratory dyspnea.

titude in that it seemed curious when approached and appeared bright, alert, and responsive. The calf had a heart rate of 120 beats/min (reference range, 100 to 120 beats/min) and clinically normal heart sounds and a respiratory rate of 60 breaths/min, with increased lung sounds over the left cranial lung field and substantially quieter sounds over the right hemithorax. The calf was pyrexic (39.8 °C; reference range, 37.8 to 39.2 °C) and mildly dehydrated. Our differential diagnosis list was expanded to include calf diphtheria subsequent to trauma during esophageal feeding as initially suspected, diaphragmatic hernia, pneumothorax, and hemothorax. In the absence of signs of shock and hypoxia, hemothorax was ruled out and pneumothorax was considered less likely. Thoracic and abdominal radiography was performed (**Figure 1**), and the calf showed signs of discomfort while the ventrodorsal and left lateral decubital views were being taken.

**Formulate differential diagnoses, then continue reading.**

## Radiographic Findings and Interpretation

There was severe atelectasis of the right lung lobes and absence of visible pulmonary vasculature in the space between the right thoracic wall and right caudal lung lobe, suggestive of free air in the pleural space (**Figure 2**). The mediastinum and heart were shifted mildly toward the left, which was likely caused by increased right intrapleural pressure combined with concurrent atelectasis of the left lung lobes resulting from the calf lying in left lateral recumbency during radiographic exposure. Although a shift in mediastinal structures is often suggestive of tension pneumothorax, this was ruled out given the calf's demeanor and lack of evidence of hemodynamic instability. The shift may also have been exaggerated by mild sternal rotation.

Multiple radiolucent air bronchograms were visible in the caudal aspect of the partially collapsed right lung lobe, the collapse of which was secondary to passive atelectasis that occurs when contact between the parietal and visceral pleura is disrupted. The 2 most common etiologies associated with this change are pneumothorax and pleural effusion. An area of increased radiolucency without visibility of vessels in the right hemithorax was consistent with unilateral pneumothorax and subsequent atelectasis of the right lung lobes.

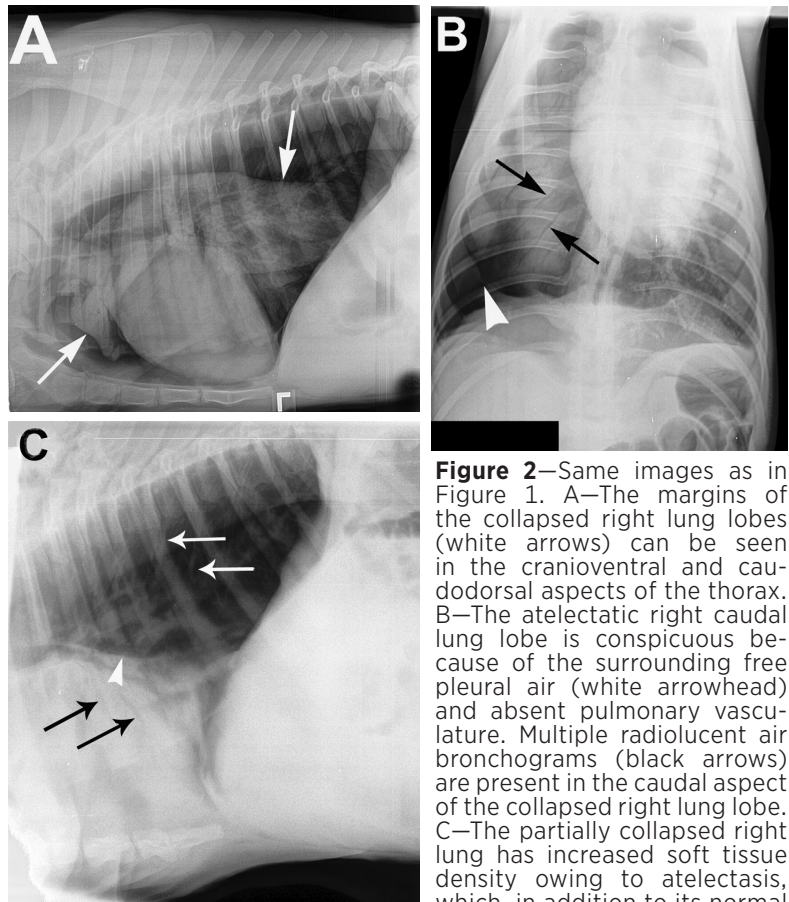
These findings were consistent with a closed right-sided unilateral pneumothorax and severe pulmonary atelectasis. Without signs consistent with a diaphragmatic hernia, it was deemed inconsequential as a viable differential diagnosis.

## Treatment and Outcome

The calf received single doses each of dexamethasone (0.1 mg/kg, IM), flunixin meglumine (1.1 mg/kg, IV) and florfenicol (40 mg/kg, SC) and was tube fed an electrolyte nutritional supplement (Hydra-Lyte; AgriLabs LCC; 1.8 L, PO through an esophageal feeder). Considered stable, the calf was subsequently returned to its barn for continued monitoring by the herdspersons. Over the next 2 days, the calf had markedly improved behavior and demeanor and was returned to the herd. Two years later, the heifer was confirmed pregnant and a member of the farm's replacement stock.

## Comments

Despite the relatively absent breath sounds over the right lung field, treatment for diphtheria



**Figure 2**—Same images as in Figure 1. A—The margins of the collapsed right lung lobes (white arrows) can be seen in the cranioventral and caudodorsal aspects of the thorax. B—The atelectatic right caudal lung lobe is conspicuous because of the surrounding free pleural air (white arrowhead) and absent pulmonary vasculature. Multiple radiolucent air bronchograms (black arrows) are present in the caudal aspect of the collapsed right lung lobe. C—The partially collapsed right lung has increased soft tissue density owing to atelectasis, which, in addition to its normal

contact with the heart, is causing a silhouette sign. The dorsal margin of the atelectatic right caudal lung lobe is evident (white arrowhead). Although air bronchograms (black arrows) are present in the right lung lobe, the vasculature of the left lung (white arrows) can clearly be seen extending toward the vertebral column.

was indicated on the basis of observed pyrexia, inspiratory dyspnea, coughing, and signs of pain elicited during laryngeal palpation. The radiographic survey of the calf's thorax on recheck examination 4 days after initial presentation did not demonstrate findings supportive of a diaphragmatic hernia, specifically, loss of the integrity of the diaphragm, presence of abdominal viscera within the thoracic cavity, or both. Instead, key findings included a ventral location of a distinctly radiopaque structure that was surprisingly visible on both lateral views (right lateral not shown) within close proximity to the heart, increased lucency in the caudodorsal right hemithorax, and absence of pulmonary vessels in the caudal right thorax (ventrodorsal view). The right accessory lung lobe also appeared collapsed. These findings were consistent with right-sided, unilateral pneumothorax.

Pneumothorax often leads to lung collapse.<sup>1</sup> It may result from leakage of air from either the lungs, trachea, or esophagus into the pleural space, leading to the disruption of contact between the parietal and visceral pleurae. However, air from the trachea or esophagus was considered unlikely because pneumomediastinum<sup>2</sup> was not observed. Given the

resolution of clinical signs without surgical intervention, sternal rotation during radiographic evaluation was believed to have caused the observed leftward mediastinal shift. Although atelectasis is a common sequela of pleural effusive disease and airway obstruction,<sup>3,4</sup> both conditions were ruled out based on a lack of corroborating evidence.

Although death is not uncommon in patients with unilateral or bilateral pneumothorax, the calf's full recovery with only conservative treatment (eg, thoracocentesis was not performed) was likely attributable to the nonfenestrated anatomy of the mediastinum in bovines. Successful control of laryngeal disease and the surprisingly mild clinical impact (eg, absence of hypoxia, hypercapnia, open-mouth breathing, severe dyspnea, and severe tachypnea<sup>4,5</sup>) of the abnormal accumulation of air within the pleural space also contributed to this calf's survival.

## Acknowledgments

Dr. Memarzadeh was a third-year student when the calf was treated.

## References

1. Kattea MO, Lababede O. Differentiating pneumothorax from the common radiographic skinfold artifact. *Ann Am Thorac Soc*. 2015;12(6):928-931.
2. Radostits OM, Gay CC, Hinchcliff KW, Constable PD. *Veterinary Medicine: a Textbook of the Diseases of Cattle, Horses, Sheep, Pigs, and Goats*. 10th ed. Saunders Elsevier; 2007.
3. Buczinski S, Forté G, Francoz D, Bélanger A-M. Comparison of thoracic auscultation, clinical score, and ultrasonography as indicators of bovine respiratory disease in preweaned dairy calves. *J Vet Intern Med*. 2014;28(1):234-242.
4. Slack JA, Thomas CB, Peek SF. Pneumothorax in dairy cattle: 30 cases (1990-2003). *J Am Vet Med Assoc*. 2004;225(5):732-735.
5. Peek SF. Respiratory emergencies in cattle. *Vet Clin North Am Food Anim Pract*. 2005;21(3):697-710.