



What Is Your Diagnosis?

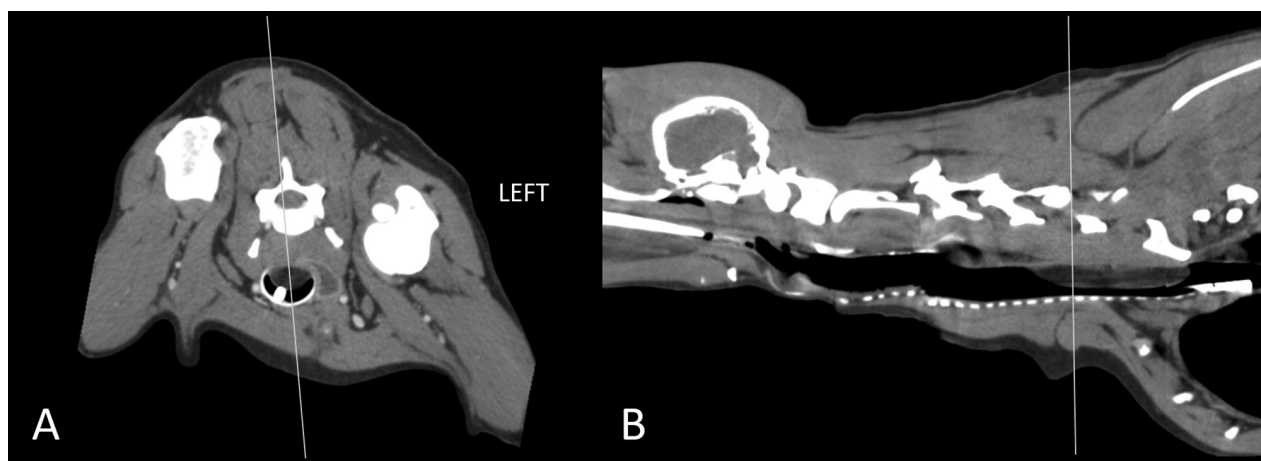


Figure 1—Transverse (A) and sagittal reconstructed (B) CT images of the neck of a 6-year-old 17.5-kg (38.5-lb) castrated male Labrador Retriever with a 2-month history of progressive coughing and respiratory distress. The vertical line in each image represents the level of the orthogonal image. A—Postcontrast image displayed in a soft tissue window (window width, 456 HU; window level, 39 HU) with a slice thickness of 0.9 mm. B—Precontrast image displayed in a soft tissue window (window width, 400 HU; window level, -10 HU) with a slice thickness of 0.9 mm.

History

A 6-year-old 17.5-kg (38.5-lb) castrated male Labrador Retriever that lived on a farm and had free access to livestock was referred for a 2-month history of progressive coughing and respiratory distress. Approximately 1 month earlier, the dog was evaluated by the referring veterinarian because of dyspnea after unwitnessed trauma. Thoracic radiography performed by the referring veterinarian at that point revealed recent fractures of the bodies of the right sixth through ninth ribs, pulmonary contusion, and a redundant tracheal membrane spanning the thoracic inlet (not shown). Although the dog seemed to recover from the traumatic event, the dog's respiratory distress progressively worsened, including the dog extending its neck and turning its head to the side to breathe and having episodes of collapse.

On referral examination, the dog was quiet and panted with its head held in a mildly extended position. Thoracic auscultation was unremarkable, and mucous membranes were pink. During periods of excitement, the dog had severe stertor and a deep nonproductive cough with a terminal retch.

The dog underwent general anesthesia for diagnostic imaging. After induction and during intubation, no respiratory airflow was detected through the endotracheal tube, and resistance was felt when the endotracheal tube was advanced more caudally. A small diameter catheter was advanced through the lumen of the endotracheal tube to ensure oxygenation. Cervical and thoracic radiography was performed (**Supplementary Figure S1**, available at: avmajournals.avma.org/doi/suppl/10.2460/javma.258.4.365), and findings were consistent with those identified by the referring veterinarian, except for a soft tissue opacity that silhouetted with the dorsal aspect of the trachea at the thoracic inlet and that appeared more focal and better defined than a dorsal tracheal membrane as described by the referring veterinarian. Therefore, a mass was considered. The endotracheal tube but not the catheter for supplemental oxygen was removed, general anesthesia was maintained with isoflurane, and the dog underwent CT^a of the neck and cranial aspect of the thorax, with images obtained before and after administration of contrast medium^b (ioversol [350 mg I/mL], 2.2 mL/kg [1 mg/lb], IV) to further characterize the lesion (**Figure 1**).

Formulate differential diagnoses and treatment strategies from the history, clinical findings, and Figure 1—then turn the page →

This report was submitted by Daniela M. Aguayo Santaella, BA; Kryssa L. Johnson, DVM; Nathan D. Helgert, VMD; Federica Morandi, DMV, MS; and Jacqueline C. Whittemore, DVM, PhD; from the Department of Small Animal Clinical Sciences, College of Veterinary Medicine, University of Tennessee, Knoxville, TN 37996. Dr. Helgert's present address is the Breathitt Veterinary Center, Murray State University, Hopkinsville, KY 42240.

Address correspondence to Dr. Whittemore (jwhittemore@utk.edu).

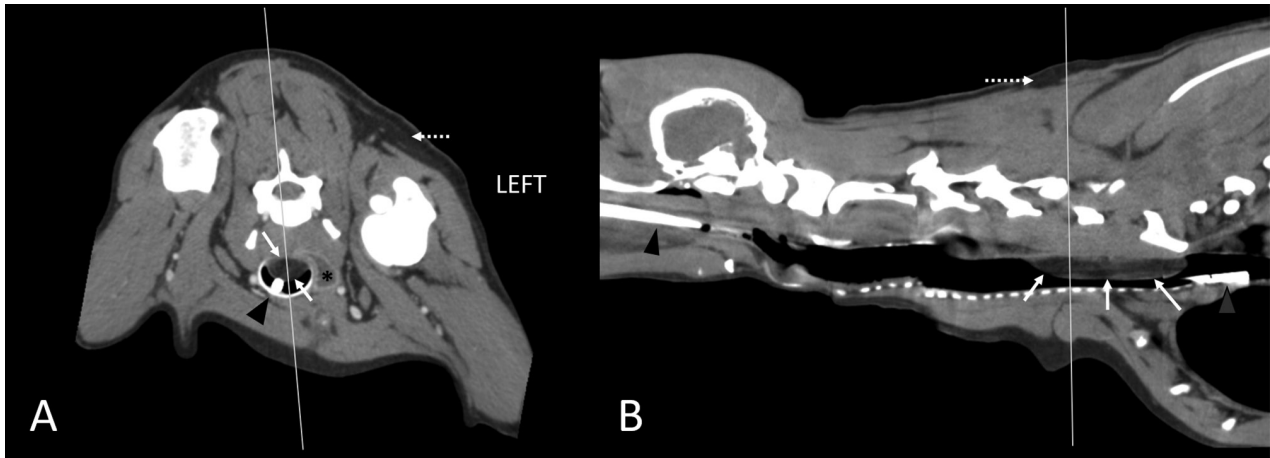


Figure 2—Same images as in Figure 1. A hypoattenuating, broad-based, smoothly-margined mass (solid arrows) associated with the dorsal aspect of the tracheal membrane occupies approximately 80% of the tracheal lumen diameter just cranial to the manubrium. This mass has attenuation similar to subcutaneous adipose tissue (dotted arrows). The small-diameter catheter (arrowheads) used to oxygenate the patient is evident in the tracheal lumen, and the fluid-filled esophagus (asterisk; A) is left of the trachea.

Diagnostic Imaging Findings and Interpretation

A smoothly margined, well-defined, broad-based mass (approx 7.5 X 1.5 X 1.0 cm [length X width X height, respectively]) associated with the dorsal aspect of the trachea was identified (**Figure 2**). The mass extended into the tracheal lumen from the level of the cranial aspect of C4 to the mid-body of C7 and tapered at its cranial and caudal aspects. At its largest transverse aspect, the mass occupied approximately 80% of the cross-sectional area of the tracheal lumen, which we considered to be the cause of our inability to position the endotracheal tube appropriately and the patient's clinical signs. The mass was homogeneously fat-attenuating (-60 to -90 HU) and did not display contrast enhancement. On the basis of these findings, this lesion was consistent with a tracheal lipoma associated with the dorsal aspect of the tracheal membrane. In addition, the caudal cervical portion of the esophagus was filled with fluid, which is a common finding in anesthetized patients and was considered incidental and unrelated to the tracheal lesion.

Tracheoscopy was performed immediately after CT and revealed a large, soft, semi-pedunculated mass that protruded from the dorsal aspect of the tracheal membrane (**Figure 3**). The mass was smooth and pale pink, had no visible signs of inflammation, and occupied most of the tracheal lumen.

Treatment and Outcome

Given its length and wide base, the mass was not considered amenable to endoscopic snaring and excision. The owner declined surgical resection of the mass and elected euthanasia for the dog. On necropsy, a pale tan to yellow soft mass (approx 7-cm-long X 2.5-cm-diameter) was identified arising from the annular ligaments of the trachea and occluding 90%

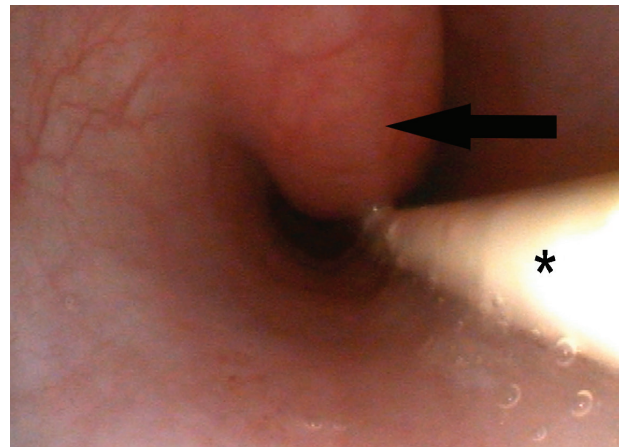


Figure 3—Craniocaudal tracheoscopic image of a large, soft, broad-based mass (arrow) that protrudes from the dorsal aspect of the trachea and occupies most of the tracheal lumen diameter. A catheter (asterisk) to provide supplemental oxygen courses ventral to the mass.

95% of the tracheal lumen. The mass contained sheets of well-differentiated adipocytes, consistent with a lipoma, as diagnosed on the basis of CT findings.

Comments

Tracheal lipoma is a rare neoplastic cause of respiratory distress in people^{1,2} and dogs,³ and clinical signs are often nonspecific respiratory signs, such as coughing, wheezing, dyspnea, stridor, or stertor, alone or in combination. Although histologically benign, the size and location of a lipoma in the trachea can result in life-threatening dyspnea.

Surgical resection can be curative, even with narrow margins, unlike more common tracheal neoplasms, such as tracheal carcinoma or osteochondroma, for which tracheal resection and anastomosis

generally are required for good long-term outcome.⁴ Preoperative identification of the type of mass is essential for an accurate prognosis and planning optimal surgical treatment. Unfortunately, endoscopically guided fine-needle aspiration and endobronchial biopsy have poor diagnostic yield because airway lipomas often are encased in fibrous capsules.^{3,5}

Computed tomography is considered key to identifying lipomas.⁵ Not only can CT be used as a valuable tool to determine anatomic location and extent of a mass and its association with other structures, all of which are essential for surgical planning, but it can also precisely quantify tissue density. Although clinically normal adipose tissue ranges in attenuation values on CT, such values are always negative, and the mass in the dog of the present report was homogeneously fat-attenuating (-60 to -90 HU). In addition, the attenuation of suspected fatty lesions can be compared with the attenuation of the patient's subcutaneous adipose tissue, as we did for the dog of the present report. Identifying features of a benign lipoma on CT are round to oval shape, well-defined margination, fat attenuation, and lack of associated hyperattenuating components; however, some lipomas could have hyperattenuating regions that may represent necrosis, hemorrhage, or fibrosis, alone or in combination.⁶ Despite having diagnostic imaging features strongly supportive of a benign fatty mass, a histologic examination is required for a definitive diagnosis.

The dog of the present report had a confounding history in that the onset of abnormal respiratory signs

and later thoracic trauma occurred approximately 2 months and 1 month, respectively, before the referral examination. Radiography revealed a structure in the dorsal aspect of the trachea but did not allow us to differentiate between a tracheal mass and a redundant tracheal membrane. Findings on CT facilitated a confident diagnosis of tracheal lipoma, both as the cause of the clinical signs and most likely as a tumor of benign origin, which was supported with postmortem histologic findings. To our knowledge, this was the first report to describe CT features of tracheal lipoma in a dog.

Footnotes

- a. Brilliance-40 mCT, Philips Medical Systems, Cleveland, Ohio.
- b. Optiray 350, Tyco Healthcare, Mallinckrodt Inc, St Louis, Mo.

References

1. Wu B-R, Chen C-H, Liao W-C, et al. Life-threatening tracheal benign tumor: lipoma. *Intern Med* 2016;55:1677-1678.
2. Morton SE, Byrd RPJ, Fields CL, et al. Tracheal lipoma: a rare intrathoracic neoplasm. *South Med J* 2000;93:497-500.
3. Piirainen KJ, Viitanen SJ, Lappalainen AK, et al. Intraluminal tracheal lipoma as a rare cause of dyspnoea in a dog. *Acta Vet Scand* 2018;60:59.
4. Carlisle CH, Biery DN, Thrall DE. Tracheal and laryngeal tumors in the dog and cat: literature review and 13 additional patients. *Vet Radiol Ultrasound* 1991;32:229-235.
5. Wu CC, Shepard J-AO. Tracheal and airway neoplasms. *Semin Roentgenol* 2013;48:354-364.
6. Spoldi E, Schwarz T, Sabattini S, et al. Comparisons among computed tomographic features of adipose masses in dogs and cats. *Vet Radiol Ultrasound* 2017;58:29-37.