



What Is Your Neurologic Diagnosis?

A 5-year-old 25.7-kg (56.5-lb) neutered male Australian Cattle Dog mix was evaluated because of a 6-month history of signs of neck pain that were characterized by a low head carriage and vocalization when the dog lowered its head to eat or drink. Five months prior to evaluation, the referring veterinarian had administered an IM injection of dexamethasone sodium phosphate and 3 days thereafter started the dog on an 8-day course of firocoxib. Treatment with both medications was repeated 3

months prior to evaluation. The owner reported that the dog's signs of pain improved during treatment but would return as soon as treatment was stopped. Signs of pain slowly progressed, and at 1 month prior to evaluation, the dog's appetite was reduced. Radiographic imaging of the cervical portion of the vertebral column was performed, and findings were unremarkable. No other regions of the vertebral column were radiographed at that time.

Neurologic examination

Observation

| | | | | | | | | | | |
|---------|--|---|-----------|--|--------------|--|---------|--|----------|---|
| Mental | Alert | X | Depressed | | Disoriented | | Stupor | | Coma | |
| Posture | Normal | | Head tilt | | Tremor | | Falling | | Other | X |
| Gait | Normal | X | Ataxia | | Pelvic limbs | | All 4 | | Circling | |
| Paresis | Pelvic limbs | | Tetra | | Hemi | | Mono | | | |
| Other | The dog maintained a neutral to lowered head position. | | | | | | | | | |

Key: 4 = Exaggerated, clonus; 3 = Exaggerated; 2 = Normal; 1 = Diminished; 0 = None; NE = Not evaluated.

Postural reactions

| | Left forelimb | Right forelimb | Left hind limb | Right hind limb |
|----------------------------|---------------|----------------|----------------|-----------------|
| Wheelbarrow | 2 | 2 | | |
| Hopping | 2 | 2 | 2 | 2 |
| Extensor postural thrust | | | 2 | 2 |
| Proprioceptive positioning | 2 | 2 | 2 | 2 |
| Hemistand/walk | 2 | 2 | 2 | 2 |
| Placing-tactile | 2 | 2 | | |
| Placing-visual | 2 | 2 | | |

Spinal reflexes

| | Left forelimb | Right forelimb | Left hind limb | Right hind limb |
|------------------|---------------|----------------|----------------|-----------------|
| Quadriceps | | | 2 | 2 |
| Extensor carpi | 2 | 2 | | |
| Flexion | 2 | 2 | 2 | 2 |
| Crossed extensor | 2 | 2 | 2 | 2 |
| Perineal | | | 2 | 2 |

Cranial nerves

| | L | R | | L | R | Comments |
|--|---|---|-------------------------|---|---|----------|
| II, VII-Vision menace | 2 | 2 | VIII-Nystagmus, resting | 2 | 2 | |
| II, III-Pupils resting | 2 | 2 | VIII-Nystagmus, change | 2 | 2 | |
| Stim L | 2 | 2 | V-Sensation | 2 | 2 | |
| Stim R | 2 | 2 | VII-Facial mm | 2 | 2 | |
| II-Fundus | 2 | 2 | V, VII-Palpebral flex | 2 | 2 | |
| III, IV, VI-Strabismus, resting | 2 | 2 | IX, X-Gag | 2 | 2 | |
| III, IV, VI, VIII-Strabismus, position | 2 | 2 | XII-Tongue | 2 | 2 | |

Sensation (Locate and describe any abnormality)

| | | |
|------------------|----|---|
| Hyperesthesia | 4 | Reduced range of motion of the neck with mild fasciculations and spasms during direct palpation |
| Superficial pain | NE | |
| Cutaneous reflex | 2 | |
| Deep pain | NE | |

What is the problem? Where is the lesion? What are the most probable causes of this problem? What is your plan to establish a diagnosis? Please turn the page.

Assessment

Anatomic diagnosis

| Problem | Rule out location |
|--|-------------------------------------|
| Cervical hyperesthesia and decreased range of motion of the neck | C1-C5 or C6-T2 spinal cord segments |

Likely location of I lesion

C1-C5 spinal cord segments

Etiologic diagnosis—Differential diagnoses for painful cervical myelopathy included degenerative disk disease, neoplasia (meningioma, glial tumor, round cell tumor, or various sarcomas), infectious meningitis or myelitis (protozoal, tick-borne, fungal, or bacterial infection), autoimmune inflammatory myelopathy (steroid responsive meningitis or meningo-myelitis of unknown origin), or infectious or autoimmune polymyositis. A CBC and serum biochemical profile were performed to assess for systemic illness and as part of preanesthesia evaluation. Magnetic resonance imaging of the cervical portion of the vertebral column was performed to identify abnormalities of the spinal cord, peripheral nerves, and surrounding structures of the neck, which prompted further imaging of the thoracic and lumbar portions of the vertebral column. A sample of CSF was collected from the cerebellomedullary junction and analyzed for evidence of meningitis or myelitis related to infectious or autoimmune disease.

Diagnostic test findings—The results of the CBC were unremarkable. The serum biochemical profile revealed moderate hyperglobulinemia (5.5 g/dL; reference range, 2.5 to 4.5 g/dL). The dog was anesthetized, and MRI^a was performed. Sagittal T2-weighted, sagittal STIR, and dorsal T1-weighted images of the entire vertebral column and transverse T2-weighted and STIR images of the vertebral areas of interest were reviewed. Transverse T1-weighted pre- and postcontrast (gadolinium administered at a dose of 0.2 mg/kg [0.09 mg/lb], IV) images through the thoracic and lumbar portions of the vertebral column were obtained on the basis of the MRI findings. There were hyperintense T2-weighted and STIR (**Figure 1**) lesions involving most of the C4 and C6 vertebral bodies, T8 and T10 vertebral bodies (these lesions extended laterally to involve the right proximal portion of the 8th rib and left proximal portion of the 10th rib, respectively), and L5 vertebral body. All affected vertebrae had effacement of the surrounding cortical margins. There was also suspicion for a similar but less invasive lesion of the cranial aspect of the T4 vertebral body. The L5 vertebral lesion also appeared to extend dorsally to involve the dorsal laminae and pedicles bilaterally as well as extend into the overlying epaxial musculature. All vertebral changes were without evidence of spinal cord compression. There

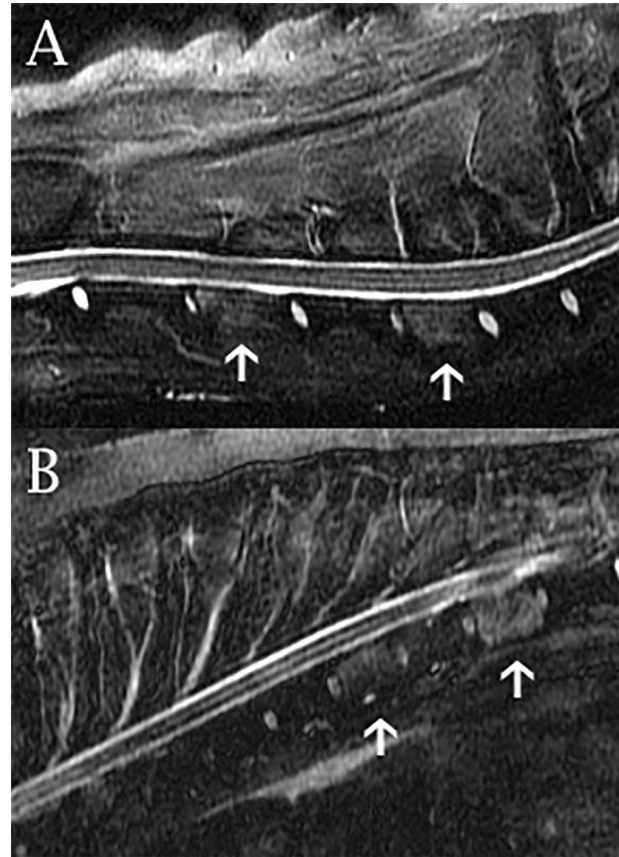


Figure 1—Midline sagittal STIR MRI images of the cervical (A) and thoracic (B) portion of the vertebral column of a 5-year-old Australian Cattle Dog mix that was evaluated because of a 6-month history of progressive signs of neck pain. There are STIR hyperintense lesions (arrows) involving most of the C4 and C6 (A) and T8 and T10 (B) vertebral bodies. No evidence of intervertebral disk involvement or spinal cord compression is identified at these regions.

was also dorsal circumferential T2-weighted and STIR hyperintensity surrounding the spinal cord at the level of the L3-4 intervertebral disk space without spinal cord compression. On transverse pre- and postcontrast T1-weighted images of the thoracic and lumbar portions of the vertebral column, there was mild heterogeneous contrast enhancement of the abnormal L5 vertebral body and surrounding tissues as well as of the lesion centered at the T8 and T10 vertebral bodies. There was also abnormal contrast enhancement of the dorsal portion of the circumfer-

entail tissue at the level of the L3-4 intervertebral disk space.

The MRI findings were consistent with multifocal aggressive bony lesions of a malignant neoplasm (multiple myeloma, another round cell tumor, or metastatic invasion from a remote primary site). Infectious osteomyelitis could not be ruled out but was considered less likely given the appearance and extent of the lesions. Analysis of the CSF sample revealed marginally high protein concentration (34 mg/dL; reference range, 0 to 30 mg/dL) but no cytologic abnormalities. Because of the MRI changes and hypergammaglobulinemia, serum protein electrophoresis was performed, which revealed polyclonal gammopathy consistent with acute inflammatory disease (ie, low albumin component, high α_2 -globulin component, and high β_2 -globulin component). A serum sample was submitted for serologic testing for antibodies against *Coccidioides* spp, *Aspergillus* spp, *Histoplasma* spp, *Blastomyces* spp, and *Cryptococcus* spp. Pending the results of the diagnostic testing, treatment of the dog with tramadol (75 mg, PO, q 8 to 12 h) and later gabapentin (300 mg, PO, q 12 h) was started for pain management. Serologic testing (by enzyme immunoassay) revealed that the dog was positive for anti-*Coccidioides* IgG (titer, > 80.0 [< 8.0 = negative, 8.0 to 9.9 = intermediate, and > 10.0 = positive]). Results of all other fungal serologic testing were negative. The dog was then administered voriconazole (100 mg, PO, q 12 h). Within 4 months after starting the initial treatment with voriconazole, the dog was described as normal by the owner. Repeated assessments of anti-*Coccidioides* antibody titer were performed at 4 and 10 months after diagnosis; the dog remained seropositive at 4 months but was seronegative at 10 months. Voriconazole administration was continued for 1 month after confirmation of the dog's seronegative status. A recheck assessment of the dog's anti-*Coccidioides* antibody titer at 3 months after stopping voriconazole was once again positive (titer > 80.0), but despite this finding, the dog remained clinically normal. Voriconazole (100 mg, PO, q 12 h) administration was restarted, and a recheck assessment of the dog's serum anti-*Coccidioides* antibody titer at 6 and 12 months after restarting medication was recommended.

Comments

Coccidioidomycosis is a disease that develops secondary to inhalation of fungal arthroconidia spores and results most commonly in primary pulmonary infections.¹ Most dogs with coccidioidomycosis have no clinical signs or mild signs of lower respiratory tract infection (eg, chronic cough, fever, anorexia, and weight loss). Disseminated disease develops in an estimated 20% to 42% of infected dogs²; it most commonly affects the long bones in dogs but can affect nearly all tissues of the body.³ Clinical signs associated with vertebral body infection are typically lim-

ited to signs of pain; however, pathological fracture or extension of the infection resulting in meningitis may also occur with vertebral disease.⁴ An estimated 10% of dogs and cats with coccidioidomycosis of the CNS have high serum globulin concentration,⁵ as was evident in the dog of the present report. In human medicine, MRI is considered the ideal imaging technique for detection of vertebral coccidioidomycosis and provides a more sensitive means than radiography for identification of bony lesions.⁴ Analysis of a CSF sample reveals high protein concentration in approximately 71% of cases, but pleocytosis is only reported for 29% of cases.⁵ The gold standard method for the diagnosis of fungal disease that affects the vertebrae is assessment of serum antibody titers.⁶

Diagnosis of *Coccidioides* infection can be difficult on the basis of advanced diagnostic imaging findings because the appearance of lesions associated with coccidioidomycosis may resemble that of several neoplastic processes. When there is disk involvement, an infectious process is considered most likely because tumors rarely cross intervertebral disk spaces.⁴ The case described in the present report was somewhat of a diagnostic challenge given that none of the intervertebral disks were involved and there were multiple, independent sites of vertebral involvement. In addition, there was no radiographic evidence of vertebral changes in the dog. In advanced states of the disease, changes in the vertebrae can often be detected radiographically and appear as irregular and poorly marginated bony lysis affecting the vertebral bodies or other vertebral regions, commonly with irregularly shaped periosteal reaction.²

A drawback of serologic testing for coccidioidomycosis in dogs is that negative results of assessments of serum anti-*Coccidioides* IgG or IgM titer do not rule out *Coccidioides* infection.¹ Among dogs with coccidioidomycosis, the percentage of false-negative serologic test results is estimated to be as high as 5% to 10%.⁷ Interpretation of serologic assessments is further complicated by the fact that low-positive test results may be obtained for clinically normal dogs living in southwestern regions of the United States.⁸ For the dog of the present report, the anti-*Coccidioides* IgG titer was > 10 times the cutoff value for seropositivity, which provided strong evidence of an active infection even though the dog resided in southwest Texas.

There is no standard protocol for medication selection and duration of treatment of coccidioidomycosis or for follow-up monitoring of animals with coccidioidomycosis. Administration of azole antifungals is commonly recommended. Fluconazole is often chosen when there is CNS involvement because of the drug's blood-brain barrier penetration⁹; for the dog of the present report, voriconazole was administered because of clinician preference. Treatment duration of 6 to 12 months is commonly recommended for dogs and cats with nondisseminated coccidioidomycosis; in cases of disseminated infection, treatment periods of 1 or more years is often considered

necessary.⁸ Conversion to a seronegative status is considered uncommon. The dog of the present report was seronegative for anti-*Coccidioides* antibodies after 10 months of treatment; however, the repeated titer assessment at 14 months after initial diagnosis revealed the dog's return to a seropositive status, and voriconazole treatment was restarted. In human medicine, recurrence of disease is common after medications are discontinued, and lifelong treatment is often required.¹⁰ It is estimated that 25% of dogs with coccidioidomycosis have recurrence of disease after cessation of treatment; therefore, continued monitoring for recurrence of signs is necessary long term.⁸ Prognosis for dogs with coccidioidomycosis is variable; prognosis is good for dogs with pulmonary involvement alone but is generally considered guarded to poor for dogs with multiple bone or CNS involvement.⁷ An initially positive response to prompt treatment suggests a better prognosis even in severe cases. The risk of a poor outcome increases when treatment is delayed, when there is a poor response to treatment, or when adverse effects of treatment, such as hepatotoxicosis, develop.⁶ In human medicine, immunologic factors have a role in response to and long-term success of treatment; in dogs with coccidioidomycosis, similar factors are suspected to have a role in the development of systemic illness and response to treatment.⁶ Fortunately, despite the extensiveness of the vertebral lesions, the dog of the present report responded very well to treatment with a reported return to apparent normalcy within the first 4 months of treatment. Unfortunately, although a seronegative status was achieved at 10 months after starting treatment, the dog had returned to a seropositive status 2 months after discontinuation of voriconazole, necessitating recommencement of treatment.

This feature is published in coordination with the American College of Veterinary Internal Medicine on behalf of the specialty of neurology. Contributors to this feature should contact Dr. Helen L. Simons (hsimons@avma.org) for case submission forms. Submissions will be sent to Dr. Karen Kline, DVM, DACVIM, for her review, except when Dr. Kline is an author.

Footnotes

- a. SIGNA MRI machine 1.5T, GE Healthcare, Waukesha, Wis.

References

1. Shubitiz LF, Dial SM. Coccidioidomycosis: a diagnostic challenge. *Clin Tech Small Anim Pract* 2005;20:220-226.
2. Johnson LR, Herrgesell EJ, Davidson AP, et al. Clinical, clinicopathologic, and radiographic findings in dogs with coccidioidomycosis: 24 cases (1995-2000). *J Am Vet Med Assoc* 2003;222:461-466.
3. Sykes JE. Coccidioidomycosis. In: *Canine and feline infectious diseases*. St Louis: Elsevier Saunders, 2014;613-623.
4. Wyatt S, De Risio L, Driver C, et al. Neurological signs and MRI findings in 12 dogs with multiple myeloma. *Vet Radiol Ultrasound* 2019;60:409-415.
5. Bentley RT, Heng HG, Thompson C, et al. Magnetic resonance imaging features and outcome for solitary central nervous system coccidioides granulomas in 11 dogs and cats. *Vet Radiol Ultrasound* 2015;56:520-530.
6. Davidson AP, Shubitiz LF, Alcott CJ, et al. Selected clinical features of coccidioidomycosis in dogs. *Med Mycol* 2019;57:S67-S75.
7. Greene RT. Coccidioidomycosis and paracoccidioidomycosis. In: Greene CE, ed. *Infectious diseases of the dog and cat*. 4th ed. St Louis: Saunders Elsevier, 2006;598-608.
8. Graupmann-Kuzma A, Valentine BA, Shubitiz LF, et al. Coccidioidomycosis in dogs and cats: a review. *J Am Anim Hosp Assoc* 2008;44:226-235.
9. Davidson AP. Coccidioidomycosis. In: Ettinger SJ, ed. *Textbook of veterinary internal medicine*. 7th ed. St Louis: Saunders Elsevier, 2010;992-996.
10. Dewsnup DH, Galgiani JN, Graybill JR, et al. Is it ever safe to stop azole therapy for *Coccidioides immitis* meningitis? *Ann Intern Med* 1996;124:305-310.

This report was submitted by Katharine J. Russell, MVB, and Danielle L. D. Powers, DVM; from MissionVet Specialty and Emergency, San Antonio, TX 78249.

Address correspondence to Dr. Russell (Katharine.Russell@ucdconnect.ie).