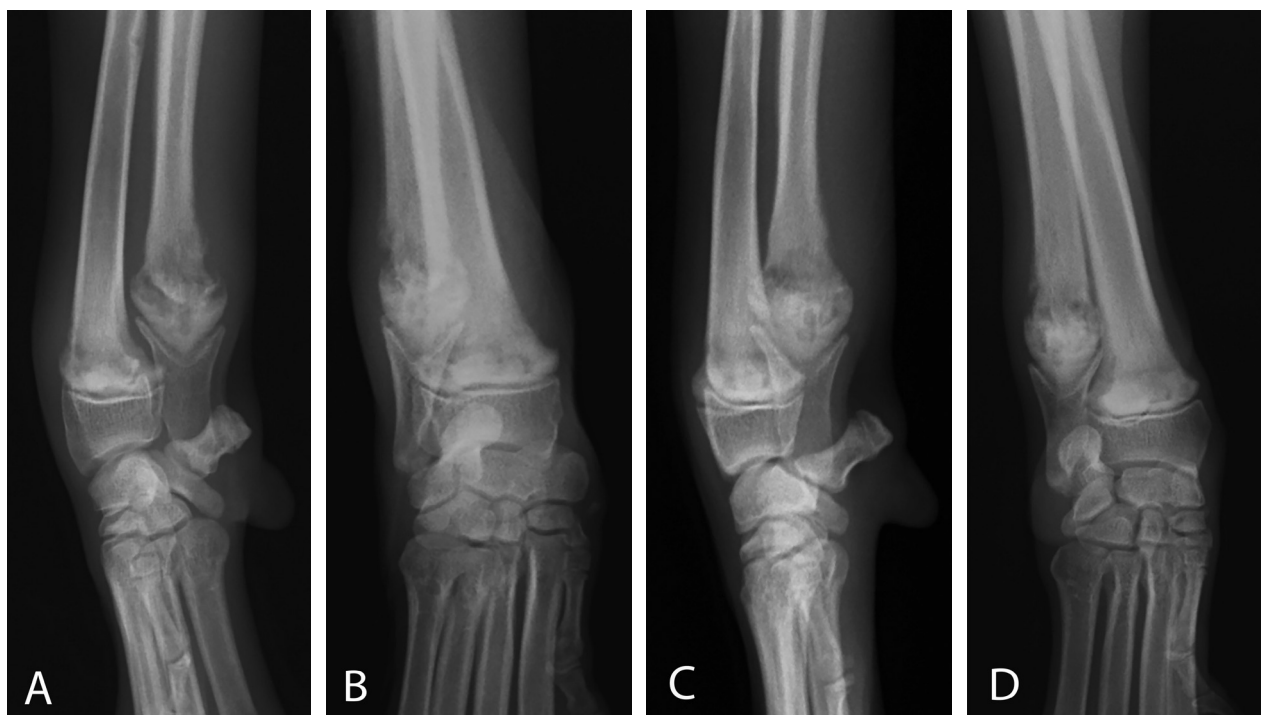



## What Is Your Diagnosis?



**Figure 1**—Lateral (A and C) and craniocaudal (B and D) radiographic views of the distal aspect of left (A and B) and right (C and D) antebrachia of a 4-month-old sexually intact female mixed-breed dog examined for a 5-day history of anorexia combined with weight-bearing lameness of the left forelimb and a 3-day history of fever.

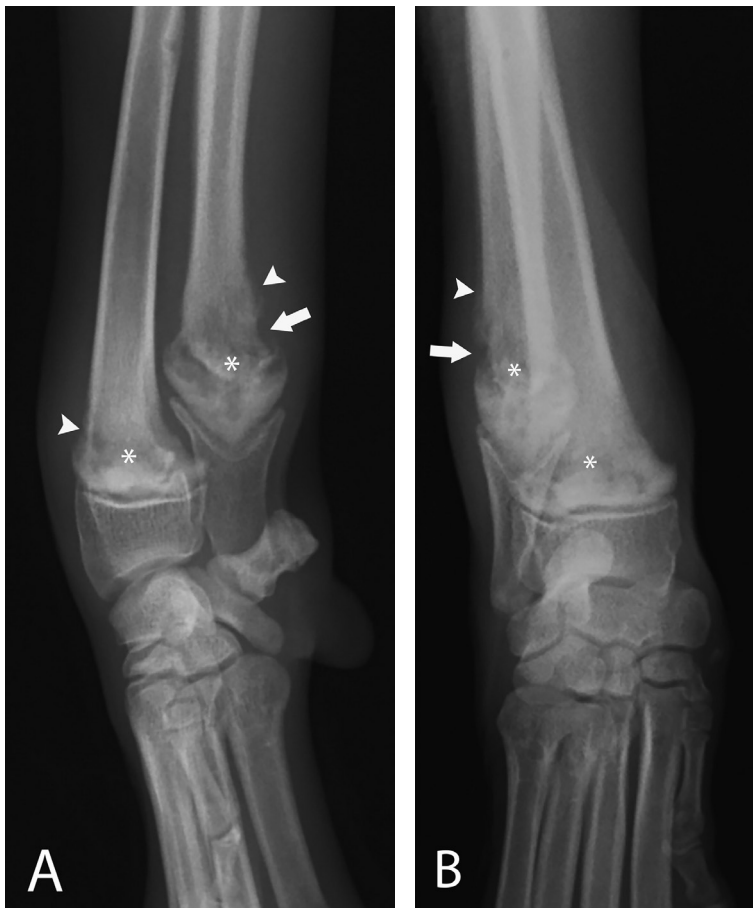
### History

A 4-month-old 5-kg (11-lb) sexually intact female mixed-breed dog was examined for a 5-day history of anorexia combined with weight-bearing lameness of the left forelimb and a 3-day history of fever (40.6°C [105.1°F]; reference range, 37.8° to 39.3°C [100.0° to 102.8°F]). According to the owner, the dog had no history of trauma. During physical examination, the dog was lethargic and normothermic (38.6°C [101.5°F]). Both distal antebrachial areas had mild soft tissue swelling that was warm to the touch and elicited signs of pain on palpation. Radiographs of the distal aspects of both antebrachia were obtained (**Figure 1**).

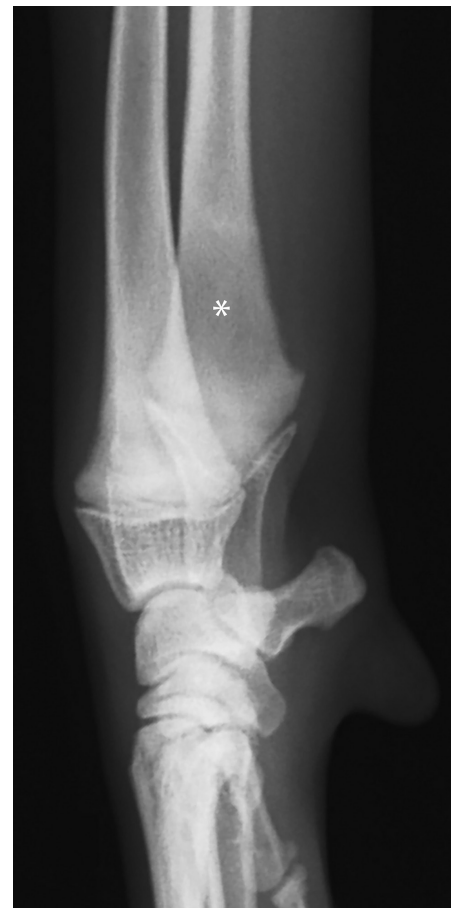**Determine whether additional imaging studies are required, or make your diagnosis from Figure 1—then turn the page →**

This report was submitted by Tzu-Yi Ma, DVM, MS; Hsian-Min Chiu, DVM, MS; Hsien-Chi Wang, DVM, PhD; and Kuan-Sheng Chen, DVM, MVS, PhD; from the Veterinary Medical Teaching Hospital (Ma, Wang, Chen) and Department of Veterinary Medicine (Wang, Chen), College of Veterinary Medicine, National Chung Hsing University, Taichung 402, Taiwan; and Yung Shin Animal Hospital, 428 Zhuangjing Rd, Taipei 110, Taiwan (Chiu).

Address correspondence to Dr. Chen (kschen@dragon.nchu.edu.tw).



**Figure 2**—Same left antebrachial radiographic images as in Figure 1. A moth-eaten pattern of lysis (asterisks) is present in the distal metaphyseal regions of the radius and ulna. Proximal to these areas of lysis, faint periosteal reactions (arrowheads) are evident. In addition, an area of cortical lysis (arrows) is visible at the caudolateral aspect of the ulna. The radial and ulnar distal physes appear normal. Mild soft tissue swelling is evident in the distal aspect of the antebrachium.



**Figure 3**—Lateral radiographic image of the distal aspect the left antebrachium of the dog in Figures 1 and 2 after 18 days of antimicrobial treatment. An area of mildly low radiolucency (asterisk) is present in the distal metaphyseal region of the ulna. No visible cortical lysis or periosteal reaction can be identified. The distal physes of the radius and ulna appear normal.

## Diagnostic Imaging Findings and Interpretation

Findings on orthogonal radiographic images were similar for both forelimbs. A moth-eaten pattern of bone lysis was evident in the distal metaphysis of each radius and ulna (**Figure 2**). Proximal to these areas of lysis, faint indications of smooth periosteal reactions were evident on each radius and ulna. In addition, an area of cortical lysis was visible at the caudolateral aspect of the distal metaphysis of each ulna. Bilaterally, the distal physes of the radius and ulna appeared normal, and mild soft tissue swelling was present in the distal aspect of each antebrachium. Differential diagnoses included hematogenous osteomyelitis and hypertrophic osteodystrophy (HOD). Primary or metastatic neoplasia were considered less likely because of the dog's young age.

## Treatment and Outcome

Ultrasonographically guided fine-needle aspiration of the lytic lesion in the metaphyseal region of

the left ulna was performed for bacterial culture and susceptibility testing, and pending results, the dog was discharged with a prescription of firocoxib (5.0 mg/kg [2.3 mg/lb], PO, q 24 h for 6 days). A *Chryseobacterium* sp was identified on bacterial culture of the aspirate, and hematogenous osteomyelitis was diagnosed. On the basis of susceptibility results, the dog was treated with levofloxacin (7.0 mg/kg [3.2 mg/lb], PO, q 12 h for 7 days) and trimethoprim-sulfamethoxazole (20.0 mg/kg [9.1 mg/lb], PO, q 12 h for 28 days). Results of a recheck radiographic examination 18 days after the start of antimicrobial treatment indicated improvement, with only an area of mildly low radiolucency remaining in the distal aspect of the left ulna (**Figure 3**) and an area of even less prominent low radiolucency remaining in the distal aspect of the right ulna (not shown). At a recheck examination 4 weeks after the onset of antimicrobial treatment, the dog had neither lameness nor soft tissue swelling, and the owners reported that the dog's activity level and appetite were normal.

## Comments

Hematogenous osteomyelitis and HOD were the most likely differential diagnoses, given the bilateral distribution and metaphyseal location of the lesions, the radiographic characteristics of the lesions, and the dog's age. Hematogenous osteomyelitis occurs most commonly in the metaphysis of long bones, where slower blood flow facilitates deposition of microorganisms.<sup>1</sup> The disease is rare in dogs and cats and is more likely to develop in immunosuppressed or young animals because they have lower leukocyte counts and incompetence of the tissue-based phagocytes.<sup>2</sup> The most common clinical signs of long bone metaphyseal hematogenous osteomyelitis are pyrexia, soft tissue swelling, anorexia, lameness, and signs of pain, and radiographic features include soft tissue swelling, cortical lysis, destruction of metaphyseal bone, and new bone formation,<sup>2</sup> consistent with the physical and radiographic findings in the dog of the present report. However, HOD, a systemic developmental disease of rapidly growing young dogs (most commonly large- and giant-breed dogs) between the ages of 2 and 7 months, can have similar signs,<sup>3</sup> making differentiation between the 2 diseases difficult.

Metaphyses of long bones are predominantly affected in both hematogenous osteomyelitis and HOD, but HOD may further cause early physal closure and angular deformity. In humans and foals, growth disturbance and angular deformity are also expected with osteomyelitis because metaphyseal arterioles traverse the physal region to connect with the epiphyseal sinusoid.<sup>1</sup> In contrast, hematogenous osteomyelitis in dogs and cats rarely affects the physes because of the lack of transphysal vessels, and infection is thus restricted to the metaphysis. Therefore, early physal closure and angular deformity are unusual in dogs and cats with hematogenous osteomyelitis.<sup>1,2</sup> Although neoplasia was a less likely diagnosis in the dog of the present report because of the dog's young age, polyostotic lymphoma in young dogs has been reported<sup>4</sup> and can affect the metaphyses of multiple long bones with apparent lytic lesions and minimal periosteal reactions. Additionally, an active periosteal reaction in the distal aspect of the radii and ulnae in immature dogs should be differentiated from the cut back zone (the area of irregular and hazy bone margins where the metaphysis remodels to the narrower diaphysis during bone growth), which is normal in young, rapidly growing bones without the presence of soft tissue swelling.<sup>5</sup> Careful radiographic evaluation for the presence of concurrent lesions (eg, cortical lysis) in metaphyseal bone may help differentiate an aggressive periosteal reaction from the cut back

zone. Because of considerable overlap in clinical signs and radiographic findings for HOD, hematogenous osteomyelitis, and neoplasia, sampling the lesions for histologic examination and bacterial culture is often required for a definitive diagnosis.<sup>2,4</sup>

*Chryseobacterium* spp are widely distributed in the environment, such as in water, soil, and dairy and animal products,<sup>6</sup> and are often isolated from aquatic animals, amphibians, and fish, but are rare in domestic animals.<sup>7</sup> To our knowledge, isolation of a *Chryseobacterium* sp from a dog with hematogenous osteomyelitis had not been reported, whereas common bacteria isolated from dogs with hematogenous osteomyelitis are *Staphylococcus* spp, *Streptococcus* spp, *Klebsiella pneumoniae*, and *Clostridium* spp.<sup>1,2</sup> Known as multidrug-resistant bacteria, *Chryseobacterium* spp produce metallo- $\beta$ -lactamase and therefore are often resistant to aminoglycosides, tetracyclines, chloramphenicol, erythromycin, clindamycin, first and second generation cephalosporins, aztreonam, and imipenem.<sup>6</sup> However, levofloxacin and trimethoprim-sulfamethoxazole have been reported<sup>6</sup> to be effective against *Chryseobacterium* spp, and results of bacterial culture and susceptibility testing performed on a fine-needle aspirate sample from a lytic lesion in the dog of the present report indicated that the isolated *Chryseobacterium* sp was susceptible to both. Further, for successful treatment of osteomyelitis, the duration of antimicrobial treatment should be 4 to 6 weeks.<sup>1,2</sup>

## Acknowledgments

The authors received no extra-institutional funding associated with the present report, and the authors declare that there were no conflicts of interest.

## References

1. Dunn JK, Dennis R, Houlton JEF. Successful treatment of two cases of metaphyseal osteomyelitis in the dog. *J Small Anim Pract* 1992;33:85-89.
2. Rabillard M, Souchu L, Niebauer GW, et al. Haematogenous osteomyelitis: clinical presentation and outcome in three dogs. *Vet Comp Orthop Traumatol* 2011;24:146-150.
3. Franklin MA, Rochat MC, Broaddus KD. Hypertrophic osteodystrophy of the proximal humerus in two dogs. *J Am Anim Hosp Assoc* 2008;44:342-346.
4. Langley-Hobbs SJ, Carmichael S, Lamb CR, et al. Polyostotic lymphoma in a young dog: a case report and literature review. *J Small Anim Pract* 1997;38:412-416.
5. Riser WH. Radiographic differential diagnosis of skeletal diseases of young dogs. *Vet Radiol Ultrasound* 1964;5:15-27.
6. Lee CH, Lin WC, Chia JH, et al. Community-acquired osteomyelitis caused by *Chryseobacterium meningosepticum*: case report and literature review. *Diagn Microbiol Infect Dis* 2008;60:89-93.
7. Zamora L, Vela AI, Palacios MA, et al. First isolation and characterization of *Chryseobacterium shigense* from rainbow trout. *BMC Vet Res* 2012;8:77.