



Anesthesia Case of the Month

History

A cardiac murmur was discovered coincidentally during a routine preventative care examination of a 6-month-old 7.0-kg (15.4-lb) female French Bulldog. As a result, the dog was referred for further evaluation, and was examined 2 weeks later at the University Veterinary Clinic of the Latvia University of Agriculture. On initial physical examination, a grade 4/6 systolic cardiac murmur was evident on auscultation of the right side of the thorax. No clinical signs of cardiac decompensation were noted. A 6-lead ECG examination indicated the presence of respiratory sinus arrhythmia and signs of right ventricular enlargement (ie, deep S waves most notable in lead I and slight right axis deviation). Continuous-wave Doppler echocardiography revealed supraaortic pulmonary artery stenosis characterized by a focal decrease in vessel diameter (1.28 cm to 0.566 cm), high blood velocity in the affected pulmonary artery segment (691 cm/s [pressure gradient, 191 mm Hg]), and moderate hypertrophy of the right ventricle. On the basis of these findings, the diagnosis was severe congenital pulmonic stenosis and stage B1 heart disease, according to American College of Veterinary Internal Medicine consensus guidelines.¹ Therefore, long-term treatment with atenolol (12.5 mg/kg [5.7 mg/lb], PO, q 12 h) was initiated; treatment of the pulmonary artery stenosis by means of balloon dilation was scheduled for the following month.

Question

The likelihood of a successful outcome for the planned balloon dilation procedure was considered to be highly dependent on the presence of an experienced anesthesiologist and surgical team. As such, should the patient be referred to a hospital at which this pro-

This report was submitted by Alexandru C. Tutunaru, DVM, PhD; Richard Chervenky, DVM, MSc; Valts Ozolins, MD; Charlotte Sandersen, DVM, PhD; and Ilmars Duritis, DVM, PhD; from the University Veterinary Clinic, Faculty of Veterinary Medicine, University of Liège, 4000 Liège, Belgium (Tutunaru, Sandersen); the University Veterinary Clinic, Faculty of Veterinary Medicine, Latvia University of Agriculture, Jelgava, LV-3004, Latvia (Chervenky, Duritis); and the Department of Pediatric Cardiology and Cardiac Surgery, University Children's Hospital, Rīga Stradiņš University, Rīga, LV-1004, Latvia (Ozolins).

Address correspondence to Dr. Tutunaru (actutunaru@ulg.ac.be).

cedure is routinely performed or would it be feasible to provide anesthesia care by means of supervision of an inexperienced anesthesiologist via real-time remote telecommunication? Is it foreseeable that this modality of communication and patient care would allow a sufficiently rapid response to potential changes in the anesthetic status of the patient?

Answer

On careful consideration, we elected to provide anesthesia care assisted via real-time remote telecommunication by an experienced, board-certified anesthesiologist (ACT) located in Liege, Belgium. The remote anesthesiologist was supervising a second-year European College of Veterinary Anesthesia and Analgesia resident. Remote assistance in real time was provided to the anesthesiologist (RC) present in the operating room located in Jelgava, Latvia. Two computers (1 in the operating room in Latvia and 1 in Belgium) were connected through a standard internet connection (**Figure 1**). Communication occurred via an internet video communication application^a that conveyed real-time views of the patient, anesthesia machine, and monitors to the remote anesthesiologist. The chat function was used for voice commu-

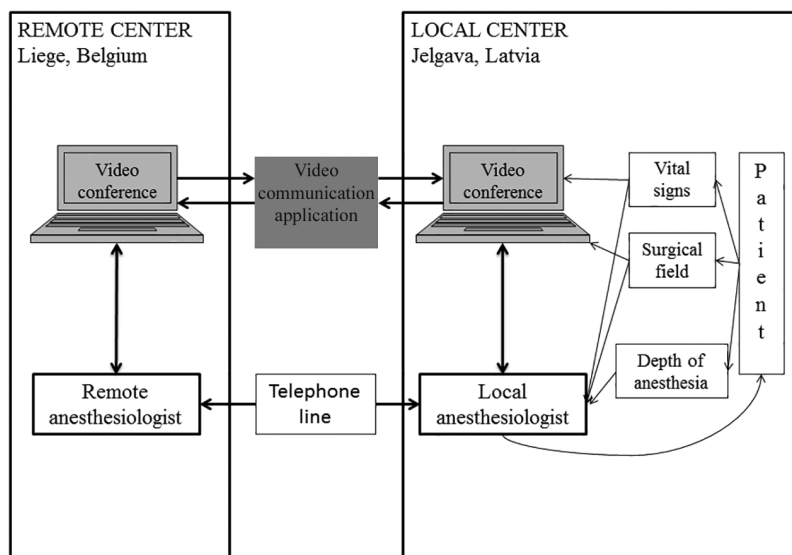


Figure 1—Schematic illustrating the mode of delivery of anesthesia care for a 6-month-old female French Bulldog undergoing balloon valvuloplasty for treatment of pulmonic stenosis. Anesthesia care occurred via real-time remote telecommunication provided by an experienced, board-certified anesthesiologist located in Liege, Belgium, communicating with the local anesthesiologist treating the patient throughout surgery in Jelgava, Latvia. Communication occurred via an internet video communication application that conveyed real-time views of the patient, anesthesia machine, and monitors to the remote anesthesiologist. The chat function was used for voice communication between the local and remote locations. A backup telephone line was available throughout.

nication between the local and remote locations. A telephone connection served as a backup in case of internet connection failure. The entire anesthesia team discussed patient status and details of the anesthesia protocol via email 1 week before the procedure. Throughout the surgery, the supervising remote anesthesiologist was asked to verify details of the anesthesia protocol, monitor the patient, and provide real-time assistance as indicated. All personnel involved in the case communicated in English.

The patient was readmitted to the referral hospital 3 weeks after the initial diagnosis of pulmonic stenosis. Results of the preoperative physical examination were shared with the remote anesthesiologist via video communication. An IV catheter was placed in a cephalic vein, and the dog was premedicated with fentanyl (0.005 mg/kg [0.0023 mg/lb], IV) and midazolam (0.2 mg/kg [0.09 mg/lb], IV). Five minutes later, general anesthesia was induced by means of administration of propofol (2 mg/kg [0.9 mg/lb], IV), and the patient was intubated. Anesthesia was maintained with propofol (250 µg/kg/min [114 µg/lb/min], IV), fentanyl (0.1 µg/kg/min [0.045 µg/lb/min], IV), and lidocaine (33 µg/kg/min [15 µg/lb/min], IV). During anesthesia, the dog was provided with 100% oxygen (3 L/min) via a Mapelson type D breathing circuit and mechanically ventilated. Monitoring included electrocardiography, oscillometry for noninvasive blood pressure measurement, pulse oximetry for determination of oxygen saturation, and capnography for measurement of end-tidal partial pressure of CO₂. Monitored data were recorded every 5 minutes by the local and remote anesthesiologists. Duration of general anesthesia and duration of surgery were 50 and 30 minutes, respectively.

Two incidents occurred during anesthesia that required prompt intervention of the remote anesthesiologist. The first incident occurred 5 minutes after induction of anesthesia; respiratory rate decreased, and the end-tidal partial pressure of CO₂ increased (60 mm Hg). The remote anesthesiologist therefore asked the local anesthesiologist to reduce the propofol infusion rate from 250 µg/kg/min, IV, to 67 µg/kg/min (30 µg/lb/min), IV, and to manually ventilate the dog for several minutes until the patient was normocapnic, which occurred in the next 3 minutes. During the second incident, the dog became hypotensive; mean arterial blood pressure decreased continuously from the time of anesthetic induction to a value of 45 mm Hg after 10 minutes. The remote anesthesiologist advised the local anesthesiologist to administer a 20-mL bolus of a crystalloid (lactated Ringer) solution, IV, over 5 minutes to improve preload and overcome a potential increase in pulmonary vascular resistance. Five minutes after the end of the infusion, mean arterial blood pressure had increased to 65 mm Hg and remained stable (60 to 70 mm Hg) for the duration of anesthesia. The heart rate remained constant during anesthesia and close to the baseline value of 110 beats/min (100 to 120 beats/min).

The balloon valvuloplasty procedure began 20 minutes after induction of anesthesia. A jugular venous catheter was placed by means of the Seldinger technique, and an additional catheter with a deflated balloon tip was advanced through this catheter. The jugular venous catheter was then connected to a pressure transducer, which was calibrated (zero reference point) at the level of the right atrium. The central venous blood pressure and the right ventricular systolic pressure were 16 and 87 mm Hg, respectively. The balloon valvuloplasty procedure that was performed to treat the pulmonic stenosis was followed by a second balloon catheter insertion to confirm the effectiveness of the first dilatation.

The patient recovered without apparent complications and was monitored continuously in the intensive care unit for 24 hours after the procedure. The local anesthesiologist was instructed to monitor for clinical signs of acute hemorrhage, but none were reported. Echocardiography was performed 1 day after the procedure. The pressure gradient in the affected pulmonary artery segment was 72 mm Hg, which was considerably lower than the value (191 mm Hg) recorded 3 weeks before surgery. No evidence of bundle branch block was recorded during or after the procedure. The patient remained in overall good condition, as prior to surgery. Atenolol treatment was continued, and a follow-up echocardiographic examination was scheduled for 3 months after the procedure. During the 3-month follow-up period, the patient showed no apparent adverse effects of the procedure and no signs of cardiac decompensation.

Discussion

Remote delivery of health-care services, also referred to as telemedicine, has been defined as the “delivery of healthcare and sharing of medical knowledge over a distance, using telecommunications systems.”² This approach may be especially useful when access to care is limited and specialists cannot be physically present at the intervention. Remote consultation is often used by radiologists, and real-time remote anesthesia is becoming increasingly common in human medicine. However, reports of real-time remote consultation and communication in veterinary practice are sparse.

Multimedia and telecommunication technologies are continually improving and have increased our ability to readily communicate between locations worldwide. Consequently, technological means of remote consultation have also improved and currently consist of 2 models. The first model is real-time (ie, synchronous) remote consultation, which requires a means of communication between 2 parties (eg, a simple telephone line or video conference equipment) and other peripheral devices that increase the remote specialist's ability to provide patient care. The second model is asynchronous remote consultation (ie, store and forward), which consists of collecting medical data from a patient and sending these data to

a specialist for further analysis and input. Both models have benefited patient care worldwide by increasing access to medical specialists.³

Anesthesia care with real-time remote telecommunication represents an advance because it allows a remote anesthesiologist to be included in the preanesthetic consultation, delivery of anesthesia, and monitoring of the patient. In human medicine, this is a relatively recent initiative that was developed to allow inexperienced anesthesiologists to perform specific procedures under the supervision of a more experienced anesthesiologist. This therefore has allowed for relatively complex surgeries to be performed in remote areas. Early studies⁴⁻⁶ in human medicine describe long-distance anesthesia preadmission consultation, real-time remote anesthetic monitoring, and real-time remote therapeutic propofol administration. One of the first published studies⁷ was a pilot study that assessed the feasibility of real-time remote anesthesia for 20 human patients undergoing thyroid surgery. All patients were successfully anesthetized with a master computer in Montreal connected to a replica computer in Pisa.

Video conferencing has been extensively used in the past decade, and is now a main method of long-distance communication. This inexpensive technology only requires 2 computers with video conference hardware, each connected to the internet. Specific applications can be used to facilitate communication between the 2 parties. A variety of video conference software applications are available for remote consultation in real-time use. Some of them are free downloads^{7a}; others require payment of a fee.^{8b} For the case described in the present report, we chose a free application^a because both the remote and the local anesthesiologist were familiar with it and it was available on both computers.

Remote consultation in real time in the health-care setting has some important limitations. Potential concerns include medical liability issues, effects of loss of the internet connection during anesthesia and surgery, and the requirement for a suitable video conference environment for the remote specialist. A backup telephone connection was available throughout anesthesia for the patient of this report, in case we lost the internet connection. Availability of a backup means of communication at all times is strongly recommended.

Medical liability issues related to practice across different states and different countries must be considered if contemplating delivery of any aspect of patient care via the modality described. In the case of the present report, the local anesthesiologist was fully responsible under Latvian law for the patient's safety. Furthermore, communication may be an issue when the clinicians speak different native languages. Differences in accents may have negative effects on information sharing via telecommunication. The remote and local anesthesiologists managing the patient of this report were specifically chosen to perform

this remote anesthesia assistance in real time because they had successfully worked together previously in person to provide anesthesia care to small animal patients; thus, we did not expect communication to be an issue. The anesthesia protocol was familiar to both anesthesiologists and included drugs that were all available for use in Latvia. To avoid communication or medication errors, the anesthetic drugs planned for use during the balloon valvuloplasty were verified and compared by the remote and local anesthesiologists during preanesthetic planning (**Supplemental Appendix S1**, available at <http://avmajournals.avma.org/doi/suppl/10.2460/javma.250.9.984>).

Pulmonic stenosis is a frequent congenital cardiac abnormality in dogs and one of the few that can be surgically treated. A retrospective review⁹ of 4,480 dogs revealed a 22% incidence of congenital heart disease; pulmonic stenosis was the most frequent abnormality reported (32%). Dogs with congenital pulmonic stenosis are at a high risk of myocardial ischemia and may develop ventricular arrhythmias. However, compared with subaortic stenosis, pulmonic stenosis rarely leads to spontaneous death and is more likely to result in exercise intolerance, syncope, and ascites.¹⁰ The balloon valvuloplasty technique was first used to treat a child with pulmonic stenosis in 1982,¹¹ after a report of a successful outcome in a test procedure in a young English Bulldog 2 years earlier.¹² Balloon valvuloplasty is regarded as a high-risk procedure; however, a retrospective study of 40 dogs reported a positive outcome for 93% (37/40). Three dogs died during the procedure, but all 3 had additional cardiac defects.¹³ A single right coronary artery abnormality is reportedly common in English Bulldogs, and in these dogs, treatment by means of balloon valvuloplasty is not recommended because of a high mortality rate.¹⁴ The anesthetic risks for patients undergoing this procedure were also highlighted in a study by Ramos et al,¹⁵ who concluded that "the successful outcome of anesthesia in these patients requires vigilant monitoring and prompt treatment of anesthetic complications."

We were not able to perform angiography to exclude the presence of an anomalous right coronary artery prior to valvuloplasty for the patient of this report. The incidence of this congenital malformation is reportedly low (0.8%) and is most common in English Bulldogs.⁹ However, if this anomaly had been present in our patient, it could have led to a fatal outcome during the procedure. We therefore suggest that preoperative angiography be performed in patients undergoing valvuloplasty to decrease the risk of death.

For the patient of this report, remote anesthesia assistance in real time allowed us to improve patient care. However, the remote assistance was limited to video conferencing. Veterinary real-time remote anesthesia will likely evolve, and provision of anesthesia care may further develop such that a remote specialist may monitor and directly alter the depth of anesthesia without the assistance of a local anesthesiologist.

This method is being used in human medicine, with automated anesthesia-delivery programs enabling remote control of IV anesthesia drug delivery.⁷

On the basis of our experience, we suggest that real-time remote anesthesia may be a helpful tool for patient care when an anesthesiologist cannot be physically present. It will not replace the expertise of an in-house, experienced, board-certified anesthesiologist, and use of this option should be carefully exercised. The presence of personnel familiar with the environment and with the anesthesiologist present at the patient's side remains the preferred option to maximize the opportunity for a successful outcome.

Footnotes

- a. Skype, version 7.17.0.105, Skype Communications SARI, Luxembourg City, Luxembourg.
- b. GoToMeeting, Citrix Systems UK Ltd, Gerrards Cross, Buckinghamshire, England.

References

1. Atkins C, Bonagura J, Ettinger S, et al. Guidelines for the diagnosis and treatment of canine chronic valvular heart disease. *J Vet Intern Med* 2009;23:1142-1150.
2. Strode SW, Gustke S, Allen A. Technical and clinical progress in telemedicine. *JAMA* 1999;281:1066-1068.
3. Chatrath V, Attri JP, Chatrath R. Telemedicine and anaesthesia. *Indian J Anaesth* 2010;54:199-204.
4. Wong DT, Kamming D, Saleniaks ME, et al. Preadmission anaesthesia consultation using telemedicine technology: a pilot study. *Anesthesiology* 2004;100:1605-1607.
5. Cone SW, Gehr L, Hummel R, et al. Remote anaesthetic monitoring using satellite telecommunications and the internet. *Anesth Analg* 2006;102:1463-1467.
6. Ihmsen H, Naguib K, Schneider G, et al. Teletherapeutic drug administration by long distance closed-loop control of propofol. *Br J Anaesth* 2007;98:189-195.
7. Hemerling TM, Arbeid E, Wehbe M, et al. Transcontinental anaesthesia: a pilot study. *Br J Anaesth* 2013;110:758-763.
8. Fiadjoe J, Guraney H, Muralidhar K, et al. Telemedicine consultation and monitoring for pediatric liver transplant. *Anesth Analg* 2009;108:1212-1214.
9. Oliveira P, Domenech O, Silva J, et al. Retrospective review of congenital heart disease in 976 dogs. *J Vet Intern Med* 2011;25:477-483.
10. Francis AJ, Johnson MJS, Culshaw GC, et al. Outcome in 55 dogs with pulmonic stenosis that did not undergo balloon valvuloplasty or surgery. *J Small Anim Pract* 2011;52:282-288.
11. Kan JS, White RI, Mitchell SE, et al. Percutaneous balloon valvuloplasty: a new method for treating congenital pulmonary valve stenosis. *N Engl J Med* 1982;307:540-542.
12. Buchanan JW, Anderson JH, White RI. The 1st balloon valvuloplasty: an historical note. *J Vet Intern Med* 2002;16:116-117.
13. Stafford Johnson M, Martin M. Results of balloon valvuloplasty in 40 dogs with pulmonic stenosis. *J Small Anim Pract* 2004;45:148-153.
14. Kittleson M, Thomas W, Loyer C, et al. Letter to the editor. *J Vet Intern Med* 1992;6:250-251.
15. Ramos RV, Monteiro-Steagall BP, Steagall PVM. Management and complications of anaesthesia during balloon valvuloplasty for pulmonic stenosis in dogs: 39 cases (2000 to 2012). *J Small Anim Pract* 2014;55:207-212.