

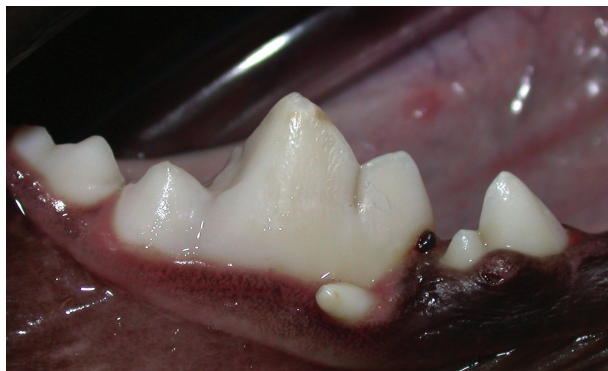

Figure 1—Photograph of the right mandibular fourth premolar tooth and first and second molar teeth of a 5-month-old 27.2-kg (59.8-lb) Alaskan Malamute that was evaluated because of a suspected foreign body associated with the right mandibular first molar tooth.

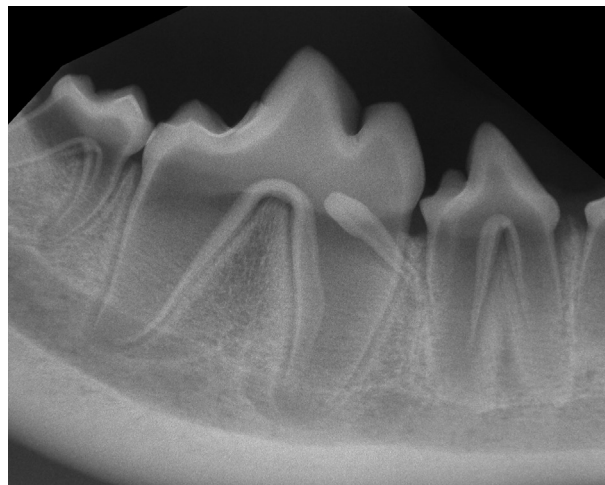


Figure 2—Intraoral radiographic view of the caudal aspect of the right mandible (including the fourth premolar tooth, first molar tooth, and rostral portion of the second molar tooth) of the same dog as in Figure 1. The image was obtained with a parallel technique.

History and Physical Examination Findings

A 5-month-old 27.2-kg (59.8-lb) sexually intact male Alaskan Malamute was referred to the Dentistry and Oral Surgery Department of a specialty hospital for evaluation of a white suspected foreign body associated with the right mandibular first molar tooth. The patient had no pertinent medical history.

On physical examination, the patient was bright, alert, and responsive. No signs of systemic disease were detected. Results of a CBC and serum biochemical profile were unremarkable. An initial oral examination of the unsedated patient was performed and revealed what appeared to be a supernumerary tooth on the mesiobuccal gingival margin of the right mandibular first molar tooth (**Figure 1**).

The patient was anesthetized, and a complete oral examination with periodontal probing and charting was performed. Full-mouth intraoral radiographs were obtained; a view of the caudal part of the right mandible is provided (**Figure 2**). Relevant clinical findings included mild localized gingivitis, plaque, and calculus accumulation. Partial eruption of the right and left maxillary canine teeth and right and left mandibular canine and third premolar teeth was noted. Mild abrasion and staining on the coronal third of the principle cusp of the right mandibular first molar tooth were also observed. A 3-mm crown-like structure resembling a supernumerary tooth at the mesiobuccal gingival surface of the right mandibular first molar tooth was discovered.

Determine whether additional studies are required, or make your diagnosis, then turn the page →

This report was submitted by Javier Collados, DVM, and Carlos A. Rice, DVM; from the Dentistry and Oral Surgery Department of the Veterinaria Specialty Hospital, Avda Reina Victoria, 9 28430 Alpedrete, Madrid, Spain (Collados); and the Dentistry and Oral Surgery Department, Center for Animal Referral and Emergency Services, 2010 Cabot Blvd, West Ste D, Langhorne, PA 19047 (Rice).

Address correspondence to Dr. Collados (javiercollados2@gmail.com).

Diagnostic Imaging Findings and Interpretation

Intraoral radiographs of the caudal aspect of the right mandible confirmed the suspected finding of a supernumerary tooth (**Figure 3**). This supernumerary tooth measured 15 mm in length and resembled an incisor or first premolar tooth. The crown of this supernumerary tooth was located on the mesio-buccal aspect of the right mandibular first molar tooth, with the root angled toward the distal root of the fourth premolar tooth. A well-defined periodontal ligament space could be traced along the entire length of the tooth root. In addition, a periapical lucency surrounded by moderately dense bone suggestive of a periapical granuloma or abscess was associated with the supernumerary tooth.

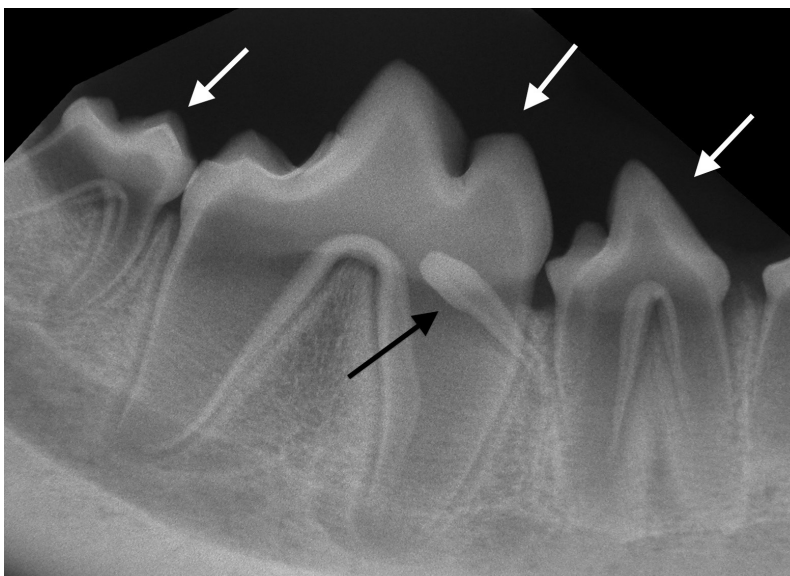


Figure 3—Same intraoral radiographic view as in Figure 2. The fourth premolar tooth, first molar tooth, and rostral part of the second molar tooth are indicated (white arrows). A supernumerary tooth (black arrow) is present.

Treatment and Outcome

With the patient under general anesthesia, a right inferior alveolar nerve block (0.6 mL [3 mg]) was performed with bupivacaine hydrochloride (5 mg/mL). A sulcular incision was performed around the supernumerary tooth with a No. 15 scalpel blade. A 2-mm luxator was used to extract the tooth without complications. One perioperative injection of meloxicam (0.2 mg/kg [0.09 mg/lb], SC) was administered.

The patient recovered well after surgery and was discharged from the hospital. The owners were instructed to administer meloxicam (0.1 mg/kg [0.045 mg/lb], PO, q 24 h, for 5 days) and tramadol hydrochloride (2 mg/kg [0.91 mg/lb], PO, q 12 h, for 1 day) for management of postoperative discomfort. The extracted tooth was submitted for histopathologic evaluation, which revealed a well-organized structure with a central pulp cavity surrounded by dentin and a crown covered by enamel, consistent with a tooth structure. Histologic analysis also confirmed the presence of a periapical granuloma. Reexamination was performed 14 days after the surgical procedure. No signs of pain or discomfort were detected, and the surgery site had completely healed.

Comments

Intraoral radiography (especially full-mouth radiography) is essential in evaluating unusual dental structures as in the dog of this report. In 1 study,¹ full-mouth intraoral radiographs provided additional, clinically useful, or essential information in 163 of 226 (72%) dogs imaged. Although results of histopathologic examination confirmed that the structure was a tooth, dental radiography provided excellent information on possible differential diagnoses and allowed us to rule out the initial suspicion of the pres-

ence of a foreign body. The main differential diagnoses after intraoral radiography was performed included the presence of a denticle as part of a compound odontoma, a tooth with an abnormal cone-shaped crown (or so-called peg tooth), or a supernumerary permanent tooth.

A compound odontoma was compatible with the patient's age; however, this type of odontoma is associated with various rudimentary tooth-like structures² known as denticles, which were not detected in this case. A peg tooth is a tooth with an abnormal crown morphology, which is known to be associated with X-linked hypohidrotic ectodermal dysplasia in dogs.³ Because the patient had a complete set of adult dentition, we excluded a peg tooth from our differential diagnosis list. Given the clinical and histologic appearance of the tooth in question, the most probable diagnosis in this case was the presence of a supernumerary tooth.

Supernumerary teeth are teeth that form in excess of the normal dental formula, and they are reported to develop in 0.3% to 3.8% of the human population.⁴ The presence of supernumerary teeth has also been evaluated in certain dog breeds. In a study⁵ of Greyhounds, the most prevalent location for a supernumerary tooth was immediately distal to the maxillary and mandibular canine teeth, and the shape was typically that of a first premolar tooth. Results of a study⁶ of supernumerary teeth in horses suggested that these teeth may develop and erupt normally; have an inverted, transverse, or ectopic position; or follow an abnormal path of eruption.

The case described in the present report was unique in that it involved the presence of a supernumerary tooth that was not similar to the regional premolar and molar teeth, and because the macro-

scopic and histologic appearance suggested similarity with a first premolar or incisor tooth. Given the supernumerary tooth's intimate association with the right mandibular first molar tooth and presence of a periapical lucency, extraction of the tooth was deemed necessary and was performed without complications.

Intraoral radiography is an essential and necessary tool used to properly diagnose and treat dental-related diseases in veterinary patients. In this particular case, the usefulness of the modality was highlighted by the ability to formulate an appropriate therapeutic plan in a timely manner while removing the need for any guesswork or additional potentially invasive procedures.

References

1. Verstraete FJ, Kass PH, Terpak CH. Diagnostic value of full-mouth radiography in dogs. *Am J Vet Res* 1998;59:686-691.
2. Chamberlain TP, Lommer MJ. Clinical behavior of odontogenic tumors. In: Verstraete FJM, Lommer MJ, eds. *Oral and maxillofacial surgery in dogs and cats*. St Louis: Saunders-Elsevier, 2012;403-410.
3. Lewis JR, Reiter AM, Mauldin EA, et al. Dental abnormalities associated with X-linked hypohidrotic ectodermal dysplasia in dogs. *Orthod Craniofac Res* 2010;13:40-47.
4. Sylvester C. Dental anomalies. In: Scheid RC, Weiss G, eds. *Woelfel's dental anatomy*. 8th ed. Philadelphia: Lippincott Williams & Wilkins, 2012;323-344.
5. Dole RS, Spurgeon TL. Frequency of supernumerary teeth in a dolichocephalic canine breed, the Greyhound. *Am J Vet Res* 1998;59:16-17.
6. Dixon PM, Easley J, Ekmann A. Supernumerary teeth in the horse. *Clin Tech Equine Pract* 2005;4:155-161.



New Veterinary Biologic Products

Product name	Species and indications for use	Route of administration	Remarks
Moraxella Bovoculi Bacterin (Addison Biological Laboratory Inc, US Vet Lic No. 355)	This product is for use in healthy cattle 14 weeks of age or older against pinkeye (infectious bovine keratonconjunctivitis). This product license is conditional; efficacy and potency have not been fully demonstrated. For more information regarding safety data, see productdata.aphis.usda.gov	2 ml dose SC	USDA licensed 1/13/17
Porcine Epidemic Diarrhea Virus Antibody Test Kit (Zoetis Inc, Kalamazoo, MI, US Vet Lic No. 190)	For the detection of antibody to PEDV in porcine serum samples	For in vitro use only	USDA licensed 3/17/17