

ECG of the Month

A 4-year-old 25.5-kg (56.1-lb) spayed female mixed-breed dog was admitted to a veterinary medical teaching hospital for corrective closed-wedge osteotomy of the left femur and a left tibial tuberosity transposition. At the time of admission, the dog was alert, responsive, and ambulatory other than mild left hind limb lameness. Cardiac auscultation revealed a left-sided grade 3/6 systolic cardiac murmur.

A complete cardiac workup had been performed 1 week prior to admission, and at that time, auscultation revealed that the dog had a left-sided grade 3/6 systolic ejection murmur near the heart base with an audible midsystolic click. Echocardiography revealed that the right ventricle and right atrium were mildly dilated; prolapse of both mitral valve leaflets was noted, and the aortic root appeared mildly hypoplastic. The dog had a mildly high aortic outflow tract velocity (2.31 m/s; reference range, 1.24 to 1.9 m/s). Spontaneous echocardiographic contrast (so-called smoke) was evident in the right atrium. Electrocardiographic findings at that time included respiratory sinus arrhythmia, a wandering pacemaker, and occasional second-degree atrioventricular (AV) block and mild ST segment depression (0.25 mV; reference range, < 0.2 mV) in lead II. A diagnosis of mild congenital aortic valve hypoplasia causing turbulent flow was made.

On the day of surgery, the dog was premedicated with 5.1 mg of hydromorphone hydrochloride^a (0.2 mg/kg [0.09 mg/lb], IM) and 5.1 mg of midazolam^b (0.2 mg/kg, IM), and anesthesia was induced 20 minutes later via IV injection of 60 mg of propofol^c (4 mg/kg [1.8 mg/lb]; dose calculated and given to effect). Following intubation of the dog, anesthesia was maintained with 1.5% isoflurane^d in oxygen. A constant rate IV infusion of lidocaine hydrochloride^e (3 mg/kg/h [1.36 mg/lb/h]) and ketamine hydrochloride^f (0.6 mg/kg/h [0.27 mg/lb/h]) in lactated Ringer's solution was started at a rate of 255 mL/h. A dose of glycopyrrolate^g (0.005 mg/kg [0.002 mg/lb]) was administered IV 10 minutes later because the dog developed bradycardia (heart rate, 45 beats/min); after glycopyrrolate administration, the heart rate increased to 60 beats/min. The dog was connected to an ECG monitor and a nerve locator^h; the return (anode) electrode for the nerve locator was placed on the left lateral aspect of the dog's abdominal wall, approximately 5 cm caudal to the last rib. The nerve locator was used to identify the femoral and sciatic nerves, which were subsequently anesthetized

by perineural injection of bupivacaine hydrochloride.ⁱ While the nerve locator was being used to locate the nerves, an initial ECG tracing was obtained (Figure 1).

ECG Interpretation

On examination, the initial ECG tracing (Figure 1) was originally incorrectly considered to represent sinus rhythm with third-degree AV block. The ventricular rate was 60 beats/min, and the rate of what appeared to be the P waves was 120/min. These presumptive P waves had no association with the following QRS complexes, and the PR intervals were highly variable.

Settings on the ECG monitor were adjusted to increase the gain (and thereby increase the amplitude) of the ECG tracing, and a second ECG tracing was obtained approximately 10 minutes after the initial tracing had been recorded and while the nerve locator was still being used (Figure 1). In this tracing, the presence of additional ECG deflections was evident. The ventricular rate was 64 beats/min, and true P waves were now visible; each P wave was clearly related to the subsequent QRS complex with a PR interval of 0.15 seconds. Thus, the correct classification of the underlying cardiac rhythm was sinus rhythm with first-degree AV block. On further review of the initial and second tracings, it was evident that the ECG deflections that were incorrectly interpreted as P waves on the original tracing were electrical impulses occurring at a rate of 120 impulses/min. This artifact was eventually determined to be a result of the nerve locator, which was sending out a pulse rate of 2 Hz with a pulse width of 0.1 milliseconds at an intensity that ranged from 0.3 to 2 mA during location of the femoral nerve. Because of the low ECG amplitude of the initial ECG tracing, true P waves were barely visible, resulting in an incorrect interpretation of the artifact as the P wave.

After the nerve locator had been turned off, a third ECG tracing was recorded (Figure 1). This tracing revealed a sinus arrhythmia (heart rate, 68 beats/min) with first-degree AV block and consistent PR intervals of 0.15 seconds. Without the nerve locator in operation, no artifact was present. The change in the appearance of the J point and ST segment between the second and third tracings was likely a result of the functioning of the high-pass filter on the ECG monitor.

Discussion

Atrioventricular block is the partial or complete failure of a depolarization wave to conduct normally through the AV node. Third-degree AV block occurs when there is complete and consistent failure of depolarization waves to conduct through the AV node and a second pacemaker distal to the AV node discharges a signal for the ventricles to contract. This results in an ECG tracing in which P waves and QRS complexes occur independently of each other. If the second pacemaker discharges from either the lower portion of the

This report was submitted by Kara N. Carvalho, DVM; John E. Rush, DVM, MS; and Lois A. Wetmore, DVM, DSc; from the Department of Clinical Sciences, Cummings School of Veterinary Medicine, Tufts University, North Grafton, MA 01536. Dr. Carvalho's present address is Colchester Veterinary Hospital, 364 Old Hartford Rd, Colchester, CT 06415.

Dr. Rush consults for Boehringer Ingelheim, Idexx, VetPharm, Toxikon, and Nestlé Purina and has recently received research funding from Idexx, Boehringer Ingelheim, and Nestlé Purina. None of these relationships are thought to represent a conflict of interest in this manuscript.

Address correspondence to Dr. Rush (john.rush@tufts.edu).

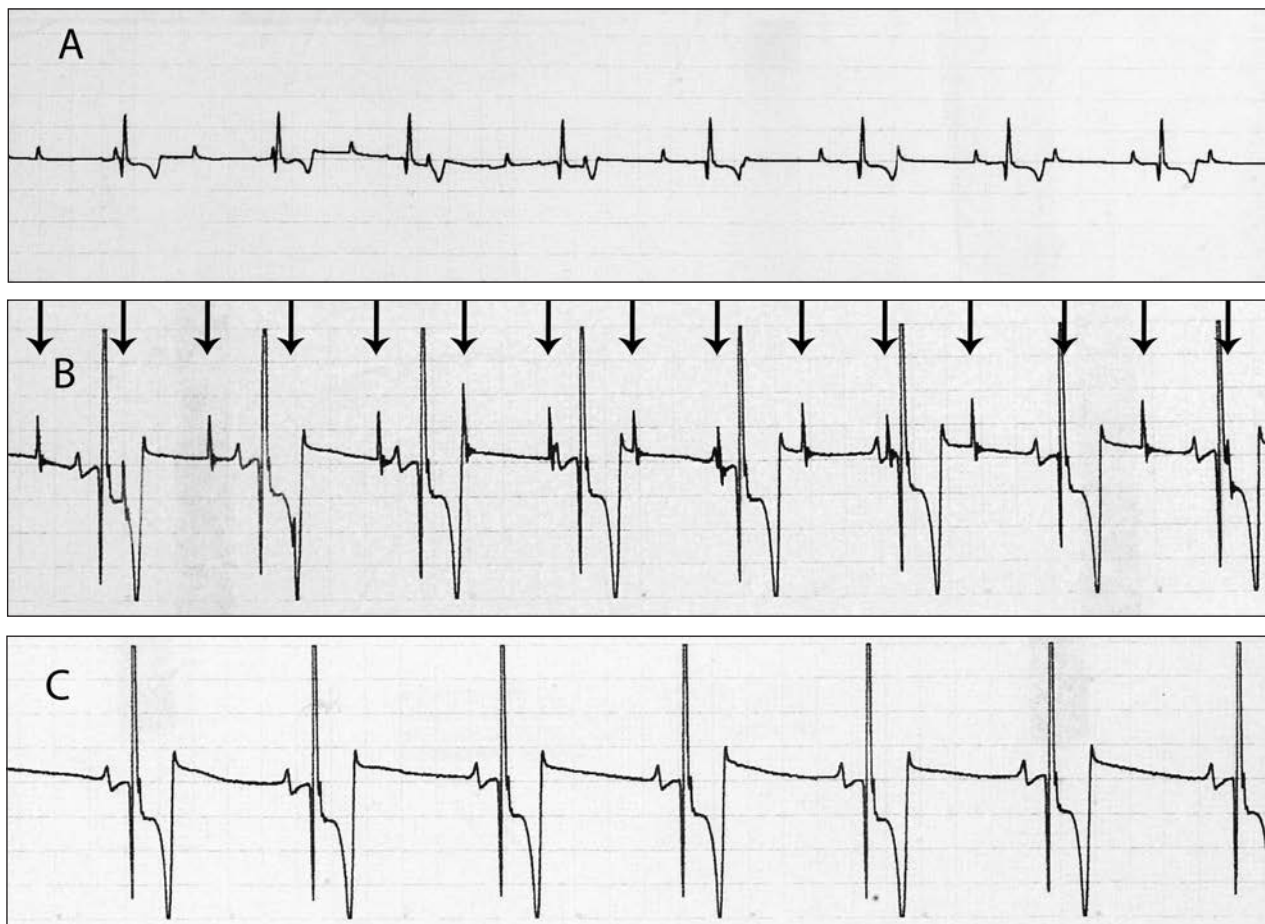


Figure 1—Electrocardiographic tracings obtained from an anesthetized dog while a peripheral nerve locator was being used for a planned nerve block. A—Initial tracing obtained during use of the nerve locator. The nerve locator has created an artifact that was mistaken as P waves at a rate of 120/min and gives the appearance of third-degree atrioventricular (AV) block. The true ECG diagnosis is sinus rhythm, but the low amplitude of the ECG deflections makes it difficult to see the true P waves. Paper speed = 25 mm/s; 0.3 cm = 1 mV. B—Second tracing obtained 10 minutes after the original ECG tracing, while use of the nerve locator use was continued. For this tracing, the voltage calibration had been increased to 2 cm/mV. Sinus rhythm is present and the P waves can now be clearly identified and differentiated from artifacts generated by the nerve locator (arrows). Paper speed = 25 mm/s; 2 cm = 1 mV. C—Third ECG tracing obtained after the nerve locator had been turned off. The ECG artifact is no longer present, and sinus rhythm with first-degree AV block is evident. Paper speed = 25 mm/s; 2 cm = 1 mV.

AV node or proximal portion of the bundle of His, QRS complexes with relatively normal configuration are produced at a rate of approximately 60 to 70 beats/min, often called a junctional escape rhythm. If the second pacemaker discharges from Purkinje cells in the ventricle, QRS-T complexes appear abnormal at a rate of approximately 30 to 40 beats/min, which is termed a ventricular escape rhythm.¹

On original inspection of the initial ECG tracing obtained from the dog of this report, P waves were not evident and the electrical impulses from the nerve stimulator were mistakenly thought to be P waves. The QRS-T complexes were considered to be the result of a junctional escape rhythm. Because the escape rhythm detected in this dog had QRS complexes of apparently normal shape and duration, the rhythm was expected to originate from a location between the AV node and the bundle of His.² The dog was hemodynamically stable under anesthesia, and there was no outward evidence on examination of a cardiac abnormality; thus, the importance of the suspected arrhythmia was unclear, even

though third-degree AV block would have represented a major change from the previously reported cardiac rhythm. A stepwise approach to the problem was undertaken, with review of the ECG obtained during the prior cardiology consultation in addition to assessment of the connection of the ECG leads to the dog and alteration in amplitude of the ECG waveforms on subsequent tracings. Following adjustment of the gain (amplitude) of the ECG recording, the sinus rhythm was readily observed; however, the cause of the additional electrical waveforms creating the ECG artifact—the artifact that was mistaken as P waves—was not clear. It was only after the nerve locator was turned off for a short period that the artifact disappeared from the ECG tracing, indicating that the cause for the artifact was the nerve stimulator.

In general, ECG monitors are designed to filter out signals from outside the range of typical human electromagnetic output. The low-intensity, low-energy current produced by nerve-locating devices was believed to not have effects on ECG monitoring.³ However, instances

of interference from use of a nerve stimulator during ECG examinations have been described in the human medical literature.^{3j} Use of a peripheral nerve stimulator during performance of an interscalene brachial plexus nerve block in a human produced a change in the interpreted ECG rhythm and an apparent increase in the heart rate from 56 to 146 beats/min.³ The rhythm mimicked multiple premature atrial depolarizations, but manual measurement of radial pulse and pulse oximetry confirmed a heart rate of 56 beats/min. After lowering the current output of the peripheral nerve stimulator, the ECG artifact disappeared.³ In another case, use of a nerve locator for peripheral nerve stimulation of the femoral nerve to perform a femoral nerve block in a 58-year-old man resulted in an apparent heart rate change from 57 to 119 beats/min, as detected in a lead II ECG reading.^j The patient's actual heart rate was 57 beats/min, as confirmed clinically and by pulse oximetry. The nerve stimulator was firing at a pulse rate of 2 Hz, which would generate a rate for the artifact of 120 beats/min,^j the same conditions as described in the case of this report. The theoretical causes for the interference cited in the human case report were direct contact between the 2 sets of leads and loop conduction effects.^j In the dog of the present report, there was no contact between the nerve locator and the ECG leads or the ECG monitoring equipment; therefore, the impulse was likely transmitted through the dog's body and recorded by the ECG machine. Peripheral nerve stimulators have also been known to interfere with the recognition or viewing of cardiac pacing impulses on the ECG monitor display in people with artificial cardiac pacemakers who are undergoing anesthesia.⁴

Accurate recognition of artifacts on an ECG recording is generally poor among physicians.⁵ The subject of ECG artifacts and their interpretation are rarely discussed at length in textbooks,⁶ and although artifacts in ECG examinations of dogs and cats have been described, those descriptions do not mention ECG artifacts from a nerve locator or from other devices that generate electrical activity, other than the well-recognized 60-cycle interference that creates a high-frequency baseline artifact whenever other electrical equipment is in close proximity to the patient or the ECG machine.⁷ A literature search for ECG artifacts reported for dogs and cats produced scant results, and we could find no veterinary medical publication that addressed ECG artifacts produced by a peripheral nerve stimulator or a nerve locator.

To avoid accidental attempts at correcting artifacts, we believe it is worth emphasizing that concurrent nerve stimulation by a nerve-locating device can in fact cause an artifact on an ECG tracing and that artifact can convincingly mimic a cardiac arrhythmia. If a cardiac arrhythmia is suspected in an anesthetized

patient undergoing a peripheral nerve block procedure, the arterial pulse rate and pulse oximeter reading should be checked for concordance with the apparent heart rate. In addition, the nerve stimulation should be discontinued and the ECG recording repeated and re-evaluated before proceeding with antiarrhythmic treatment. There is no safe and effective pharmaceutical treatment for complete AV block, especially in a dog that has failed to respond to an anticholinergic drug; in such situations, artificial cardiac pacing may be required or the episode of anesthesia may have to be terminated because of cardiac concerns. Thus, for the dog of this report, it was important to identify the artifact and eliminate the possibility of unnecessary therapeutic intervention. In this case, possible AV block during anesthesia was especially convincing given the dog's history of second-degree AV block when it was awake, making the role of thorough investigation of the ECG abnormality all the more important.

-
- a. Hydromorphone HCL injection (USP), West-Ward Pharmaceuticals, Eatontown, NJ.
 - b. Midazolam injection (USP), West-Ward Pharmaceuticals, Eatontown, NJ.
 - c. Propofol, Abbott Animal Health, North Chicago, Ill.
 - d. Isoflurane, Abbott Animal Health, North Chicago, Ill.
 - e. Lidocaine HCL injection (USP), Hospira Inc, Lake Forest, Ill.
 - f. Ketaset, Fort Dodge Animal Health, Fort Dodge, Iowa.
 - g. Glycopyrrrolate injection (USP), West-Ward Pharmaceuticals, Eatontown, NJ.
 - h. Nerve locator/stimulator, Tracer II, Life-Tech Inc, Stafford, Tex.
 - i. Marcaine, Hospira Inc, Lake Forest, Ill.
 - j. Crowley M, Asif P, D'Souza G. Electrocardiogram (ECG) monitor "pacing" interference from a peripheral nerve stimulator when performing a peripheral nerve block (abstr). *Regional Anesth Pain Med* 2008;33:87.
-

References

1. Tilley LP, Smith FWK. Electrocardiography. In: Tilley LP, Smith FWK, Oyama MA, et al, eds. *Manual of canine and feline cardiology*. 4th ed. Saunders Elsevier, 2008;49-77.
2. Schwartzman D. Atrioventricular block and atrioventricular dissociation. In: Zipes DP, Jalife J, eds. *Cardiac electrophysiology: from cell to bedside*. 4th ed. Philadelphia: WB Saunders Co, 2004;485-489.
3. Patel V, Hadzic A, Gadsden J, et al. An electrocardiograph artifact caused by peripheral nerve stimulation during an interscalene brachial plexus nerve block. *Reg Anesth Pain Med* 2010;35:118-119.
4. Rozner MA. Peripheral nerve stimulators can inhibit monitor display of pacemaker pulses. *J Clin Anesth* 2004;16:117-120.
5. Knight BP, Pelosi F, Michaud GF, et al. Physician interpretation of electrocardiographic artifact that mimics ventricular tachycardia. *Am J Med* 2001;110:335-338.
6. Patel SI, Souter MJ. Equipment-related echocardiographic artifacts: causes, characteristics, consequences, and correction. *Anesthesiology* 2008;108:138-148.
7. Tilley LP. Analysis of common canine cardiac arrhythmias. In: Tilley LP, ed. *Essentials of canine and feline electrocardiography*. 3rd ed. Malvern, Pa: Lea & Febiger, 1992;127-207.