

# Enthesopathy and desmitis of the medial collateral ligament of the cubital joint in 4 horses

Robin M. Dabareiner, DVM, PhD, DACVS; M. Keith Chaffin, DVM, MS, DACVIM;  
Heather Quirham; G. Kent Carter, DVM, MS, DACVIM

**Case Description**—4 horses with enthesopathy and desmitis of the medial collateral ligament of the cubital joint were examined.

**Clinical Findings**—All 4 horses had a history of acute, severe, unilateral forelimb lameness and had signs of pain during manipulation of the affected upper forelimb; 2 also had swelling in the axillary region. There was no improvement in lameness after diagnostic local analgesia below the carpal region, and 1 of 4 horses had mild improvement after cubital joint analgesia. Radiography revealed enthesophyte formation on the radial tuberosity and linear mineralization of the medial collateral ligament in 2 horses and periosteal reaction on the humeral condyle in all 4 horses. One horse had mild osteoarthritis of the cubital joint, and 3 had osteophytosis of the cranial aspect of the radius. Although all horses were initially examined because of an acute onset of lameness, all had chronic abnormalities visible on imaging. Ultrasonography revealed an irregular boney contour and enthesopathy at the insertion of the short medial collateral ligament to the radial tuberosity and desmitis of the short medial collateral ligament. Two horses had radiographic evidence of similar but less severe lesions of the contralateral cubital joint.

**Treatment and Outcome**—All horses received phenylbutazone and rest. All horses were free of lameness after a median of 3 months (range, 2 to 4 months) and returned to previous use after a median of 6 months (range, 3 to 8 months).

**Conclusions and Clinical Relevance**—The results of the present report suggested that performance horses with enthesopathy and desmitis of the medial collateral ligament of the cubital joint may have a good prognosis for return to previous use following appropriate treatment. (*J Am Vet Med Assoc* 2013;242:1152–1158)

An 18-year-old 557-kg (1,225-lb) Quarter Horse gelding used for team roping (horse 1) was brought to the Texas A&M University Veterinary Medical Teaching Hospital because of an acute left forelimb lameness. The horse had a 4-year history of intermittent left forelimb lameness but was reportedly sound immediately prior to the time of injury. The owner was roping on the horse 3 days prior to examination when the horse stumbled after the steer was roped and became immediately non-weight bearing lame on the left forelimb. Physical examination revealed heat and fluctuant swelling in the axillary region of the left forelimb. The horse had signs of pain during manipulation of the upper portion of the limb and had a grade 4 of 5 left forelimb lameness with an abnormal cranial phase of its gait. As the horse walked forward, it would swing the affected limb axially across its body and land with the limb crossed over the unaffected limb as if trying to bear weight on the lateral aspect of the left forelimb. The horse did not improve after perineural anesthesia of the distal portion of the limb up to and including the origin of the suspensory ligament. Additionally, no improvement was seen after administration of anesthetic into the caudal pouch of the cubital joint or

## ABBREVIATIONS

LMC	Long medial collateral
SMC	Short medial collateral

after analgesia of the shoulder joint. Because the horse did not improve after diagnostic local analgesia but had signs of pain in response to manipulation of the upper portion of the limb, the left cubital joint and shoulder joint were radiographed. Radiography of the left shoulder joint showed no abnormalities. The craniocaudal radiographic view (peak kilovoltage, 90 kV; amperage, 12 mA) of the left cubital joint revealed a periosteal reaction at the medial aspect of the humeral condyle and a chronic enthesophyte and periosteal reaction on the medial aspect of the radial tuberosity at the insertion of the medial collateral ligament (Figure 1). The lateromedial (peak kilovoltage, 80 kV; amperage, 12 mA) radiographic projection revealed a small osteophyte at the cranial aspect of the radius. No other abnormalities of the articular aspect of the cubital joint were noted. Radiographic evaluation of the right cubital joint revealed similar but less severe lesions (Figure 2).

Ultrasonography of the cubital joint of the lame left forelimb, proximal aspect of the radius, and distal portion of the humerus was performed with 10.0-MHz linear and 6.0- to 7.5-MHz microconvex transducers to evaluate periarticular structures and the periosteal sur-

From the Department of Large Animal Clinical Sciences, College of Veterinary Medicine and Biomedical Sciences, Texas A&M University, College Station, TX 77843.  
Address correspondence to Dr. Dabareiner (rdabareiner@cvm.tamu.edu).

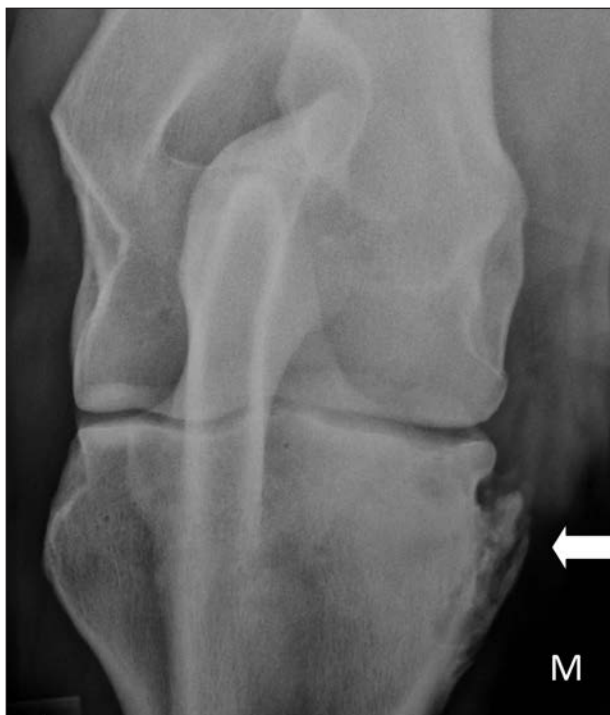

Figure 1—Craniocaudal radiographic view of the cubital joint of an 18-year-old 557-kg (1,225-lb) Quarter Horse gelding used for team roping (horse 1) with an acute onset of left forelimb lameness during exercise and a subsequent diagnosis of enthesopathy and desmitis of the SMC ligament. A severe enthesopathy at the attachment of the SMC ligament on the proximal medial (M) aspect of the radius (arrow) is evident on this image.

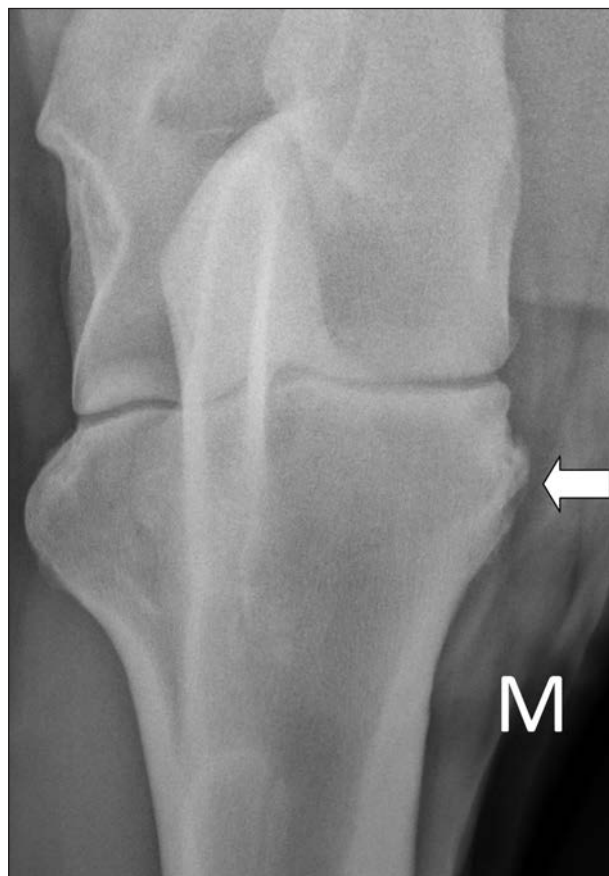

Figure 2—Craniocaudal radiographic view of the cubital joint of the (nonlame) contralateral right forelimb of the horse in Figure 1 (horse 1) showing a similar but less severe enthesopathy at the attachment of the SMC ligament on the proximal medial (M) aspect of the radius (arrow).

face of the bone of the affected limb. The left forelimb was positioned in front of the right forelimb to facilitate access to the medial aspect of the cubital joint and was scanned during weight bearing. The longitudinal ultrasonographic evaluation of the medial aspect of the elbow joint revealed a normal fiber pattern in the LMC ligament, which measured 0.26 cm in thickness. The SMC ligament was thickened, measuring 0.93 cm at the level of the cubital joint, with mild to moderate fiber irregularity along its length. There was evidence of moderate irregular bony margins at the origin of the SMC ligament attaching to the proximal aspect of the medial humeral condyle and moderate roughening and severe enthesopathy of the proximal aspect of the medial radial tuberosity at the insertion of the SMC ligament (Figure 3). Ultrasonography of the lateral collateral ligament revealed mild diffuse fiber irregularity, and the ligament had a thickness of 1.71 cm at the level of the joint. Ultrasonography of the cubital joint of the contralateral forelimb revealed similar but less severe enthesopathy of the proximal aspect of the radial tuberosity. The LMC ligament had a normal fiber pattern, measuring 0.22 cm thick; however, the SMC ligament was thickened, measuring 0.68 cm at the level of the joint surface and having a normal fiber pattern. Cross-sectional images of the medial collateral ligaments were difficult to obtain and interpret owing to the close proximity of the ligament to the pectoral musculature. This musculature interfered with positioning of the ultrasonographic transducer; thus, the images of the cranial and caudal margins of the SMC ligament were not well demarcated,

and repeatable cross-sectional measurements were not obtainable.

This horse had ultrasonographic findings suggestive of bilateral enthesopathy and desmitis of the SMC ligament; however, to our knowledge, the normal dimensions of the cubital joint collateral ligaments in Quarter Horses or other breeds have not been previously described. Therefore, we performed an ultrasonographic evaluation on both medial and lateral collateral ligaments of the cubital joints in both front limbs on 3 Quarter Horses (6 medial and lateral collateral ligaments) from our teaching herd that were free of lameness with normal cubital joint radiographs for comparison, to confirm our suspected diagnosis of SMC ligament desmitis. Positioning of the limbs for the ultrasonographic examination was performed as described for horse 1. The lateral collateral ligament of the right and left cubital joints was visible over the lateral aspect of the cubital joints when the transducer was oriented longitudinally or transversely. Linear fibers were visible in the single body of the ligament. Median thickness (axial-to-abaxial dimension) of the 6 lateral collateral ligaments in the nonlame horses was 1.4 cm at its proximal extent and origin on the humerus (range, 1.38 to 1.41 cm). The ligament gradually tapered to a median thickness of 0.82 (range, 0.80 to 0.85 cm) at its distal aspect at its insertion on the radius. It measured 1.1 cm in thickness at the

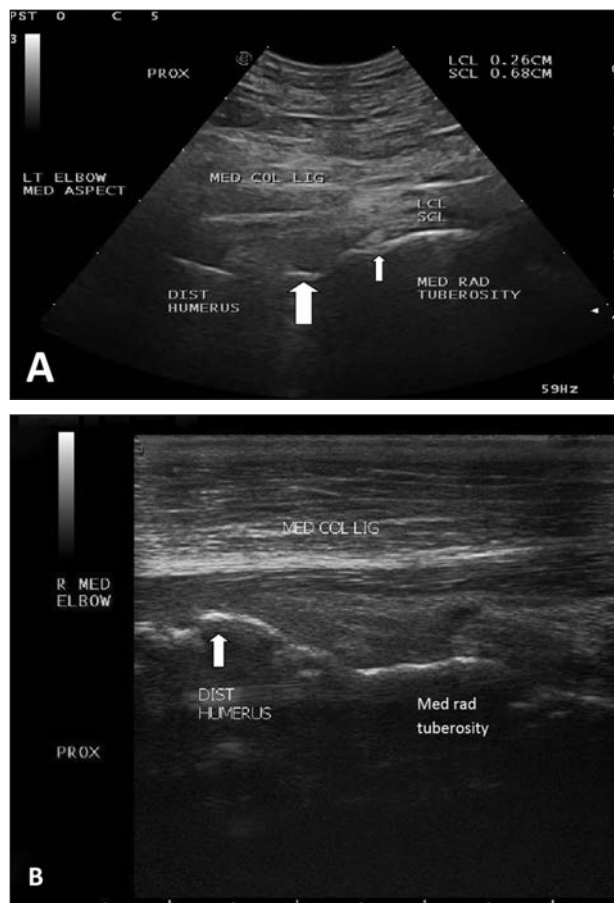


Figure 3—Ultrasonographic images of the medial collateral ligaments of the left cubital joint of horse 1. A—Note the thickened short MCL and fiber pattern irregularity at the joint space (arrow). Also note irregular bone margins of the radial tuberosity distal to the joint space (small arrow). B—Same ultrasonographic image as in panel A, but note irregular bone margins of the humerus (arrow) and radial tuberosity. Both images were obtained with the transducer oriented longitudinally over the medial aspect of the cubital joint, with proximal on the left side of the image and distal on the right side of the image. COL = Collateral. DIST = Distal. LCL = Long medial collateral ligament. LIG = Ligament. LT = Left. MED = Medial. PROX = Proximal. R = Right. RAD = Radial. SCL = Short medial collateral ligament.

level of the joint. The median cross-sectional area of the lateral collateral ligament was  $0.86 \text{ mm}^2$  (range,  $0.85$  to  $0.89 \text{ mm}^2$ ) when the transducer was oriented transversely. The medial collateral ligaments of the right and left cubital joints were also visible when the transducer was placed longitudinally on the medial aspect of the cubital joint. This ligament consists of 2 parts: a long or superficial body and a deeper, short body.<sup>1</sup> The 2 parts were distinctly visible ultrasonographically. The LMC ligament had a consistent thickness throughout its entire length, with a median thickness of  $0.23 \text{ cm}$  (range,  $0.17$  to  $0.26 \text{ cm}$ ). The deeper SMC ligament had a median thickness of  $0.40 \text{ cm}$  at the level of the cubital joint (range,  $0.37$  to  $0.50 \text{ cm}$ ; Figure 4). Cross-sectional images of the medial collateral ligaments were difficult to obtain for similar reasons as described for horse 1. With this information available, a diagnosis of bilateral SMC ligament desmitis and left lateral collateral ligament desmitis was made for horse 1.

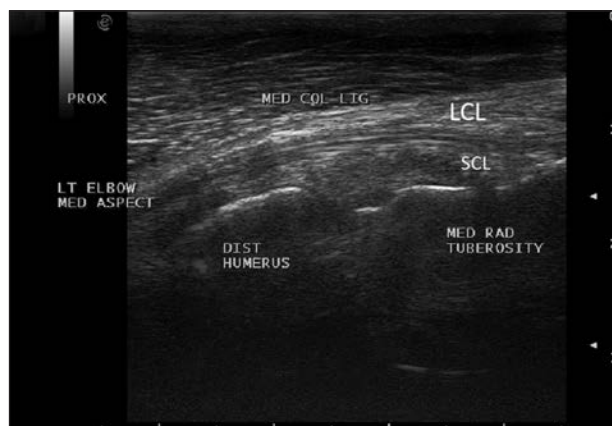


Figure 4—Ultrasonographic image of medial collateral ligaments of the left cubital joint of a clinically normal 14-year-old 537-kg (1,181-lb) Quarter Horse gelding used as a blood donor. This image was obtained with the transducer oriented longitudinally over the medial aspect of the cubital joint, with proximal on the left side of the image and distal on the right side of the image. See Figure 3 for remainder of key.

Horse 1 received phenylbutazone ( $2.2 \text{ mg/kg}$  [ $1.0 \text{ mg/lb}$ ], PO, q 12 h) for 7 days and was confined to a small turnout area for 4 months. The horse was sound on the follow-up examination 4 months after the initial injury. Repeated radiography revealed no changes from the initial evaluation. Follow-up ultrasonography was declined by the owner for financial reasons. The owner increased the horse's exercise regimen slowly over a 2-month period, and the horse returned to roping activity 6 months after the initial injury and was still performing as a team roping horse without signs of lameness at last follow-up 2 years after initial diagnosis.

An 11-year-old 580-kg (1,276-lb) Andalusian gelding used for dressage (horse 2) was brought to the Texas A&M University Veterinary Medical Teaching Hospital because of acute right forelimb lameness. The owner was performing in a dressage competition with the horse 7 days prior to examination when the horse became non-weight bearing lame on the right forelimb. The owner gave the horse  $2 \text{ g}$  of phenylbutazone PO once daily for 3 days after the injury and confined the horse to a stall. The horse had a grade 4 of 5 right forelimb lameness on initial examination. Apart from the lameness, results of physical examination were unremarkable, except that the horse resisted manipulation of the upper portion of the limb. Results of hoof-tester examination were negative. The horse did not improve after diagnostic local analgesia of the limb, which was performed as described for horse 1. Scintigraphy of both forelimbs was performed with technetium Tc 99m oxidronate; bone-phase images<sup>a</sup> were obtained 3 hours after IV injection of the radioisotope, which revealed a high increase in pharmaceutical uptake in the medial aspect of the proximal end of the affected radius (Figure 5).

The cubital joint of the lame right forelimb was radiographed as described for horse 1. The craniocaudal radiographic projection revealed a large enthesophyte and periosteal reaction at the proximal medial aspect of the radial tuberosity and mineralization in the distal aspect of the medial collateral ligament. The proximal medial aspect of the radius had bony sclerosis and a

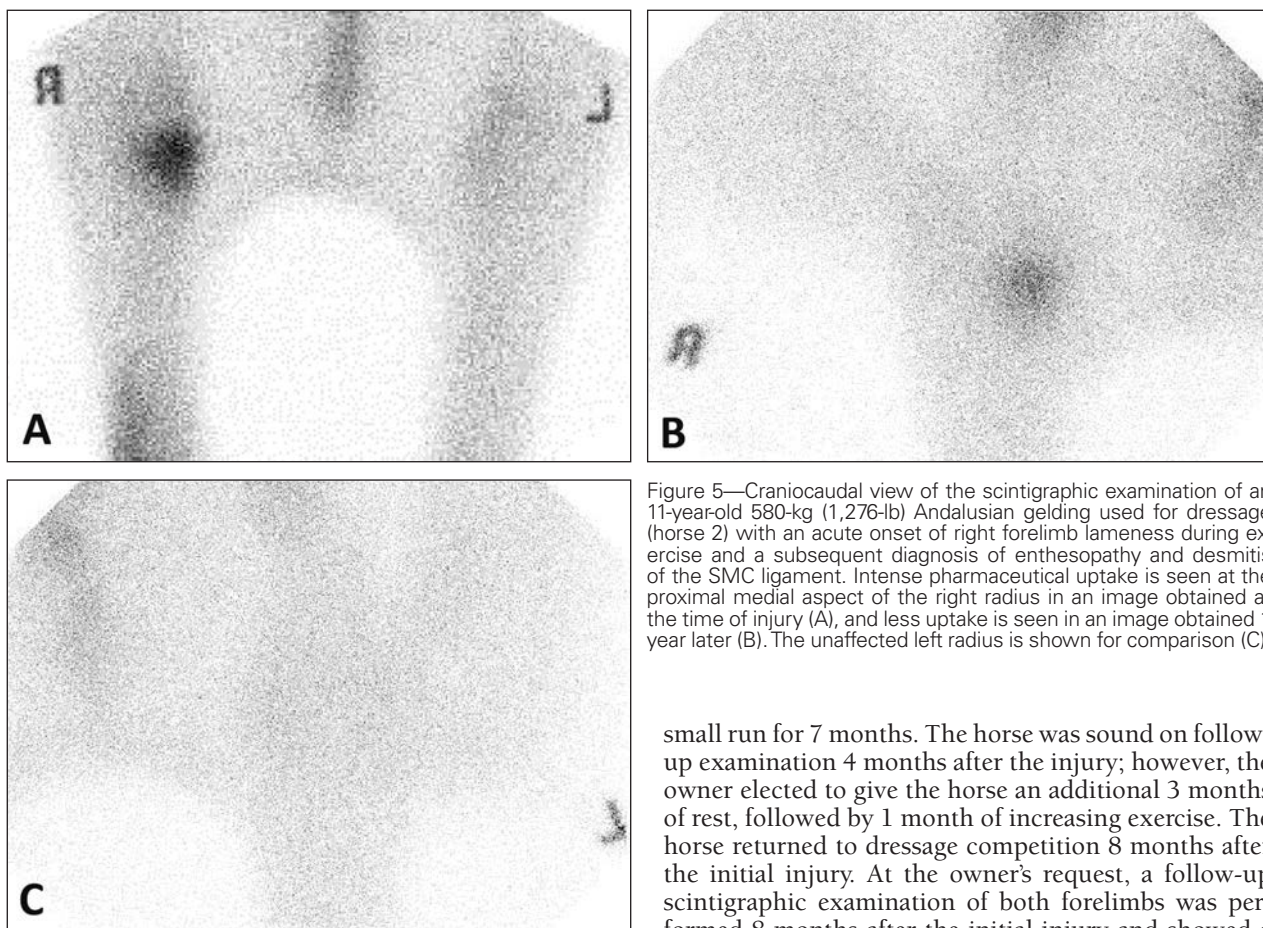


Figure 5—Craniocaudal view of the scintigraphic examination of an 11-year-old 580-kg (1,276-lb) Andalusian gelding used for dressage (horse 2) with an acute onset of right forelimb lameness during exercise and a subsequent diagnosis of enthesopathy and desmitis of the SMC ligament. Intense pharmaceutical uptake is seen at the proximal medial aspect of the right radius in an image obtained at the time of injury (A), and less uptake is seen in an image obtained 1 year later (B). The unaffected left radius is shown for comparison (C).

small osteophyte located at the cranial articular surface of the radius. Ultrasonographic examination of both cubital joints was performed as described for horse 1. The longitudinal ultrasonographic evaluation of the medial aspect of the right cubital joint revealed a normal fiber pattern in the LMC ligament; however, the SMC ligament was thickened, with mild to moderate fiber irregularity. The LMC ligament of the right and left forelimbs had a thickness measurement of 0.25 cm with a normal fiber pattern. The thickness of the right SMC ligament at the level of the cubital joint surface was 1.22 cm, and there was diffuse mineralization throughout it. There was also an irregular boney margin at the attachment of the ligament to the proximal medial aspect of the radial tuberosity. The cubital joint of the nonlame left limb was radiographed for comparison and had similar but less severe lesions. Ultrasonography of the left cubital joint showed that the thickness of the SMC ligament was 0.98 cm at the level of the cubital joint with similar but less severe irregularity of the radial tuberosity. A diagnosis of bilateral enthesopathy and SMC ligament desmitis was made. The medial collateral ligament of the right forelimb was treated with extracorporeal shock wave therapy<sup>b</sup> via a 5-mm probe (energy level 7; frequency, P240 with 1,000 pulses/treatment session). This treatment was repeated at 2-week intervals, for 3 treatments.

This horse received phenylbutazone (2.2 mg/kg, PO, q 12 h) for 7 days and was confined to a stall and

small run for 7 months. The horse was sound on follow-up examination 4 months after the injury; however, the owner elected to give the horse an additional 3 months of rest, followed by 1 month of increasing exercise. The horse returned to dressage competition 8 months after the initial injury. At the owner's request, a follow-up scintigraphic examination of both forelimbs was performed 8 months after the initial injury and showed a mild but notable decrease in pharmaceutical uptake at the right radius, compared with the previous scan (Figure 5). A follow-up ultrasonographic examination was offered but was declined by the owner.

A 17-year-old 557-kg (1,225-lb) Quarter Horse gelding used for team roping (horse 3) was brought to Texas A&M University Veterinary Medical Teaching Hospital because of an acute left front limb lameness. Bilateral navicular area pain had been diagnosed 2 years previously, but the horse was not lame prior to this injury according to the owner. The owner was roping on the horse 2 days prior to examination when the horse became non-weight bearing lame on the left forelimb just after the steer was roped. At initial examination, the horse had a grade 4 of 5 left forelimb lameness and stood with the left forelimb adducted to the opposite side of its body. Physical examination revealed a large fluctuant swelling in the axillary region of the left forelimb, and the horse resisted manipulation of the upper portion of the limb. Results of hoof-tester examination were negative. The horse did not improve after perineural and intra-articular anesthesia as described for horse 1. The left cubital joint and shoulder joint were radiographed as described for horse 1. The craniocaudal radiographic projection of the left cubital joint revealed a linear mineralization of the soft tissues medial to the cubital joint. The proximal medial aspect of the radius had an irregular margination, and there was osteophytosis of the cranial proximal aspect of the articular margin of the radius. Findings on radiographic evalu-

ation of the left forefoot were unchanged from 4 years previously and showed mild degenerative changes of the distal sesamoid bone. Ultrasonographic examination of the left cubital joint was performed as described for horse 1. The fluctuant swelling was consistent with a seroma, which did not communicate with the joint capsule. The longitudinal ultrasonographic evaluation of the medial aspect of the elbow joint revealed a normal fiber pattern in the LMC ligament; however, the SMC ligament was thickened and had mild fiber pattern irregularity. The LMC ligament of the left forelimb had a median thickness of 0.26 cm with a normal fiber pattern at the level of the joint. The thickness of the left SMC ligament at the level of the cubital joint surface was 0.82 cm, and there was diffuse mineralization throughout it. There was also an irregular bony margin at the attachment of the ligament to the proximal medial aspect of the radial tuberosity. The contralateral cubital joint was not examined. A diagnosis of left SMC ligament desmitis was made.

This horse received phenylbutazone (2.2 mg/kg, PO, q 12 h) for 7 days and was confined to a small turnout area for 2 months, followed by 1 month of light riding. The horse was sound on follow-up examination 3 months after the injury and returned to roping activity at that time.

A 6-year-old 495-kg (1,088-lb) Quarter Horse mare used for barrel racing (horse 4) was examined at Texas A&M University Veterinary Medical Teaching Hospital for an acute left forelimb lameness. Historically, the owner had competed in a barrel race 5 days previously when the horse became non-weight bearing lame after turning the third barrel. Physical examination findings were unremarkable except for signs of pain during manipulation of the upper portion of the left forelimb. The horse had a grade 4 of 5 left forelimb lameness and adducted the limb during the cranial phase of the stride at the walk. The horse did not improve after distal limb perineural anesthesia as described for horse 1 but improved to grade 3 of 5 lameness after intra-articular anesthesia of the caudal pouch of the cubital joint. Radiographic evaluation of the left cubital joint revealed a subchondral radiolucency and periosteal reaction of the medial aspect of the radial tuberosity. There was also some irregularity of the articular margin at the medial aspect of the joint. Ultrasonography showed thickness of the LMC ligament, which measured 0.24 cm at the level of the joint and had a normal fiber pattern. The SMC ligament had a moderately disrupted fiber pattern, with a thickness of 0.85 cm. The proximal medial aspect of the radial tuberosity had an irregular bony margin. The cubital joint of the contralateral nonlame limb was not examined. A diagnosis of left forelimb SMC ligament desmitis and mild cubital joint osteoarthritis was made.

The hair over the left cubital joint was clipped; the skin was aseptically prepared, and the joint was injected with 6 mg of triamcinolone, 125 mg of amikacin, and 20 mg of hyaluronate. This horse received phenylbutazone (2.2 mg/kg, PO, q 12 h) for 7 days and was confined to a small turnout area for 2 months. The horse was sound on follow-up examination 2 months after the injury. Follow-up radiographic examination showed sclerosis of the proximal medial aspect of the radius and enthesophyte formation at the proximal

medial aspect of the radial tuberosity at the attachment of the distal SMC ligament. These radiographic observations had progressed in severity, compared with the findings on previous radiographs. The owner was instructed to confine the horse to a small area for an additional 3 months, followed by 1 month of increasing exercise. The horse returned to barrel racing 6 months after the original injury.

## Discussion

The cubital joint is a typical ginglymus joint in which its only movement is in flexion and extension. It is supported medially and laterally by collateral ligaments. The joint capsule is very thin caudally, but cranially, it is strengthened by oblique fibers from the medial and lateral collateral ligaments. The medial collateral ligament originates on an eminence on the medial epicondyle of the humerus and is divided into 2 parts: the long, superficial part that inserts on the medial aspect of the radius just distal to the interosseous space and the deeper, short part of the medial collateral ligament that inserts on the radial tuberosity. The lateral collateral ligament is strong and short, originates proximally at the lateral epicondyle of the humerus, and inserts distally on the radial tuberosity.<sup>1</sup> The close approximation of the medial aspect of the cubital joint with the body protects it from direct trauma; perhaps this explains why reported cases of medial collateral ligament injuries of the cubital joint are rarely reported in the literature. Alternately, the combination of a lack of response to diagnostic local analgesia and difficulty in imaging this area via ultrasonography could result in cubital joint medial collateral ligament desmitis being underdiagnosed.

In the literature, injury to the collateral ligaments of the cubital joint has been primarily associated with subluxation or luxation of the joint and is usually secondary to a traumatic event such as severe abduction of the limb or a fall.<sup>2</sup> On the basis of limited published data, prognosis for returning to riding or performance after luxation is guarded.<sup>2</sup> There is minimal soft tissue coverage on the lateral aspect of the cubital joint, making it vulnerable to injury from direct trauma or penetrating wounds.<sup>3</sup>

Damage to the lateral collateral ligament has been previously reported,<sup>2</sup> and horses with concomitant enthesopathy or new bone formation had persistent lameness. There is a description of a 15-year-old pony having a chronic forelimb lameness secondary to a fall.<sup>4</sup> This pony had entheseous new bone proliferation at the origin and insertion of both medial and lateral collateral ligaments of the cubital joint. Postmortem evaluation confirmed desmitis of the lateral collateral ligament and cubital joint osteoarthritis. One case report<sup>5</sup> describes traumatic avulsion of the lateral collateral ligament of the cubital joint in a 12-year-old Thoroughbred gelding. This horse was euthanized as a result of poor prognosis for returning to athletic use; however, the authors of that report<sup>5</sup> do state that minor lesions respond well to rest and controlled exercise. To our knowledge, there are no published reports describing exercise-related medial collateral ligament injury of the cubital joint in horses. In addition, ultrasonographic measurements

of the clinically normal or abnormal medial collateral ligaments of the cubital joint have not been reported to date.

Although all of the horses of this report had an acute onset of non-weight bearing lameness, which occurred when performing their respective activities, all had radiographic evidence of chronic disease. Two of the horses were older Quarter Horse geldings used solely for team roping, and 1 was used for barrel racing. No evidence of collateral ligament injuries of the cubital joint were reported in 2 previous studies<sup>6,7</sup> of the cause of lameness and poor performance in 236 horses used for team roping or barrel racing activity. We found 4 horses with medial collateral ligament damage during a 4-year period of time, which supports that this is a rare diagnosis in adult horses. It is possible that this injury is underdiagnosed for reasons previously described, or perhaps these horses are rested and return to previous work without a lameness evaluation and, thus the injury is not detected.

All the patients described in this report were initially examined with a severe forelimb lameness of grade 4 of 5. Catastrophic causes of lameness such as fracture should be ruled out prior to performing diagnostic local analgesia during initial evaluation for an acute, severe lameness.<sup>8</sup> All horses resisted manipulation of the upper portion of the limb, and 2 horses had a fluctuant swelling in the axial area. Three of the 4 horses had an abnormal gait described as placing the affected limb across the front of the horses' body and crossing over the unaffected limb. We suspect the horses were trying to bear weight on the lateral aspect of the affected limb and thereby decrease weight bearing on the damaged medial aspect of the axillary region. Diagnostic local analgesia failed to localize the lameness in 3 of 4 horses, and only mild improvement was seen in 1 horse (horse 4) after cubital joint anesthesia. Considering that the collateral ligaments are extracapsular, it is not surprising that cubital joint analgesia did not result in complete soundness in these horses; however, we would expect some improvement from anesthetic diffusion from the synovial pouch to the adjacent ligament fibers. Horse 4 had radiographic evidence of an irregularity at the articular joint margin at the medial aspect of the joint; therefore, it may have had mild intra-articular damage that was not seen radiographically. This could explain the mild improvement after intra-articular anesthesia, or perhaps anesthetic diffusion did occur in this horse.

All horses were radiographed within 7 days after onset of the acute lameness. Radiography in all horses demonstrated chronic enthesophytes and periosteal reaction at both the origin and insertion of the medial collateral ligament, indicating previous injury to this area. The ultrasound examination revealed that the SMC ligament had mild to moderate fiber pattern disruption, compared with the opposite limb, and was thickened (median thickness, 0.90 cm; range, 0.82 to 1.22 cm), compared with the thickness in unaffected horses (median, 0.40 cm; range, 0.37 to 0.49 cm). The increase in ligament thickening could have been secondary to acute swelling, or perhaps, the ligament was enlarged from scar tissue from a previous insult. These clinical findings suggest that the horses of the present

report sustained an acute exacerbation of a chronic cubital joint problem. The previous medial collateral ligament damage was severe enough to result in the notable radiographic findings.

Only 2 of the horses had a history of previous lameness, and 1 horse had the previous lameness localized to the feet. There are a few possible explanations for this chronic problem initially manifesting as an acute lameness. It is possible that the 2 horses with previous lameness had cubital joint pain that was not detected. Alternately, perhaps the owners were unaware of their horses' lameness or the lameness was subtle and overlooked until the acute, severe injury occurred. It is also possible that horse sustained a previous cubital joint injury under the care of a previous owner. One could also argue that this was a chronic previous injury that was not causing the acute lameness; however, all horses developed signs of pain in response to manipulation of the upper portion of the limb, 2 horses had fluctuant swelling in the axillary region, and 1 horse had intense pharmaceutical uptake on the bone scan, which supports an acute exacerbation of a chronic problem.

In 2 horses, we radiographed the unaffected cubital joint to compare it with the affected or lame limb. We were surprised to see similar but less severe enthesophytes and a periosteal reaction at the radial tuberosity and humeral condyle. On physical examination, we did not observe bilateral forelimb lameness in either horse, although a secondary lameness in the contralateral limb may have been present but was not seen since the primary limb lameness could not be localized with diagnostic local analgesia. Both horses had abnormal findings on ultrasonographic examination of both SMC ligaments. We suspect the severity of lameness in the affected limb masked the opposite forelimb lameness or the opposite limb had also previously sustained injury, but it was a subclinical lesion on initial examination. For the other 2 horses, radiographic and ultrasonographic images of the cubital joint of the contralateral limb were not obtained. It is possible that medial collateral ligament desmitis of the cubital joint is a bilateral forelimb problem similar to navicular disease. We recommend imaging both cubital joints in horses with suspected cubital joint medial collateral ligament desmitis.

Ultrasonographic evaluation of the cubital joint was more useful than plain radiography alone in identifying both ligamentous and periarticular abnormalities in the horses of the present report. The importance of ultrasonographic examination when evaluating the elbow, brachium, and shoulder regions of horses has previously been stressed.<sup>4</sup> Imaging the medial aspect of the cubital joint was difficult given the anatomic location of the medial collateral ligaments and was best facilitated when the affected limb was situated approximately 1 foot ahead of the opposite forelimb. It is important to have the limb weight bearing during the examination to avoid relaxation artifacts, which could mimic a disrupted fiber pattern in the collateral ligaments. Ideally, both transverse and longitudinal images of the medial collateral ligaments would be obtained; however, the transverse images that were obtained were not considered of diagnostic quality. In the transverse image, the

medial collateral ligament was indistinguishable from the overlying muscle and connective tissue. Therefore, thickness measurements of the SMC ligament were obtained from longitudinal images. We recognize the potential for error when measuring SMC ligament thickness, given that proliferative cubital joint synovium underlying the ligament could have inadvertently been included in the measurement; however, there was a substantial size and fiber pattern difference between the 4 horses of this report and the 6 ligaments from the 3 clinically normal horses that we imaged. The most dramatic findings were the roughened boney changes and enthesopathies located at the origin and insertion of the medial collateral ligament on the humeral epicondyle and radial tuberosity, respectively. Real-time ultrasonography allowed us to trace the ligaments and evaluate the fiber pattern and then to follow the contours of the radius and humerus looking for boney irregularities and enthesopathy. One still image of the medial aspect of the cubital joint rarely showed all of the pathological results seen with real-time imaging.

The contralateral cubital joint was evaluated in 2 affected horses to compare it with the affected side, and we found similar but less severe boney and ligamentous lesions. To attempt to have a normal comparison for medial collateral ligament size and thickness, we evaluated the 6 cubital joint medial and collateral ligaments in 3 sound horses of the same breed and similar size, with no radiographic lesions of the cubital joint. We acknowledge that 6 is a small number of medial collateral ligaments and therefore does not represent a true reference range for clinically normal horses, but all 6 images and measurements were very consistent and dramatically different from those for the 4 horses of this report. To our knowledge, there are no descriptions of the ultrasonographic appearance of the equine cubital joint medial collateral ligaments in the literature. In all horses, the short or deep portion of the medial collateral ligament was affected and thickened with moderate fiber pattern disruption and the superficial or long portion of the medial collateral ligament appeared undamaged.

One horse underwent scintigraphic evaluation at the time of injury. Eight months after the initial evaluation, the horse underwent a second scintigraphic evaluation even though the horse was free of lameness and back in dressage work. There remained a mild pharmaceutical uptake in the medial proximal aspect of the radius, although it was notably decreased from the original study. The findings in this patient suggest that scintigraphic evaluation may not be a good predictor

of when the horse should return to previous activity. Although only 1 of 4 horses underwent scintigraphic evaluation, the importance of this imaging modality should not be overlooked. Nuclear scintigraphy of the proximal aspect of the forelimbs is indicated when diagnostic local analgesia fails to localize the source of lameness and is especially useful when extra-articular structures are involved, such as the collateral ligaments of the cubital joint.<sup>4</sup>

All horses returned to their previous level of activity after a moderate period of rest. Horses were sound a median of 3 months (range, 2 to 4 months) after the initial injury and returned to previous use a median of 6 months (range, 3 to 8 months) from the time of injury. To our knowledge, none of the horses required additional intra-articular medications or chondroprotectants to perform their activities. In contrast to the poor prognosis reported for traumatic cubital joint avulsion injuries,<sup>2,4</sup> and on the basis of the outcome in this small number of horses, horses with exercise-related medial collateral ligament enthesopathy and desmitis of the cubital joint may have a good prognosis for return to athletic use with appropriate treatment and a moderate period of rest.

- 
- a. Ultra-Scan System, Enhanced Technologies Corp, Bedford, Tex.  
b. Versatron, Health Tronics Inc, Marietta, Ga.
- 

## References

1. Sisson S. Equine syndesmology. In: Getty R, ed. *Sisson and Grossman's the anatomy of the domestic animals*. 5th ed. Philadelphia: WB Saunders Co, 1975;349–375.
2. Hubert J, Stashak TS. The antebrachium, elbow and humerus. In: Baxter GM, ed. *Lameness in horses*. 6th ed. Ames, Iowa: Wiley-Blackwell, 2011;687–708.
3. Swinebroad EL, Dabareiner RM, Swor TM, et al. Osteomyelitis secondary to trauma involving the proximal end of the radius in horses: five cases (1987–2001) *J Am Vet Med Assoc* 2003;223:486–491.
4. Dyson SJ. The elbow, brachium, and shoulder. In: Dyson SJ, Ross MW, eds. *Diagnosis and management of lameness in the horse*. 2nd ed. St Louis: Elsevier Saunders, 2011;456–474.
5. Chopin JB, Wright JD, Melville L, et al. Lateral collateral ligament avulsion of the humeroradial joint in a horse. *Vet Radiol Ultrasound* 1997;38:50–54.
6. Dabareiner RM, Cohen ND, Carter GK, et al. Musculoskeletal problems associated with lameness and poor performance among horses used for barrel racing: 118 cases (2000–2003). *J Am Vet Med Assoc* 2005;227:1646–1650.
7. Dabareiner RM, Cohen ND, Carter GK, et al. Lameness and poor performance in horses used for team roping: 118 cases (2000–2003). *J Am Vet Med Assoc* 2005;226:1694–1699.
8. Bassage LH, Ross MW. Diagnostic analgesia. In: Dyson SJ, Ross MW, eds. *Diagnosis and management of lameness in the horse*. 2nd ed. St Louis: Elsevier Saunders, 2011;100–135.