

# Diagnostic Imaging in Veterinary Dental Practice

In cooperation with  
**AVDC**  
AMERICAN VETERINARY DENTAL COLLEGE

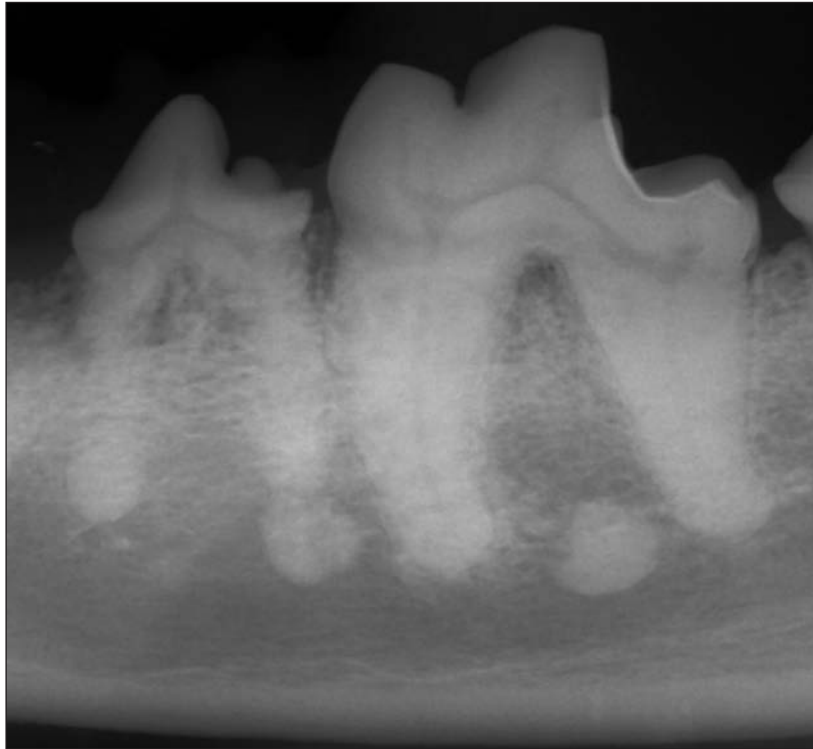


Figure 1—Lateral intraoral radiographic view of the left mandibular fourth premolar and first molar teeth of a 14-year-old 23-kg (51-lb) spayed female Labrador Retriever evaluated prior to extraction of a luxated right mandibular canine tooth and treatment of mild periodontal disease.

## **History and Physical Examination Findings**

A 14-year-old 23-kg (51-lb) spayed female Labrador Retriever was referred for extraction of the right mandibular canine tooth, which had been luxated as a result of a low-velocity vehicular impact, and for treatment of mild periodontal disease. The dog was anesthetized, and a complete oral examination was performed. The oral examination revealed complicated crown fractures of the right and left maxillary second incisor teeth and missing right maxillary first and second incisor teeth. The right mandibular canine tooth was mobile and laterally luxated. There was mild to moderate generalized plaque and calculus, mild gingivitis, and abrasion of the mandibular first molar teeth.

Full-mouth digital intraoral radiography was performed to screen for abnormalities or injuries not evident during the oral examination. An intraoral radiographic view of the caudal portion of the left mandible is provided (Figure 1).

**Determine whether additional imaging studies are required, or make your diagnosis, then turn the page →**

---

This report was submitted by Diane S. Carle, DVM, and Bonnie H. Shope, DVM, DAVDC; from Veterinary Dental Services LLC, 138 Great Rd, Acton, MA 01720.  
Address correspondence to Dr. Carle (dcarle@veterinarydental.com).

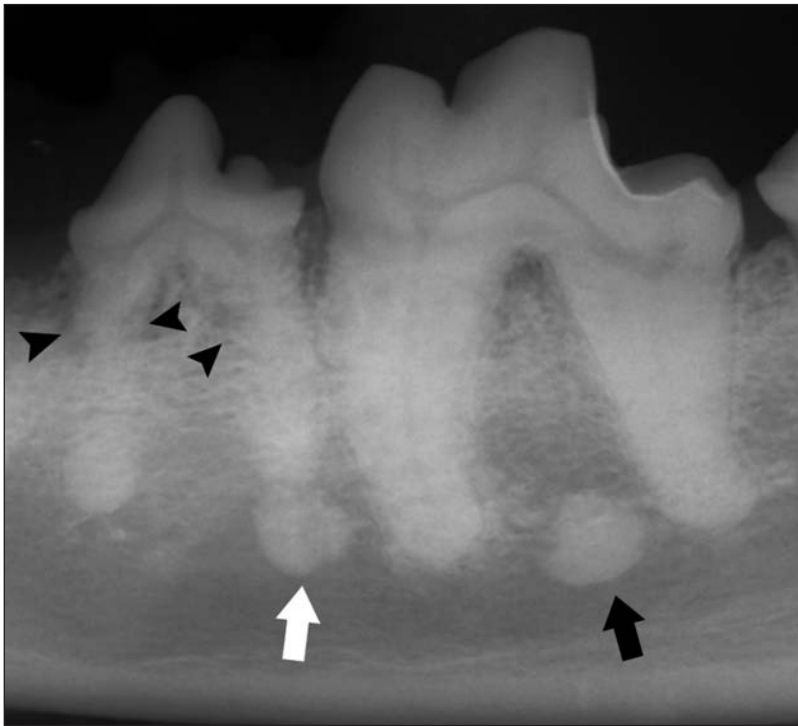


Figure 2—Same radiographic view as in Figure 1. Notice the circular radiopacities between the roots of the first molar tooth (black arrow) and at the distal root of the fourth premolar tooth (white arrow). The periodontal ligament space of the fourth premolar tooth is indistinct, and there is evidence of replacement of the tooth structure with trabecular bone (black arrowheads).

### **Diagnostic Imaging Findings and Interpretation**

On the intraoral radiographic view of the caudal portion of the left mandible (Figure 2), a well-defined, localized, circular (5.0-mm-diameter) radiopacity with irregular edges can be seen between the roots of the first molar tooth, and a similar circular (4.6-mm-diameter) radiopacity can be seen ventral to the distal root of the fourth premolar tooth. The periodontal ligament space of the fourth premolar tooth is indistinct, and there is apparent replacement of the root structure by trabecular bone, consistent with external replacement tooth resorption. The cusps of the first molar tooth are blunted, corresponding to the finding of abrasion of this tooth during oral examination.

In dogs, mandibular radiopacities can be associated with or distinct from the tooth roots. Radiopacities not associated with a tooth root are most likely osteosclerosis and of no clinical importance.<sup>1,2</sup> These lesions can occur between the roots or away from the teeth, although they can also occur at the root apices.<sup>1</sup> In addition to osteosclerosis, differential diagnoses for an opacity near the apex of a tooth include a periapical inflammatory lesion or stage 3 periapical cemental dysplasia.<sup>3</sup>

The radiopacity between the roots of the first molar tooth was not associated with a tooth root and was considered to most likely represent osteosclerosis. The radiopacity at the distal root of the fourth premolar tooth was very close to the apex of the tooth. However, the tooth did not have any signs of periodontal or endo-

dontic disease, so an inflammatory lesion was considered unlikely and osteosclerosis was considered the most likely cause of this lesion. Although external tooth resorption is associated with inflammation in humans, external replacement root resorption is believed to be an incidental radiographic finding in dogs and should not require treatment.<sup>4,5</sup>

### **Treatment and Outcome**

No treatment was recommended for the mandibular radiopacities or tooth resorption. Appropriate treatment was given for all other lesions.

### **Comments**

Full-mouth radiography often reveals unexpected lesions that are not apparent during an oral examination. In the dog of the present report, the left mandibular fourth premolar tooth was clinically unremarkable, but had radiographic signs of external replacement tooth resorption. In addition, 2 radiopacities were seen on a radiographic view of the mandible. To our knowledge, there have been no reported studies of the histologic appearance of similar mandibular radiopacities in dogs, so interpretation is based on clinical and radiographic similarities to lesions found in humans.

In the human literature, osteosclerosis is also called enostosis, dense bone islands, bone scar, and focal periapical osteopetrosis.<sup>1,2,6</sup> Histologic examination of these lesions reveals vital bone with obliteration of the normal marrow spaces by dense compact bone and minimal or nonexistent inflammatory elements.<sup>2,7</sup> These lesions can be difficult to distinguish from inflammatory lesions if they are centered on the root apex. However, if the periodontal ligament space around the apex of the tooth is uniform and the periphery of the lesion does not blend into the surrounding trabeculae, it is likely that the lesion is osteosclerosis.<sup>6</sup>

In humans, periapical cemental dysplasia is an asymptomatic condition of unknown etiology whereby normal cancellous bone is replaced with various mixtures of fibrous tissue, cementum-like material, and abnormal bone. The condition begins as a periapical lucency, then progresses to a mature stage (stage 3), at which time a dense, radiopaque structure is evident within the radiolucency.<sup>6,8</sup> Lesions of stage 3 cemental dysplasia are radiopaque<sup>3</sup> but, in humans, may have a slight radiolucent periphery, distinguishing them from lesions of osteosclerosis.<sup>8</sup>

In the human literature, inflammatory lesions visible as radiopacities associated with the mandibular tooth roots have been called focal periapical osteopetrosis, sclerosing osteitis, or condensing osteitis. All are the result of stimulation of bone formation as a result of chronic inflammation associated with long-term pulpitis. Typically,

these radiopacities are located at the apex of the tooth, although they can occur at other areas of the tooth root near accessory canals.<sup>6</sup>

The left mandibular fourth premolar tooth in the dog of the present report had radiographic signs of tooth resorption. Although the type of tooth resorption can only be definitively identified through histologic examination,<sup>3</sup> the radiographic appearance and lack of clinical signs were consistent with external replacement resorption. External replacement resorption is characterized radiographically by loss of the periodontal ligament space around the roots and replacement of the dental structures by alveolar bone.<sup>4,5</sup> In dogs, external replacement resorption has not been associated with inflammation or concurrent dental disease.<sup>4,5</sup> It is likely that the radiopacity at the apex of the tooth root in this dog was unrelated to the root resorption.

In dogs, mandibular radiopacities are sometimes discovered when full-mouth radiography is performed. In the absence of clinical or radiographic signs of endodontic or periodontal disease, these lesions are most likely incidental findings and do not require further treatment.

## References

1. Sisman Y, Ertas ET, Ertas H, et al. The frequency and distribution of idiopathic osteosclerosis of the jaw. *Eur J Dent* 2011;5:409–414.
2. Bsoul SA, Alborz S, Terezhalmay GT, et al. Idiopathic osteosclerosis. *Quintessence Int* 2004;35:590–591.
3. DuPont GA, DeBowes LJ. Miscellaneous conditions. In: DuPont GA, DeBowes LJ, eds. *Atlas of dental radiography in dogs and cats*. Philadelphia: WB Saunders Co, 2009;221–228.
4. Arnjberg J. Idiopathic dental root resorption in old dogs. *J Vet Dent* 1996;13:97–98.
5. Peralta S, Verstraete FJM, Kass PH. Radiographic evaluation of the types of tooth resorption in dogs. *Am J Vet Res* 2010;71:784–793.
6. Lee L. Inflammatory lesions of the jaw. In: White SC, Pharoh MJ, eds. *Oral radiology: principles and interpretation*. 5th ed. St Louis: Mosby, 2004;366–371.
7. Giest JR, Katz JO. The frequency and distribution of idiopathic osteosclerosis. *Oral Surg Oral Med Oral Pathol* 1990;69:388–393.
8. White SC, Pharoh MJ. Diseases of bone manifested in the jaws. In: White SC, Pharoh MJ, eds. *Oral radiology: principles and interpretation*. 5th ed. St Louis: Mosby, 2004;485–515.





**50 YEARS**  
Protecting You & Your Assets  
**AVMA**



**PLIT**  
Security • Stability • Strength  
1962 • 2012

# Strength

since 1962

**Solutions for your practice**

- Business Property/Liability
- Data Breach
- Flood
- Umbrella Liability
- Workers' Compensation
- Commercial Auto
- Employment Practices Liability

**Solutions for your livelihood**

- Professional Liability
- Veterinary License Defense
- Extension (Animal Bailee)
- Embryo and Semen Transfer Services Coverage
- Safety Resources

**Solutions for your home**

- Auto
- Home
- Renters
- Excess

Call **855.228.PLIT (7548)** today for an evaluation of your insurance portfolio and a free premium quotation.

[www.avmaplit.com](http://www.avmaplit.com)

Trust Broker and Administrator

HUB International Midwest Limited, HUB International Midwest Insurance Agency (CA)