

# What Is Your Diagnosis?

In cooperation with

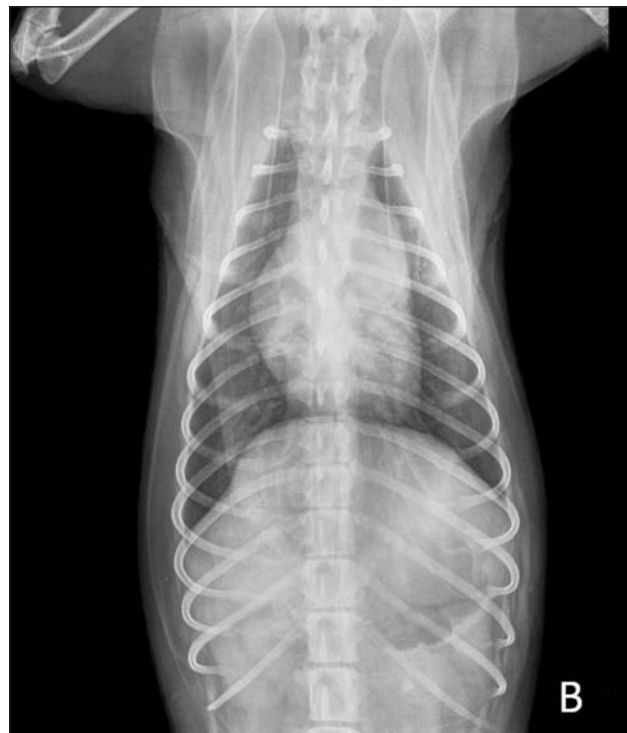
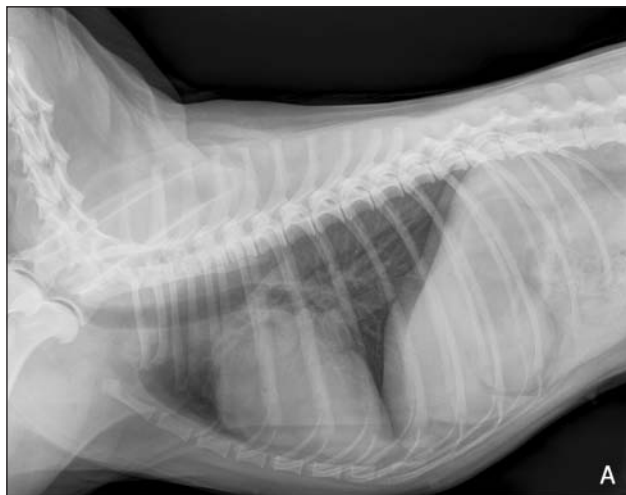
Figure 1—Right lateral (A) and dorsoventral (B) radiographic views of the thorax of a mixed-breed dog evaluated because of a single episode of collapse.

## History

An 8-kg (17.6-lb) 2-year-old female mixed-breed dog was examined after a single episode of collapse during exercise. On physical examination, the dog had a regular cardiac rhythm with a heart rate of 104 beats/min (reference range, 70 to 180 beats/min). On palpation, the femoral arterial pulse was weak. A grade V/VI systolic murmur, best heard at the left heart base, was audible. Electrocardiography revealed sinus rhythm with right atrial enlargement and right-axis deviation with a mean electrical axis of the QRS complex of  $120^\circ$  in the frontal plane. Results of a CBC, serum biochemical analysis, and urinalysis were within reference limits. Radiographs of the thorax were obtained (Figure 1).

Determine whether additional imaging studies are required, or make your diagnosis from Figure 1—then turn the page →

This report was submitted by Alessia Luciani, DVM; Sarah Sconza, DVM, PhD; and Carlo Guglielmini, DVM, PhD; from the Department of Veterinary Clinical Sciences, Faculty of Veterinary Medicine, University of Teramo, 64100 Teramo, Italy. Dr. Guglielmini's present address is Department of Veterinary Clinical Sciences, Faculty of Veterinary Medicine, University of Padova, 35020 Legnaro (PD), Italy. Address correspondence to Dr. Luciani (aluciani@unite.it).

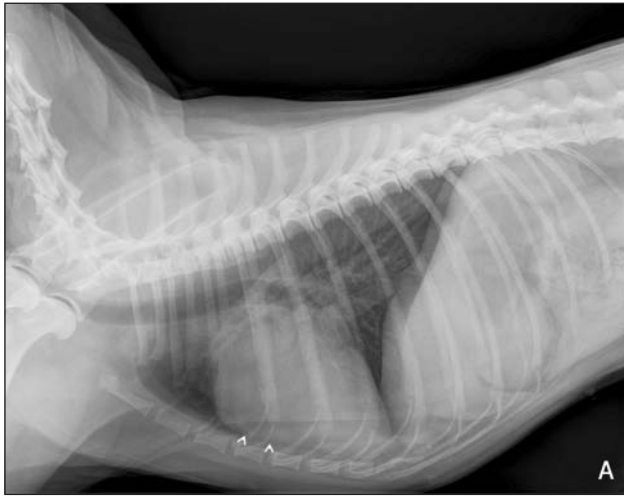
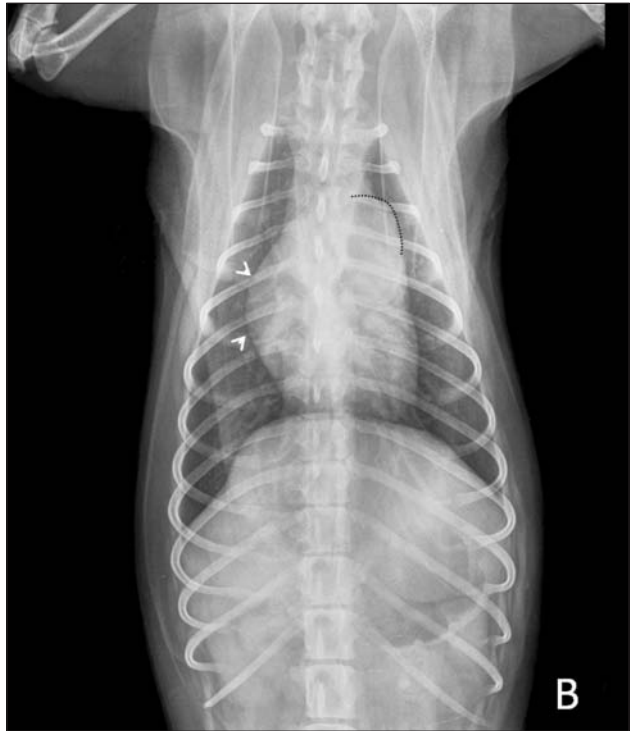
Figure 2—Same radiographic views as in Figure 1. On the lateral view (A), notice the increased sternal contact of the cardiac silhouette (arrowheads). On the dorsoventral view (B), the heart has a reversed letter D appearance (arrowheads) and there is a bulge in the 1 to 2 o'clock position (dotted line).



### Diagnostic Imaging Findings and Interpretation

On the lateral radiographic view (Figure 2), the cardiac silhouette is mildly enlarged with a vertebral heart score of 10.9 vertebrae (reference range, 8.5 to 10.6 vertebrae) and there is increased sternal contact. On the dorsoventral radiographic view, the cardiac silhouette has a reversed D appearance, with prominence of the main pulmonary trunk. Differential diagnoses included right-sided cardiac diseases, pulmonary hypertension, and heartworm disease.

Echocardiography was performed, and an echogenic membranous stenosis of the main pulmonary artery (PA), 13 mm distal to the normal pulmonic valve, was found (Figure 3). The internal diameter of the stenotic lesion was 7 mm, and the diameter of the pulmonic valve was 14 mm. Mild right ventricular concentric hypertrophy was also found. Color flow Doppler ultrasonographic mapping revealed laminar blood flow through the pulmonic valve, high-velocity turbulent flow during systole, and laminar diastolic flow at the level of the stenotic lesion. Peak flow velocity, measured by use of continuous wave Doppler ultrasonography, was 4.02 m/s, and a peak systolic pressure gradient of 65 mm Hg was calculated by use of the modified Bernoulli equation. Selective right ventricular angiography under fluoroscopy was performed and confirmed an isolated lesion of the main PA just proximal to the bifurcation without involvement of the branched or peripheral segmental pulmonary arteries. Thus, supravalvular PA stenosis (PAS) of probable congenital origin was diagnosed.

### Comments

Pulmonary artery stenosis in dogs can be valvular or supravalvular, with the supravalvular type being rare.<sup>1,2</sup> Four forms of congenital supravalvular PAS have been described. Type I is a single constriction of either the main, right, or left PA of various length. Type II is found at the bifurcation of the main PA with involvement of the distal portion of the main PA. Type III is stenoses of multiple PA segments at their ostia, and type IV is multiple stenoses

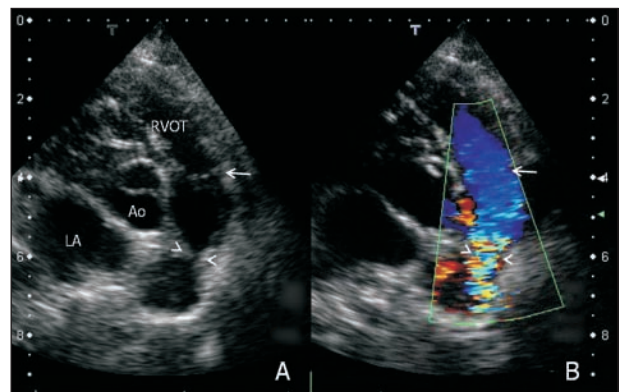


Figure 3—Two-dimensional right parasternal short-axis echocardiogram at the level of the aortic valve (A) and color flow mapping of pulmonary blood flow (B) of the same dog as in Figure 1. Notice the echogenic membranous stenosis (arrowheads) distal to the pulmonic valve (arrows). Color flow Doppler ultrasonography shows turbulent blood flow during systole, as indicated by a mosaic-like color display, at the level of the stenotic lesion. Blood flow is laminar at the level of the pulmonic valve. Scale markers to the left and right of images indicate distance in centimeters. Ao = Aorta. LA = Left atrium. RVOT = Right ventricular outflow tract.

involving peripheral segments as well as central pulmonary arteries.<sup>2</sup> According to the peak systolic pressure gradient, PAS is considered mild (< 50 mm Hg), moderate (50 to 100 mm Hg), or severe (> 100 mm Hg). In the dog described here, mild to moderate type I supravalvular PAS was diagnosed. The dog was discharged without treatment, and neither worsening of clinical signs nor deterioration of echocardiographic findings was observed at follow-up examinations during the subsequent 2 years.

1. Buchanan JW. Causes and prevalence of cardiovascular diseases. In: Kirk RW, Bonagura JD, eds. *Current veterinary therapy XI: small animal practice*. Philadelphia: WB Saunders Co, 1992;647–654.
2. MacGregor JM, Winter MD, Keating J, et al. Peripheral pulmonary artery stenosis in a four-month-old West Highland White Terrier. *Vet Radiol Ultrasound* 2006;47:345–350.