

Description and genetic analysis of three sets of monozygotic twins resulting from transfers of single embryos to recipient mares

Semira S. Mancill, DVM, DACT; Glenn Blodgett, DVM; Robert J. Arnott, DVM; Marco Alvarenga, DVM, PhD; Charles C. Love, DVM, PhD, DACT; Katrin Hinrichs, DVM, PhD, DACT

Case Description—3 sets of monozygotic twins resulting from transfers of single embryos to recipient mares were examined.

Clinical Findings—In all 3 recipient mares with twin pregnancies, only 1 embryonic vesicle was detected before day 25 of gestation. In 1 recipient mare, 2 apparent adjacent vesicles, each containing an embryo with a heartbeat, were visualized on ultrasonographic examination on day 37 of gestation. The other 2 recipient mares underwent ultrasonographic examination on day 30 of gestation, at which time only 1 vesicle and embryo was identified. In these latter 2 recipient mares, however, a thorough ultrasonographic examination for a second conceptus on day 30 had not been performed, as only 1 embryo had been transferred and visualized on early ultrasonographic examination.

Treatment and Outcome—All twin pregnancies resulted in death of both fetuses. Genetic analysis confirmed that each set of monozygotic twins originated from the transferred embryo.

Clinical Relevance—Monozygotic twin pregnancy may occur after embryo transfer; thus recipient mares should be examined thoroughly for multiple conceptuses, especially between 25 and 30 days of gestation. At this time, the allantoides of monozygotic twins should be visible ultrasonographically and effective management may still be possible. (*J Am Vet Med Assoc* 2011;238:1040–1043)

A 12-year-old Quarter Horse mare intended as an embryo donor was treated with a compounded formulation of deslorelin acetate^a (1.5 mg, IM) when a single preovulatory follicle was 45 mm in diameter, and the mare was inseminated with shipped cooled semen that day. The mare had ovulated when checked 36 hours after deslorelin administration. The day of detection of donor mare ovulation was designated day 0 of gestation. Uterine flush for embryo recovery was performed 7 days after detection of ovulation. One expanded blastocyst of normal size for day 7 was identified immediately after the flush. The embryo was shipped cooled in holding medium^b within a shipping container^c by overnight delivery.

The embryo was transferred transcervically to a recipient mare (mare 1) that had ovulated 5 days previously. The recipient mare was treated with a long-acting

progesterone formulation^d (1,500 mg, IM, q 1 wk for 3 months). Transrectal ultrasonographic examination of the reproductive tract was performed on days 12, 16, and 23 of gestation, and only 1 embryonic vesicle was seen. Ultrasonographic examination on day 37 of gestation revealed 2 embryos with heartbeats, adjacent to each other but apparently in separate sacs. The mare was monitored approximately every month, and 2 fetuses continued to be detected. The mare aborted 2 sorrel colts (**Figure 1**) at 10 months of gestation.

Examination of the aborted tissue revealed that the foals were in separate amnions. There appeared to be separate allantoic sacs within 1 continuous external chorionic membrane (**Figure 2**). The umbilical cords of the 2 foals attached closely to each other at the bifurcation of the uterine horns, 1 on each side of the dividing membrane between the 2 sacs. An apparent division line could be seen in the external chorionic membrane, but attempts to pull the membrane apart at this area caused tearing of the tissue.

Hair samples were taken from both foals, from the recipient mare, and from the donor mare and were analyzed for genetic markers at an external laboratory.^e Genetic analysis of 13 microsatellites revealed that the aborted twin foals had identical genotypes and that they qualified as being offspring of the donor mare, and that the recipient mare could not be the genetic dam of the aborted foals.

A 5-year-old Thoroughbred mare to be used as an embryo donor was inseminated with frozen-thawed semen within 2 hours after ovulation. The mare was examined again 8 hours later and was observed to

From the Department of Large Animal Clinical Sciences, College of Veterinary Medicine, Texas A&M University, College Station, TX 77843 (Mancill, Love, Hinrichs); 6666 Ranch, PO Box 130, 1102 Dash For Cash Rd, Guthrie, TX 79236 (Blodgett); Saint John Valley Veterinary Services Inc, 192 Broadway St, Woodstock, NB E7M 6B3, Canada (Arnott); and the Department of Animal Reproduction and Veterinary Radiology, Veterinary School, University of Sao Paulo State, UNESP, Botucatu, SP 18618-000, Brazil (Alvarenga). Dr. Mancill's present address is SDP Buffalo Ranch, 1790 FM 2871, Fort Worth, TX 76126.

Supported in part by the Link Equine Research Fund, Texas A&M University.

Presented in abstract form at the Annual Convention of the 54th American Association of Equine Practitioners, San Diego, December 2008.

Address correspondence to Dr. Mancill (semiradvm@gmail.com).

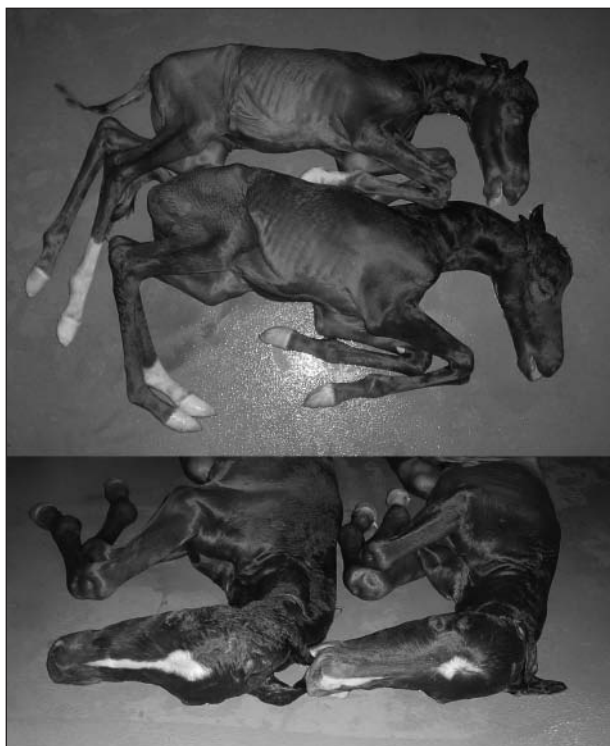

Figure 1—First set of monozygotic twin colts that were aborted at 10 months of gestation from recipient mare 1 of this report. Notice the differences in facial and limb markings between the colts.

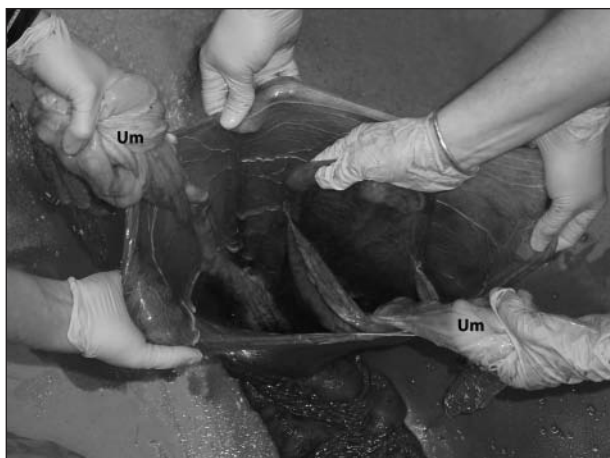

Figure 2—Placenta from monozygotic twins that were aborted at 10 months of gestation from recipient mare 1 in this report. The view is from the opening at the cervical star; notice that there are 2 allantoic sacs. The chorionic surface was continuous. Um = Umbilicus.

have ovulated a second follicle. The mare's uterus was flushed for embryo recovery on day 8 after ovulation, and 2 embryos were recovered. One embryo was located immediately and was classified as a normal 8-day blastocyst. The other embryo was located after 1 hour; this embryo was small and was thought to be either a morula or an unfertilized oocyte.

The blastocyst was transferred transcervically to a recipient mare that had ovulated 5 days previously; no pregnancy resulted from this transfer. The small embryo was transferred to a 9-year-old Thoroughbred re-

ipient mare (mare 2) that had ovulated 1 of 2 large follicles 4 days previously. This recipient mare was not followed to determine whether the second follicle went on to ovulate. On day 16 of gestation, the reproductive tract of recipient mare 2 was examined by transrectal ultrasonography and one 20-mm-diameter embryonic vesicle was visualized. The mare was evaluated again on day 30 of gestation, and a conceptus with an embryonic heartbeat was observed.

The recipient mare gave birth to twin foals, both bay fillies, at 10.5 months of gestation. Both foals were dead at delivery. The foals were in separate amnions, and there appeared to be only 1 chorioallantois, although a thorough examination of the placenta was not performed.

Mane hairs were taken from both foals, from the recipient mare, and from the donor mare and were analyzed for genetic markers via microsatellite analysis at an external laboratory.^c Genetic analysis of 13 microsatellites revealed that the aborted twin foals had identical genotypes and that they qualified as being offspring of the donor mare and that the recipient mare could not be the genetic dam of the aborted foals.

An 18-year-old Holsteiner mare intended as an embryo donor was inseminated with frozen semen within 8 hours after ovulation. Uterine flush for embryo recovery was performed 9 days after insemination. One embryo was identified immediately after the flush and was classified as a morula.

The embryo was transferred transcervically to a recipient mare (mare 3) that had ovulated 6 days previously. The recipient mare was checked for pregnancy on days 16 and 30 of gestation, and only 1 vesicle was seen on each examination. The mare gave birth to twin bay colts at 345 days of gestation; both foals died within a few hours after birth. The foals were in separate amnions, and there appeared to be only 1 chorioallantois, although a thorough examination of the placenta was not performed.

Hair samples were taken from both foals and from the donor mare and were analyzed for genetic markers at a private laboratory.^f Genetic analysis of 13 microsatellites revealed that the aborted twin foals had identical genotypes and that they qualified as being offspring of the donor mare. The genotype of the recipient mare was not evaluated.

Discussion

Monozygotic twins are defined as 2 individuals derived from fertilization of 1 oocyte by 1 sperm, with the result that their DNA makeup is identical. This is in contrast to dizygotic twins, which result from the ovulation of 2 oocytes, with fertilization of each oocyte by separate sperm. Embryonic factors associated with twin pregnancies in humans have been reviewed.¹ Twenty percent to 30% of live-born human monozygotic twins have completely separate placental membranes (ie, they are dichorionic diamniotic). This may occur by blastomere separation in the first few days after fertilization, with 2 separate blastocysts formed from the separated blastomeres. Alternatively, a single growing blastocyst may be pinched into 2 during so-called hatching from the zona pellucida. Most (70% to 75%) monozygotic

twins in humans are monochorionic (ie, share 1 chorionic membrane and thus 1 placenta) but are diamniotic (ie, each fetus is enclosed within a separate amniotic sac). This is thought to occur when 2 inner cell masses form within 1 blastocyst. Monochorionic monoamniotic twins are the least common, being seen in only 1% to 2% of monozygotic twins. These twins, which include conjoined twins, occur when 2 embryos form from 1 inner cell mass.

A multiple monozygotic pregnancy is generally assumed to be rare in horses. In 1 report,² apparent monochorionic diamniotic twins were identified on necropsy of aborted fetuses but no genetic testing was performed. Meadows et al³ identified monochorionic triamniotic triplets in a Thoroughbred mare. The 3 embryos were visualized on transrectal ultrasonographic examination of the reproductive tract during the first examination of the mare 24 days after mating and were removed from the mare 4 days later. The 3 embryos were contained within separate amniotic sacs, and each had its own allantois. The embryos shared a communal yolk sac, and the outer chorion was continuous around all 3 embryos. The 3 embryos had identical genotypes on analysis of 4 microsatellites.

McCue et al⁴ reported on 3 sets of twins that were detected after surgical transfer of single embryos, all morulae, into the uteri of recipient mares. McCue et al⁴ reported that all 3 twin equine pregnancies resulted in loss of both embryos; no genetic analyses were performed. Two of these embryos were reported as being collected on day 7 after ovulation; the day of collection of the third embryo was not given. For 1 of the 3 twin pregnancies reported, 2 embryonic vesicles were seen ultrasonographically at 16 days of gestation. For the other 2 twin pregnancies reported, a single embryonic vesicle was visualized on ultrasonographic examination on days 12 to 16 of gestation, but subsequent evaluations on days 25 to 33 of gestation revealed that in each twin pregnancy, the vesicle contained 2 embryos with heartbeats. In both of these pregnancies, the conceptus was lost before 45 days.

Findings in the present report confirm that formation of monozygotic equine twins can occur after embryo transfer of a single embryo. A notable feature in the present report and the report by McCue et al⁴ (although not genetically verified in that report) is that 5 of the 6 the sets of monozygotic equine twins resulted from transfer of embryos that were apparently retarded in development (ie, they were at the morula stage even though they were collected at day 7 or 8 after ovulation). The equine embryo is expected to be an expanded blastocyst by day 7 and grows rapidly in diameter during the following days. Embryos that have retarded development are commonly seen when uterine flushes are done in older mares; 3 of the 6 donor mares in these 2 reports (the present report and that of McCue et al⁴) were ≥ 18 years old. These morulae may already have had perturbations in development, and their retarded developmental status may be indicative of errors ongoing in blastocoele formation. Alternatively, morulae may be more sensitive to environmental insult than are blastocysts; relative to this, it should be noted that one of the morulae in the present report was not located

until an hour after uterine flushing, and 2 of the morulae reported by McCue et al⁴ were shipped in a passive cooling system before transfer. The blastocyst in the present report that produced twins after embryo transfer was also shipped overnight.

In humans, monozygotic twin pregnancies are seen more commonly after assisted reproductive techniques (ie, in vitro fertilization or intracytoplasmic sperm injection and embryo culture).⁵ Monozygotic twin pregnancies after assisted reproductive techniques in humans have been associated with breaching of the zona pellucida, which occurs during sperm injection or is performed intentionally to enable so-called assisted hatching.⁵ The proposed mechanism for the development of monozygotic twins is that embryonic tissue pushes through the small opening in the zona pellucida and then pinches off, resulting in the division of the embryo into 2. This form of monozygotic twin pregnancy is unlikely to occur in horses for 2 reasons. First, the equine zona thins and fragments off the capsule, so no protrusion of the blastocyst through a narrow opening (ie, hatching) normally occurs; second, even if there were a hatching-type event (eg, because of a break in the zona), the presence of the equine embryonic capsule would impede separation of the blastocyst into 2 pieces. Other factors, such as embryo handling, makeup of embryo culture media, and criteria for selection of embryos for transfer, have been related to monozygotic twin pregnancy after assisted reproductive techniques in humans.⁵

Applying human nomenclature to equine twin pregnancy can be problematic. In humans, the allantois is rudimentary and is not typically mentioned in twin classification, whereas in horses, the allantois is the main fluid cavity of the pregnancy. The equine amnion forms around the developing embryonic disk starting at about day 16 after ovulation.⁶ The allantois arises from the equine hindgut at approximately day 21 after ovulation; therefore, any twin pregnancy that is diamniotic (having fetuses in separate amnions) must also be diallantoic (ie, have separate allantoides). In humans, twins with shared allantoides have been reported, but because the allantois arises from the embryonic hindgut, shared allantoides are seen only in ischiopagus twins (ie, those that are conjoined in the perineum, pelvis, and lower abdominal wall).⁷

The time of formation of the equine allantois explains the clinical findings in the present report and those of McCue et al⁴ in which only 1 vesicle was seen on early ultrasonographic examination, but 2 adjacent sacs were visualized on day 20 of gestation. Although no second conceptus was observed in recipient mares 2 and 3 of the present report, a thorough ultrasonographic examination for a second conceptus after day 25 of gestation was not conducted in either of these recipient mares, as only 1 embryo had been transferred and visualized on early ultrasonographic examination. Potential development of monozygotic twins from a single blastocyst having 2 inner cell masses is depicted (Appendix). When evaluating a mare having this type of development, early ultrasonographic examinations would reveal a single vesicle, whereas later examinations, after day 25 of gestation, when the allantoides are large enough to be visible on ultrasonographic ex-

amination, would reveal 2 embryos proper in separate sacs. It is likely that Doppler ultrasonography of such a vesicle at 16 to 18 days of gestation would reveal 2 separate early indicator spots, as described for singleton pregnancies at the site of later appearance of the embryo proper.⁸

Because the embryos have separate amnions and allantoides but are enclosed within the same chorion, these are diamniotic, diallantoic, monochorionic equine twins. Comparable anatomy was found for monozygotic triplets previously reported after natural cover³; the 3 embryos were each in their own amnion and allantois, within a continuous chorion. This mode of development is compatible with the placental anatomy found after abortion of the first set of twins of the present report, in which 2 inner sacs were found within an apparently continuous outer chorionic membrane. In dizygotic (fraternal) twins, placentae may initially appear to be joined but may be separated by gentle traction, revealing an avillous area on each at the interface between the 2 chorioallantoides. It is theoretically possible that the chorioallantoides of dizygotic twins could fuse and might appear similar to that described for the first set of twins of the present report.

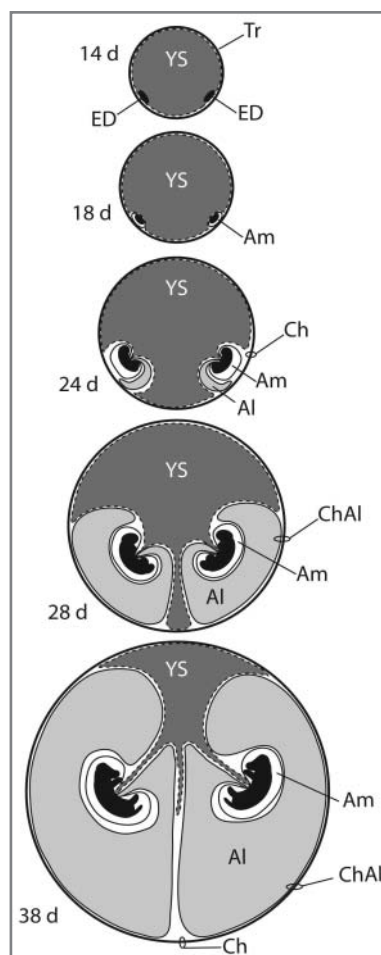
The recognition of 3 sets of monozygotic twins within a 2-year period suggests that monozygotic twins in horses may be more common than previously thought. As is found in cloned horses,⁹ markings were not identical in the monozygotic twins in the present report as seen in the differences in both facial and limb markings in the colts of mare 1. Thus, monozygotic twins observed after birth or abortion may not be obviously identical. Although monozygotic twins are of the same sex, so would be 50% of fraternal (dizygotic) twins. It is only in approximately the last 15 years that DNA typing has become readily available to definitively prove monozygosity, and during this time, the incidence of twin pregnancies and thus twin births has been greatly reduced through the ability to recognize and correct these by use of transrectal ultrasonography and manual twin reduction or early abortion if unilateral twins are present after approximately 30 days (as would be true of the monochorionic twins as defined in the present report). Thus, the population of twin births from which monozygotic twins could be definitively identified via genetic analysis has been greatly reduced.

To our knowledge, this is the first report of monozygotic twin pregnancies after embryo transfer confirmed by genetic analysis. Although monozygotic twin pregnancy is the most likely reason for the previously reported multiple pregnancies after embryo transfer,⁴ other possibilities exist, such as conception by the recipient as a result of unintended mating on the previous estrus. Birth of foals within a single chorion is not in itself evidence of monozygosity, as chimerism (fusion of dizygotic twins) could potentially result in monochorionic or monoamniotic membranes and even in formation of a single individual from 2 separate embryos, as has been reported in brindle horses.¹⁰ In the present report, genetic testing of the foals verified that monozygotic twins resulted from 1 transferred embryo.

- a. Wickliffe Pharmacy, Lexington, Ky.
- b. Emcare, ICPbio, Auckland, New Zealand.
- c. Equitainer, Hamilton Research Inc, South Hamilton, Mass.
- d. BETPharm, Lexington, Ky.
- e. Veterinary Genetics Laboratory, University of California-Davis, Davis, Calif.
- f. LINKGEN, Sao Paulo, Brazil.

References

1. Hall JG. Twinning. *Lancet* 2003;362:735–743.
2. Rooney JR. *Autopsy of the horse*. Baltimore: Williams & Wilkins, 1970.
3. Meadows SJ, Binns MM, Newcombe JR, et al. Identical triplets in a Thoroughbred mare. *Equine Vet J* 1995;27:394–397.
4. McCue PM, Thayer J, Squires EL, et al. Twin pregnancies following transfer of single embryos in three mares: a case report. *J Equine Vet Sci* 1998;18:832–834.
5. Moayeri SE, Behr B, Lathi RB, et al. Risk of monozygotic twinning with blastocyst transfer decreases over time: an 8-year experience. *Fertil Steril* 2007;87:1028–1032.
6. Ginther OJ. Embryology and placentation. In: *Reproductive biology of the mare: basic and applied aspects*. Cross Plains, Wis: Equiservices, 1992;345–418.
7. Spencer R. Minimally united ischiopagus twins: infraumbilical union with cloacal anomalies. *J Pediatr Surg* 1996;31:1538–1545.
8. Silva LA, Ginther OJ. An early endometrial vascular indicator of completed orientation of the embryo and the role of dorsal endometrial encroachment in mares. *Biol Reprod* 2006;74:337–343.
9. Hinrichs K, Choi YH, Varner DD, et al. Production of cloned horse foals using roscovitine-treated donor cells and activation with sperm extract and/or ionomycin. *Reproduction* 2007;134:319–325.
10. Hamilton C. One in a million. *J Am Quarter Horse Assoc* 2006;52–55.



Appendix

Schematic depiction of development of monozygotic (diamniotic, diallantoic, and monochorionic) equine twins. Al = Allantois. Am = Amnion. Ch = Chorion. ChAl = Chorioallantois (allantochorion). ED = Embryonic disc. Tr = Trophoblast. YS = Yolk sac. Note that a single chorion encloses both fetuses, whereas they have separate allantoic cavities. (Adapted from single embryo figure, Ginther OJ. Embryology and placentation. In: *Reproductive biology of the mare: basic and applied aspects*. Cross Plains, Wis: Equiservices, 1992;345–418.)