

Pathology In Practice

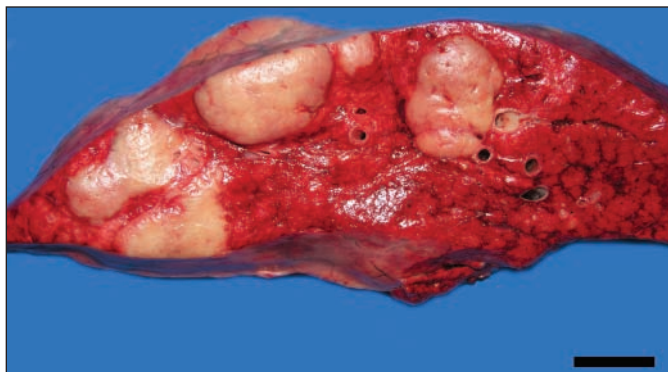


Figure 1—Photograph of the right caudal lung lobe of a young horse that had weight loss and respiratory tract signs (including cough and nasal discharge) of approximately 6 months' duration. The horse was considered to have a guarded to poor prognosis and was euthanized. Notice that the normal pulmonary parenchyma is replaced by sharply delimited, white, firm, coalescing nodules that range from 2 to 8 cm in diameter. Bar = 3 cm.

History

A 2-year-old Arabian filly had been imported to the United States from Germany as a weanling in the fall of 2006. In July 2007, the horse developed weight loss and respiratory tract signs including cough and nasal discharge. Treatment with trimethoprim-sulfamethoxazole resulted in clinical improvement for a short period, but in December 2007, the horse began to lose weight again and became lethargic and dyspneic. The horse was referred for evaluation in January 2008.

Clinical and Gross Findings

At the initial evaluation, the horse weighed 331.1 kg (728.4 lb) and was thin (body condition score, 2.5 on a scale of 1 to 9). Rectal temperature was 37.2°C (98.9°F), heart rate was 36 beats/min, and respiratory rate was 44 breaths/min. Mucopurulent nasal discharge from both nares was evident, and a productive cough was elicited via gentle tracheal palpation. Diffuse crackles and wheezes were detected via thoracic auscultation, and a tracheal rattle was noticeable via tracheal auscultation. Thoracic radiography revealed multiple moderately well-defined soft tissue opacities (ranging from 1-cm nodules to larger, coalescing masses [9 to 10 cm in diameter]), consistent

with a severe nodular interstitial pattern. Transthoracic ultrasonography revealed multiple discrete nodules (8 to 24 mm in diameter) within the periphery, which were more prominent in the cranioventral portion of the thorax from the 4th to 11th intercostal spaces. Results of clinicopathologic analyses indicated that the horse had hyperfibrinogenemia (700 mg/dL [reference range, 100 to 400 mg/dL]). Assessment of transtracheal wash samples revealed neutrophilic inflammation (76% non-degenerate neutrophils, 21% large mononuclear cells, and 3% small lymphocytes) without evidence of fungal or bacterial organisms. A bronchoalveolar lavage sample contained a high number of cells (35% neutrophils, 10% small lymphocytes, and 55% large mononuclear cells). Bacterial and fungal cultures of transtracheal wash fluid yielded no growth. The result of an equine herpesvirus (EHV) type 5 PCR assay performed on bronchoalveolar lavage fluid was positive.

Pending results of the microbiologic cultures, the horse was treated with antimicrobials and flunixin meglumine for 4 days. On the basis of the extent of lung involvement, negative culture results, and the positive EHV-5 PCR assay result, the horse was considered to have a guarded to poor prognosis and was euthanized. On gross examination, the lungs did not collapse and had coalescing white areas that slightly raised the overlying pleura. Numerous white, firm, coalescing nodules (2 to 8 cm in diameter) effaced as much as 80% of the pulmonary parenchyma (Figure 1). The visceral pleura of the cranioventral areas of the lungs had tortuous neovascularization. All mediastinal lymph nodes were severely enlarged, and cut surfaces were white.

Formulate differential diagnoses from the history, clinical findings, and Figure 1—then turn the page →

This report was submitted by Steven V. Kubiski, DVM; Raquel R. Rech, DVM, PhD; Melinda S. Camus, DVM; Alessandra Pellegrini-Masini, DVM, PhD, DACVIM; Johanna R. Elfenbein, DVM; and Elizabeth W. Howerth, DVM, PhD, DACVP; from the Departments of Pathology (Kubiski, Rech, Camus, Howerth) and Large Animal Medicine (Pellegrini-Masini, Elfenbein), College of Veterinary Medicine, University of Georgia, Athens, GA 30602.

The authors thank Dr. Kurt Williams, Michigan State University, for performing the equine herpesvirus type 5 PCR assay. Address correspondence to Dr. Howerth.

Histopathologic Findings

The lungs of the horse were removed during necropsy and processed for histologic examination. Extensive areas of the lungs had marked interstitial expansion of septa by well-organized mature collagen, which preserved the alveolar architecture and resulted in a glandular appearance of the parenchyma (Figure 2). The interstitium was infiltrated by moderate numbers of lymphocytes and plasma cells and fewer macrophages

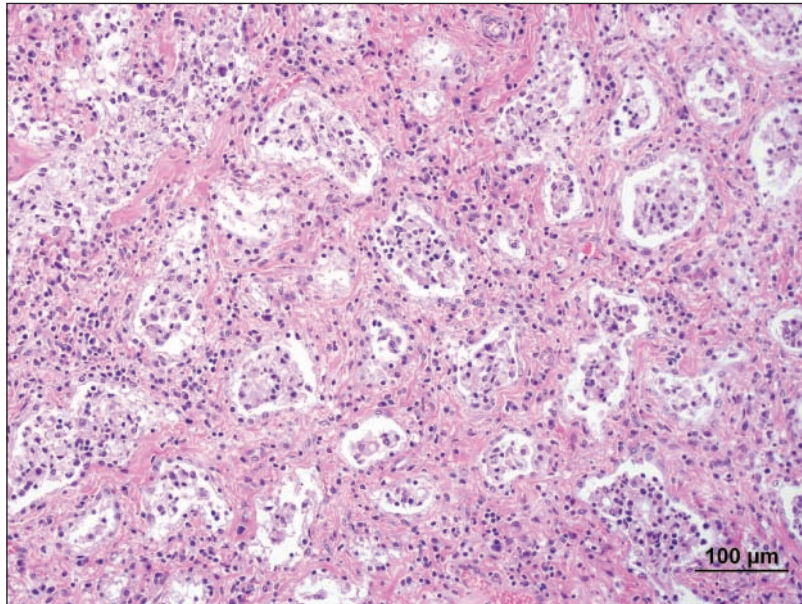


Figure 2—Photomicrograph of a section of lung obtained from the horse in Figure 1. Notice that the parenchyma has a glandular appearance; the alveolar septa are thickened with mature fibrous connective tissue, a mixed inflammatory infiltrate is present, and type II cell hyperplasia is evident. H&E stain; bar = 100 μ m.

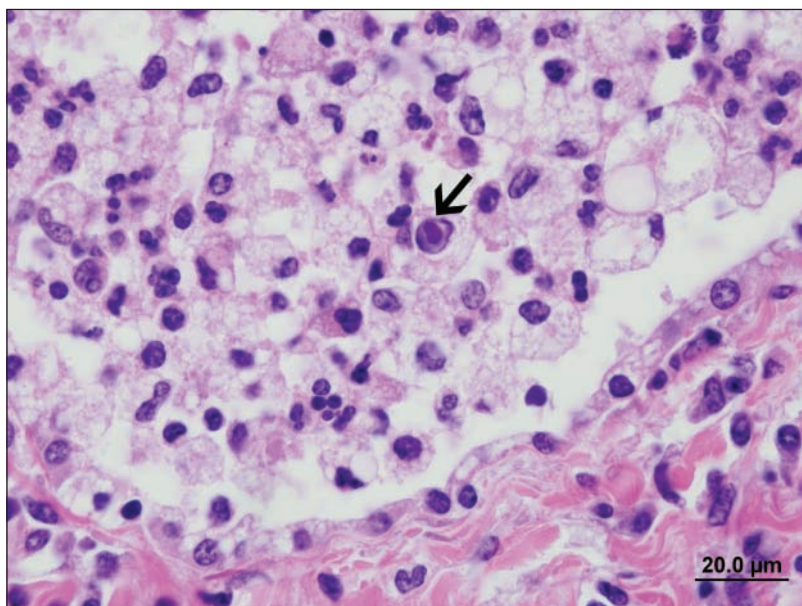


Figure 3—Photomicrograph of a section of lung obtained from the horse in Figure 1. Notice that the alveolus is filled with multiple foamy cells and neutrophils. There is a large, single, intranuclear, amphophilic inclusion body (arrow) in a foamy cell within the alveolus. Vacuolated hyperplastic type II cells line the alveolar wall. H&E stain; bar = 20 μ m.

and neutrophils. Alveoli were lined by foamy cuboidal epithelial cells and filled with moderate numbers of degenerate and viable neutrophils and large macrophages with abundant eosinophilic or foamy cytoplasm. Multinucleated giant cells with as many as 6 nuclei were common within alveoli. Large, oval, eosinophilic to amphophilic intranuclear inclusion bodies surrounded by a clear halo were occasionally observed in multiple large cells (either macrophages or epithelial cells) in the luminal exudate within alveoli (Figure 3). Bronchioles were lined by mildly hyperplastic epithelium with mildly increased numbers of goblet cells, compared with the number expected to be present in apparently normal bronchioles; the bronchioles were filled with the same inflammatory cells as were the alveoli. In samples of lung tissue, EHV-5 was detected via PCR assay; however, samples were negative for EHV-2.

Morphologic Diagnosis

Severe, nodular, interstitial pneumonia with fibrosis and intranuclear inclusion bodies.

Comments

The gross and microscopic lesions in the lungs of the horse of this report were characteristic of a newly defined pulmonary disease in horses—equine multinodular pulmonary fibrosis (EMPF). This disease is thought to be caused by EHV-5.^{1,2} Equine herpesvirus type 5, along with EHV-2, has been reclassified recently into the subfamily Gammaherpesvirinae.¹ Although the alphaherpesviruses that affect horses (EHV-1, EHV-4, and EHV-3) are etiologic agents in respiratory tract disease and abortion, EHV-2 and EHV-5 have not commonly been implicated as causes of morbidity in horses.³ In the 1970s, EHV-5 was identified in horses with respiratory tract disease,⁴ but its prevalence, genomic characteristics, and role as a major respiratory tract pathogen in horses have only recently been investigated.¹ By use of a PCR assay, EHV-5 can be detected in nasal swab samples and peripheral blood leukocytes obtained from healthy and ill adult horses and foals; in addition, viruses closely related to equine gammaherpesviruses have been detected in donkeys with similar disease.^{1,5-9} Recently, EHV-5 nucleic acid has been detected by use of PCR procedures in transtracheal wash and bronchoalveolar lavage fluid samples and in fresh or fixed lung tissue obtained from horses with EMPF, suggesting a relationship between the virus and the condition.^{1,2} Although EHV-5 does infect lymphocytes,¹⁰ its low prevalence in peripheral blood leukocytes (determined via PCR assay)^{7,8} suggests that lymphocytes are not the main reservoir of this virus.

Clinical diagnosis of EMPF can be difficult because clinical signs are typically nonspecific. In the horse of this report, the initial differential diagnoses included severe bacterial pneumonia with abscess formation, fungal pneumonia, primary or metastatic pulmonary neoplasia, and EMPF. The interpretation of diagnostic test results, such as findings of assessments of transtracheal wash and bronchoalveolar lavage fluid samples, can be complicated by secondary infections, so other data, such as radiographic and PCR assay findings, are important to the diagnosis of EMPF in horses.

Two distinct gross patterns of lesion distribution in lung tissue have been associated with EMPF. There is a disseminated nodular form, which is characterized by multifocal coalescing white fibrotic nodules that vary from < 1 to 5 cm in diameter; pulmonary parenchyma with a normal appearance is scant. A less common discrete nodular form may develop, which is characterized by large (8- to 10-cm-diameter) discrete nodules that are separated by visible areas of unaffected lung.² The horse of this report had the discrete nodular form of EMPF.

Although exposure of horses to EHV-5 is widespread, clinical signs of disease are uncommon. Nevertheless, the role of EHV-5 infection in the pathogenesis of EMPF has been strongly supported by clinicopathologic data.^{1,2} A similar disease in humans, called idiopathic pulmonary fibrosis, has been described. It is believed that idiopathic pulmonary fibrosis results from ongoing alveolar epithelial injury and abnormal wound repair that result in activation and proliferation of fibroblasts by profibrotic cytokines and subsequently a T helper cell type 2 (Th-2)-driven response.^{9,11} This disease has been widely investigated, with particular focus on how herpesviruses might be involved in the process. It has been proposed that herpesviruses, especially Epstein-Barr virus (a gammaherpesvirus), may be an important initial source of alveolar epithelial injury.¹¹ Many of the pathologic features of idiopathic pulmonary fibrosis in humans have been successfully reproduced in murine

models of pulmonary fibrosis that involve Th-2-biased interferon- γ R-/- mice infected with gammaherpesvirus MHV-68.¹¹ The role of herpesvirus infection in these models is to promote the vicious cycle of injury of the epithelium and alteration of the regenerative capacity of the lung.^{9,11} Further studies of these similar diseases in horses, humans, and mice are necessary to elucidate the exact mechanism of herpesvirus-induced lesion in this process.

References

1. Williams KJ, Maes R, Del Piero F, et al. Equine multinodular pulmonary fibrosis: a newly recognized herpesvirus-associated fibrotic lung disease. *Vet Pathol* 2007;44:849-862.
2. Wong DM, Belgrave RL, Williams KJ, et al. Multinodular pulmonary fibrosis in five horses. *J Am Vet Med Assoc* 2008;232:898-905.
3. Telford EAR, Studdert MJ, Agius CT, et al. Equine herpesviruses 2 and 5 are gamma-herpesviruses. *Virology* 1993;195:492-499.
4. Bell SA, Balasuriya UB, Gardner IA, et al. Temporal detection of equine herpesvirus infections of a cohort of mares and their foals. *Vet Microbiol* 2006;116:249-257.
5. Borchers K, Frolich K, Ludwig H. Detection of equine herpesvirus types 2 and 5 (EHV-2 and EHV-5) in Przewalski's wild horses. *Arch Virol* 1999;144:771-780.
6. Kleiboeker SB, Schommer SK, Johnson PJ, et al. Association of two newly recognized herpesviruses with interstitial pneumonia in donkeys (*Equus asinus*). *J Vet Diagn Invest* 2002;14:273-280.
7. Nordengrahn A, Merza M, Ros C, et al. Prevalence of equine herpesvirus types 2 and 5 in horse populations by using type-specific PCR assays. *Vet Res* 2002;33:251-259.
8. Torfason EG, Thorsteinsdóttir L, Thorsteinsdóttir S, et al. Study of equid herpesviruses 2 and 5 in Iceland with a type-specific polymerase chain reaction. *Res Vet Sci* 2008;85:605-611.
9. Doran P, Egan JJ. Herpesviruses: a cofactor in the pathogenesis of idiopathic pulmonary fibrosis? *Am J Physiol Lung Cell Mol Physiol* 2005;289:L709-L710.
10. Dunowska M, Holloway SA, Wilks CR, et al. Genomic variability of equine herpesvirus-5. *Arch Virol* 2000;145:1359-1371.
11. Mora AL, Woods CR, Garcia AP, et al. Lung infection with γ -herpesvirus induces progressive pulmonary fibrosis in Th-2 biased mice. *Am J Physiol Lung Cell Mol Physiol* 2005;289:L711-L721.