

Treatment of acute epistaxis secondary to guttural pouch mycosis with transarterial nitinol vascular occlusion plugs in three equids

Kira C. Delfs, DVM; Jan F. Hawkins, DVM, DACVS; Daniel F. Hogan, DVM, DACVIM

Case Description—2 horses and 1 pony were evaluated for right-sided (1 horse and the pony) and left-sided (1 horse) acute epistaxis of 1 day's to 1 month's duration.

Clinical Findings—Endoscopic examination of the 3 equids revealed that the hemorrhage originated from the right maxillary artery in 2 equids and from the left internal carotid artery in the third. Mycosis of the auditory tube diverticulum (guttural pouch) was detected in all 3 equids.

Treatment and Outcome—All 3 equids underwent surgery, and transarterial nitinol intravascular plugs were placed to occlude affected blood vessels. All equids survived for a long period (ie, a minimum of 1 to 2 years) and returned to their previous use. All had complete regression of clinical signs of guttural pouch mycosis without additional medical treatment.

Clinical Relevance—The use of transarterial nitinol intravascular plugs appeared to be an effective alternative to other techniques for the treatment of epistaxis secondary to guttural pouch mycosis, including transarterial occlusion devices such as embolization coils. (*J Am Vet Med Assoc* 2009;235:189–193)

A 284-kg (625-lb) 28-year-old female Pony of the Americas was admitted for evaluation of a 1-day history of right-sided epistaxis. Initial physical examination revealed that the pony was bright, alert, and responsive. The heart rate was 48 beats/min (reference range, 25 to 40 beats/min), respiratory rate was 40 breaths/min (reference range, 8 to 16 breaths/min), and rectal temperature was 38.3°C (101.1°F; reference range, 36.9° to 38.3°C [98.5° to 101.4°F]). The Hct was 27% (reference range, 35% to 45%), and serum total protein concentration was 6.0 g/dL (reference range, 5.5 to 7.0 g/dL). Dried blood was detected on the right nostril, but no active bleeding was evident.

An endoscopic examination of the upper respiratory tract was performed. Blood was detected exiting the opening of the right auditory tube diverticulum (guttural pouch). The endoscope was positioned into the right guttural pouch, and frank blood and blood clots were evident on the floor of the pouch. A fungal plaque was centered over the right maxillary artery. There was no apparent involvement of the internal carotid artery.

Treatment options were discussed with the owners, including maxillary artery occlusion with surgically placed Fogarty venous thrombectomy catheters and intravascular occlusion via placement of nitinol vascular plugs.^a The owners chose nitinol vascular plug placement. Prior to anesthesia, penicillin G potassium (22,000 U/kg [10,000 U/lb], IV, q 6 h), gentamicin sulfate (6.6 mg/kg [3 mg/lb], IV, q 24 h), and flunixin meglumine (1.1 mg/kg [0.5 mg/lb], IV, q 12 h) were administered to the pony. The pony was routinely anesthetized and positioned in left lateral recumbency. The

From the Department of Veterinary Clinical Sciences, School of Veterinary Medicine, Purdue University, West Lafayette, IN 47907. Address correspondence to Dr. Delfs.

ABBREVIATION

GPM Guttural pouch mycosis

head and cranial aspect of the neck were positioned on an acrylic table that allowed transmission of the fluoroscopic beam.

Fluoroscopic imaging^b was used to facilitate catheter manipulation and guide angiography. To ensure correct positioning of the vascular plug, a videoendoscope was inserted into the right guttural pouch prior to initiation of the angiogram. Following aseptic preparation of the cranial aspect of the neck over the right jugular vein, a 10-cm incision was made dorsal to the vein. The vein was retracted ventrally, and the omohyoideus muscle was incised to expose the common carotid artery. The common carotid artery was isolated with care to avoid injuring the vagosympathetic trunk and recurrent laryngeal nerve, and a 0.64-cm Penrose drain was positioned to retract the common carotid artery toward the incision. The common carotid artery was punctured with an 18-gauge vascular-access needle^c that had a 0.10-cm short wire guide, and the needle was used to insert a 7-F introducer and dilator set,^d leaving the introducer in place. The introducer included a hemostasis valve with a side port for injection.

An angiogram was performed by injecting 20 mL of contrast material^e rapidly through the transducer. The angiogram revealed a leak of contrast material from the right maxillary artery. A 4-F diagnostic catheter^e was inserted through a 75-cm, 5-F vascular sheath,^f and both were inserted through the 7-F vascular access sheath in the common carotid artery. The diagnostic catheter and flexible guide wire were advanced to the right maxillary artery at a point at which it made a sharp, 90° to

110° turn. Ideally, an artery that is bleeding should be occluded on the aspect of the hemorrhage site furthest from the heart as well as the aspect closest to the heart. However, it was difficult to maneuver the diagnostic catheter through the acute angle of the blood vessel, and endoscopy within the guttural pouch revealed that the catheter had disrupted the fungal lesion and the maxillary artery had begun to hemorrhage. Therefore, to obstruct anterograde (toward the heart) blood flow to the site of hemorrhage, a 10-mm vascular plug was deployed through the long 5-F vascular sheath within the maxillary artery (**Figure 1**). Endoscopically, the hemorrhage from the maxillary artery appeared to slow dramatically after 20 to 30 seconds. To prevent retrograde blood flow, the major palatine artery was occluded with a 6-F Fogarty thrombectomy catheter as described elsewhere.¹⁻³

After occlusion of the aspects of the maxillary hemorrhage site that were closest to and furthest from the heart, angiography was repeated to confirm complete occlusion of the right maxillary artery. The 7-F vascular sheath was removed, and the right carotid artery was closed by means of an interrupted pattern with 5-0 polyglactin 910. The subcutaneous tissue was closed by means of a simple continuous pattern with 2-0 polyglactin 910. The skin was closed with cutaneous stainless steel staples.⁸

Four days after surgery, the pony developed serosanguineous nasal discharge from the right nostril. Endoscopic examination revealed that the nasal discharge originated from lysis of the blood clot on the floor of the guttural pouch. The Fogarty catheter was removed from the right major palatine artery on the fifth day after surgery. Six days after surgery, the pony was discharged with no evidence of epistaxis. No episodes of hemorrhage were reported following discharge. When the pony was reexamined endoscopically 1 month after surgery, the fungal




Figure 1—Photograph of a nitinol intravascular plug used to treat acute epistaxis secondary to GPM in a horse.

plaque on the maxillary artery was no longer evident. At 2 years after the surgical procedure, the pony remained free of epistaxis or problems related to the surgical procedure.

A second equid, a 390-kg (860-lb) 8-year-old Paint mare, was admitted for evaluation of a 1-week history of intermittent right-sided epistaxis. At admission, the horse was bright, alert, and responsive. Heart and respiratory rates were high at 48 beats/min and 24 breaths/min, respectively; however, the rectal temperature was unremarkable (38.0°C [100.4°F]). Similar to the pony, the Hct was low (27%), but unlike the pony, the horse was hypoproteinemic (5.2 g of total protein/dL). Results of a coagulation profile did not indicate major abnormalities (prothrombin time, 11.7 seconds [reference range, 10.9 to 12.1 seconds]; partial thromboplastin time, 36.6 seconds [reference range, 40.1 to 50.1 seconds]). Dried blood was detected on the right nostril, but no active bleeding was observed.

An endoscopic examination of the upper respiratory tract was performed. Blood was visible exiting the opening of the right guttural pouch. The endoscope was advanced into the right guttural pouch, where frank blood and blood clots were detected. It could not be determined whether the right internal carotid or maxillary artery was the source of hemorrhage.

Treatment options were discussed with the owner as described for the pony, and a similar treatment approach was chosen. The horse underwent the same surgical procedure as did the pony. Intraoperative fluoroscopic angiography identified extravasation of contrast material from the right maxillary artery. Although the site of hemorrhage from the right maxillary artery was essentially the same as that in the pony, the diagnostic catheter and 5-F vascular sheath were able to traverse the acute angles of the maxillary artery so that vascular plugs could be positioned on the aspects of the site of arterial leakage that were furthest from and closest to the heart. Vascular occlusion was achieved by deploying 10-mm and 12-mm vascular plugs on the aspects of the hemorrhage site furthest from and closest to the heart, respectively (**Figure 2**). The common

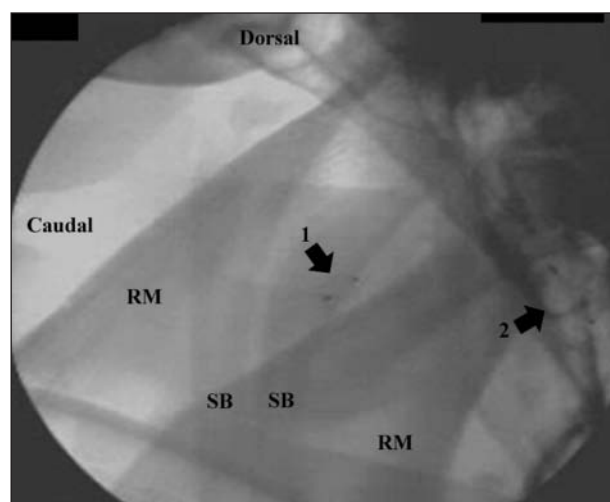


Figure 2—Image obtained during intraoperative fluoroscopic angiography in a horse with epistaxis secondary to GPM. Angiography revealed that the maxillary artery was the leaking blood vessel. Vascular occlusion was achieved by inserting transarterial vascular plugs on the aspects of the affected maxillary artery that were closest to the heart (arrow 1) and furthest from the heart (arrow 2). RM = Ramus of mandible. SB = Stylohyoid bone.

carotid artery and the incision were closed in the same manner as in the pony. Three days after surgery, the mare was discharged with no evidence of epistaxis. Three weeks after surgery, an endoscopic evaluation revealed that the fungal plaque had regressed to a small plaque over the right maxillary artery. One year after surgery, a follow-up telephone interview with the owner revealed that the horse had no additional episodes of epistaxis and had returned to its former use.

A third equid, a 435-kg (957-lb) 3-year-old Paint mare, was admitted for evaluation of a 1-month history of intermittent left-sided epistaxis. On the evening of admission, the horse had profuse bilateral epistaxis. At admission, the horse was bright, alert, and responsive. Similar to the other 2 equids, the horse was tachycardic (heart rate, 52 beats/min) and tachypneic (respiratory rate, 24 breaths/min); however, the horse was also normothermic (rectal temperature, 38.1°C [100.7°F]). Again, the Hct was low (17%), and the horse was hypoproteinemic (total protein concentration, 4.0 g/dL). Results of a coagulation profile did not indicate major abnormalities (prothrombin time, 11.7 seconds [reference range, 10.9 to 12.1 seconds]; partial thromboplastin time, 38.8 seconds [reference range, 40.1 to 50.1 seconds]). Dried blood was observed on the left nostril, but active bleeding was not evident.

An endoscopic examination was performed in this horse as described previously. Blood was detected exiting the opening of the left guttural pouch, and the endoscope was advanced into the left guttural pouch. Frank blood and blood clots were evident on the floor of the pouch. A fungal plaque was centered over the left internal carotid artery. Endoscopic examination of the right guttural pouch revealed no abnormalities. The historically reported bilateral epistaxis most likely originated from hemorrhage from the left internal carotid artery. There was no apparent involvement of the left external carotid artery or the left maxillary artery.

The decision was made to perform intravascular occlusion by use of the vascular plug, and the horse underwent the same procedure as the other 2 equids. Angiography revealed extravasation of contrast material from the left internal carotid artery. Vascular occlusion was achieved by inserting a 12-mm vascular plug at the aspects of the hemorrhage site that were furthest from and closest to the heart. The common carotid artery and the incision were closed as described for the other equids. Five days after surgery, the mare was discharged with no evidence of epistaxis. It had no additional episodes of epistaxis after surgery, and an endoscopic examination was not performed after hospital discharge. When interviewed by telephone 5 months after surgery, the owner reported that the horse had no additional episodes of epistaxis and had returned to its former use.

Discussion

Guttural pouch mycosis is caused by a fungal invasion into the mucosal lining of the guttural pouch, and *Aspergillus* spp are the most commonly involved fungi.^{2,4,5} Clinical signs, diagnosis, and treatment options for GPM have been described.^{1,6-8} The present report differs from the others in that a novel technique was used to occlude the arteries affected by the GPM. In equids with hem-

orrhage caused by GPM, the involved artery or arteries should be occluded to avoid exsanguination.⁹ To prevent hemorrhage from the affected artery, normograde and retrograde flow should be stopped.^{1,10} Ligation of only the aspect of the affected blood vessel closest to the heart does not eliminate retrograde blood flow from the cerebral arterial circle (circle of Willis).^{6,11-13}

Multiple techniques of arterial occlusion have been described, including ligation of the common carotid artery and its branches, Fogarty venous thrombectomy catheter placement, detachable balloon system placement, and transarterial coil embolization.¹⁴⁻¹⁷ Fogarty thrombectomy catheter techniques have been described for management of arterial hemorrhage from internal carotid, external carotid, and maxillary arteries.^{2,3,7} For many years, use of Fogarty thrombectomy catheters was considered the gold-standard method of arterial occlusion for equids with GPM. The use of Fogarty thrombectomy catheters requires catheterization of 1 or more arteries, depending on which blood vessel is involved.¹⁻³ An open approach to placement of catheters in affected artery or arteries is required. The catheters need to be buried under the skin or left exiting the skin or mucous membranes of the mouth. Because of this, some horses develop infections surrounding the catheter foreign body. Another disadvantage of Fogarty thrombectomy catheter placement is the possibility of inadvertent catheterization of anomalous blood vessels.^{18,19} Improper placement is possible because typically the catheters are positioned in the absence of intraoperative guidance from fluoroscopy or other types of intraoperative imaging.

To avoid complications associated with catheter placement and possible surgical removal of the catheters, an improved method for vascular occlusion was developed making use of polyester fiber-covered, stainless steel coils.^{14-17,h} With these coils, vascular occlusion takes place because the positively charged metal coils react with the negatively charged blood components to encourage agglutination and adherence with the coils; furthermore, the polyester fibers play a role in initiating thrombus formation. Similar to the method described in this report, coil placement is performed with fluoroscopic guidance. Multiple coils are positioned until vascular occlusion has occurred as determined via intraoperative angiography. In a study²⁰ of 31 horses with GPM treated with coil embolization, 84% of horses survived. Reported complications associated with coil embolization in horses include death secondary to incomplete resolution of the fungal plaque, blindness, and the potential for coil migration if the coil is not properly sized or deployed in the correct location.^{1,2,7,10} Embolization coils are used in humans for various vascular disorders. Complications of embolization coils in humans include coil migration, coil embolization of cerebral arterial circle, meningitis, and recannulation of the embolized artery or arteries.^{21,22} With the exception of the outcome reported for 1 horse,²³ vascular occlusion of an artery affected by GPM generally leads to resolution of the fungal plaque without additional medical treatment. Therefore, complete vascular occlusion of the affected artery is required for successful resolution of the fungal plaque.^{11,24}

Nitinol vascular occlusion plugs have been used to occlude various vascular abnormalities in humans and dogs.^{9,23,25,26} To our knowledge, use of the type of plug placed in the horses of the present study has not been reported. The vascular plug is a self-expanding, cylindrical device of nickel-titanium wire mesh secured on both ends with platinum marker bands (Figure 1). It is attached to a delivery cable and is flexible enough to be deployed through narrow catheters. The delivery cable allows for accurate positioning, deployment, and recapture of the plug. Once correct positioning is confirmed via fluoroscopy and angiography, the plug can be pushed from the delivery catheter and released by rotation of the cable in a counterclockwise fashion. If needed, the plug can be retrieved after it has been released.

The type of nitinol vascular plug described in this report is available in sizes ranging from 4 to 16 mm in diameter. Three of the 5 plugs placed in the 3 equids of this report were 12 mm in size, and 2 were 10 mm. Therefore, a 10-mm or 12-mm nitinol vascular plug appears to be adequate for vascular occlusion of internal carotid and maxillary arteries in a horse of typical size, but the appropriateness of the size should be confirmed via angiography prior to plug placement. Ideally, the diameter of the plug should be 130% to 150% of the diameter of the targeted blood vessel. Once an appropriately sized plug is deployed, it lodges in the blood vessel and the risk of migration or dislodgement from the blood vessel is extremely low. Therefore, in our opinion, the nitinol vascular plug can be delivered more precisely and with greater safety than embolization coils. This conclusion is supported by findings in humans in which large blood vessels can require occlusion.^{21–23}

Some physicians favor the use of nitinol vascular plugs versus embolization coils in humans to reduce the risk of migration of the embolic device from the location of interest. The nitinol vascular plug used in the equids of the present report is designed to block blood flow in a vessel, similar to a cork in a bottle. The nitinol vascular plug stops blood flow through a vessel, although not immediately because fibrin must accumulate on the wire mesh to complete the occlusion. In the pony in the present report, active bleeding from the affected artery was observed via endoscopy for up to 15 to 20 seconds after deployment of the plug. When the nitinol vascular plug is used in high-flow applications such as closure of a patent ductus arteriosus, it may take as long as 10 minutes to completely occlude the vessel.²³

The primary differences between vascular plugs and embolization coils can be summarized as follows. First, vascular plugs can be used to completely occlude an affected blood vessel with 1 plug on each side of the bleeding vessel, whereas multiple embolization coils are usually required for the same purpose. Second, vascular plugs are more easily retrieved than coils, particularly when multiple coils are used. Third, the nitinol vascular plug completely fills a blood vessel, whereas coils fill the lumen of the vessel with overlapping strands of wire and polyester fiber. Finally, appropriately sized, nitinol vascular plugs are unlikely to become dislodged because of the radial tension they exert on the vessel wall.

The cost to occlude a blood vessel with vascular plugs may be similar to the cost associated with embolization coils. Multiple embolization coils are usually required to effectively occlude a leaking blood vessel,^{14,20} whereas 1 vascular plug on the aspect closest to the heart and 1 on the aspect furthest from the heart side are sufficient. The cost of each plug is approximately \$300, and the cost of embolization coils ranges from approximately \$50 to \$100 each. The disadvantage of using transarterial nitinol vascular plugs for occlusion instead of surgical ligation or Fogarty catheters is the need for specialized equipment and the expertise of an interventional cardiologist or another individual familiar with interventional peripheral vascular techniques; these characteristics of vascular plug placement limit use of the technique to well-equipped hospitals or teaching hospitals. Specialized equipment and expertise are also required for embolization coils. Fluoroscopy and angiography are essential for accurate identification of blood vessels before occlusion to ensure vascular anomalies and aberrant blood vessels are not involved and for accurate placement of the vascular plug. The only complication we encountered with the use of nitinol vascular plugs was the inability to position the plug on the aspect furthest from the heart side of the maxillary artery defect in the pony because of the tortuous course of the maxillary artery. Veterinary surgeons should be aware of the possibility of a similar complication when lesions involving the maxillary artery are diagnosed. However, in most equids, hemorrhage attributable to GPM is caused by fungal erosion of an internal carotid artery, which has a larger diameter and a straighter course than the maxillary artery and therefore allows a more direct route for placement of the vascular plugs.

- a. Amplatzer nitinol-based vascular plug, AGA Medical Corp, Plymouth, Minn.
- b. Ziehm Exoscop 7000, Ziehm Imaging Inc, Riverside, Calif.
- c. Cook Medical, Bloomington, Ind.
- d. Introducer-dilator combination (RCF-7-38-J), Cook Medical, Bloomington, Ind.
- e. Ultravist contrast agent (iopromide), Bayer Health Care Pharmaceuticals, Leverkusen, Germany.
- f. Flexor sheath KCFW-5.0-35-55-RB-RAABE, Cook Medical, Bloomington, Ind.
- g. Proximate Plus MD 35W, Ethicon Inc, Somerville, NJ.
- h. Dacron, Dupont, Kingston, NC.

References

1. Cook WR. The clinical features of guttural pouch mycosis in the horse. *Vet Rec* 1968;83:336–345.
2. Greet TRC. Outcome of treatment in 35 cases of guttural pouch mycosis. *Equine Vet J* 1987;19:483–487.
3. Caron JP, Fretz PD, Bailey JV, et al. Balloon-tipped catheter arterial occlusion for prevention of hemorrhages caused by guttural pouch mycosis: 13 cases (1982–1985). *J Am Vet Med Assoc* 1987;191:345–349.
4. Smith KM, Barber SM. Guttural pouch hemorrhages associated with lesions of the maxillary artery in two horses. *Can Vet J* 1984;25:239–242.
5. Freeman DE, Ross MW, Donawick WJ, et al. Occlusion of the external carotid and maxillary arteries in the horse to prevent hemorrhage from guttural pouch mycosis. *Vet Surg* 1989; 18:39–47.
6. Edwards GB, Greet T. Disorders of the guttural pouches. Gut-

- tural pouch mycosis. In: *Equine respiratory medicine and surgery*. Philadelphia: WB Saunders Co, 2007;424–430.
7. Freeman DE, Donawick WJ. Occlusion of the internal carotid artery in the horse by means of a balloon-tipped catheter: evaluation of a method designed to prevent epistaxis caused by guttural pouch mycosis. *J Am Vet Med Assoc* 1980;176:232–235.
 8. Freeman DE, Donawick WJ. Occlusion of the internal carotid artery in the horse by means of a balloon-tipped catheter: clinical use of the method to prevent epistaxis caused by guttural pouch mycosis. *J Am Vet Med Assoc* 1980;176:236–240.
 9. Leveille R, Hardy J, Robertson JT, et al. Transarterial coil embolisation of the internal and external carotid and maxillary arteries for prevention of hemorrhages from guttural pouch mycosis in horses. *Vet Surg* 2000;29:389–397.
 10. Hardy J, Robertson JT, Wilkie DA. Ischemic optic neuropathy and blindness after arterial occlusion for treatment of guttural pouch mycosis in two horses. *J Am Vet Med Assoc* 1990;196:1631–1634.
 11. Church S, Wyn-Jones G, Park AH, et al. Treatment of guttural pouch mycosis. *Equine Vet J* 1986;18:362–365.
 12. McIlwraith CW. Surgical treatment of acute epistaxis associated with guttural pouch mycosis. *Vet Med Small Anim Clin* 1978;73:67–69.
 13. Owen RR, Ap R. Epistaxis prevented by ligation of the internal carotid artery in the guttural pouch. *Equine Vet J* 1974;6:143–149.
 14. Lane JG. The management of guttural pouch mycosis. *Equine Vet J* 1989;21:321–324.
 15. Cook WR, Campbell RSF, Dawson C. The pathology and aetiology of guttural pouch mycosis in the horse. *Vet Rec* 1968;83:422–428.
 16. Guillot J, Collobert C, Gueho E, et al. *Emericella nidulans* as an agent of guttural pouch mycosis in a horse. *J Med Vet Mycol* 1997;35:433–435.
 17. Kaufman SI, Martin LG, Zuckerman AM, et al. Peripheral transcatheter embolization with platinum microcoils. *Radiology* 1992;184:369–372.
 18. Partington BP, Partington CR, Biller DS, et al. Transvenous coil embolization for treatment of patent ductus venosus in a dog. *J Am Vet Med Assoc* 1993;202:281–284.
 19. Snaps FR, McEntee K, Saunders J, et al. Treatment of patent ductus arteriosus by placement of intravascular coils in a pup. *J Am Vet Med Assoc* 1995;207:724–725.
 20. Hardy J, Leveille R. Disease of the guttural pouch. *Vet Clin North Am Equine Pract* 2003;19:123–158.
 21. Ha CD, Calcagno D. Amplatzer Vascular Plug to occlude the internal iliac arteries in patients undergoing aortoiliac aneurysm repair. *J Vasc Surg* 2005;42:1058–1062.
 22. Rossi M, Rebonato A, Greco L, et al. A new device for vascular embolization: report on case of two pulmonary arteriovenous fistulas embolization using the amplatzer vascular plug. *Cardiovasc Intervent Radiol* 2006;29:902–906.
 23. Fischer G, Apostolopoulou S, Rammos S, et al. Transcatheter closure of coronary arterial fistulas using the new Amplatzer vascular plug. *Cardiol Young* 2007;17:283–287.
 24. Speirs VC, Harrison IW, van Veenendaal JC, et al. Is specific antifungal therapy necessary for the treatment of guttural pouch mycosis in horses? *Equine Vet J* 1995;27:151–152.
 25. Tabori NE, Love BA. Transcatheter occlusion of pulmonary arteriovenous malformations using the Amplatzer Vascular Plug II. *Catheter Cardiovasc Interv* 2008;71:940–943.
 26. Hogan DF, Green HW, Sanders RA. Transcatheter closure of patent ductus arteriosus in a dog with a peripheral vascular occlusion device. *J Vet Cardiol* 2006;8:139–142.