

# Chronic cor pulmonale secondary to pulmonary atherosclerosis in an African Grey parrot

Cassidy D. Sedacca, DVM; Terry W. Campbell, DVM, PhD; Janice M. Bright, MS, DVM, DACVIM; Brett T. Webb, DVM; Tawfik A. Aboellail, BVSc, MVSc, PhD, DACVP

**Case Description**—A 20-year-old sexually intact female African Grey parrot (*Psittacus erithacus*) was evaluated to determine the cause of lethargy, hyporexia, weight loss, and persistent ascites of 21 days' duration.

**Clinical Findings**—Physical examination revealed a markedly distended abdomen and systolic heart murmur. Thoracic radiography revealed cardiomegaly and hepatomegaly. Doppler echocardiography revealed severe eccentric and concentric hypertrophy of the right ventricle with systolic dysfunction, moderate regurgitation through the right atrioventricular valve, a substantial increase in estimated systolic pulmonary arterial pressure, hepatic venous congestion, and coelomic effusion. A clinical diagnosis of chronic cor pulmonale was established.

**Treatment and Outcome**—The parrot was initially stabilized by use of coelomocentesis. During the next month, the parrot was treated by administration of furosemide, hydrochlorothiazide, spironolactone, benazepril, and pimobendan. The parrot appeared to be responding well to treatment but was found dead in its cage 35 days following initial examination. Post-mortem examination revealed substantial atherosclerosis of the large pulmonary arteries, with lesions extending into the medium-size arteries. Pulmonary atherosclerosis was suspected as a cause of the severe pulmonary hypertension.

**Clinical Relevance**—Although atherosclerosis most commonly affects the systemic and coronary arteries of parrots, sclerotic changes within the pulmonary vasculature should be considered as a possible cause of pulmonary hypertension and as a differential diagnosis for right-sided congestive heart failure in psittacine species. (*J Am Vet Med Assoc* 2009;234:1055–1059)

A 20-year-old sexually intact female African Grey parrot (*Psittacus erithacus*) was examined at Colorado State University Veterinary Medical Center because of a history of lethargy, hyporexia, weight loss, and ascites of 21 days' duration. Multiple therapeutic coelomocenteses had been performed by the referring veterinarian to maintain the parrot's comfort during the 21 days prior to examination at our facility. Results of fluid analysis and microscopic examination of the coelomic fluid aspirated by the referring veterinarian were consistent with a modified transudate (2.6 g of total protein/L, 112 nucleated cells/ $\mu$ L, and < 100,000 RBCs/ $\mu$ L).

Initial examination at our veterinary medical center revealed that the parrot had a body weight of 0.49 kg (1.08 lb). The keel was moderately prominent, which was suggestive of atrophy of the pectoral muscles. The parrot had a markedly distended abdomen and was tachypneic and dyspneic. The respiratory effort became substantially worse when the parrot was tilted backward at an angle between 45° and complete dorsal recumbency. Cardiac auscultation revealed a regular rhythm and a grade 3/6 holosystolic murmur.

Results of a CBC were within the respective reference ranges; however, plasma biochemical analysis revealed se-

vere hypoproteinemia (1.0 g/dL; reference range,<sup>1</sup> 3.0 to 5.0 g/dL), hypoalbuminemia (0.4 g/dL; reference range, 1.57 to 3.23 g/dL), and hypocholesterolemia (64 mg/dL; reference range, 160 to 425 mg/dL); a mild decrease in aspartate aminotransferase activity (90 U/L; reference range, 100 to 350 U/L); and a mild increase in bile acids concentration (99  $\mu$ mol/L; reference range, 12 to 96  $\mu$ mol/L). Thoracic and abdominal radiography revealed severe generalized cardiomegaly (proportion for the width of the cardiac silhouette to width of the thorax, 70%; reference range,<sup>2</sup> 51% to 61%; proportion for the width of the cardiac silhouette to width of the coracoid, 745%; reference interval, 545% to 672%) and marked hepatomegaly. Although the pulmonary parenchyma appeared normal, the air sacs were minimally visible because of severe compression from coelomic fluid. There was a reduction in detail of the serosa in the coelomic cavity.

With the parrot standing in an upright position, Doppler ultrasonographic–echocardiographic evaluation<sup>a</sup> was performed to obtain horizontal and vertical views by use of a ventromedian approach described in another report.<sup>3</sup> Specific measurements and calculations for the horizontal view were determined and compared with reference values reported elsewhere.<sup>3</sup> A large amount of anechoic fluid was visible between the heart and liver, which was consistent with coelomic effusion. Marked distention of the hepatic venous system was also detected, which was suggestive of severe hepatic congestion (Figure 1). The right atrium (length, 8.4 mm, and width, 8.5 mm; respective reference ranges not established) was believed to be substantially dilated because it was larger in size than the left atrium (length, 6.0 mm, and width,

From the Department of Clinical Sciences (Sedacca, Campbell, Bright) and the Veterinary Diagnostic Laboratory and Department of Microbiology, Immunology, and Pathology (Webb, Aboellail), College of Veterinary Medicine and Biomedical Sciences, Colorado State University, Fort Collins, CO 80523.

The authors thank Dr. Krystan Grant for clinical assistance and June Boon for echocardiographic assistance.

Address correspondence to Dr. Sedacca.

8.1 mm; reference range [mean  $\pm$  SD],  $4.8 \pm 1.2$  mm and  $10.9 \pm 2.5$  mm, respectively). The right ventricular chamber was severely enlarged as well, with a marked increase in end-diastolic width (9.3 mm; reference range,  $4.8 \pm 1.1$  mm) and length (21.3 mm; reference range,  $11.5 \pm 1.9$  mm). The interventricular septum appeared to be skewed toward the left ventricle as a result of the severe enlargement of the right ventricular chamber. Thickness of the right ventricular wall (3.4 mm; reference range not established) exceeded that of the left ventricular wall (3.2 mm; reference range not established), and thickness of the interventricular septum (3.2 mm; reference range,  $2.5 \pm 0.3$  mm) was increased. Typically, the left ventricle of a psittacine is heavily walled

and approximately 2 to 3 times as thick as the right ventricular wall.<sup>4</sup> Thus, echocardiographic findings were indicative of mixed concentric and eccentric hypertrophy of the right ventricle.

Systolic right ventricular myocardial function was severely depressed as determined by an increase in end-systolic width (8.5 mm; reference range,  $2.8 \pm 0.9$  mm) and length (16.8 mm; reference range,  $9.2 \pm 1.4$  mm) and a marked reduction in fractional shortening (9.4%; reference range,  $39.6 \pm 11.4\%$ ). The left ventricle appeared mildly volume contracted (end-diastolic width, 7.3 mm, and end-diastolic length, 20.1 mm; reference range,  $9.1 \pm 1.5$  mm and  $23.9 \pm 1.9$  mm, respectively), and left ventricular systolic function (end-systolic width, 3.1 mm; end-systolic length, 17.7 mm; and fractional shortening, 57.2%; reference range,  $7.0 \pm 1.1$  mm,  $22.2 \pm 1.9$  mm, and  $23.1 \pm 4.6\%$ , respectively) was considered normal.

Color Doppler echocardiography revealed moderately severe insufficiency of the right atrioventricular valve, with a regurgitant jet that was subjectively assessed to occupy

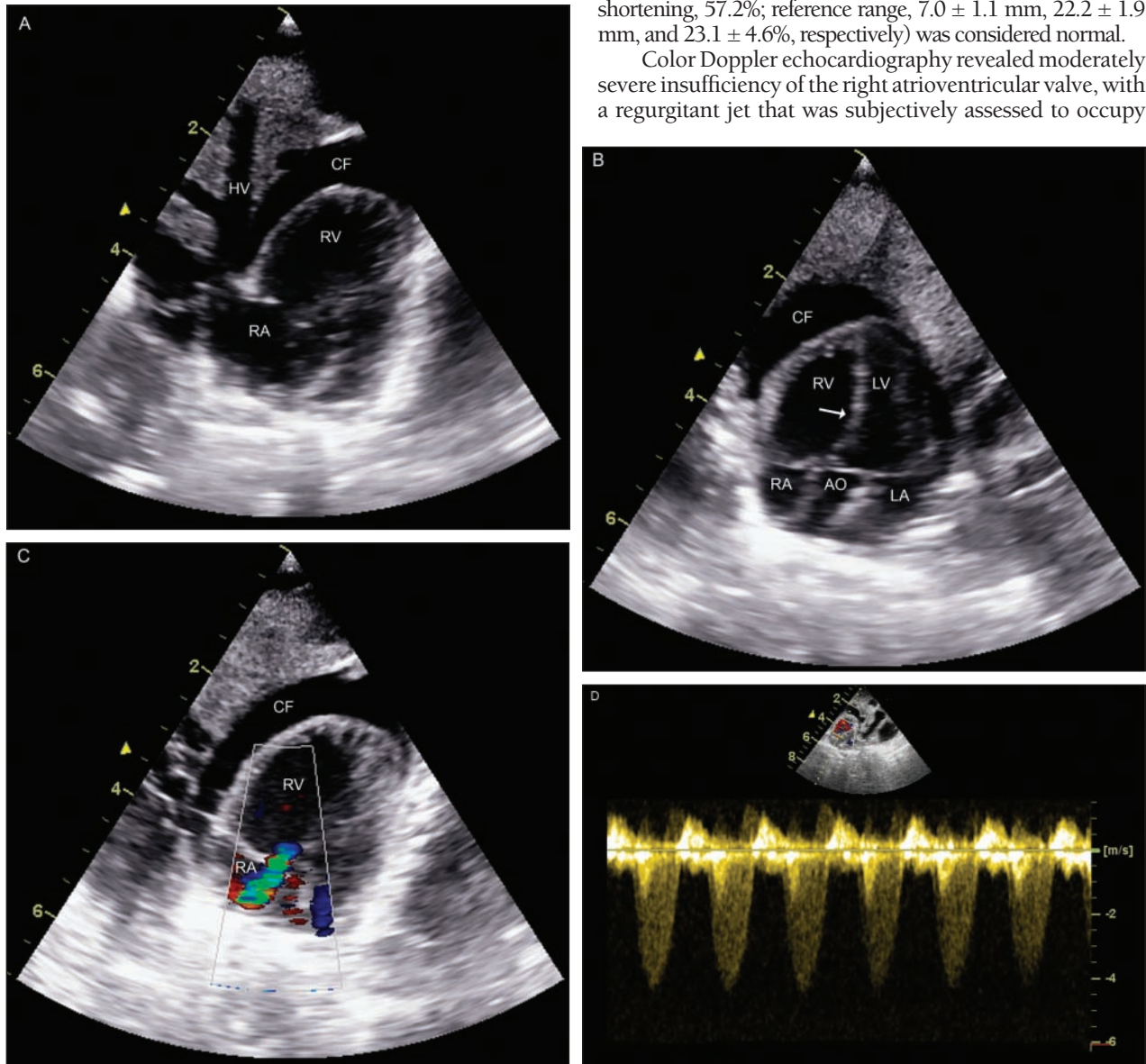


Figure 1—Horizontal echocardiographic views obtained by use of a ventromedian transducer position in an African Grey parrot with lethargy, hyporexia, weight loss, and persistent ascites. A—Notice the severe hepatic venous distention. The large volume of anechoic fluid between the heart and liver represents coelomic effusion. B—Notice the hypertrophy of the right ventricular wall and the substantial enlargement of the right ventricle and right atrium. The interventricular septum (arrow) is skewed toward the left ventricle as a result of the severe enlargement of the right ventricular chamber. C—Color Doppler echocardiographic image of blood flow through the right atrioventricular valve during systole. Notice the moderately severe regurgitation (blue and green areas originating from the valve and entering the right atrium). D—Continuous-wave spectral Doppler echocardiographic image of regurgitant blood flow through the right atrioventricular valve with a peak instantaneous velocity during systole of  $> 4$  m/s. Scale for the echocardiographic images in panels A, B, and C represents the number of centimeters. AO = Aortic root. CF = Coelomic fluid. HV = Hepatic vein. LA = Left atrium. LV = Left ventricle. RA = Right atrium. RV = Right ventricle.



approximately a third of the right atrial area (Figure 1). By use of the simplified Bernoulli equation,<sup>5</sup> peak velocity of the regurgitant jet through the right atrioventricular valve measured with continuous-wave Doppler echocardiography (4.5 m/s) predicted that the systolic right ventricular pressure was 80.5 mm Hg greater than the right atrial pressure. Absence of pulmonary valve stenosis or obstruction of the right ventricular outflow tract was concluded on the basis of a lack of structural abnormalities because accurate measurements of outflow tract velocity could not be obtained. Because the right atrium and hepatic veins were severely dilated and there was coelomic effusion, the mean right atrial pressure was assumed to be increased to at least 10 mm Hg. Consequently, the systolic pulmonary arterial pressure was estimated by use of Doppler echocardiography to be at least 90 mm Hg. The clinical and diagnostic findings supported a diagnosis of right-sided congestive heart failure secondary to pulmonary hypertension.

Coelomocentesis was performed to improve respiratory function by providing more room for expansion of the air sacs. Clinicians were careful to remove as little fluid as possible to provide patient comfort while minimizing worsening of the hypoproteinemia. After successful stabilization, the parrot was discharged to the owner later the same day with instructions to administer several cardiac medications, including furosemide (1 mg/kg [0.45 mg/lb], PO, q 12 h), benazepril (0.5 mg/kg [0.23 mg/lb], PO, q 24 h), and pimobendan (0.25 mg/kg [0.114 mg/lb], PO, q 12 h). It was also recommended that the parrot be fed a high-protein diet.

One week later, the parrot was returned to our veterinary medical center for reevaluation. The owner reported that the parrot was doing better and had improvements in attitude and appetite. Although less abdominal distention was evident during physical examination and the respiratory rate and effort had improved, the keel appeared more prominent, which suggested additional muscle atrophy. Renal function remained normal, as estimated on the basis of uric acid and phosphorus concentrations. Although the amount of coelomic fluid was subjectively assessed as being reduced on an echocardiogram, there was still a substantial amount of effusion. The combination diuretic spironolactone-hydrochlorothiazide (1 mg/kg, PO, q 12 h) was added to the medications administered to the parrot.

Although reportedly doing well on the prescribed cardiac medications, the parrot was found dead in its cage by the owner 35 days after initial examination at our veterinary medical center. Necropsy revealed that the coelomic cavity contained approximately 10 mL of serosanguineous fluid with mild hydropericardium and pericardial thickening. The heart had a globoid appearance with marked dilatation of the right ventricle. The ratio of the thickness of the right ventricular free wall to thickness of the left ventricular free wall was approximately 1:1. Gross examination of the ascending aorta and main pulmonary artery revealed diffuse and irregular thickening with lumens that were variably narrowed. The liver was diffusely pale gray in color but of normal consistency.

Histologic examination of the pulmonary vasculature revealed circumferential expansion of the tunica media and subintimal layers of the large pulmonary arteries attributable to multifocal scattered islands of hyaline cartilage suspended in amphophilic to basophilic ground substance (Figure 2). The resultant thickening of the tunica media and subintima substantially narrowed the vessel

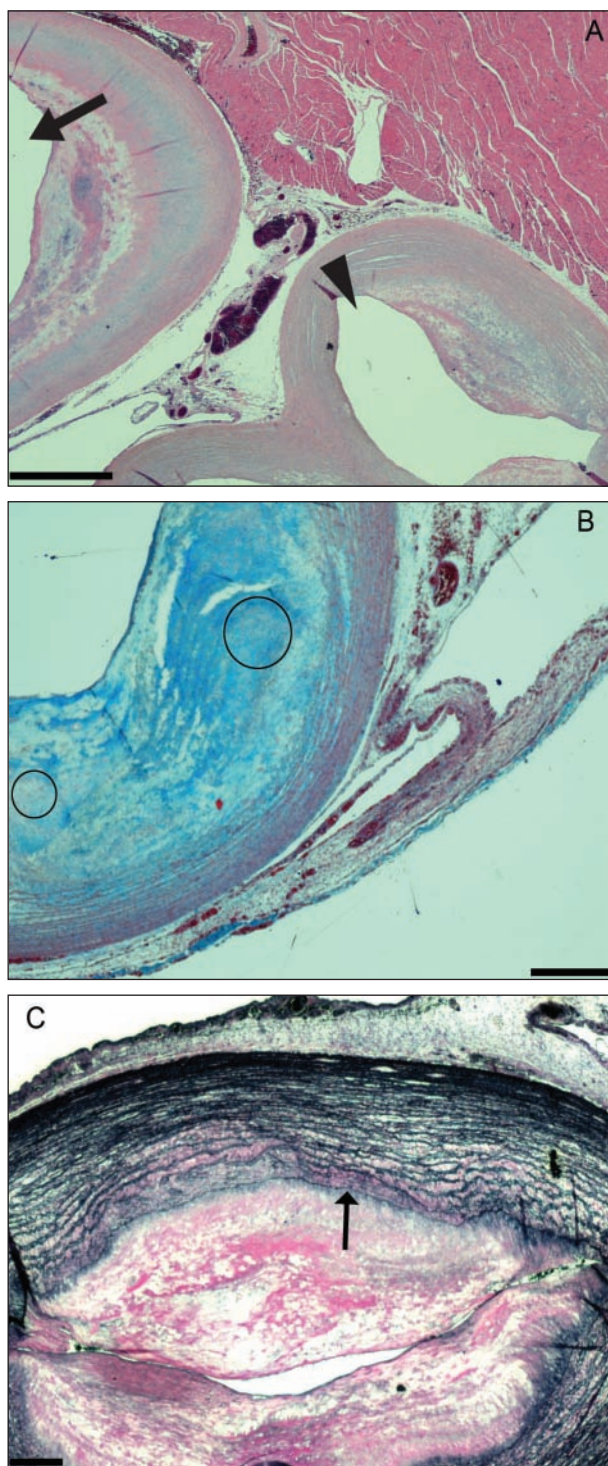


Figure 2—Photomicrographs of tissue sections obtained from the pulmonary vasculature of the African Grey parrot in Figure 1. A—Section at the base of the heart that reveals the aorta (arrow) and main pulmonary artery (arrowhead). Notice the narrowing of the lumen as a result of marked thickening of the subintima and tunica media. H&E stain; bar = 960  $\mu$ m. B—Section of a large pulmonary artery with extensive subintimal islands of hyaline cartilage (circles) embedded in a homogenous to finely fibrillar collagenous matrix (chondroid metaplasia). Masson-trichrome stain; bar = 400  $\mu$ m. C—Section of a pulmonary artery with irregularity of the internal elastic lamina (arrow), substantial thickening of the subintima, and marked narrowing of the lumen. Verhoeff-van Gieson stain; bar = 360  $\mu$ m.

lumens. Admixed multifocally within the subintimal layer were aggregates of acicular clefts, which was consistent with cholesterol clefts and accumulations of eosinophilic edema fluid. Endothelial cells were vacuolated with radial orientation of their nuclei into the lumen. Use of Verhoeff-van Gieson stain revealed multifocal scarcity to a total lack of the internal elastic lamina, with thin, irregular medial elastin fibers. Medium-size pulmonary arteries within the lungs were similarly affected. Within sections of the heart, there was multifocal epicardial fibrosis with varying degrees of subepicardial interstitial fibrosis. Adjacent to areas of fibrosis were numerous ectatic lymphatic vessels. Cardiac myocytes within affected areas were moderately reduced in cross-sectional diameter, vacuolated, or both. In some sections of liver, the fibrous perivascular capsule (ie, Glisson's capsule) was thickened as a result of organized fibrin. There was moderate to marked congestion of hepatic sinusoids and portal vessels with multifocal, randomly arranged aggregates of macrophages laden with coarse granules that had positive results when stained with Prussian blue dye (hemosiderin). Hepatocytes contained a fine dusting of similar granules within their cytoplasm.

## Discussion

The clinical, echocardiographic, and necropsy findings of the African Grey parrot described here were consistent with chronic cor pulmonale, characterized by regurgitation through the right atrioventricular valve, right ventricular systolic dysfunction, and right-sided congestive heart failure secondary to pulmonary atherosclerosis. Although pulmonary arterial pressures have not been established for clinically normal birds, an estimated pulmonary systolic pressure of at least 90 mm Hg identified in this parrot would be considered severely elevated in humans and other domestic animals in which reference values have been established. Although the underlying cause for the pulmonary hypertension could not be determined with certainty, pulmonary hypertension secondary to severe pulmonary atherosclerosis was likely. The histopathologic changes identified throughout the large- and medium-size pulmonary arteries suggested that  $\geq 50\%$  of the diameter of the arteries was compromised. Changes in the pulmonary arteries associated with the atherosclerotic process can theoretically result in pulmonary hypertension by increasing vascular resistance and reducing vascular compliance. Atherosclerosis reduces the total cross-sectional area of the pulmonary vasculature and also increases the impedance of blood flow through the pulmonary circulation. Furthermore, vascular endothelial injury, inflammation, and platelet activation secondary to the atherosclerotic process can release and activate endothelin, serotonin, and other vasoactive substances that can further increase pulmonary vascular resistance.<sup>6</sup>

Atherosclerosis is 1 type of arteriosclerosis, which is the general term for thickened and hardened arteries. Atherosclerosis is a disease process that results when the influx and deposition of cholesterol in the artery wall exceed the egress of cholesterol.<sup>7</sup> A chronic inflammatory process, atherosclerosis results in plaque formation (deposition of fatty substances, cholesterol,

cellular waste products, calcium, and fibrous connective tissue) within the intima of the arterial wall. As a result, the wall of the artery thickens, which decreases the luminal diameter and obstructs blood flow.<sup>8</sup>

Atherosclerosis is common among birds, especially within the family Psittaciformes, with Amazon parrots (*Amazona* spp) and African Grey parrots (*Psittacus* spp) being most susceptible.<sup>9</sup> The incidence of atherosclerosis in African Grey parrots has been reported to be as high as 92.4%.<sup>10</sup> Atherosclerosis has been described in the central portion of the systemic circulation in parrots. The thoracic portion of the aorta, brachiocephalic arteries, and coronary arteries are the most frequently and severely affected.<sup>11-13</sup> Although much less common, the main pulmonary artery and smaller pulmonary arteries can also be affected.<sup>11,13</sup>

Parrots rarely have clinical signs of atherosclerosis, and its diagnosis is often made during postmortem examinations. Although rare, antemortem clinical signs usually reflect reduced perfusion of the CNS (ie, signs of neurologic dysfunction) or left-sided heart failure.<sup>11</sup> However, to the authors' knowledge, no reports exist that describe atherosclerosis as a cause of right-sided congestive heart failure in an avian species. Although a postmortem study<sup>13</sup> characterizing cardiac disease in 26 psittacine birds describes right-sided congestive heart failure secondary to cor pulmonale in 2 birds, both had severe pneumonia attributed to *Aspergillus* spp infection. All other birds with right-sided congestive heart failure had primary cardiac pathologic changes without pulmonary lesions.

The anatomy of the avian heart and lungs may predispose birds to right-sided cardiac failure secondary to pulmonary hypertension. In contrast to the lungs of mammals, the lungs of birds are rigid and less compliant, perhaps contributing to more rapid development of pulmonary hypertension.<sup>4</sup> Furthermore, the right atrioventricular valve in birds consists of a simple muscular flap devoid of chordae tendinae.<sup>4</sup> As a result of its anatomic structure, the right atrioventricular flap is believed to malfunction easily in response to a sustained pressure overload (ie, pulmonary hypertension), which predisposes to right-sided congestive heart failure.<sup>4,13</sup> Consequently, right-sided cardiac failure is more common than left-sided failure in psittacine birds.<sup>13</sup>

Right-sided congestive heart failure has been described in case reports of birds (a Blue-fronted Amazon parrot [*Amazona aestiva*]<sup>14</sup> and a Yellow-crowned Amazon parrot [*Amazona ochrocephala*]<sup>15</sup>). Grossly, the hearts of both birds were similar in appearance to that of the African Grey parrot described here. The underlying cause of cardiac failure in the Blue-fronted Amazon parrot was believed to be a chronic (possibly congenital) fissure in the muscular portion of the right atrioventricular valve.<sup>14</sup> Interestingly, focal sclerotic changes identified within the lungs of the Blue-fronted Amazon parrot were speculated to have exacerbated the right-sided heart failure. However, no measurements or estimates of pulmonary arterial pressures were reported. The cause of cardiac failure in the Yellow-crowned Amazon parrot was unknown.<sup>15</sup> No gross or histologic abnormalities of the right atrioventricular valve or large pulmonary vessels were found.



The specific goals of cardiac treatment in the African Grey parrot reported here were to decrease right atrial and right ventricular filling pressures through the use of diuretics and venodilation and to improve right-sided cardiac output by increasing right ventricular contractility and decreasing right ventricular afterload (ie, pulmonary arterial pressure). For these reasons, the phosphodiesterase-III inhibitor pimobendan was used for both its positive inotropic effect on the right ventricular myocardium and its smooth muscle-relaxing effects within the pulmonary arterial vasculature. Theoretically, these benefits increase right ventricular stroke volume, improve pulmonary blood flow, and indirectly reduce right ventricular filling pressures. Aggressive treatment with diuretics (furosemide, hydrochlorothiazide, and spironolactone) was used to reduce right-sided preload, thereby decreasing hepatic venous congestion and coelomic fluid accumulation. Inhibition of angiotensin-converting enzyme by use of benazepril was also instituted to counteract the deleterious effects of the renin-angiotensin-aldosterone system, which was assumed to be activated as a result of right-sided heart failure. Systemic effects of the renin-angiotensin-aldosterone system were antagonized through reduction of the sodium concentration and retention of water by inhibition of aldosterone secretion and through reduction of angiotensin II-induced venous and arteriolar vasoconstriction.

It is important to mention that the specific goals for management of heart failure and use of the pharmacologic agents in this African Grey parrot were adapted from treatment of nonavian species with heart failure. Beneficial effects have been reported in humans and several other mammalian species and consequently were only speculative in the parrot described here. Pharmacokinetics, pharmacodynamics, efficacy, and safety margins of the specific agents used have not been established in avian species. Case reports<sup>15-19</sup> have described treatment of birds with cardiac failure by use of a variety of drugs, including digoxin, enalapril, and furosemide. However, the actual efficacy and pharmacokinetics of these agents in birds are not known, and doses are extrapolated and empirical.

The information reported here described pulmonary atherosclerosis in an African Grey parrot that resulted in chronic cor pulmonale. Cardiac disease in captive birds is currently believed to be more common than previously suspected,<sup>4,15,20</sup> with right-sided heart failure most frequently recognized.<sup>13</sup> Although atherosclerosis usually affects the systemic and coronary arteries of parrots, there can be sclerotic changes within the pulmonary vasculature that may result in an increase in pulmonary arterial pressure as vascular resistance increases and compliance decreases. For this reason, pulmonary atherosclerosis and resultant pulmonary ar-

terial hypertension should be considered as a differential diagnosis for right-sided congestive heart failure in psittacine species.

- 
- a. GE Vivid 7 Dimension 10s multifrequency transducer, GE Healthcare, Fairfield, Conn.
- 

## References

1. Pollock C, Carpenter JW, Antinoff N. Birds. In: Carpenter JW, ed. *Exotic animal formulary*. 3rd ed. St Louis: Elsevier Saunders, 2005;264.
2. Straub J, Pees M, Krautwald-Junghanns M-E. Measurement of the cardiac silhouette in psittacines. *J Am Vet Med Assoc* 2002;221:76-79.
3. Pees M, Straub J, Krautwald-Junghanns M-E. Echocardiographic examinations of 60 African grey parrots and 30 other psittacine birds. *Vet Rec* 2004;155:73-76.
4. Krautwald-Junghanns M-E, Braun S, Pees M, et al. Research on the anatomy and pathology of the psittacine heart. *J Avian Med Surg* 2004;18:2-11.
5. Weyman AE, Griffin BP. Principles of flow. In: Weyman AE, ed. *Principals and practice of echocardiography*. 2nd ed. Philadelphia: Lea & Febiger, 1994;184-200.
6. Chin KM, Rubin LJ. Pulmonary arterial hypertension. *J Am Coll Cardiol* 2008;51:1527-1538.
7. Mahley RW. Development of accelerated atherosclerosis: concepts derived from cell biology and animal model studies. *Arch Pathol Lab Med* 1983;107:393-399.
8. Berliner JA, Navab M, Fogelman AM, et al. Atherosclerosis: basic mechanisms, oxidation, inflammation, and genesis. *Circulation* 1995;91:2488-2496.
9. Bavelaar FJ, Beynen AC. Atherosclerosis in parrots. A review. *Vet Q* 2004;26:50-60.
10. Bavelaar FJ, Beynen AC. Severity of atherosclerosis in parrots in relation to the intake of  $\alpha$ -linolenic acid. *Avian Dis* 2003;47:566-577.
11. Johnson JH, Phalen DN, Kondik VH, et al. Atherosclerosis in psittacine birds, in *Proceedings*. 13th Annu Conf Assoc Avian Vet 1992;150-153.
12. Phalen DN, Hays HB, Filippich LJ, et al. Heart failure in a macaw with atherosclerosis of the aorta and brachiocephalic arteries. *J Am Vet Med Assoc* 1996;209:1435-1440.
13. Oglesbee BL, Oglesbee MJ. Results of postmortem examination of psittacine birds with cardiac disease: 26 cases (1991-1995). *J Am Vet Med Assoc* 1998;212:1737-1742.
14. Pees M, Straub J, Krautwald-Junghanns M-E. Insufficiency of the muscular atrioventricular valve in the heart of a Blue-fronted Amazon (*Amazona aestiva aestiva*). *Vet Rec* 2001;148:540-543.
15. Pees M, Schmidt V, Coles B, et al. Diagnosis and long-term therapy of right-sided heart failure in a Yellow-crowned Amazon (*Amazona ochrocephala*). *Vet Rec* 2006;158:445-447.
16. Wilson RC, Zenoble RD, Horton CR, et al. Single dose digoxin pharmacokinetics in quaker conure. *J Zoo Wildl Med* 1989;20:432-434.
17. Rosenthal K, Stamoulis M. Congestive heart failure due to mitral regurgitation in an Indian hill mynah bird, in *Proceedings*. 13th Annu Conf Assoc Avian Vet 1992;171-173.
18. Hamlin RL, Stalnaker PS. Basis for use of digoxin in small birds. *J Vet Pharmacol Ther* 1987;10:354-356.
19. Straub J, Pees M, Enders F, et al. Pericardiocentesis and the use of enalapril in a Fischer's lovebird. *Vet Rec* 2003;152:24-26.
20. Straub J, Pees M, Krautwald-Junghanns M-E. Heart diseases in birds: rare or just not diagnosed?, in *Proceedings*. 21st Annu Conf Assoc Avian Vet 2000;285-289.