



# What Is Your Diagnosis?

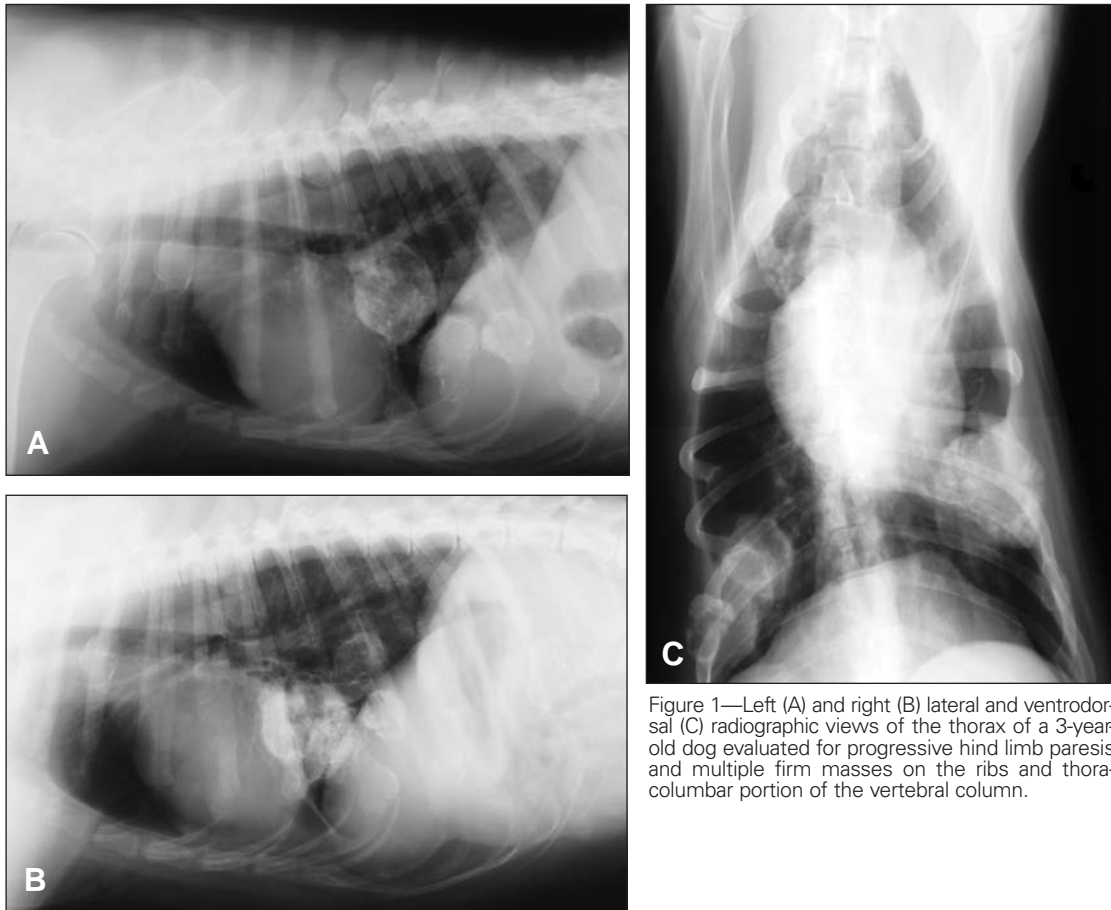

Figure 1—Left (A) and right (B) lateral and ventrodorsal (C) radiographic views of the thorax of a 3-year-old dog evaluated for progressive hind limb paresis and multiple firm masses on the ribs and thoracolumbar portion of the vertebral column.

## History

A 3-year-old sexually intact male Golden Retriever was evaluated for mild bilateral hind limb ataxia of 2 years' duration that had become worse during the 3 weeks prior to evaluation and multiple firm masses over the thorax and vertebral column. On physical examination, the dog was normothermic. Abnormal findings detected during neurologic examination included ataxia, conscious proprioceptive deficits, and hyper-reflexive to normal withdrawal and patellar reflexes in both hind limbs. Hyperesthesia was detected during palpation of the thoracic and lumbar portions of the vertebral column. Neuroanatomic lesion localization was compatible with a T3 through L3 myelopathy. No clinically important abnormalities were detected on CBC and serum biochemical analyses. Radiographs of the thorax were obtained (Figure 1).

Determine whether additional imaging studies are required, or make your diagnosis from Figure 1—then turn the page ▶

This report was submitted by Zachary H. Ricker, DVM; Arathi Vinayak, DVM; and Sharon C. Kerwin, DVM, MS, DACVS; from the Department of Small Animal Clinical Sciences, College of Veterinary Medicine and Biomedical Sciences, Texas A&M University, College Station, TX 77843. Dr. Ricker's present address is Department of Small Animal Clinical Sciences, Boren Veterinary Medical Teaching Hospital, Oklahoma State University, Stillwater, OK 74078.  
Address correspondence to Dr. Ricker.

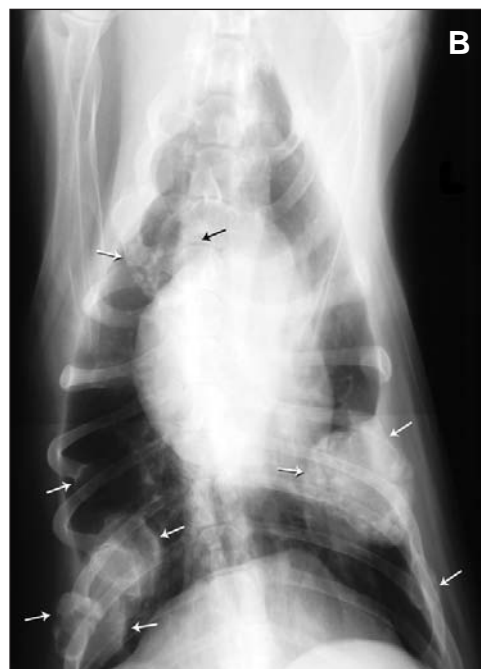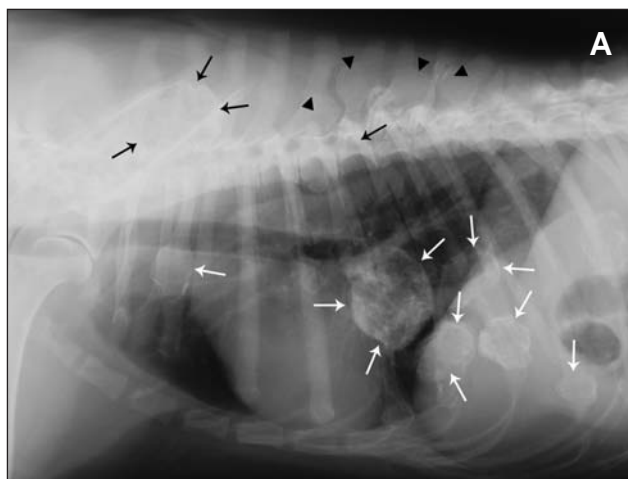


Figure 2—Same left lateral (A) and ventrodorsal (B) radiographic views as in Figure 1. Notice expansile osseous lesions (white arrows) originating from the sixth, seventh, and eighth ribs on the left side and the third, sixth, seventh, eighth, and ninth ribs on the right side of the thorax. A large lesion is evident at the level of the spinous processes at T2-T3, and a small lesion is evident at T7 (black arrows). Additional lesions are evident at the fifth, sixth, eighth, and ninth thoracic spinous processes (arrowheads).

## Radiographic Findings and Interpretation

Multiple expansile osseous lesions ranging in size from 3 to 5 cm are evident on multiple ribs (Figure 2). Additional expansile lesions are evident on the spinous processes of the thoracic vertebrae with the largest lesion seen at the level of the second and third thoracic vertebrae. Radiographic findings are compatible with a diagnosis of multiple cartilaginous exostoses (MCE).

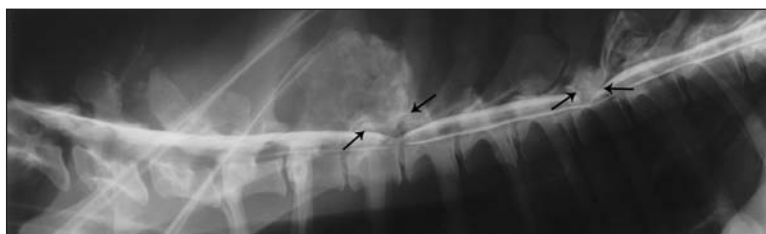

Figure 3—Lateral myelographic view of the thoracic portion of the vertebral column of the dog in Figure 1. Excessive osseous proliferation of the spinous processes with subsequent dorsal compression of the spinal cord is evident at T3-T4 and T7 (arrows).

## Comments

Multiple cartilaginous exostoses is a benign proliferative bone and cartilage disease that is seen more commonly in skeletally immature animals with growth typically stopping with skeletal maturation.<sup>1</sup> Growth after maturity suggests neoplastic transformation. Bones that develop by endochondral ossification are most often affected, and multiple bone involvement is common. Dogs may have a familial tendency for MCE; however, no breed or sex predilections have been identified.<sup>1</sup> Displacement of chondrocytes from the physis, creating a physis-like structure perpendicular to the long axis of the bone, has been implicated in the etiopathogenesis of MCE; however, the exact mechanism is not known.<sup>1</sup>

Clinical signs are caused by anatomic malformations, disfigurement, and compression of surrounding structures. Neurologic abnormalities are caused by proliferation of bony tissue causing compression of neural structures. Diagnosis is dependent on radiography of the entire skeleton and biopsy of lesions; however, the radiographic appearance of circumscribed, benign-appearing exostosis on multiple bones is pathognomonic for this unusual condition.<sup>1</sup> In the dog of this report, results of myelography of the thoracic and lumbar portions of the vertebral column confirmed spinal cord compression at 2 thoracic sites from osseous proliferation associated with the spinous process (Figure 3).

Back-scattered scanning electron microscopy of biopsy specimens has recently been described as aiding in the histologic diagnosis of MCE<sup>2</sup>; the centripetal calcification pattern, composition, and maturity of the trabeculae can only be distinguished by this technique.<sup>2</sup>

Treatment in dogs with subclinical disease is not necessary because the disease is usually self-limiting after skeletal maturity. Radiographic monitoring is recommended because malignant transformation to chondrosarcoma or osteosarcoma has been reported.<sup>1</sup> In dogs developing clinical disease, excision or decompression is indicated. The prognosis for severely affected or clinically affected growing dogs is guarded to poor. The prognosis has been reported as favorable in skeletally mature dogs with subclinical disease without evidence of neoplastic transformation.<sup>3</sup>

Because of the guarded to poor prognosis for the dog in this report, the owner chose to have the dog euthanized. Necropsy and histologic examination of lesions confirmed a diagnosis of MCE.

1. Pool RR, Thompson KG. Tumors of bones. In: Meuten DJ, ed. *Tumors in domestic animals*. 4th ed. Ames, Iowa: Iowa State Press, 2002;245-317.

2. Franch J, Font J, Ramis A, et al. Multiple cartilaginous exostoses in a Golden Retriever cross-bred puppy. *Vet Comp Orthop Traumatol* 2005;18:189-193.

3. Gambardella PC, Osborne CA, Stevens JB. Multiple cartilaginous exostoses in the dog. *J Am Vet Med Assoc* 1975;166:761-768.