



# What Is Your Diagnosis?

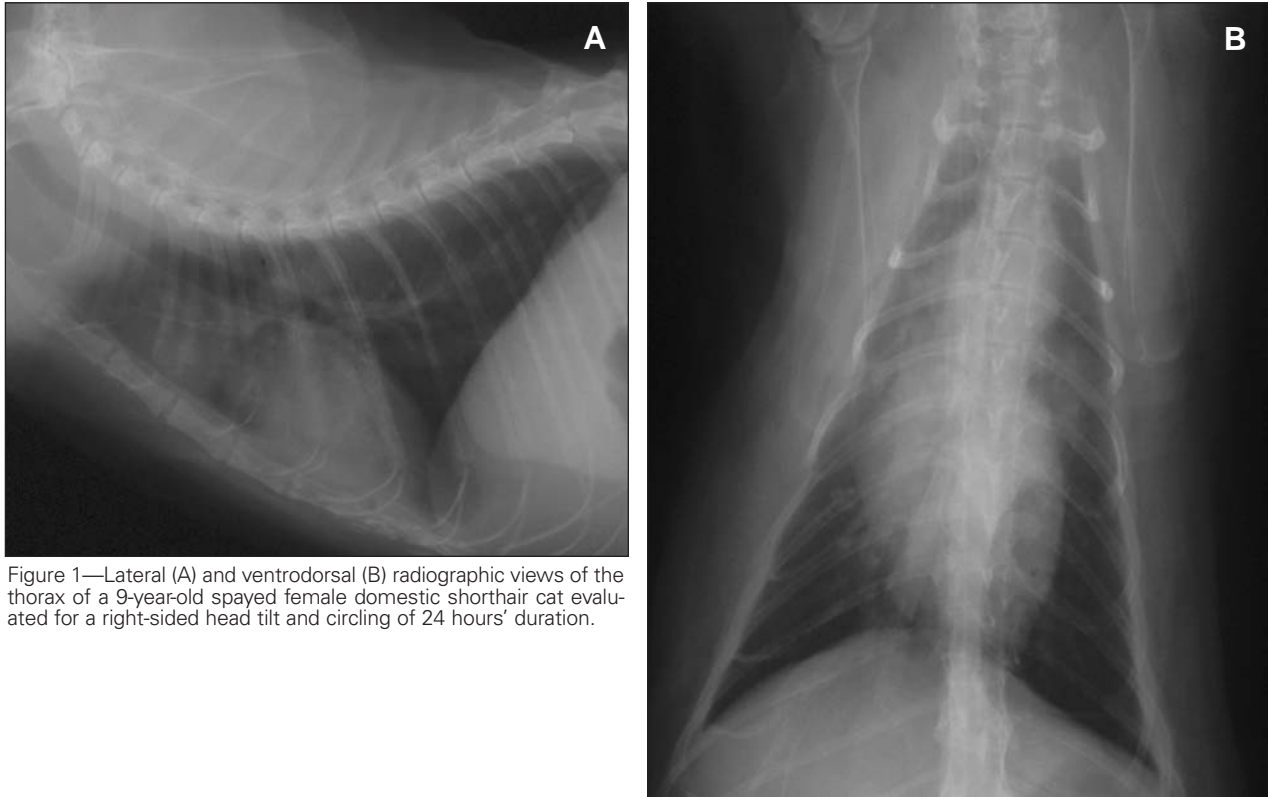


Figure 1—Lateral (A) and ventrodorsal (B) radiographic views of the thorax of a 9-year-old spayed female domestic shorthair cat evaluated for a right-sided head tilt and circling of 24 hours' duration.

## History

A 9-year-old spayed female domestic shorthair cat was evaluated for a right-sided head tilt and circling of 24 hours' duration. The cat had a 6-year history of intermittent otitis externa, which had been treated with prednisone and antimicrobials. Results of serologic testing for infection with FeLV and FIV were negative, and the cat's vaccination status was adequate. On physical examination, the cat was quiet but responsive. Decreased conscious proprioception was detected in the right forelimb; conscious proprioception in the other limbs and spinal reflexes in all limbs were considered normal. Radiographs of the thorax were obtained to evaluate for evidence of neoplasia (Figure 1).

Determine whether additional imaging studies are required, or make your diagnosis from Figure 1—then turn the page

This report was submitted by Cody A. Laas, DVM; Arathi Vinayak, DVM; Sharon C. Kerwin, DVM, MS, DACVS; and Anne Bahr, DVM, MS, DACVR; from the Departments of Small Animal Clinical Sciences (Laas, Vinayak, Kerwin) and Large Animal Clinical Sciences (Bahr), College of Veterinary Medicine and Biomedical Sciences, Texas A&M University, College Station, TX 77843. Dr. Laas' present address is the Department of Anatomy and Radiology, College of Veterinary Medicine, University of Georgia, Athens, GA 30602. Address correspondence to Dr. Laas.

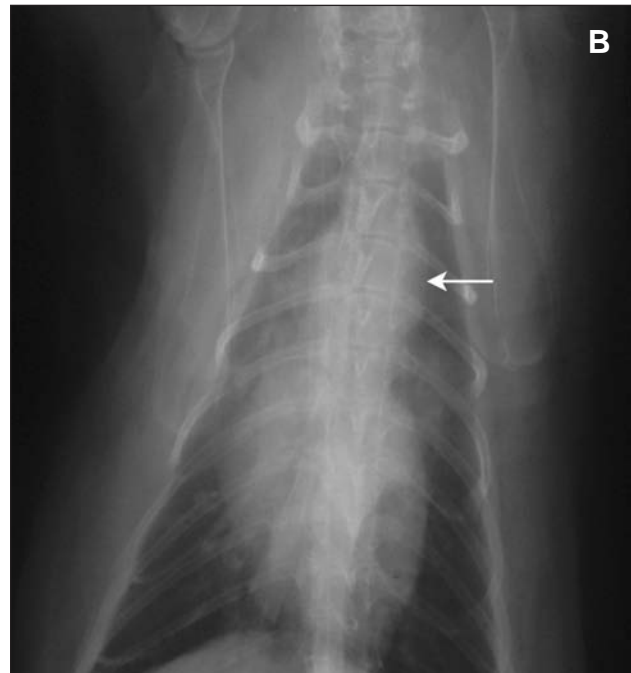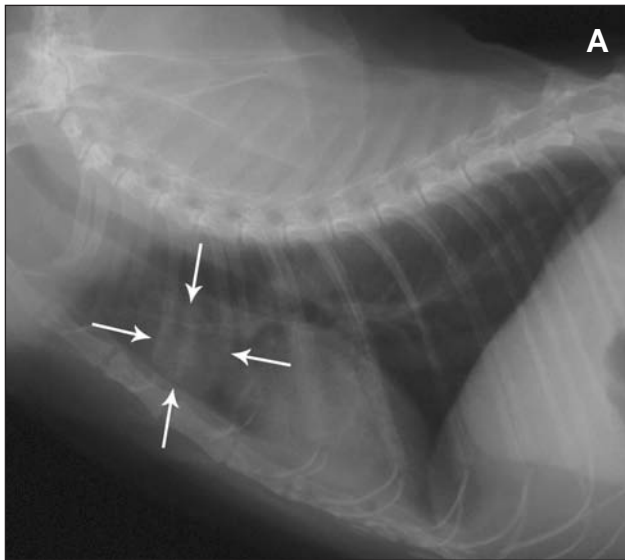


Figure 2—Same radiographic views as in Figure 1. A round soft tissue opacity is evident in the ventral aspect of the cranial mediastinum (arrows). On the ventrodorsal radiographic view, the cranial mediastinum appears wide and has round, convex margins (arrow).

### Radiographic Findings and Interpretation

On the lateral radiographic view, a round soft tissue opacity can be seen in the ventral aspect of the cranial mediastinum. On the ventrodorsal radiographic view, the cranial mediastinum appears wide and has round, convex margins (Figure 2). Radiographic findings were compatible with a cranial mediastinal soft tissue mass. Differential diagnoses for a cranial mediastinal mass in cats include mediastinal lymphoma, thymoma, ectopic thyroid tumor, lymphadenopathy, granuloma, abscess, hematoma, and mediastinal cyst.<sup>1</sup>

### Comments

Ultrasonography of the thorax revealed a discrete, thin-walled, anechoic mass with regular margins in the cranial mediastinum (Figure 3). Analysis of an ultrasonographically guided, fine-needle aspirate of the mass revealed fluid with low cellularity, low protein concentration, rare nucleated cells, and erythrocytes; infectious agents and neoplastic cells were not detected. The cytologic character of the fluid was consistent with cystic fluid. In the cat of this report, these findings were compatible with a diagnosis of mediastinal cyst.

Mediastinal cysts are not common in cats.<sup>1</sup> Often congenital, mediastinal cysts tend to develop in the cranial mediastinum. Histologic examination is necessary to differentiate the cellular origin of the cyst; however, this invasive step is seldom necessary as mediastinal cysts are often incidental findings with few associated clinical signs. In the cat of this report, no further diagnostic or therapeutic procedures were performed because of the lack of clinical signs attributable to the cyst.

Otoscopic and cytologic examinations of both ears were performed to rule out peripheral vestibular disease as the cause of the neurologic signs in the cat. The cause of the right-sided head tilt, circling, and central proprioceptive deficits was localized to a right-sided central vestibular lesion. Neurologic signs in the cat

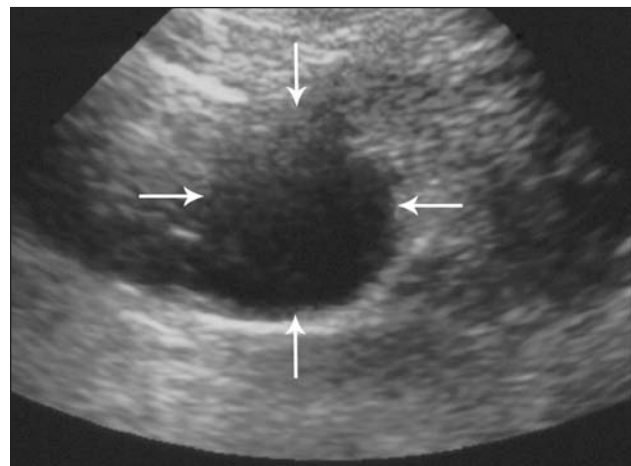


Figure 3—Ultrasonographic image of the thorax of the cat in Figure 1. Notice a discrete, thin-walled, anechoic mass with regular margins in the cranial mediastinum (arrows).

resolved within 24 hours; therefore, the owners chose not to pursue further diagnostic testing. Because of the acute onset and resolution of neurologic signs, feline ischemic encephalopathy and feline idiopathic vestibular disease were considered as possible differential diagnoses<sup>2,3</sup>; however, other differential diagnoses such as otitis media, encephalitis, meningitis, neoplasia, or abscess or granuloma of the brainstem could not be ruled out without further diagnostic testing.<sup>2,3</sup> Five months after the initial evaluation, the owner reported that the cat appeared to be normal.

1. Rogers KS, Walker MA. Disorders of the mediastinum. *Compend Contin Educ Pract Vet* 1997;19:69–82.

2. DeLahunta A. *Veterinary neuroanatomy and clinical neurology*. 2nd ed. Philadelphia: WB Saunders Co, 1983;144–145, 247.

3. Fenner WR. Diseases of the brain. In: Ettinger SJ, Feldman EC, eds. *Veterinary internal medicine*. 5th ed. Philadelphia: WB Saunders Co, 2000;580–582.