

Aortic ejection velocity in healthy Boxers with soft cardiac murmurs and Boxers without cardiac murmurs: 201 cases (1997–2001)

Shianne L. Koplitz, DVM; Kathryn M. Meurs, DVM, PhD, DACVIM; Alan W. Spier, DVM, PhD, DACVIM; John D. Bonagura, DVM, MS, DACVIM; Virginia Luis Fuentes, VetMB, PhD, DACVIM; Nicola A. Wright, BS

Objective—To determine aortic ejection velocity in healthy adult Boxers with soft ejection murmurs without overt structural evidence of left ventricular outflow tract obstruction and in healthy Boxers without cardiac murmurs.

Design—Retrospective study.

Animals—201 Boxers.

Procedure—Dogs were examined independently by 2 individuals for evidence of a cardiac murmur, and a murmur grade was assigned. Maximal instantaneous (peak) aortic ejection velocity was measured by means of continuous-wave Doppler echocardiography from a subcostal location. Forty-eight dogs were reexamined approximately 1 year later.

Results—A soft (grade 1, 2, or 3) left-basilar ejection murmur was detected in 113 (56%) dogs. Overall median aortic ejection velocity was 1.91 m/s (range, 1.31 to 4.02 m/s). Dogs with murmurs had significantly higher aortic ejection velocities than did those without murmurs (median, 2.11 and 1.72 m/s, respectively). Auscultation of a murmur was 87% sensitive and 66% specific for the identification of aortic ejection velocity > 2.0 m/s. An ejection murmur and aortic ejection velocity > 2.0 m/s were identified in 73 (36%) dogs. For most dogs, observed changes in murmur grade and aortic ejection velocity during a follow-up examination 1 year later were not clinically important.

Conclusions and Clinical Relevance—Results suggested that ejection murmurs were common among healthy adult Boxers and that Boxers with murmurs were likely to have high (> 2.0 m/s) aortic ejection velocities. The cause of the murmurs in these dogs is unknown. (*J Am Vet Med Assoc* 2003;222:770–774)

Low-grade left-basilar ejection murmurs are frequently identified in Boxers, with at least 50% of dogs at European breed shows having this type of cardiac murmur.¹⁻³ These ejection murmurs are presump-

tively related to increased aortic ejection velocity,^{1,4} which may be associated with obstructive or physiologic flow disturbances in the left ventricular outflow tract (LVOT). Aortic stenosis (AS), typically subvalvular, is the most common form of LVOT obstruction in Boxers.^{5,6} Alternatively, such murmurs in healthy dogs may represent undefined physiologic flow disturbances in the LVOT associated with sympathetic tone,^{1,7} athleticism,⁸ or anatomic factors (such as body conformation or size and shape of the aorta relative to the proximal portion of the LVOT).^{9,10}

Determining the cause of these murmurs is of great importance for owners of breeding dogs, as congenital AS is considered a heritable defect.¹¹⁻¹³ It is also important for owners of pet dogs not intended for breeding, as dogs with mild AS have an increased risk of developing bacterial endocarditis,⁶ a potentially life-threatening condition. To investigate the scope of this diagnostic dilemma, we retrospectively evaluated auscultatory and Doppler echocardiographic findings in a group of Boxers. The purpose of the study reported here was to determine aortic ejection velocity in healthy Boxers with soft ejection murmurs without overt structural evidence of LVOT obstruction and in healthy Boxers without cardiac murmurs. A secondary aim was to determine whether aortic ejection velocity or murmur grade varied over time in these dogs.

Criteria for Selection of Cases

Records of 228 mature client-owned Boxers evaluated as part of a prospective study of Boxer cardiomyopathy between January 1997 and December 2001 were reviewed. Boxers that were at least 1 year old and did not have overt evidence of AS were considered for inclusion in the present study. For the purposes of this study, overt evidence of AS was defined as a loud (> grade 3 on a scale from 1 to 6) systolic murmur or an obvious structural abnormality in the LVOT on a long-axis echocardiographic view obtained from a right parasternal location. Only dogs with an ejection murmur loudest over the aortic valve area or at the left base and those without a murmur were included. Dogs known to have a systemic disease and those medicated with β -adrenergic receptor antagonists or L-thyroxine were excluded. No attempt was made to evaluate specific family groups, although a number of dogs included in the study were related.

Procedures

Cardiovascular examinations were conducted by 2 of the authors (KMM and AWS). Auscultation was per-

From the Department of Veterinary Clinical Sciences, College of Veterinary Medicine, The Ohio State University, Columbus, OH 43201. Dr. Spier's present address is the Department of Medicine and Surgery, College of Veterinary Medicine, University of Missouri, Columbia, MO 65211.

Supported by the AKC Canine Health Foundation and American Boxer Charitable Trust.

Presented as a poster at the Annual Meeting of the American College of Veterinary Internal Medicine, Dallas, June, 2002.

Address correspondence to Dr. Koplitz.

formed in a quiet room while dogs were gently restrained. Intermittently, both nostrils were occluded for 3 to 5 seconds to decrease the likelihood that respiratory noises might obscure soft cardiac murmurs. The absence or presence of a cardiac murmur was recorded, and the severity of the murmur was graded by each examiner without knowledge of the other's results. The following classification scheme was used: grade 0 = no murmur was detected by either examiner after prolonged (at least 1 minute) cardiac auscultation; grade 1 = a soft intermittent ejection murmur was heard or a soft localized murmur was identified but only after prolonged auscultation; grade 2 = a soft localized murmur was immediately evident to the examiner; grade 3 = a moderately intense murmur was detected radiating over > 1 valve area.¹⁴ When the recorded murmur grade differed between examiners, auscultation was repeated by each until a consensus was reached.

All dogs underwent Doppler echocardiographic examination of the LVOT and ascending aorta. Dogs with cardiac murmurs also underwent standard 2-dimensional and color-flow Doppler echocardiography of the left ventricular inflow and outflow tracts. Maximal aortic ejection velocity was determined by means of continuous-wave Doppler echocardiography with simultaneous electrocardiography. For echocardiography, dogs were manually restrained in right lateral recumbency on a padded echocardiography table. No sedatives or tranquilizers were administered for these examinations. A color-flow echocardiography system^a with a 2.5-MHz transducer was used to record aortic ejection velocities from the subcostal position.¹⁵ The cursor was aligned parallel to the blood flow using concurrent 2-dimensional and color-flow Doppler echocardiography, and optimal signal strength was obtained by observing the real-time spectral display and listening to the audio signal of the Doppler system. Doppler velocity spectra were recorded as digital files on a magneto-optical disk and measured off-line with electronic calipers on an integrated workstation.^b Three to 5 aortic ejection velocity spectra with clear envelopes and well-defined peaks were identified and measured. Results were averaged to determine maximal instantaneous (peak) aortic ejection velocity.

Following the initial evaluation, owners were asked to return with their dogs for reexamination on an annual basis. For dogs included in the present study that had been examined more than once, results of auscultation and Doppler echocardiography performed during follow-up examinations were compared with results for the initial examination. For dogs that were examined more than twice, information from only 1 follow-up examination was used in analyses; the follow-up examination that was used was the one during which the greatest difference in aortic ejection velocity was identified.

Statistical analyses—Measured cardiac variables were cardiac murmur grade and maximal instantaneous (peak) aortic ejection velocity. Body weight, age, and sex were also recorded. For purposes of statistical evaluation, dogs were grouped according to whether they did or did not have a cardiac murmur and as to

whether they had aortic ejection velocity ≤ 2.0 m/s or > 2.0 m/s. The cutoff of 2.0 m/s was selected on the basis of published recommendations for determining normal and abnormal aortic ejection velocities in dogs.^{6,13,16-19}

Mann-Whitney tests were used to compare age and aortic ejection velocity between male and female dogs, to compare age and aortic ejection velocity between dogs with and without cardiac murmurs, and to compare murmur grade between dogs with aortic ejection velocity ≤ 2.0 m/s versus > 2.0 m/s. Student *t*-tests were used to compare weight between male and female dogs and between dogs with and without cardiac murmurs. Student *t*-tests were also used to compare follow-up age and weight between dogs that changed auscultatory grouping (ie, those that changed from not having a cardiac murmur to having a murmur or that changed from having a cardiac murmur to not having a murmur) and those that did not and to compare follow-up age and weight between dogs that changed aortic ejection velocity classification (≤ 2.0 m/s vs > 2.0 m/s) with those that did not. Associations between aortic ejection velocity and age, body weight, and murmur grade were examined with Pearson product-moment correlation or Spearman rank correlation. Associations between change in murmur grade, change in aortic ejection velocity, change in age, and change in body weight were similarly assessed. A Kruskal-Wallis ANOVA was used to compare aortic ejection velocities across murmur grades. When significant differences were detected, the Dunn test was used for pairwise comparisons. A paired *t*-test was used to identify differences between aortic ejection velocity measured at baseline and at the time of follow-up examination. Statistical calculations were performed with standard software.^c For all analyses, values of $P < 0.05$ were considered significant.

Results

Overall, 201 Boxers met the criteria for inclusion in the study. Of these, 80 (40%) were male, and 121 (60%) were female. Mean age was 4.4 years (range, 1 to 12.7 years; median, 3.9 years), and mean body weight was 28.2 kg (62 lb; range, 15.9 to 42.7 kg [35 to 94 lb]; median, 27.7 kg [61 lb]). Mean body weight of the male dogs (31 kg [68 lb]) was significantly ($P < 0.001$) greater than that of the female dogs (26 kg [57 lb]). However, median age was not significantly ($P = 0.7$) different between males and females.

Overall, median maximum instantaneous aortic ejection velocity was 1.91 m/s (range, 1.31 to 4.02 m/s; mean, 2.0 m/s). Median aortic ejection velocity was not significantly ($P = 0.1$) different between males (1.96 m/s) and females (1.87 m/s). A weak positive correlation was observed between aortic ejection velocity and body weight ($r = 0.16$; $P = 0.03$). No significant correlation was found between aortic ejection velocity and age ($r = -0.14$; $P = 0.06$).

Eighty-eight (44%) dogs did not have a detectable heart murmur (ie, grade 0). Of these, 27 (31%) were male, and 61 (69%) were female. The remaining 113 (56%) dogs had soft (grade 1, 2, or 3) left-basilar ejection murmurs. Of these, 53 (47%) were male, and 60

(53%) were female. Dogs without a cardiac murmur were significantly ($P < 0.001$) older (median, 4.3 years) than dogs with a murmur (median, 3.2 years). A significant difference in body weight was not detected between dogs with and without murmurs ($P = 0.7$), although the power for this test was low (0.05).

Median aortic ejection velocity for dogs without a murmur was 1.72 m/s (range, 1.31 to 2.38 m/s; mean, 1.75 m/s), which was significantly ($P < 0.001$) less than median aortic ejection velocity for dogs with a murmur (2.11 m/s; range, 1.57 to 4.02 m/s; mean, 2.20 m/s). Aortic ejection velocity was > 2.0 m/s in 11 of the 88 (13%) dogs without a murmur, compared with 73 of the 113 (65%) dogs with a murmur.

Murmur grade was positively correlated with aortic ejection velocity ($r = 0.67$; $P < 0.001$; Fig 1). Median aortic ejection velocities for dogs without a murmur (ie, grade 0) and for dogs with a grade-1 murmur were significantly different from median aortic ejection velocities for dogs with a grade-2 murmur and for dogs with a grade-3 murmur. However, median aortic ejection velocity for dogs without a murmur was not significantly different from median velocity for dogs with a grade-1 murmur, and median velocity for dogs with a grade-2 murmur was not significantly different from median velocity for dogs with a grade-3 murmur. Median murmur grade for dogs with aortic ejection velocity ≤ 2.0 m/s was significantly ($P < 0.001$) lower than the median murmur grade for dogs with an aortic ejection velocity > 2.0 m/s (Fig 2). Auscultation of a murmur was 87% sensitive but only 66% specific for identification of aortic ejection velocity > 2.0 m/s. Of the 201 dogs, 73 (36%) had both a systolic ejection murmur and aortic ejection velocity > 2.0 m/s.

Forty-eight dogs underwent follow-up examination, including 26 dogs without a murmur initially and 22 dogs with a murmur initially. Median time between initial and follow-up examinations was 13.5 months (range, 12 to 31 months; mean, 16 months). At the time of the follow-up examination, 22 of the 26 (85%) dogs that did not have a murmur initially still did not have a murmur, but 4 (15%) had developed a

left-basilar ejection murmur. Mean age of the 4 dogs that developed a murmur (3.6 years) was not significantly ($P = 0.053$) different from the mean age (6.6 years) of the 22 dogs that did not. Twelve of the 22 (55%) dogs with a murmur on initial examination continued to have a murmur on follow-up examination; however, a murmur was not detected in the remaining 10 (45%) dogs that had a murmur on initial examination. The maximum individual changes in murmur grade were a decrease from grade 3 to grade 0 and an increase from grade 0 to grade 2. The change in murmur grade was not correlated with the change in age between examinations ($P = 0.93$) or the change in body weight ($P = 0.11$).

Thirty-six of the 48 (75%) dogs that underwent follow-up examinations had an aortic ejection velocity ≤ 2.0 m/s at the initial examination, and for 28 of the 36 (78%), aortic ejection velocity remained ≤ 2.0 m/s at the follow-up evaluation. In the remaining 8 (22%) dogs, aortic ejection velocity at the follow-up examination was > 2.0 m/s with a mean increase of 0.31 m/s (range, 0.15 to 0.59 m/s). The largest individual increase in aortic ejection velocity was from 1.84 to 2.43 m/s. Twelve of the 48 (25%) dogs that underwent follow-up examination had an initial aortic ejection velocity > 2.0 m/s, and 6 of these dogs still had an aortic ejection velocity > 2.0 m/s at the follow-up examination. In the remaining 6, aortic ejection velocity had decreased to < 2.0 m/s with a mean decrease of 0.21 m/s (range, 0.07 to 0.39 m/s). The largest individual decrease was from 2.07 to 1.68 m/s. Overall mean aortic ejection velocity at the follow-up examination (1.87 m/s) was significantly ($P = 0.04$) greater than mean aortic ejection velocity at the initial examination (1.81 m/s); however, this difference was not considered clinically relevant (Fig 3). The change in aortic ejection velocity was not correlated with the change in age between examinations ($P = 0.18$) or with the change in body weight ($P = 0.65$). A positive correlation was detected between the change in murmur grade and the change in aortic ejection velocity ($r = 0.45$; $P = 0.002$); however, considerable individual variation was observed (Fig 4).

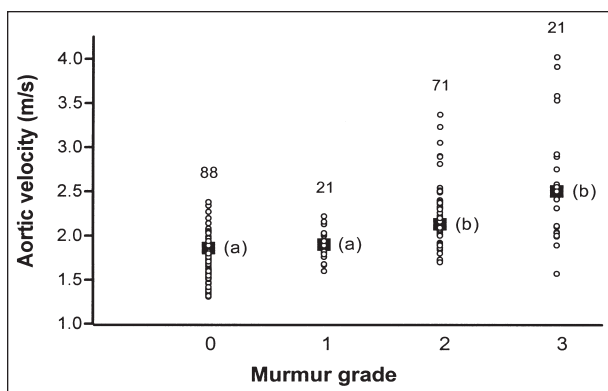


Figure 1—Relationship between cardiac murmur grade and aortic ejection velocity in 201 adult Boxers without overt evidence of structural left ventricular outflow tract obstruction. Aortic ejection velocity was measured echocardiographically from a subcostal location. Solid black squares represent median aortic ejection velocities; median aortic ejection velocities with different letters were significantly ($P < 0.05$) different.

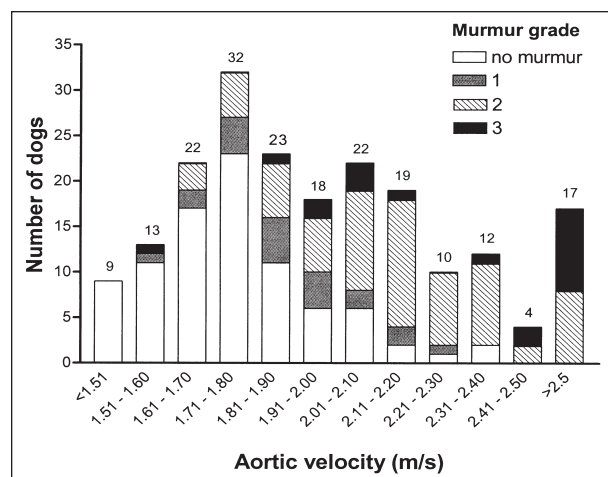


Figure 2—Murmur grade as a function of aortic ejection velocity in 201 adult Boxers without overt evidence of structural left ventricular outflow tract obstruction.

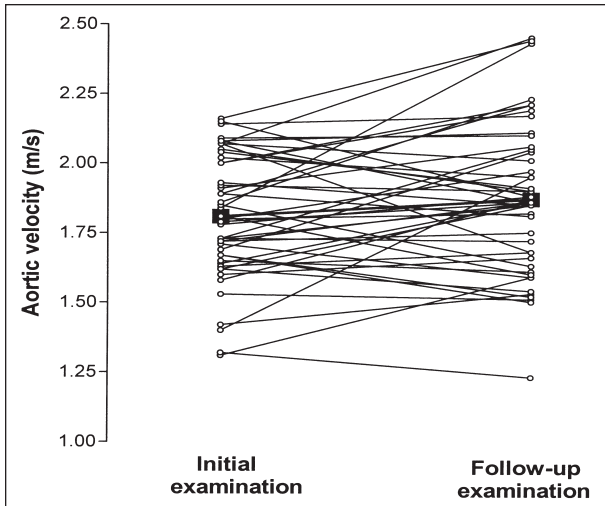


Figure 3—Change in aortic ejection velocity from the time of initial examination to the time of follow-up examination at least 12 months later in 48 adult Boxers. Solid black squares represent mean aortic ejection velocity during each examination.

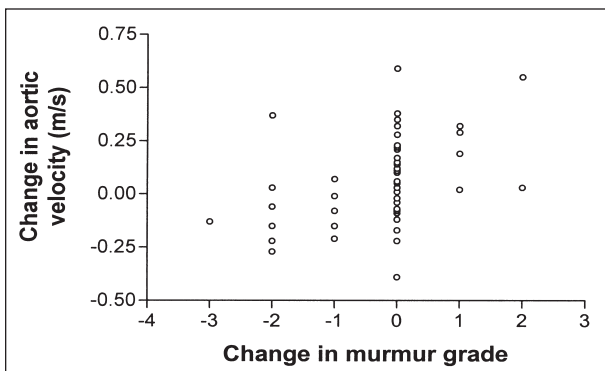


Figure 4—Change in aortic ejection velocity as a function of change in murmur grade between the time of initial examination and a follow-up examination at least 12 months later in 48 adult Boxers.

Discussion

Results of the present study confirmed the high prevalence of ejection murmurs among mature Boxers and indicated that Boxers with murmurs were more likely to have high aortic ejection velocities. In addition, auscultation was a sensitive screening test for identifying dogs in this population with an aortic ejection velocity > 2.0 m/s. For most dogs, observed changes in murmur grade and aortic ejection velocity during a follow-up examination 1 year later were not clinically important.

One hundred thirteen of 201 (56%) dogs in this study had low-grade left-basilar ejection murmurs. The high prevalence of ejection murmurs in this population parallels findings in previous studies¹⁻³ involving European Boxers. In most circumstances, such murmurs reflect either obstruction to ventricular outflow (aortic or pulmonic stenosis) or presumed physiologic flow disturbances that are unrelated to a cardiac abnormality (functional murmur). Aortic stenosis is well-recognized in Boxers,^{5,6} but physiologic murmurs are also thought to be common in these dogs. Such physiologic murmurs may result from an exaggerated response to sympathetic tone or an anatomic variant in the LVOT not related to stenosis, such as aortic hypoplasia.¹³ Because the true cause of

the high prevalence of ejection murmurs in Boxers is unknown, their presence presents a diagnostic dilemma.

Data in the present study suggested that detection of a left-basilar ejection murmur was useful in predicting aortic ejection velocity. This is clinically important, because aortic ejection velocity currently represents an important criterion for identification of dogs with mild AS. In general, dogs with ejection murmurs in the present study had higher aortic ejection velocities than did dogs without murmurs (median aortic ejection velocity, 2.11 and 1.72 m/s, respectively), and a strong positive correlation was detected between murmur grade and peak aortic ejection velocity. Auscultation was a sensitive screening test for identification of dogs with aortic ejection velocity > 2.0 m/s (sensitivity, 87%), although the specificity of auscultation (66%) was lower. These findings validate the common practice of using auscultation to screen dogs for high aortic ejection velocity prior to further evaluation with Doppler echocardiography, a more specific but more expensive test.

In the present study, we recorded maximal instantaneous (peak) aortic ejection velocity from echocardiographic images obtained from a subcostal location. This location permits the most parallel imaging to aortic blood flow and consequently yields the most accurate aortic ejection velocities.¹⁵ We analyzed our results using a cutoff of 2.0 m/s to distinguish normal from high aortic ejection velocity, as this is a commonly reported upper limit for normal aortic ejection velocity in dogs.¹⁹ However, other investigators consider velocities up to 2.25 m/s to be normal.²⁰ Unfortunately, a reference range for aortic ejection velocity measured from the subcostal location in dogs has not been established. The only published information for healthy dogs describes aortic ejection velocity determined from an alternate echocardiographic location (left apical) and indicates an upper limit for aortic ejection velocity of 1.5 to 1.7 m/s.^{16,21,22,d}

An increase in aortic ejection velocity is a major determinant in the diagnosis of AS; therefore, distinguishing normal from abnormal aortic ejection velocity is important. Even though dogs with mild AS do not typically develop congestive heart failure or die suddenly, they may have an increased risk of developing endocarditis.⁶ More importantly, the genetic basis of AS is established in Newfoundlands,¹¹ and the condition is presumed to be genetic in other breeds as well. Therefore, the correct classification of dogs likely has substantial breeding implications. Assuming the diagnostic criteria for AS were detection of an ejection murmur in conjunction with an aortic ejection velocity > 2.0 m/s, AS would have been diagnosed in 73 of the 201 (36%) Boxers in this study. Thirty-four (17%) would still have fit the criteria if the cutoff for aortic ejection velocity was increased to 2.25 m/s.

The high prevalence of low-grade left-basilar ejection murmurs and mildly elevated aortic ejection velocities in Boxers may represent physiologic changes that are unrelated to any anatomic cardiac defect. The influence of sympathetic tone on these parameters has been recognized.^{1,7,23} Dynamic changes in ventricular loading conditions associated with sinus arrhythmia, such as increased preload or decreased afterload with longer R-to-R intervals, may explain some intermittent murmurs and highly variable aortic ejection velocities.¹⁶ Furthermore, normal

aortic ejection velocity for Boxers may be different from the normal velocity for dogs of other breeds. In the present study, dogs with murmurs were significantly younger than dogs without a murmur. Thus, young Boxers may more commonly experience the physiologic changes that cause functional murmurs and mild increases in aortic ejection velocity.

Most dogs in the present study did not have clinically important changes in auscultatory or Doppler echocardiographic findings when reexamined 1 year after the initial examination. However, follow-up examination revealed a murmur in 4 of 26 (15%) dogs that had not had a murmur during the initial examination and failed to identify a murmur in 10 of 22 (45%) dogs that had had a murmur during the initial examination. Intermittent murmurs in Boxers have been reported,¹ and this may explain the apparent discrepancy. Another potential explanation is that murmurs were present at both examinations but were not detected at 1 or the other because of excessive respiratory noise or excitability of the dog. Six (13%) dogs had a decrease in aortic ejection velocity from > 2.0 m/s to ≤ 2.0 m/s. An additional 8 dogs had an increase in aortic ejection velocity from ≤ 2.0 m/s to > 2.0 m/s, which might have been clinically important. Mean increase for these dogs was 0.31 m/s, and the largest individual change was from 1.84 m/s to 2.43 m/s. The mild variability in murmur grade and aortic ejection velocity between examinations may represent structural changes in the LVOT over time¹³ or may simply reflect different physiologic conditions at separate examinations, such as level of excitement, stage of estrus cycle, or time waited for evaluation.

The relationship between aortic ejection velocity and grade of ejection murmur must be evaluated in light of the fact that auscultation and Doppler examination were not conducted simultaneously. Perceived inconsistencies between these variables may be related to dynamic (minute-to-minute) changes. Such labile characteristics of ventricular outflow may explain the absence of a murmur in 11 dogs with an aortic ejection velocity > 2.0 m/s. For dogs that underwent follow-up examinations in this study, it may also explain the relatively wide variation in change in aortic ejection velocity, even as the murmur grade remained unchanged.

Several limitations of this study must be acknowledged. Anatomic evidence for LVOT obstruction was assessed with a single echocardiographic plane, the long-axis view obtained from a right parasternal location, and it is possible that abnormalities would have been detected in some dogs if other echocardiographic planes had been used. In addition, pulmonic stenosis was not systematically excluded by means of Doppler echocardiography as a cause for the basilar ejection murmur in each dog. Pulmonic stenosis is recognized in Boxers; however, the reported prevalence is much less than that of AS.³ Finally, we were unable to control or quantify variations in autonomic tone that may have had an impact on cardiac murmur grade or measured aortic ejection velocity.

Despite these limitations, the study demonstrated a high prevalence of ejection murmurs and high aortic ejection velocities among a large group of healthy Boxers from North America. Whether these findings represent a variant of normal or signify the presence of a genuine

cardiac malformation remains debatable, and further comparative echocardiographic, pathologic, and genetic studies are necessary to address this clinical question.

^aVingmed System V, GE Medical, Horten, Norway.

^bEchopac, GE Vingmed Ultrasound, Horten, Norway.

^cSigmaStat for Windows, version 2.03, SPSS Inc, San Rafael, Calif.

^dGaber CE. Normal pulsed Doppler flow velocities in adult dogs (abstr), in *Proceedings*. 5th Annu Vet Med Forum 1987;923.

References

1. Heiene R, Kvarn C, Indrebo A, et al. Prevalence of murmurs consistent with aortic stenosis among boxer dogs in Norway and Sweden. *Vet Rec* 2000;147:152–156.
2. Luis Fuentes V. Aortic stenosis in Boxers. *Vet Ann* 1993;33:220–229.
3. Bussadori C, Quintavalla C, Capelli A. Prevalence of congenital heart disease in Boxers in Italy. *J Vet Cardiol* 2001;3:7–11.
4. Kvarn C, French AT, Luis Fuentes V, et al. Analysis of murmur intensity, duration and frequency components in dogs with aortic stenosis. *J Small Anim Pract* 1998;39:318–324.
5. Buchanan JW. Causes and prevalence of cardiovascular disease. In: Kirk RW, Bonagura JD, eds. *Current veterinary therapy XI*. Philadelphia: WB Saunders Co, 1992;647–655.
6. Kienle RD, Thomas WP, Pion PD. The natural clinical history of canine congenital subaortic stenosis. *J Vet Intern Med* 1994;8:423–431.
7. Lehmkuhl LB, Bonagura JD. CVT update: canine subvalvular aortic stenosis. In: Bonagura JD, Kirk RW, eds. *Current veterinary therapy XII*. Philadelphia: WB Saunders Co, 1995;822–827.
8. Stepien RL, Hinchcliff KW, Constable PD, et al. Effect of endurance training on cardiac morphology in Alaskan sled dogs. *J Appl Physiol* 1998;85:1368–1375.
9. Bussadori C. Echo patterns in Boxers with subaortic stenosis, in *Proceedings*. 18th Annu Vet Med Forum 2000;86–87.
10. Paspoularides A. Clinical assessment of ventricular ejection dynamics with and without outflow obstruction. *J Am Coll Cardiol* 1990;15:859–882.
11. Pyle RL, Patterson DF, Chacko S. The genetics and pathology of discrete subaortic stenosis in the Newfoundland dog. *Am Heart J* 1976;92:324–334.
12. O'Grady MR, Holmberg DL, Miller CW, et al. Canine congenital aortic stenosis: a review of the literature and commentary. *Can Vet J* 1989;30:811–815.
13. French A, Luis Fuentes V, Dukes-McEwan J, et al. Progression of aortic stenosis in the Boxer. *J Small Anim Pract* 2000;41:451–456.
14. Sisson DD, Ettinger SJ. The physical examination. In: Fox PR, Sisson D, Moise NS, eds. *Textbook of canine and feline cardiology*. Philadelphia: WB Saunders Co, 1999;46–64.
15. Lehmkuhl LB, Bonagura JD. Comparison of transducer placement sites for Doppler echocardiography in dogs with subaortic stenosis. *Am J Vet Res* 1994;55:192–198.
16. Bonagura JD, Miller MW, Darke PG. Doppler echocardiography I: pulsed-wave and continuous-wave examinations. *Vet Clin North Am Small Anim Pract* 1998;28:1325–1359.
17. Luis Fuentes V, Darke PG, Cattanauch BM. Aortic stenosis in Boxer dogs, in *Proceedings*. 12th Annu Vet Med Forum 1994;309–311.
18. Belanger MC, Fruscia RD, Dumesnil JG, et al. Usefulness of the indexed effective orifice area in the assessment of subaortic stenosis in the dog. *J Vet Intern Med* 2001;15:430–437.
19. Kienle RD. Aortic stenosis. In: Kittleson MD, Kienle RD, eds. *Small animal cardiovascular medicine*. St Louis: Mosby, 1998;260–272.
20. Bussadori C, Amberger C, Le Bobiniec G, et al. Guidelines for the echocardiographic studies of suspected subaortic and pulmonic stenosis. *J Vet Cardiol* 2000;2:17–24.
21. Brown DJ, Knight DH, King RR. Use of pulsed-wave Doppler echocardiography to determine aortic and pulmonary velocity and flow variables in clinically normal dogs. *Am J Vet Res* 1991;52:543–550.
22. Yuill CD, O'Grady MR. Doppler-derived velocity of blood flow across the cardiac valves in the normal dog. *Can J Vet Res* 1991;55:185–192.
23. Bonagura JD. Problems in the canine left ventricular outflow tract (edit). *J Vet Intern Med* 2001;15:427–429.