

# Outcome of and complications associated with prophylactic percutaneous laser disk ablation in dogs with thoracolumbar disk disease: 277 cases (1992–2001)

Kenneth E. Bartels, DVM, MS; Russell G. Higbee, PhD, DVM; Robert J. Bahr, DVM, DACVR; David S. Galloway, DVM; Tiffany S. Healey, DVM; Christopher Arnold, DVM

**Objective**—To determine outcome of and complications associated with prophylactic percutaneous laser disk ablation in dogs with thoracolumbar disk disease.

**Design**—Retrospective study.

**Animals**—277 dogs.

**Procedure**—Medical records of dogs with a history of thoracolumbar disk disease in which the 7 intervertebral disks from T10-11 through L3-4 were ablated with a holmium-yttrium-aluminum-garnet laser inserted through percutaneously placed needles were reviewed. Complications and episodes of a recurrence of neurologic signs (eg, paresis or paralysis) were recorded. Owners were contacted by telephone for follow-up information.

**Results**—Nine of 262 (3.4%) dogs for which follow-up information was available had a recurrence of paresis or paralysis. Follow-up time ranged from 1 to 85 months (mean, 15 months); signs recurred between 3 and 52 months (mean, 15.1 months) after laser disk ablation. Acute complications occurred in 5 dogs and included mild pneumothorax in 1 dog, an abscess at a needle insertion site in 1 dog, and proprioceptive deficits in 3 dogs, 1 of which required hemilaminectomy within 1 week because of progression and severity of neurologic signs. One dog developed diskospondylitis.

**Conclusions and Clinical Relevance**—Results suggest that prophylactic percutaneous laser disk ablation is associated with few complications and may reduce the risk of recurrence of signs of intervertebral disk disease in dogs. (*J Am Vet Med Assoc* 2003;222:1733–1739)

A percutaneous method for photothermal ablation or coagulation of the nucleus pulposus of the thoracolumbar disks with a holmium-yttrium-aluminum-garnet (Ho:YAG) laser has been described.<sup>1</sup> A clinical technique for use in dogs was developed in conjunction with a research project to determine the long-term histologic effects of laser-assisted disk decompression in human beings.<sup>2</sup> Since then, percutaneous laser disk

ablation (PLDA) has been recommended as a prophylactic procedure to reduce the risk of recurrence of clinical signs in dogs with a history of thoracolumbar disk disease. Prophylactic PLDA is minimally invasive, compared with surgical fenestration and, therefore, should be associated with a lower complication rate and shorter recovery times.<sup>3,4</sup> The procedure is intended to prevent extrusion into the spinal canal of additional nucleus pulposus from partially herniated disks and protrusion or extrusion of the nucleus pulposus in adjacent intervertebral disks. However, it is not a replacement for surgical treatment in dogs with thoracolumbar disk disease that require removal of disk fragments causing spinal cord or nerve root compression.

To our knowledge, no reports of the outcome of dogs with thoracolumbar disk disease that have undergone prophylactic PLDA have been published. The purpose of the study reported here was to determine outcome of and complications associated with prophylactic PLDA in dogs with thoracolumbar disk disease. In particular, we wanted to determine the percentage of dogs undergoing this procedure in which clinical signs of thoracolumbar disk disease recurred.

## Criteria for Selection of Cases

Medical records and laser surgery logs at the Oklahoma State University Veterinary Teaching Hospital were searched, and dogs that underwent Ho:YAG laser ablation of the nucleus pulposus of intervertebral disks T10-11 through L3-4 between October 1992 and December 2001 were identified.

Dogs were included in the study if they had a documented history of thoracolumbar intervertebral disk disease and had undergone prophylactic PLDA following recovery from an episode of disk disease. For dogs included in the study, a tentative diagnosis of thoracolumbar intervertebral disk disease had been made by the referring veterinarian on the basis of signalment, clinical signs, and results of a neurologic evaluation. Survey radiographs of the thoracolumbar vertebrae were examined for narrowing or wedging of any intervertebral space, narrowing of any articular space, and a decrease in size or increase in density of the intervertebral foramen, compared with adjacent foramina. The diagnosis of thoracolumbar disk disease was confirmed if radiographic signs were consistent with the suspected neuroanatomic location of the lesion. During an episode of thoracolumbar disk disease, dogs with signs of pain alone were treated with cage rest, with or with-

From the Department of Veterinary Clinical Sciences and the Sarkeys Surgical Laser Laboratory, College of Veterinary Medicine, Oklahoma State University, Stillwater, OK 74078.

Funded in part by the Presbyterian Health Foundation, Oklahoma City, and the Sarkeys Foundation, Norman, Okla.

The authors thank Drs. George A. Henry, W. Tod Drost, Margaret A. Blaik, Mark C. Rochat, and Ellen B. Davidson for technical assistance. Address correspondence to Dr. Bartels.

out administration of anti-inflammatory medications. Dogs with evidence of paresis or paralysis were immediately referred for additional diagnostic evaluation and decompressive surgery.

Dogs were included in the present study only if prophylactic PLDA was performed after dogs had completely recovered from a previous episode of disk disease and no longer had any signs of neurologic disease. In addition, dogs that had been treated with an anti-inflammatory medication were included only if PLDA was performed at least 2 weeks after anti-inflammatory treatment was discontinued. Dogs that had undergone surgical decompression (hemilaminectomy) for removal of protruded or extruded intervertebral disk material were eligible for inclusion in the study if PLDA had been performed after the dogs had recovered completely and regained normal proprioceptive responses or after the dogs had recovered and proprioceptive deficits had been static for at least 6 months.

### Procedures

**Surgical procedure**—Owners of all dogs were required to sign informed consent forms prior to their dogs undergoing PLDA. A CBC, serum biochemical analyses, and urinalysis were performed to identify abnormalities. The dog was then anesthetized, and right lateral and ventrodorsal radiographic projections of the thoracolumbar portion of the vertebral column were obtained and examined for radiographic signs of intervertebral disk disease, including mineralized disk material in the vertebral canal.

If the dog was determined to be a suitable candidate, PLDA was performed as described.<sup>1</sup> Briefly, 20-gauge, 2.5-in spinal needles<sup>a</sup> were inserted through the skin and directed toward the center of intervertebral disks T10-11 through L3-4 (3.5-in spinal needles were used in obese dogs weighing > 10 kg [22 lb]). When all 7 spinal needles were in position, left lateral and ventrodorsal fluoroscopic images were obtained to verify the position of each needle; hard copies of the images were made for archival purposes.

For each needle in turn, the stylet was removed, and a laser fiber<sup>b</sup> was inserted through the needle. Prior to insertion of the laser fiber, positioning of the needle was again checked fluoroscopically, and the needle was rotated in place, if necessary, to ensure that its bevel faced toward the greatest thickness of the nucleus pulposus. The Ho:YAG<sup>c</sup> laser was activated for 40 seconds at 2 W of power with a 15-Hz pulse repetition rate, resulting in a total energy dose of 80 J and a fluence of 105 J/cm<sup>2</sup> at the fiber tip. After each site was treated, the needle was removed. Disk sites at the location of a previous hemilaminectomy were ablated in the same manner as other disks.

A neurologic examination was performed on all dogs immediately following anesthetic recovery, and dogs were observed in the veterinary teaching hospital for a minimum of 24 hours after surgery. At the time of discharge, owners were instructed to restrict the dog's activity to leash exercise for 2 weeks, and then to gradually increase the level of activity over the next 4 weeks.

**Follow-up evaluations**—After surgery, owners

were contacted by telephone to determine their opinion of the outcome of the procedure. In particular, owners were asked whether their dogs were better, the same, or worse immediately after undergoing PLDA, whether their dogs had had any signs of pain immediately after the procedure, whether their dogs' condition was currently better than it had been at the time of the procedure, and whether any new clinical abnormalities had developed. Owners were specifically asked to describe any physical abnormalities their dogs may have developed after undergoing PLDA. During this discussion, emphasis was placed on abnormalities attributable to neurologic or orthopedic diseases, such as signs of lumbar pain, incoordination, paresis, paralysis, or lameness. Finally, owners were asked if they had any additional comments on their dogs' welfare and progress.

**Data analysis**—Descriptive statistics were calculated. No attempts were made to identify factors associated with complications, because the complication rate was too low.<sup>d</sup>

### Results

A total of 277 dogs met the criteria for inclusion in the study. There were 164 Dachshunds (59.2%), 17 Cocker Spaniels (6.1%), 14 Shih Tzus (5.1%), 11 Lhasa Apsos (4.0%), 8 Schnauzers (2.9%), 8 Pekingese (2.9%), 7 Miniature Poodles (2.5%), 4 Beagles (1.4%), 17 dogs of other breeds (6.1%; Jack Russell Terrier [3], Maltese [2], Yorkshire Terrier [2], and Basset Hound, Bichon Frise, Boston Terrier, Chihuahua, Fox Terrier, French Bulldog, Japanese Chin, Miniature Pinscher, Springer Spaniel, and Pomeranian [1 each]), and 27 dogs of mixed breeding (9.8%). Overall, 122 (44.0%) dogs were spayed females, 77 (27.8%) were castrated males, 49 (17.7%) were sexually intact males, and 29 (10.5%) were sexually intact females. Age of the dogs at the time of PLDA ranged from 1 to 15 years (mean, 5.9 years).

Two hundred three (73.3%) of the 277 dogs had had a single episode of thoracolumbar disk disease prior to undergoing PLDA, 45 (16.3%) had had 2 episodes, 22 (7.9%) had had 3 episodes, and 7 (2.5%) had had 4 episodes. Sixteen (5.8%) dogs had undergone hemilaminectomy for removal of protruded or extruded disk material prior to undergoing PLDA.

**Perioperative complications**—Five (1.8%) of the 277 dogs developed complications during the perioperative period. In 1 Dachshund, pneumothorax with accumulations of air near intervertebral disks T10-11 and T11-12 was identified on fluoroscopic images obtained following percutaneous needle placement. No other abnormalities or adverse clinical signs were evident. Following 24 hours of cage rest, the pneumothorax had resolved, as determined by means of follow-up radiography.

On the second day after undergoing PLDA, a 6-year-old Bichon Frise developed a small (3- to 4-mm diameter) abscess at the insertion site for 1 of the needles. No radiographic or neurologic abnormalities were seen, and the abscess resolved with appropriate local treatment and oral administration of antimicrobials.

Three dogs developed neurologic abnormalities, including proprioceptive deficits, paresis, or paralysis, after undergoing PLDA. One of these was a 4-year-old Yorkshire Terrier evaluated early during the study period that was examined because of a history of recurrent signs of lumbar pain and incoordination of the hind limbs. At the time of PLDA, clinical abnormalities had been absent for 7 days. Radiography revealed multiple calcified thoracolumbar intervertebral disks with possible narrowing of the T12-13 disk. Because the dog appeared neurologically normal, PLDA was performed within 24 hours after admission to the veterinary teaching hospital. Immediately after recovering from anesthesia, the dog had paresis of the hind limbs. The dog was hospitalized for 5 days, during which time its condition did not worsen, and was then discharged. One week later, it was readmitted with a 6-hour history of acute paralysis of the hind limbs. Myelography and hemilaminectomy revealed extrusion of the T12-13 intervertebral disk. The dog recovered without further complications and was able to walk within 1 week after surgery. It did not have any other recurrences for the subsequent 5 years.

Two other dogs had proprioceptive deficits and paresis of the hind limbs immediately after undergoing PLDA. When examined prior to surgery, neither had had any neurologic abnormalities for at least 1 month. Both dogs were hospitalized and observed, and both were ambulating normally within 7 days. Owners of both dogs indicated that the dogs had signs of mild discomfort during gentle palpation of the lumbar area for an additional week. These signs responded to cage rest and oral administration of nonsteroidal anti-inflammatory agents.

**Owner evaluations of outcome and long-term complications**—Owners of 265 of the 277 dogs were contacted 1 or more times by telephone after their dogs underwent PLDA (mean follow-up time, 22.3 months; range, 1 to 85 months).

Eight dogs (2.9%) died or were euthanatized as a result of conditions other than neurologic disease, including trauma associated with an automobile accident, acute pancreatitis, renal carcinoma, diffuse lymphoma, and cervical trauma.

Of the 262 respondents, 198 (75.6%) indicated their dogs were improved immediately after undergoing PLDA, 58 (22.1%) said their dogs were the same, and 6 (2.3%) said their dogs were worse. Sixty-four (24.4%) owners indicated that their dogs had signs of pain immediately after the procedure, whereas 198 (75.6%) indicated their dogs did not have any signs of pain. Some of these owners indicated that it was difficult to restrict their dogs' activity, because they did not have any signs of discomfort. Two hundred forty-one (92%) of the 262 owners indicated that their dogs' condition at the time of follow-up evaluation was better than it had been at the time of the procedure, 15 (5.7%) said it was the same, and 6 (2.3%) said it was worse.

Two hundred thirteen (81.3%) owners reported that their dogs had not had a recurrence of signs of thoracolumbar disk disease or evidence of pain since

undergoing PLDA. The remaining 49 (18.7%) owners, however, reported that > 4 weeks after undergoing PLDA, their dogs had had clinical signs potentially attributable to orthopedic (eg, lameness), soft-tissue (eg, signs of abdominal or visceral pain), or neurologic (eg, incoordination, signs of cervical or lumbar pain, paresis, or paralysis) disease. Twenty-two of these 49 owners reported that their dogs recovered completely from these signs following a period of rest at home.

The remaining 27 owners reported that signs, including lameness, recurrent back pain, paresis, or paralysis, were not responsive to rest or were severe enough to warrant reevaluation by a veterinarian. These dogs were reexamined between 7 weeks and 72 months after undergoing PLDA. In 3 of the 27 dogs, signs were attributed to an orthopedic problem, including rupture of the cranial cruciate ligament in 1 and degenerative joint disease involving the hip joints in the other 2.

Nine dogs in which their owners reported had signs of back pain were reexamined between 8 and 48 months after undergoing PLDA for possible thoracolumbar disk protrusion. Results of neurologic examination and appropriate ancillary tests, including radiography, myelography, and in some instances, computed tomography, indicated that in all 9, signs were a result of cervical intervertebral disk disease.

An additional 5 dogs were reexamined because of signs potentially consistent with recurrent lumbar pain. Results of neurologic and musculoskeletal examinations were unremarkable, but radiographs of the thoracolumbar area were obtained, and myelography was performed to rule out compression of the thoracolumbar spinal cord. In all 5 dogs, disk spaces that had undergone ablation appeared to be narrower than normal, as would be expected, but there was no evidence of compression of the spinal cord. All dogs responded to medical treatment consisting of cage rest and oral administration of a nonsteroidal anti-inflammatory drug for 7 to 14 days.

One dog developed diskospondylitis at 2 sites (L1-2 and L3-4) that had been ablated 7 weeks previously. The dog was initially reexamined because of a 2-week history of signs of lumbar pain. Treatment included cage rest and oral administration of nonsteroidal anti-inflammatory drugs and appropriate antimicrobials. Signs resolved within 2 weeks, and there was radiographic evidence of fusion of the involved vertebral bodies 5 weeks later. The owner reported that the dog did not have any additional recurrences during a 52-month follow-up period.

The final 9 dogs that were reexamined were confirmed ( $n = 8$ ) or assumed (1) to have had a recurrence of a thoracolumbar disk herniation at a site that had previously been ablated. Four of these 9 had had 2 episodes of thoracolumbar disk disease prior to undergoing PLDA, but all 4 had been free of signs for at least 2 weeks before the procedure. The remaining 5 dogs had had 1 episode of thoracolumbar disk disease prior to undergoing PLDA.

One of the 8 dogs confirmed to have had a recurrence of thoracolumbar disk herniation at a site that had been ablated had undergone hemilaminectomy

prior to undergoing PLDA. The other 7 had been treated medically for episodes of thoracolumbar disk disease prior to undergoing PLDA. Time from PLDA to recurrence of thoracolumbar disk disease ranged from 3 to 52 months (mean, 15.1 months). All 8 developed hind limb paresis or paralysis but retained superficial and deep pain perception. Myelography revealed a compressive lesion caused by a herniated intervertebral disk. In all 8 dogs, the herniated disk that caused the compressive lesion was retrospectively documented as being calcified at the time of PLDA.

A hemilaminectomy was performed on all 8 dogs to remove extruded disk material. Most of the disk material removed from the spinal canal contained carbonized particles in the calcified nucleus pulposus. All 8 dogs recovered without complications and were ambulating normally within 8 weeks. None have had additional recurrences with follow-up intervals ranging from 6 months to 5 years. Computed tomography was performed at the time of recurrence of thoracolumbar disk extrusion in 1 of these dogs, and a radiolucency in the vertebral end plates adjacent to a laser ablation site was evident (Fig 1). The dog did not develop any complications associated with this radiolucency.

The dog that was assumed to have had a recurrence of thoracolumbar disk herniation at a site that had previously been ablated had developed hind limb paralysis 2 months after undergoing PLDA. However, the owner was unable to return the dog to the veterinary teaching hospital for examination, and the dog was euthanized by the referring veterinarian following an examination. Although a necropsy was not performed, it was considered likely that the dog had had a recurrence of thoracolumbar disk extrusion.

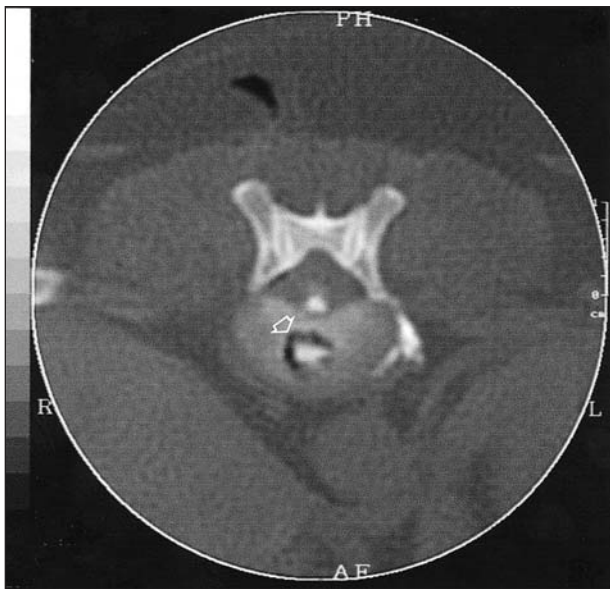


Figure 1—Transverse computed tomographic image of the T11-12 intervertebral disk space and cranial endplate of the T12 vertebral body in a mixed-breed dog that had undergone percutaneous disk ablation with a holmium-yttrium-aluminum-garnet laser 4.5 years earlier. Notice the radiolucency (open arrow) within the subchondral bone of the cranial endplate of the vertebral body.

## Discussion

During PLDA, laser energy from the Ho:YAG laser results in vaporization, coagulation, and shrinkage of the nucleus pulposus.<sup>2,5</sup> Some vaporized material escapes in the laser plume that exits through the lumen of the spinal needle. Experimental studies have shown that the therapeutic effectiveness of laser discectomy in humans is due primarily to a reduction in the intradiskal pressure.<sup>6-8</sup> In dogs, however, the effectiveness of PLDA is more likely due to removal and coagulation of the nucleus pulposus by photothermal vaporization. The ablative process involves vaporization of the water content of the nucleus pulposus and coagulation of collagen in the disk itself.<sup>2,5,9,10</sup> As with surgical fenestration, ablated disk spaces are narrower than are nonablated disk spaces.<sup>11</sup>

Breed, sex, and age distributions of dogs with thoracolumbar intervertebral disk disease in the present study were similar to distributions in previous reports.<sup>12,13</sup> The intervertebral disks selected for PLDA were the same as those selected for surgical fenestration, except that the L4-5 and L5-6 disks were not ablated. These 2 disks were not included in the current clinical protocol because they were not part of the initial investigation designed to prove safety and efficacy of the ablation procedure.<sup>1,2</sup> The prevalence of disk herniation at these sites is also reported to be lower, and a surgical approach to these disks may cause postoperative complications as a result of iatrogenic trauma to closely related anatomic structures.<sup>4,12-15</sup>

Laser ablation of thoracolumbar intervertebral disks offers an advantage over surgical removal or fenestration in dogs, because it is a minimally invasive technique that has been associated with low morbidity and complication rates.<sup>1,4</sup> However, perioperative and long-term neurologic and non-neurologic complications are still possible. For dogs included in the present study, the only observed intraoperative complication was development of pneumothorax in 1 dog. Pneumothorax has also been reported<sup>4</sup> to be a complication of surgical fenestration of thoracolumbar intervertebral disks through a dorsolateral approach.

A localized abscess developed at a needle insertion site in 1 dog in the present study and was most likely a result of contamination during the ablation procedure. The problem resolved with local treatment; however, considering the potential adverse effects of abscess formation, taking all possible steps to avoid this complication is advised. In particular, aseptic preparation of the procedure site is essential. In addition, care must be taken during insertion of the spinal needles and repeated placement of the sterile laser fiber through the needle lumen. Both superficial and deeper tissues, including the disks, are subject to potential contamination and resulting infection.

In human patients undergoing PLDA, postablation diskitis has been identified and is presumed to be related to skin contamination.<sup>16</sup> Signs typically do not develop until some time after the procedure, and definitive diagnosis requires bacterial culture of an aspirate of the disk site. However, a presumptive diagnosis can be made on the basis of results of radiography, computed tomography, or magnetic resonance

imaging.<sup>16</sup> In the dog with diskospondylitis in the present study, we believe the infection was related to the introduction of bacterial organisms into the affected sites during percutaneous needle insertion. The dog had a history of primary idiopathic seborrhea (seborrhea oleosa) with secondary bacterial folliculitis. Prior to admission for PLDA, the skin condition had responded to medicated baths and antimicrobial administration. At the time of radiographic diagnosis of diskospondylitis, bacterial culture of urine and blood samples did not yield any growth, and the dog was seronegative for antibodies to *Brucella canis*. A bactericidal antimicrobial (clindamycin) was administered on the basis of the presumption that the infection was caused by a *Staphylococcus* species. Successful treatment precluded further diagnostic testing, such as aspiration and culture. Considering the circumstances of this case, all dogs with a history of, or clinical signs compatible with, bacterial infection involving the skin, urinary bladder, or gingiva are now given appropriate antimicrobial and adjunctive treatment before PLDA is performed. The potential for development of diskospondylitis secondary to the photothermal changes that occur with disk ablation and the possible introduction of microorganisms during the percutaneous approach highlights the necessity for strict aseptic technique.

Owners of 64 of 262 (24.4%) dogs in the present study reported that their dogs had signs of lumbar pain or muscle spasms associated with needle insertion sites following PLDA. Other than the dog that developed an abscess at a needle insertion site, these signs were temporary and resolved in 5 to 7 days. Treatment consisted of exercise restriction and oral administration of nonsteroidal anti-inflammatory drugs. Although PLDA is minimally invasive, inflammatory responses can be expected at the multiple needle insertion sites.

Three of the 272 dogs in the present study had proprioceptive deficits after undergoing PLDA. Two of these dogs had not had any signs of thoracolumbar disk disease for at least 1 month prior to the procedure and recovered within 1 week with medical treatment, which included cage confinement in the hospital. The third dog had a more recent history of signs of back pain and proprioceptive deficits, but signs had not been evident for at least 1 week prior to PLDA. Immediately following PLDA, severe hind limb paresis was observed, and the dog underwent hemilaminectomy at T12-13 within a week after undergoing PLDA. This dog was extremely small (3 kg [6.6 lb]), and percutaneous placement of needles into the T10-11, T11-12, and T12-13 intervertebral disks was subjectively considered by the interventional radiologist to be more difficult than usual. However, the radiologist indicated that although needle insertion took longer than usual, he was confident that neither the spinal cord nor the nerve roots had been traumatized. These cases emphasize that the percutaneous method for needle insertion required for PLDA is technically difficult, even for experienced interventional radiologists. Individuals contemplating performing this procedure should acquire adequate training prior to performing it on clinical cases.

Another reason besides iatrogenic trauma must also be considered as a potential cause of the postablation neurologic complications in these 3 dogs. Because of engineering considerations, commercially available, solid-state Ho:YAG lasers used for medical applications must operate in a pulsed mode and, therefore, induce both photothermal and photomechanical effects.<sup>12,17</sup> The photothermal effects are of primary importance in intervertebral disk ablation.<sup>2,5,17</sup> In contrast, photomechanical effects can cause acoustical sledgehammer-type effects that can potentially cause further protrusion or extrusion of the nucleus pulposus. Because of this, the protocol for Ho:YAG laser disk ablation was changed at our institution after the first 22 dogs were treated. In particular, dogs with paresis or signs of recurrent back pain were required to be treated with cage rest and to have not received any steroidal anti-inflammatory drugs for a minimum of 2 to 4 weeks before undergoing PLDA to permit stabilization by the attendant inflammatory response and fibrosis of an unstable disk after acute herniation.<sup>18</sup> Following institution of this policy, coupled with the requirement that dogs be free from signs of pain and neurologic abnormalities (or have stable neurologic abnormalities) for the same period, no other dogs have developed acute postablation neurologic complications at our institution.

The photomechanical effect produced by the Ho:YAG laser is also known as the Moses or cavitation effect and has been reported to induce vapors in adjacent tissues because of an expanding vapor cavity and subsequent laser pulse-induced stresses.<sup>12,17</sup> One dog in the present study that underwent computed tomography 4.5 years after PLDA had radiolucencies in the vertebral endplates of the T11-12 disk space. It is possible that these lesions were caused by the photomechanical effects of the Ho:YAG laser. However, similar postablation subchondral abnormalities in human patients are believed to be caused by photothermal energy.<sup>16</sup> As in people,<sup>16</sup> the subchondral changes observed in this dog were not associated with clinical abnormalities.

Although the laser energy parameters we used were consistently effective, variations in ablation efficiency of the nucleus pulposus of each disk were possible because of differences in the laser-tissue interaction.<sup>12,17,19</sup> Such differences result from interactions of the laser wavelength, the laser energy parameters, and the optical absorption characteristics of the disk material. Thus, age-related degenerative or metaplastic (calcification) changes of the nucleus pulposus could alter the laser-tissue interaction.<sup>19,20</sup> In all 8 dogs in which a recurrence of lumbosacral disk disease was confirmed, the involved disk appeared calcified on radiographs obtained prior to PLDA. Further studies are needed on the potential variation in laser energy necessary for adequate ablation of degenerated disks, particularly calcified disks.

Five dogs in the present study were reexamined because of signs of recurrent lumbar pain reported by their owners. Neurologic, radiographic, and myelographic evaluations did not reveal any abnormalities, and we were unable to attribute the reported recurrence of lumbar pain to protrusion or extrusion of the nucleus pulposus at an ablated disk site.

Overall, 198 of 262 (75.6%) owners reported that their dogs improved immediately after undergoing PLDA, despite the fact that dogs were considered candidates for PLDA only if they were free from signs of thoracolumbar disk disease. Nevertheless, some owners did comment that their dogs seemed more active and less apprehensive during exercise almost immediately after the procedure. Although such statements must not be relied on too heavily, immediate relief of lower back pain has been stated as a benefit of PLDA in humans. In human patients, the decrease in intradiskal pressure associated with laser ablation is believed to decrease compression of associated nerve ganglia,<sup>6,8</sup> which in turn increases intraneural blood flow and restores the supply of oxygen and other nutrients to the nerve tissue.<sup>21</sup> Similarly, it has been suggested that in dogs with diskogenic pain, fenestration may alleviate clinical signs.<sup>22,23</sup>

From the telephone survey, 49 (18.7%) owners reported that > 4 weeks after the PLDA procedure, their dogs had clinical signs attributable to orthopedic, soft-tissue, or neurologic disease. Twenty-seven of these dogs were reexamined, while 22 recovered completely following a controlled period of rest at home. It was not determined whether the dogs that recovered at home did in fact have a minor recurrent episode of disk disease. Additional diagnostic evaluation with more stringent inclusion criteria, such as myelographic or computed tomographic imaging evidence, would have been appropriate.

Whether ablation of the nucleus pulposus with a laser or removal through surgical fenestration is truly an effective method of preventing subsequent thoracolumbar disk herniation is still unclear. Brown et al<sup>24</sup> suggested that fenestration was unnecessary if appropriate decompressive surgery was performed, because extrusion of an adjacent disk following treatment of an extruded or protruded disk was rare. Thus, the authors recommended laminectomy and removal of the single offending disk, rather than prophylactic fenestration of all disks. In the present study, 16 dogs that underwent hemilaminectomy for decompression of an extruded or protruded disk subsequently underwent PLDA. One of these animals required a second decompressive surgery at another thoracolumbar disk site even after laser ablation, suggesting that in some dogs, multiple disks may be involved in recurrent episodes of thoracolumbar disk disease.

Because disk fenestration is often performed in conjunction with a decompressive procedure in dogs with intervertebral disk disease, determining the recurrence rate in dogs that have undergone fenestration alone is difficult. A few authors<sup>25-28</sup> have recommended fenestration for dogs with acute, severe neurologic signs (paresis or paralysis), rather than decompression, but this is contrary to the recommendations of most neurologists and surgeons. Accordingly, surgical fenestration to reduce the risk of recurrence of thoracolumbar disk disease remains controversial.<sup>28</sup> As mentioned previously, PLDA is not indicated as a therapeutic procedure for dogs with acute, severe disk protrusions or extrusions. However, only 9 of 262 (3.4%) dogs in the present study developed hind limb paresis or paralysis

following PLDA, and this recurrence rate was less than that reported for other prophylactic surgical fenestration procedures.<sup>4,25,28-31</sup>

The simplicity and apparent safety of PLDA make it a potentially attractive adjunctive treatment for dogs with thoracolumbar disk disease. However, obvious limitations will prevent the use of this technique in most veterinary practices, including the cost of the Ho:YAG laser and the fluoroscopic equipment required for verification of needle placement.

Results of the present study suggest that percutaneous ablation with a Ho:YAG laser of the thoracolumbar disks in dogs with thoracolumbar disk disease may help prevent future disk protrusions or extrusions. Overall, owners were pleased with the outcome of the procedure. However, additional studies are needed to determine how frequently thoracolumbar disk herniation occurs at multiple sites and the recurrence rates of neurologic signs following medical treatment and decompressive surgery without prophylactic disk fenestration or ablation.

<sup>a</sup> Monoject spinal needle (No. 8881, diamond point), Sherwood Medical, St Louis, Mo.

<sup>b</sup> Model 1320 320-micron fiber optic, New Star Lasers, Roseville, Calif.

<sup>c</sup> Model NS 1500, New Star Lasers, Roseville, Calif.

<sup>d</sup> Payton ME, Department of Statistics, Oklahoma State University, Stillwater, Okla: Personal communication, 2002.

## References

1. Dickey DT, Bartels KE, Henry GA, et al. Use of the holmium yttrium aluminum garnet laser for percutaneous thoracolumbar intervertebral disk ablation in dogs. *J Am Vet Med Assoc* 1996; 208:1263-1267.
2. Fry TR, Bartels KE, Henry GA, et al. Holmium:YAG discectomy in dogs. A pilot study. *Prog Biomed Opt (SPIE)* 1994;2128F: 554-560.
3. Bartels KE. Lasers in veterinary medicine—where have we been and where are we going? *Vet Clin North Am Small Anim Pract* 2002;32:495-515.
4. Bartels KE, Creed JE, Yturraspe D. Complications associated with the dorsolateral muscle-separating approach for thoracolumbar intervertebral disk fenestration in the dog. *J Am Vet Med Assoc* 1983; 183:1081-1083.
5. Gotlob C, Kopchok GE, Peng S, et al. Holmium:YAG laser ablation of human intervertebral disc: preliminary evaluation. *Lasers Surg Med* 1992;12:86-91.
6. Choy DSJ, Case RB, Fielding W, et al. Percutaneous laser nucleolysis of lumbar discs. *N Engl J Med* 1987;317:771-772.
7. Casper GD, Hartman VL, Mullins LL. Results of a clinical trial of the holmium:YAG laser in disc decompression utilizing a side-firing fiber: a two-year follow-up. *Lasers Surg Med* 1996;19:90-96.
8. Choy DSJ. Rapid correction of neurologic deficits by percutaneous laser disc decompression (PLDD). *J Clin Laser Med Surg* 1996;14:13-15.
9. Phillips JJ, Kopchok GE, Peng S, et al. MR imaging of Ho:YAG laser discectomy with histologic correlation. *J Magn Reson Imaging* 1993;3:515-519.
10. Min K, Hansjorg L, Zweifel K. Quantitative determination of ablation in weight of lumbar intervertebral discs with holmium:YAG laser. *Lasers Surg Med* 1996;18:187-190.
11. Dallman MJ, Moon ML, Giovannitti-Jensen A. Comparison of the width of the intervertebral disk space and radiographic changes before and after intervertebral disk fenestration in dogs. *Am J Vet Res* 1991;52:140-145.
12. Horlein BF. Intervertebral disc disease. In: Oliver JE, Horlein BF, Mayhew IG, eds. *Veterinary neurology*. Philadelphia: WB Saunders Co, 1987;321-341.

13. Gage ED. Incidence of clinical disc disease in the dog. *J Am Anim Hosp Assoc* 1975;11:135–138.
14. Oliver JE, Lorenz MD, Kornegay JN. Pelvic limb paresis, paralysis, or ataxia. In: Oliver JE, Lorenz MD, Kornegay JN, eds. *Handbook of veterinary neurology*. 3rd ed. Philadelphia: WB Saunders Co, 1997;129–172.
15. Yturraspe DG, Lumb WV. A dorsolateral muscle-separating approach for thoracolumbar intervertebral disk fenestration in the dog. *J Am Vet Med Assoc* 1973;162:1037–1040.
16. Cvitanic OA, Schimandle JS, Casper GD, et al. Subchondral marrow changes after laser discectomy in the lumbar spine: MR imaging findings and clinical correlation. *Am J Radiol* 2000;174:1363–1369.
17. Buchlet M, Schlangmann B, Schmolke S, et al. High power Ho:YAG laser ablation of intervertebral discs: efficiency of ablation rates and temperature profile. *Lasers Surg Med* 1995;16:179–183.
18. Simpson ST. Intervertebral disc disease. *Vet Clin North Am Small Anim Pract* 1992;22:889–897.
19. Onik GM, Helms C. Nuances in percutaneous discectomy. *Radiol Clin North Am* 1998;36:523–532.
20. Bray JP, Burbridge HM. The canine intervertebral disk. Part two: degenerative changes—nonchondrodystrophoid versus chondrodystrophoid disks. *J Am Anim Hosp Assoc* 1998;34:135–144.
21. Rydevik B, Brown MD, Lundborg G. Pathoanatomy and pathophysiology of nerve root compression. *Spine* 1984;9:7–14.
22. Toombs JR, Bauer MS. Intervertebral disc disease. In: Slatter D, ed. *Textbook of small animal surgery*. 2nd ed. Philadelphia: WB Saunders Co, 1993;1070–1087.
23. Seim HB. Surgery of the thoracolumbar spine. In: Fossum TW, ed. *Small animal surgery*. St Louis: Mosby Year Book Inc, 1997;1101–1130.
24. Brown NO, Helpfrey ML, Prata RG. Thoracolumbar disk disease in the dog: a retrospective analysis of 187 cases. *J Am Anim Hosp Assoc* 1977;13:665–672.
25. Butterworth SJ, Denny HR. Follow-up study of 100 cases with thoracolumbar disc protrusions treated by lateral fenestration. *J Small Anim Pract* 1991;32:443–447.
26. Denny HR. The lateral fenestration of thoracolumbar disc protrusions: a review of 30 cases. *J Small Anim Pract* 1978;19:259–266.
27. Wheeler SJ, Sharp NJH. Thoracolumbar disc disease. In: Wheeler SJ, Sharp NJH, eds. *Small animal spinal disorders, diagnosis and surgery*. London: Mosby-Wolfe, 1994;85–108.
28. Coates JR. Intervertebral disk disease. *Vet Clin North Am Small Anim Pract* 2000;30:77–110.
29. Knapp DW, Pope ER, Hewett JE, et al. A retrospective study of thoracolumbar disk fenestration in dogs using a ventral approach: 160 cases (1976 to 1986). *J Am Anim Hosp Assoc* 1990;26:543–549.
30. Levine SH, Caywood DD. Recurrence of neurological deficits in dogs treated for thoracolumbar disk disease. *J Am Anim Hosp Assoc* 1984;20:889–894.
31. Davies JV, Sharp NJH. A comparison of conservative treatment with fenestration for thoracolumbar disc disease in the dog. *J Small Anim Pract* 1983;24:721–729.