

# Jejunioleal anastomosis following small intestinal resection in horses: seven cases (1999–2001)

Dawn A. Loesch, DVM; Dwayne H. Rodgerson, DVM, MS, DACVS; Gregory R. Haines, DVM; Bruce C. Watt, DVM, DACVS

**Objective**—To report the postoperative outcome in horses undergoing jejunioleal anastomosis performed with a 2-layer simple continuous technique.

**Design**—Retrospective study.

**Animals**—7 horses.

**Procedure**—Information regarding signalment, clinical signs, findings at surgery, and postoperative complications was obtained from medical records of horses that underwent exploratory ventral midline celiotomy, small intestinal resection, and jejunioleal anastomosis to correct various small intestinal strangulating lesions. Follow-up information was obtained via telephone conversations with owners or trainers.

**Results**—Six males and 1 female of various breeds aged 10 months to 27 years and weighing 312 to 785 kg (686.4 to 1,727 lb) were included. The most common complications were mild to moderate tachycardia and mild to moderate signs of abdominal pain. Two horses developed incisional infections and soft, fluctuant swelling at the incision site following resolution of the infection. Follow-up time ranged from 7 to 17 months after surgery. Owners reported no further colic episodes and no diet change necessary following surgery. All horses had returned to their intended level of use.

**Conclusions and Clinical Relevance**—Advantages to the jejunioleal technique include maintaining the normal ileocecal valve and a postoperative recovery period similar to that described following other small intestinal anastomoses. Jejunioleal anastomosis is a viable alternative to ileal bypass. This technique appears to result in a postoperative complication rate similar to that reported following jejunojejunostomy procedures. (*J Am Vet Med Assoc* 2002;221:541–545)

Strangulating small intestinal lesions represent an important cause of equine colic in which surgical correction is required. Small intestinal disorders reportedly account for 27 to 64% of all referred colic cases,<sup>1,2</sup> and of this same group, 55 to 84% involve a strangulating lesion.<sup>1,3,4</sup> Within this group of strangulating lesions, up to 46% involved the ileum.<sup>2</sup>

Small intestinal strangulation requires surgical resection and anastomosis to correct the lesion. Various methods of anastomosis have been described, depending on the portion of intestine

affected by the primary lesion. When any portion of the ileum is resected following involvement in a strangulating lesion, creation of a jejunocecal anastomosis has been recommended.<sup>5,7</sup> However, horses undergoing jejunocecal anastomosis may be at increased risk of postoperative complications, compared with those undergoing jejunojejunostomy, because the ileocecal valve is bypassed and dissimilar intestinal segments must immediately function as a unit.<sup>5</sup> When sufficient healthy ileum is present following resection, jejunioleal anastomosis may be performed. Jejunioleal anastomosis reportedly results in a higher rate of postoperative complications, especially postoperative obstruction at the anastomosis site.<sup>5</sup> The apposition of the thick-walled, muscular ileum to the relatively thin-walled jejunum has been theorized to result in postoperative obstruction. It is hypothesized that the distal jejunum used in the anastomosis may not have the muscular strength to assist in overcoming intraluminal pressure within the cecum, preventing complete emptying of distal small intestinal contents into the cecum and resulting in obstruction at the anastomosis.<sup>8</sup> To our knowledge, successful use of jejunioleal anastomosis following small intestinal resection in a group of horses has not been described in the literature.

Techniques for small intestinal anastomosis include end-to-end, side-to-side, end-to-side, and functional end-to-end using either a hand-sewn or stapled method, depending on the location and extent of affected intestine and surgeon preference.<sup>5,7,9-11</sup> The ideal technique should minimize vascular compromise at the anastomosis site and adequately appose the submucosa. However, the anastomosis closure method should not promote adhesions nor result in intraluminal stricture formation.<sup>6</sup> Thus, choices between available techniques of small intestinal anastomosis often represent a compromise. Hand-sewn, end-to-end small intestinal anastomoses have most often been performed with a 1- or 2-layer inverting suture pattern, which minimizes adhesion formation at the anastomosis site while securely apposing the submucosal layers.<sup>5,9</sup> A 2-layer simple continuous suture pattern had been previously used by 1 of the authors (DHR) to appose jejunojejunal anastomoses with good clinical outcome. To our knowledge, this technique has not been previously reported.

The purposes of the study reported here were to report the postoperative outcome of 7 horses undergoing a small intestinal resection and a hand-sewn, end-to-end jejunioleal anastomosis using 2 simple continuous hemicircumferential suture patterns and to evaluate short-term complications.

From the Department of Large Animal Clinical Sciences, College of Veterinary Medicine, University of Florida, Gainesville, FL 32610. Dr. Watt's present address is Markham, ON, Canada. Dr. Rodgerson's present address is Hagyard-Davidson-McGee Associates, 4250 Ironworks Pike, Lexington, KY 40511. Address correspondence to Dr. Loesch.

## Criteria for Selection of Cases

Medical records of horses admitted to the University of Florida Veterinary Medical Teaching Hospital were reviewed. Horses with strangulating small intestinal lesions treated by jejunioileal anastomosis between July 1999 and June 2001 were included in the study.

## Procedures

The following information was obtained from the medical records: signalment, clinical signs, surgical lesion, and postoperative complications. Telephone conversations with owners or trainers yielded follow-up information including incisional complications that developed after hospital discharge, occurrence of colic episodes, necessary diet changes following surgery, and whether the horse had returned to its previous activity.

**Surgical procedure**—All horses were anesthetized and positioned in dorsal recumbency. A routine ventral midline approach was used in all cases. Following identification and reduction or exteriorization of the strangulating lesion, the affected intestine was isolated from the abdomen with saline (0.9% NaCl)-soaked towels or laparotomy sponges. Strangulated small intestine was then resected as described elsewhere.<sup>3-7</sup>

The anastomosis was accomplished with size 2-0 or 3-0 polydioxanone.<sup>a</sup> The mucosa was apposed with a simple continuous suture pattern starting at the mesenteric edge; a long tag of suture was left after knot tying to act as a stay suture. When the pattern approached the antimesenteric surface, the simple continuous pattern was tied but not cut. The mucosal closure was continued on the opposite side of the intestine until the mesenteric surface was reached where the suture was tied for the third time. A similar method was used to appose the seromuscular layer to complete the anastomosis. Long suture tags used as modified stay sutures were cut at the serosal surface. The mesenteric defect was then closed with size 2-0 or 3-0 polydioxanone<sup>a</sup> in a simple continuous suture pattern to complete the anastomosis (Fig 1). The anastomosis site and intestine were copiously lavaged with sterile saline solution

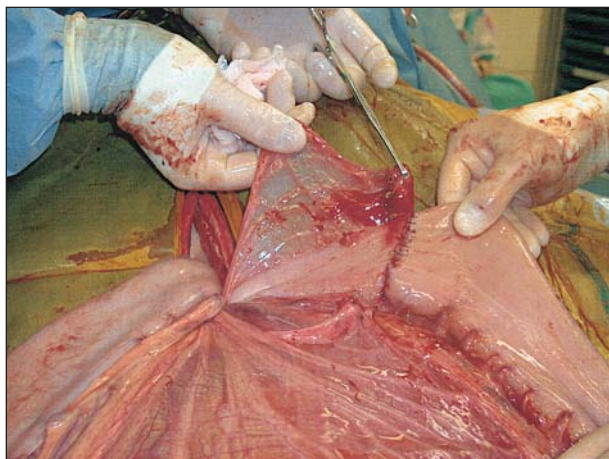


Figure 1—Photograph of a completed jejunioileal anastomosis in a horse. Notice the sharp demarcation between the jejunum and ileum, as evidenced by abrupt ending of the antimesenteric fold of the ileum at the level of the anastomosis.

and examined for leakage before being returned to the abdomen. Ventral abdominal incisions were closed routinely in 3 layers. The linea alba was apposed with size 3 polyglactin 910<sup>b</sup> in a simple continuous suture pattern. Subcutaneous tissue was closed with size 2-0 polydioxanone<sup>a</sup> in a simple continuous suture pattern. Skin edges were apposed in a continuous horizontal mattress pattern with size 0 or 2-0 poliglecaprone 25.<sup>c</sup>

Horses received potassium penicillin G (22,000 U/kg [10,000 U/lb], IV, q 6 h) and gentamicin (6.6 mg/kg [3 mg/lb], IV, q 24 h) immediately prior to surgery and for 3 to 5 days after surgery. Flunixin meglumine (1.1 mg/kg [0.5 mg/lb], IV, q 12 h) was administered before surgery and continued for 3 to 5 days following surgery. Horses were treated with sodium heparin (44 U/kg [20 U/lb], IV or SC, q 8 h) for 1 to 4 days after surgery. One horse received a bolus of 99% dimethyl sulfoxide (500 ml in 5 L of balanced polyionic fluids, IV) in the first 24 hours after surgery. One horse also received butorphanol tartrate (0.044 mg/kg [0.02 mg/lb], IM, q 2 h) for the first 6 hours following surgery. Intravenous fluid therapy was continued after surgery as needed on the basis of serial PCV and total plasma protein concentrations. Horses were allowed access to water within 12 to 24 hours after surgery. Short periods of grazing or small amounts of food were offered within 12 to 36 hours after surgery or as soon as the patient's clinical condition allowed. Initial feeding protocols included 5-minute periods of grazing, complete pelleted feed, or handfuls of alfalfa or timothy hay offered every 4 hours. The amount of food was gradually increased until the horse had access to free choice hay or was discharged from the hospital.

## Results

Seven horses were included in the study. Breeds represented included Thoroughbred (n = 1), Warmblood (2), American Quarter Horse (1), Belgian (1), and Arabian (2). Sex distribution included 3 stallions, 3 geldings, and 1 juvenile female. Ages ranged from 10 months to 27 years (mean, 14.5 years) and body weights ranged from 312 to 785 kg (686.4 to 1,727 lb; mean, 522 kg [1,148.4 lb]). Six horses were referred for emergency examination of colic, while 1 horse was referred to the veterinary hospital for evaluation of umbilical swelling. Two horses with signs of abdominal pain and the horse with umbilical swelling were hospitalized for 8 to 20 hours, during which time monitoring indicated deterioration of clinical condition necessitating surgical intervention. The remaining 4 horses were taken to surgery immediately following initial examination and routine colic evaluation.

Exploratory ventral midline celiotomy was performed on all horses. Strangulation of the proximal ileum and distal jejunum was diagnosed in all horses. Causes of the strangulation included inguinal herniation (3 horses), parietal hernia (Richter's hernia; 1), strangulating lipoma (1), epiploic foramen entrapment (1), and ileocecal fold rent (1). Length of resected small intestine varied from 2 to 25 ft (mean, 5.6 ft). Ileal resection sites varied from the most proximal edge of the antimesenteric fold of the ileum to those performed at the level of the abdominal incision, repre-

senting a range of 10 to 70% of its total length. Minimal to no abdominal contamination was encountered during all procedures. Two horses with inguinal hernias were hemicastrated on the affected side only, with the external inguinal ring and scrotal skin incision closed primarily. The third horse with an inguinal hernia was bilaterally castrated and scrotal incisions were left open to drain. Mean duration of hospitalization was 8 days (range, 5 to 12 days).

The most common complications were mild to moderate tachycardia and mild to moderate signs of abdominal pain (lying down or pawing). Tachycardia developed after surgery in 3 horses, continued for 24 to 72 hours following surgery, and resolved without specific medical treatment beyond the routine postoperative colic management described. Three to 5 days after surgery, mild to moderate signs of abdominal pain developed in 3 horses, which was successfully managed by administration of either flunixin meglumine (0.5 to 1.1 mg/kg [0.22 to 0.5 mg/lb], IV) or xylazine hydrochloride (0.2 to 0.4 mg/kg [0.09 to 0.18 mg/lb], IV). One horse developed ileus and required gastric decompression every 2 to 4 hours for the first 72 hours after surgery.

Follow-up time ranged from 7 to 17 months (mean, 13 months) following surgery and information was available for all 7 horses. All horses were alive at the time of follow-up and all had been returned to the normal diet they had been offered prior to surgery. One horse was reported to have mild signs of abdominal pain for the first 3 days following discharge. The owner of this horse elected to start treatment for gastric ulcers at that time, after which no further signs of colic were noticed. None of the remaining horses in this study were reported to have episodes of colic following discharge from the hospital. Two horses developed incisional drainage, which resolved with local wound treatment. Owners of both horses reported mild, intermittent, fluctuant swelling at the incision site following resolution of the infection. All horses had been returned to the desired level of work including trail riding, driving, and dressage. One hemicastrated stallion had been successfully used for breeding with adequate conception rates.

## Discussion

Results suggest that jejunioleal anastomosis is a viable alternative to ileal bypass. It has been reported<sup>8,9</sup> that jejunioleal anastomoses may result in frequent short-term postoperative complications, primarily because of ileus and obstruction at the anastomosis site resulting from the differences in intestinal lumen size and wall thickness of the jejunum and ileum. These anastomoses reportedly do not function as consistently as those performed between 2 segments of jejunum.<sup>5</sup> Our findings, however, contradict these statements in that all 7 horses of this study that underwent jejunioleal anastomosis had mild postoperative complications that may be expected following small intestinal surgery. The postoperative complications reported herein are similar to those reported in other studies of horses undergoing small intestinal resection and anastomosis.<sup>12,13</sup> Additionally, the single ileal blood supply

has been suggested to be insufficient to support anastomotic healing in this section of the intestinal tract, thereby increasing the risk of anastomotic failure.<sup>6,7,10</sup> Various lengths of ileum were resected during surgery on the horses in this study, requiring the anastomosis to depend on the remaining ileal blood supply. None of the horses of this study developed signs of dehiscence at the anastomosis site, suggesting that the ileal blood supply was adequate to support anastomotic healing.

As an alternative anastomosis technique when the ileum is involved in the strangulating lesion, jejunocostomy (to bypass the ileum) has been recommended.<sup>5,6</sup> However, the outcome following this technique is variable. One review of factors contributing to survival following small intestinal resection and anastomosis indicated that horses undergoing anastomosis of small intestine to the cecum had shorter survival times than those horses undergoing anastomosis of 2 segments of small intestine.<sup>12</sup> Horses in that report that underwent jejunocecal anastomosis had an approximately 20% survival rate 1 year after surgery. A substantial proportion of those horses undergoing jejunocostomy did not survive because they developed peritonitis secondary to leakage from the ileal stump. Those horses likely had extensive ileal involvement in the strangulating lesion, preventing complete resection of all affected tissue. In this situation, jejunioleal anastomosis as described in our study would not have been appropriate. A more recent report<sup>13</sup> describing the postoperative outcome following stapled small intestinal anastomoses indicated that horses having anastomosis of the small intestine to the cecum (especially without resection) have more favorable survival rates, compared with those that underwent anastomosis of 2 small intestinal segments. The group of horses undergoing jejunocecal anastomosis with resection had an estimated survival rate of 60% 1 year following surgery. Direct comparison between these 2 studies should be considered with caution, as differences in surgical technique and surgical findings among groups of horses may have influenced the different outcomes reported.

Compared with jejunojejunostomy procedures, jejunocecal anastomoses have also been reported to result in additional postoperative complications.<sup>5</sup> Similar to jejunioleal anastomoses, jejunocostomy places 2 dissimilar portions of the intestinal tract into apposition, requiring them to function as a unit. Jejunocostomy has the additional disadvantage of bypassing the ileocecal valve. This requires the jejunum to overcome intraluminal pressure within the cecum to empty small intestinal contents. Using remaining ileum in the anastomosis (as was performed in the horses in our study) maintains the normal distal small intestinal anatomy, especially the ileocecal valve.<sup>11</sup> This may have contributed to the uncomplicated postoperative recovery reported in our horses. One report<sup>13</sup> of outcome following stapled small intestinal anastomoses includes a group of horses that underwent jejunioleal anastomosis. Although postoperative complications were not described for each anastomotic group in that study, the long-term survival rate (1 year) for the horses that underwent jejunioleostomy was estimated to be 50%.



This is considerably lower than the survival rate for the horses in the study reported here. Differences in the anastomotic closure (stapled vs hand-sewn), anastomotic orientation (side-to-side or functional end-to-end vs end-to-end), and the most common surgical lesions identified in each group may have influenced the outcome, among other factors.

Closure options for small intestinal anastomoses include hand-sewn or stapled techniques and whether to perform an end-to-end or side-to-side procedure. The use of intestinal stapling devices has been reported to result in rapid healing because of the nonreactive nature of the stainless steel staples along the anastomosis and maintenance of blood flow resulting from the B-shaped configuration of the closed staple.<sup>6</sup> Disadvantages include the possibility of staples pulling or tearing from the anastomotic line from tension, inadequate closure of excessively thick tissue, and expense.<sup>6</sup> Hand-sewn anastomoses allow careful apposition of tissue layers and may decrease cost to the owner, as expensive abdominal stapling devices are not used. The hand-sewn technique described for the horses in this study was chosen to avoid the complications and expense of using intestinal stapling devices.

Side-to-side small intestinal anastomoses have been performed using hand-sewn or stapled techniques in isoperistaltic or antiperistaltic (functional end-to-end) directions. These approaches align segments of intestine in such a way that the physiologic polarity of the intestine is disrupted, with fewer migrating myoelectrical complexes actually crossing the anastomosis site.<sup>5</sup> End-to-end anastomoses return the intestine to a more normal physiologic state, compared with the side-to-side techniques.<sup>5</sup> Postoperative complications such as leakage secondary to inadequate overlapping of staple lines, anastomotic obstruction by edematous inverted mucosa, and intussusception from the anastomosis site have been reported following various side-to-side small intestinal anastomotic techniques.<sup>5</sup> These complications were not evident following the end-to-end anastomosis in the horses of our study.

Peritonitis and adhesions have been reported as the most common causes of death following small intestinal resection and anastomosis.<sup>12,13</sup> The degree of peritonitis present prior to surgery may influence postoperative outcome. Increased peritoneal protein concentration and WBC count create an environment in which a number of inflammatory mediators may be released.<sup>14</sup> When present before surgery, this altered biochemical environment may interfere with anastomotic healing and predispose the horse to intestinal adhesion formation. Oftentimes decreased intestinal motility is detected prior to surgery. When gastrointestinal ileus continues after surgery, it may necessitate a second exploratory celiotomy or euthanasia.<sup>15</sup> Additionally, when intestinal tract motility is decreased, 1 mechanical barrier to adhesion formation may be removed, creating an environment favorable for the formation of abdominal adhesions. Both preoperative peritonitis and ileus can be worsened by the inflammation caused during exploratory celiotomy in horses, especially if intestinal resection and anastomosis are necessary. Of the 7 horses

described in this study, 5 had peritoneal fluid collected by abdominocentesis. Of these 5, only 2 had evidence of mild peritonitis with slightly increased peritoneal protein concentrations and normal or mildly high WBC counts. The mild peritonitis in these horses may have contributed to their successful postoperative outcome.

Postoperative peritonitis and adhesion formation have been problematic in a variety of anastomotic techniques and closure approaches. Methods to close hand-sewn anastomoses include interrupted or continuous suture patterns that either appose or invert the intestinal layers. Efforts to reduce the occurrence of peritonitis and adhesions have resulted in the popularity of a 2-layer closure with a simple continuous mucosal layer followed by an inverting (Cushing or Lembert) pattern in the seromuscular layer.<sup>5,6,9,11</sup> Inverting suture patterns offer the advantage of burying the suture material and leaving less foreign material exposed to the abdomen, which is thought to reduce the formation of adhesions. However, inversion of the wound edges may result in intraluminal cuff formation, which may result in postoperative obstruction.<sup>6</sup> Additionally, inverting patterns poorly appose the tissue layers, which may result in delayed wound healing and a slower return to normal motility.<sup>6</sup> Appositional patterns (such as the simple continuous suture) have the advantage of improved apposition, which may decrease the likelihood of anastomotic leakage and secondary peritonitis. These patterns are also more effective at providing maximal luminal diameter, but have been suggested to be associated with increased incidence of postoperative adhesion formation.<sup>11</sup> To our knowledge, the use of a 2-layer, hemicircumferential simple continuous suture pattern for small intestinal end-to-end anastomosis has not been reported in the literature. A 2-layer closure was used in the horses of this study to ensure an adequate seal of the lumen to minimize peritoneal contamination secondary to leakage at the anastomotic site. In addition, this technique was technically easy and quickly performed. The initial simple continuous layer was placed within the mucosa, as has been commonly reported in 2-layer closures.<sup>5,7,9,11</sup> However, a second simple continuous layer was used in the seromuscular layer in an effort to reduce postoperative stricture and obstruction at the anastomosis site, especially given the supposed predisposition of jejunoileal anastomoses to these complications.<sup>5</sup> The follow-up results in the horses of this study suggest that this 2-layer simple continuous anastomotic technique evidently does not result in substantial postoperative intraluminal obstruction or abdominal adhesion formation. Additional work is necessary to determine characteristics of anastomotic healing, bursting strength, and incidence of adhesion formation or other complications following the use of this suture pattern for end-to-end small intestinal anastomoses.

The mild abdominal discomfort, moderate ileus, and incisional infections that developed in the horses described in this study are complications consistent with those reported in other studies evaluating outcome following small intestinal resection and anastomosis.<sup>12,13</sup> In 1 study,<sup>12</sup> the most common postoperative

complications (in descending order of frequency) included incisional drainage, dehiscence, herniation, peritonitis, adhesions, and ileus. Another report<sup>13</sup> indicated that diarrhea, colic, ileus, incisional drainage, and incisional infection were the most common complications in the immediate postoperative period.

<sup>a</sup>PDS II, Ethicon Inc, Somerville, NJ.

<sup>b</sup>Vicryl, Ethicon Inc, Somerville, NJ.

<sup>c</sup>Monocryl, Ethicon Inc, Somerville, NJ.

## References

1. Vachon AM, Fischer AT. Small intestinal herniation through the epiploic foramen: 53 cases (1987-1993). *Equine Vet J* 1995;27:373-380.
2. Kersjes AW, Bras GE, Németh F, et al. Results of operative treatment of equine colic with special reference to surgery of the ileum. *Vet Q* 1988;10:17-25.
3. Vatisas NJ, Snyder JR, Wilson WD, et al. Surgical treatment for colic in the foal (67 cases): 1980-1992. *Equine Vet J* 1996;28:139-145.
4. Phillips TJ, Walmsley JP. Retrospective analysis of the results of 151 exploratory laparotomies in horses with gastrointestinal disease. *Equine Vet J* 1993;25:427-431.
5. Freeman DE. Small intestine. In: Auer JA, Stick JA, eds. *Equine surgery*. 2nd ed. Philadelphia: WB Saunders Co, 1999; 249-252.
6. McIlwraith CW, Robertson JT. Surgery of the gastrointestinal tract. In: McIlwraith CW, Robertson JT, eds. *McIlwraith & Turner's equine surgery: advanced techniques*. 2nd ed. Baltimore: The Williams & Wilkins Co, 1998;327-341.
7. Robertson JT. Intestinal enterotomy, resection, and anastomosis. In: White NA, ed. *The equine acute abdomen*. Philadelphia: Lea & Febiger, 1990;261-268.
8. Freeman DE. Surgery of the small intestine. *Vet Clin North Am Equine Pract* 1997;13:261-301.
9. Pascoe JR, Peterson PR. Intestinal healing and methods of anastomosis. *Vet Clin North Am Equine Pract* 1989;5:309-333.
10. Edwards GB. Resection and anastomosis of small intestine: current methods applicable to the horse. *Equine Vet J* 1986;18:322-330.
11. Mueller POE, Allen DA. Instrumentation and techniques in equine gastrointestinal surgery. *Vet Clin North Am Equine Pract* 1996;12:207-233.
12. MacDonald MH, Pascoe JR, Stover SM, et al. Survival after small intestine resection and anastomosis in horses. *Vet Surg* 1989;18:415-423.
13. Fugaro MN, Coté NM. Survival rates for horses undergoing stapled small intestinal anastomosis: 84 cases (1988-1997). *J Am Vet Med Assoc* 2001;218:1603-1607.
14. Hardy J, Rakestraw PC. Postoperative care and complications associated with abdominal surgery. In: Auer JA, Stick JA, eds. *Equine surgery*. 2nd ed. Philadelphia: WB Saunders Co, 1999; 294-306.
15. Baxter GM, Broome TE, Moore JN. Abdominal adhesions after small intestinal surgery in the horse. *Vet Surg* 1989;18:409-414.