

What Is Your Diagnosis?

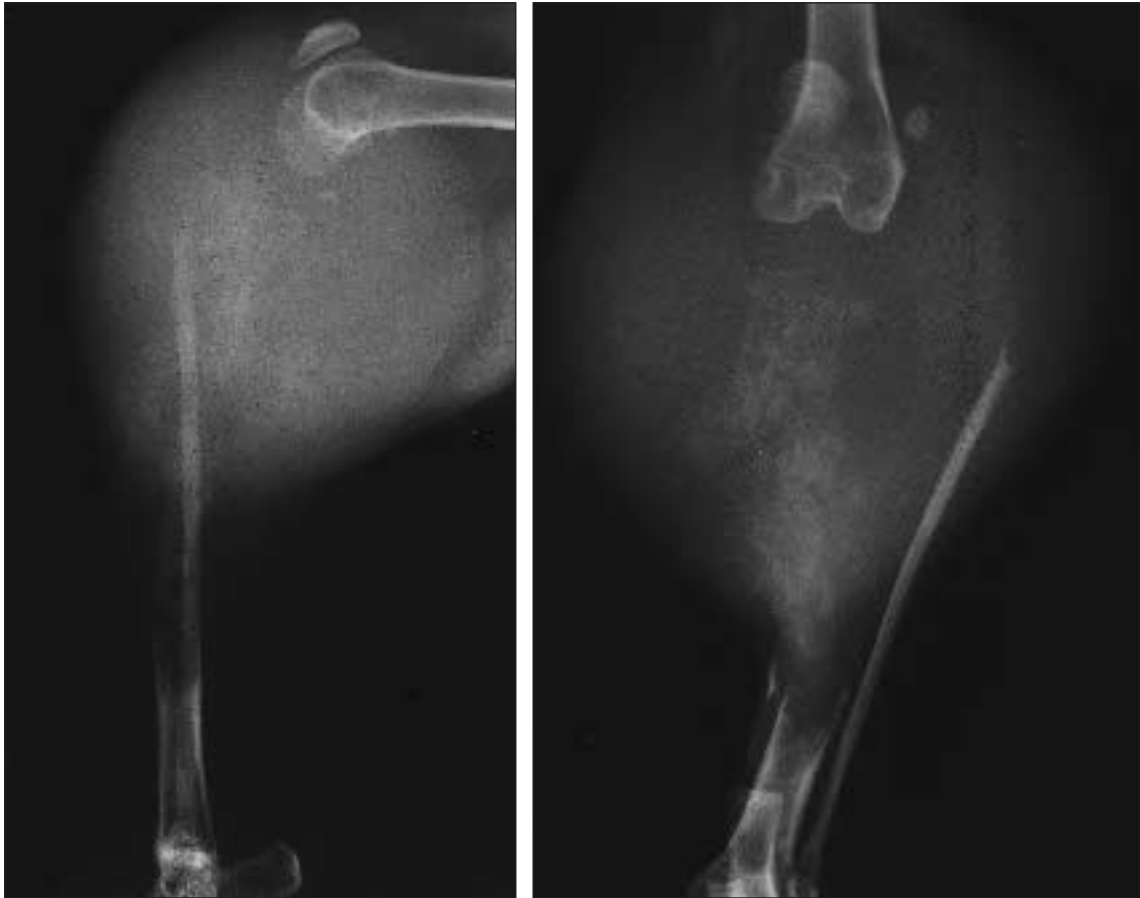


Figure 1—Lateral (left) and craniocaudal (right) radiographic views of the left stifle region of a 4.5-year-old cat with chronic left hind limb lameness.

History

A 4.5-year-old spayed female cat was admitted for evaluation of chronic left hind limb lameness. According to the owner, the lameness originally was mild with an acute onset and progressed to a severe intermittent non-weight-bearing lameness over a 3- to 4-month period. For several days prior to evaluation, the cat had been hiding, and the owner noticed that the left stifle region was large. On physical examination, the thigh muscles were severely atrophied, and the cat would not bear weight on the left hind limb. A firm swelling was evident extending from the stifle joint to the middiaphysis of the tibia. Signs of pain were elicited on palpation of this area. In addition, range of motion in the stifle joint was limited. Radiographs of the left hind limb were obtained (Fig 1).

Determine whether additional imaging studies are required, or make your diagnosis from Figure 1—then turn the page ▶

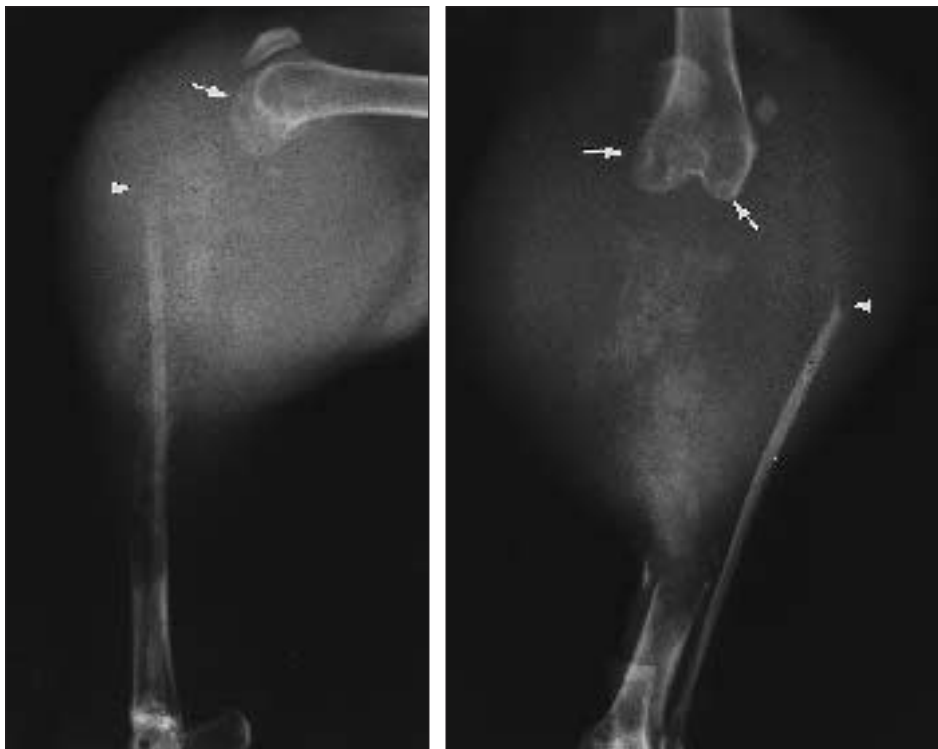


Figure 2—Same radiographic views as in Figure 1. Notice the severe osteolysis of the proximal two thirds of the tibia and associated soft-tissue swelling. The stifle joint is disarticulated, and the fibula is displaced cranially and laterally. Lysis of the head of the fibula (arrowheads) and radiolucencies within the femoral condyles (arrows) are also apparent.

Diagnosis

Radiographic diagnosis—Severe osteolysis of the proximal two thirds of the tibia with associated soft-tissue swelling (Fig 2).

Comments

Severe osteolysis and soft-tissue swelling were evident. The stifle joint was disarticulated, and the fibula was displaced cranially and laterally. Lysis of the fibular head and radiolucencies within the femoral condyles were also apparent (Fig 2). Differential diagnoses included primary soft-tissue tumor with secondary bony involvement or primary bone tumor with soft tissue involvement. Because of the severity of the lesion, we considered fungal or bacterial osteomyelitis less likely. Abnormalities were not detected on thoracic radiographs. On the basis of the radiographic appearance of the limb, amputation was recommended.

Histologic analysis of the amputated limb revealed normal bone obliterated by a cellular mass. Oval to fusiform highly anaplastic cells were arranged in broad sheets. In some regions, these cells formed pale eosinophilic material consistent with osteoid. Most of the tumor cells were found at the periphery of the mass, and more than half of the central tumor regions were necrotic. There was no evidence of tumor in the distal region of the femur. The diagnosis was high-grade osteosarcoma (OSA).

Parosteal and medullary OSA have been described in cats.¹⁻³ Medullary OSA is the more common form and develops predominantly in the tibia and femur.^{1,2,4} Radiographically, periosteal new bone proliferation is generally not apparent in affected cats.^{3,4} Instead,

tumors are typified by cortical bone destruction of varying severity.³

In cats, OSA are often large, slow-growing masses that may not elicit signs of pain on palpation but are associated with chronic lameness.³ The metastatic rate of appendicular OSA in cats at the time of diagnosis is between 5 and 10%.² Amputation is thus the treatment of choice for cats with appendicular OSA. In a previous study,⁴ amputation of the affected limb resulted in a 50% survival rate 64 months after surgery. Median survival time was 49 months for cats that died of OSA after amputation. However, in a more recent study,² median survival time was only 16.7 months after amputation or excisional biopsy.² The cat described in this report recovered well after amputation of the affected limb. Eight months after surgery, the owner reported that the cat was walking and otherwise appeared healthy.

1. Liu SK, Dorfman HD, Patnaik AK. Primary and secondary bone tumours in the cat. *J Small Anim Pract* 1974;15:141-156.

2. Heldmann E, Anderson MA, Wagner-Mann C. Feline osteosarcoma: 145 cases (1990-1995). *J Am Anim Hosp Assoc* 2000;36:518-521.

3. Turrel JM, Pool RR. Primary bone tumors in the cat: a retrospective study of 15 cats and a literature review. *Vet Radiol* 1982;23:152-166.

4. Bitetto WV, Patnaik AK, Schraeder SC, et al. Osteosarcoma in cats: 22 cases (1974-1984). *J Am Vet Med Assoc* 1987;190:91-93.

This report was submitted by Sarah L. Gillings, DVM, and Philip D. Pacchiana, DVM; from the Ham Lake-Blaine Pet Clinic, 13060 Central Ave NE, Blaine, MN 55434 (Gillings), and the Department of Small Animal Clinical Sciences, College of Veterinary Medicine, University of Minnesota, St. Paul, MN 55108 (Pacchiana). Address correspondence to Dr. Pacchiana.