

Treatment of dogs infected with *Hepatozoon americanum*: 53 cases (1989–1998)

Douglass K. Macintire, DVM, MS, DACVIM, DACVECC; Nancy A. Vincent-Johnson, DVM, MS, DACVIM; Curtis W. Kane, DVM; David S. Lindsay, PhD; Byron L. Blagburn, PhD; Allen R. Dillon, DVM, MS, DACVIM

Objective—To determine clinical and pathologic findings before and after short-term (group 1) and long-term (group 2) treatment in dogs with *Hepatozoon americanum* infection.

Design—Retrospective study.

Animals—53 dogs with *H americanum* infection.

Procedure—Medical records of dogs that were treated for hepatozoonosis diagnosed on the basis of meront or merozoite stages in skeletal muscle were reviewed.

Results—Circulating gametocytes of *H americanum* were identified in 12 of 53 dogs. Dogs were treated with various drugs, including toltrazuril, trimethoprim-sulfadiazine, clindamycin, pyrimethamine, and decoquinat. Mean WBC counts prior to treatment were 85,700 and 75,200 cells/ μ l in groups 1 and 2, respectively, and 1 month after initiation of treatment were 12,600 and 14,600 cells/ μ l, respectively. Initial response to treatment was excellent in all dogs. Twenty-three of 26 dogs in group 1 relapsed at least once and died within 2 years; mean (\pm SD) survival time was 12.6 ± 2.2 months. Twenty-two of 27 group-2 dogs survived; 11 dogs had no clinical signs and were still receiving decoquinat (mean duration of treatment, 21 months), 11 dogs had no clinical signs after treatment for 14 months (range, 3 to 33 months; mean survival time, 39 months [range, 26 to 53 months]), 2 dogs were lost to follow-up, and 3 dogs were euthanatized because of severe disease.

Conclusions and Clinical Relevance—Although no treatment effectively eliminated the tissue stages of *H americanum*, treatment with trimethoprim-sulfadiazine, clindamycin, and pyrimethamine followed by long-term administration of decoquinat resulted in extended survival times and excellent quality of life. (*J Am Vet Med Assoc* 2001;218:77–82)

Two species of *Hepatozoon* organisms are known to infect domestic dogs. *Hepatozoon canis* was first reported in a dog in India in 1905¹ and has since been reported in dogs from around the world, including Japan,² Israel,^{3,4} Africa,⁵ the Philippines,⁶ Malaysia,⁷ and southern Europe.^{8–10} The definitive host is the brown dog tick, *Rhipicephalus sanguineus*, which is found

worldwide.¹¹ Pathogenicity of the organism has been questioned, because subclinical infections are common, and gametocytes in circulating WBC are often an incidental finding in dogs without clinical signs.³ Dogs may have fever, lethargy, and leukocytosis with *H canis* infection, but concurrent disease or immunosuppression are common underlying factors.⁴ Recommended treatment for *H canis* infection is IM or SC administration of imidocarb hydrochloride^a at a dose of 5 to 6.6 mg/kg (2.3 to 3 mg/lb) of body weight, given twice, 14 days apart. This treatment is effective in eliminating parasitemia and relieving clinical signs.¹²

In 1978, hepatozoonosis was reported in dogs from the gulf coast area of Texas in the United States.¹³ The organism was initially thought to be *H canis*, but differences in pathogenicity, microstructure, clinical syndrome, and tissue stages led to the designation of a new species, *H americanum*, in 1997.¹⁴ The definitive host is the gulf coast tick, *Amblyomma maculatum*,¹⁵ and the disease has been reported in dogs from Texas, Oklahoma, Louisiana, Mississippi, Alabama, Georgia, and Florida.^{16–19} The disease is likely to occur anywhere in the natural geographic habitat of *A americanum*, which currently includes the southern United States, particularly the gulf coast states.¹⁵

Hepatozoon americanum causes a distinct clinical syndrome in dogs characterized by fever, lethargy, weight loss, stiffness, signs of pain, paresis, and ocular discharge.²⁰ Common hematologic abnormalities include nonregenerative anemia, substantial leukocytosis, hypoalbuminemia, hypoglycemia, and increased serum activity of alkaline phosphatase.^{17,19}

Hepatozoon americanum infection is usually diagnosed by finding tissue stages of the organism in fixed specimens of skeletal muscle, because gametocytes are rare and difficult to find on a blood smear.²¹ The life cycle is complex and requires a tick host for sexual reproduction and a canine host for asexual reproduction.²⁰

Treatment of *H americanum* infection has been ineffective at inducing long-term remission or cure, because no medication eradicates tissue stages of the organism.¹⁷ Palliative treatment with nonsteroidal anti-inflammatory drugs has been recommended to relieve fever and signs of pain in affected dogs.¹¹ The disease is characterized by frequent relapses and a chronic waxing and waning course.²⁰ Consequences of chronic infection include cachexia, hypoproteinemia, amyloidosis, glomerulonephropathy, vasculitis, and death within 12 to 24 months after initial clinical signs.¹⁷ Because *H americanum* is an emerging tick-borne disease that has only recently been described, retrospective studies that document the efficacy of treatment in affected dogs are lacking.

From the Departments of Small Animal Surgery and Medicine (Macintire, Vincent-Johnson, Kane, Dillon) and Pathobiology (Lindsay, Blagburn), College of Veterinary Medicine, Auburn University, AL 36849. Dr. Vincent-Johnson's present address is US Army Veterinary Command, ATTN: MCVS-P, 2050 Worth Rd, Ste 5, Fort Sam Houston, San Antonio, TX 78234. Dr. Lindsay's present address is the Department of Biomedical Sciences and Pathobiology, Virginia-Maryland College of Veterinary Medicine, Virginia Tech and University of Maryland, Blacksburg, VA 24061.

The purpose of the study reported here was to determine clinical and pathologic findings before and after short- and long-term treatment in dogs with naturally occurring *H americanum* infection.

Criteria for Selection of Cases

Medical records of dogs with a primary diagnosis of hepatozoonosis whose owners requested treatment and agreed to follow-up office visits 1 month after initiation of treatment and then at 3-month intervals were reviewed. Records were included only if the diagnosis had been confirmed by microscopic identification of *H americanum* meronts or merozoites in skeletal muscle biopsy specimens obtained from the hind limb or epaxial muscles.

Procedures

The following information was obtained from each medical record: pretreatment and 1-month posttreatment values for WBC count, Hct, weight, serum concentrations of albumin and glucose, serum alkaline phosphatase activity, and rectal temperature; drugs used, duration of treatment, and number of clinical relapses; evidence of chronic disease (vasculitis, proteinuria, cachexia); cause of death; number of months of survival; number of months of continuous daily treatment for dogs that received decoquinat; and most recent survival and historical data from owners or veterinarians of dogs that had incomplete records.

Statistical analyses—For statistical analyses, dogs that received short-term treatment were allocated into group 1, and dogs that received long-term treatment were allocated into group 2. Clinicopathologic values obtained before and 1 month after treatment was initiated were distributed normally and were compared by use of a paired *t*-test. Body weight values in groups 1 and 2 failed normality testing, so testing for differences was made by use of the Wilcoxon signed rank test. Each comparison was 2-tailed; statistical software^b was used for analyses.

Kaplan-Meier^{22,23} survival curves were constructed for groups 1 and 2 and compared by use of the log-rank test. Starting point for each dog was designated as the time of diagnosis of *Hepatozoon* infection; end point was death from hepatozoonosis. For analysis purposes, those dogs that were euthanatized because of their disease were considered to have died from hepatozoonosis. Dogs that died from causes not related to hepatozoonosis or treatment for hepatozoonosis and dogs lost to follow-up were censored from the survival curves at time of death or time of loss to follow-up, respectively. A value of $P < 0.05$ was considered significant for all comparisons. Values are reported as mean \pm SD unless otherwise indicated.

Results

Dogs and treatment—Fifty-three dogs met the criteria for inclusion in this study. Mean age for all dogs was 3 ± 1 years. There were 28 males (3 neutered) and 25 females (21 spayed). Mean weight for dogs in group 1 was 16.2 ± 6 kg (35.6 ± 13.2 lb) and for dogs in group 2 was 17.8 ± 6 kg (39.2 ± 13.2 lb). Breeds represented

included mixed-breed ($n = 17$), Labrador Retriever (7), Golden Retriever (4), Cocker Spaniel (4), German Shepherd Dog (3), Dachshund (3), Miniature Schnauzer (3), Coonhound (2), and 1 each of the following: Doberman Pinscher, Shar Pei, Miniature Poodle, Collie, Pekinese, American Staffordshire Terrier, Chihuahua, Shetland Sheepdog, Yorkshire Terrier, and Rottweiler. Twenty-six dogs were included in the short-term treatment group (group 1) and included 21 dogs that received toltrazuril^c (5 mg/kg, PO, q 12 h, for 5 days [$n = 12$] or 10 days [9]) and 5 dogs that received a combination of trimethoprim-sulfadiazine,^d clindamycin,^e and pyrimethamine^f (TCP), as follows: trimethoprim-sulfadiazine (15 mg/kg [6.8 mg/lb], PO, q 12 h), clindamycin (10 mg/kg [4.5 mg/lb], PO, q 8 h), and pyrimethamine (0.25 mg/kg [0.11 mg/lb], PO, q 24 h) for 14 days. Twenty-seven dogs were included in the long-term treatment group (group 2); these dogs received TCP for 14 days, followed by oral administration of 10 to 20 mg/kg [4.5 to 9.1 mg/lb] of decoquinat^g every 12 hours, mixed in food, for 3 to 33 months. Dogs in both groups were retreated with TCP if relapse resulted in clinical signs of fever and leukocytosis. Concurrent tick-borne diseases were detected in 4 dogs in group 1 (Rocky Mountain spotted fever [$n = 2$], *Ehrlichia platys* infection [2]) and 3 dogs in group 2 (Rocky Mountain spotted fever [2], *Ehrlichia canis* infection [1]). These dogs were also treated with doxycycline (5 mg/kg, PO, q 12 h, for 14 days).

Clinicopathologic findings before treatment—Pretreatment clinicopathologic abnormalities included substantial leukocytosis in all dogs, hypoglycemia in 24 of 26 (92%) group-1 dogs and 25 of 27 (93%) group-2 dogs, increased serum alkaline phosphatase activity in all group-1 dogs and 23 of 27 (85%) group-2 dogs, hypoalbuminemia in 22 of 26 (85%) group-1 dogs and 19 of 27 (70%) group-2 dogs, and nonregenerative anemia in 17 of 26 (65%) group-1 dogs and 16 of 27 (60%) group-2 dogs. Common clinical signs among dogs in both groups included fever, weight loss, mucopurulent ocular discharge, signs of pain, and stiffness.

Short-term response to treatment—Short-term response to treatment was excellent for dogs in both groups. A significant ($P < 0.001$) improvement was detected in all variables measured 1 month after initiation of treatment, compared with values obtained before treatment (Table 1). Treatments with toltrazuril and TCP were equally effective in inducing remission of clinical signs within 48 to 72 hours. Rectal temperature returned to reference range and clinical signs of pain and stiffness began to resolve. By 1 month after initiation of treatment, attitude and appetite had improved. Weight gain occurred in all dogs and resulted in an increase in body mass of 2 to 38%.

Outcome for group-1 dogs—The clinical improvement seen in group-1 dogs was short-lived. Twenty-three dogs relapsed; mean number of relapses for each dog was 2 (range, 1 to 5 relapses). Clinical signs at relapse and response to treatment were similar to those

Table 1—Clinicopathologic values obtained before treatment and 1 month after initiation of short-term treatment (group 1; n = 26) or long-term treatment (group 2; 27) for hepatozoonosis in dogs

Group	WBC ($\times 10^3$ cells/ μ l)	Hct (%)	Albumin (g/dl)	Glucose (g/dl)	Alk Phos (U/L)	Rectal temperature (C)	Body weight (kg)
Group 1							
Before	83.9 \pm 38.7	30.5 \pm 3.4	2.1 \pm 0.2	53 \pm 11	161 \pm 90	39.8 \pm 0.4	14.8 (5.9–23.1)
After	14.7 \pm 4.9*	38.2 \pm 3.8*	2.7 \pm 0.3*	86 \pm 8*	58 \pm 29*	38.4 \pm 0.3*	15.8 (6.6–26.0)*
Group 2							
Before	77.6 \pm 38.7	34.1 \pm 4.5	2.3 \pm 0.4	55 \pm 20	157 \pm 99	39.7 \pm 0.6	15.8 (12.8–1.4)
After	14.8 \pm 4.1*	41.5 \pm 6.4*	3.1 \pm 0.4*	86 \pm 9*	50 \pm 26*	38.4 \pm 0.4*	16.7 (14.8–27.2)*
Reference range	6.0–17.0	37–55	2.6–3.5	80–100	19–50	37.8–39.2	NA

Values are reported as mean \pm SD, except body weight values, which are reported as median (interquartile range).
 *Significant ($P < 0.001$) difference between values obtained before and after treatment.
 Alk Phos = Alkaline phosphatase. NA = Not applicable.
 To convert C to F, multiply by 9/5 and add 32. To convert kg to lb, multiply by 2.2.

observed initially. Mean remission time before the first relapse was 6.1 ± 0.6 months. Subsequent relapses occurred more frequently. Of the 26 dogs in group 1, 13 were euthanatized because of chronic wasting, 8 died from the disease, 2 were lost to follow-up, and 3 dogs have survived > 3 years. Two survivors were treated with toltrazuril (5 mg/kg, PO, q 12 h, for 5 days) and received TCP twice (at admission and 13 months later). Two of the survivors had low numbers of cysts without evidence of inflammation in muscle biopsy specimens taken 2 years after the initial diagnosis was made. The other surviving dog had normal findings in muscle biopsy specimens. Median survival time for group-1 dogs that died from hepatozoonosis was 12 months (range, 4 to 24 months). Evidence of chronic disease detected at postmortem examination included chronic cachexia (n = 16), glomerulonephritis (6), and thrombosis (2). The 2-year survival rate for the 24 dogs in group 1 for which follow-up evaluation was available was 12.5%. The typical clinical course for dogs in group 1 was an initial good response to treatment, followed by periodic relapses that subsequently resulted in chronic wasting and debilitation that ending in renal failure, death, or euthanasia. None of the dogs that died of renal disease had evidence of glomerulonephropathy or chronic nephritis at the time of initial diagnosis and treatment.

Outcome for group-2 dogs—Twelve dogs in group 2 relapsed; 8 of these dogs relapsed more than once (mean, 1.7 relapses; range, 0 to 3 relapses). In 4 of these dogs, relapse occurred within 1 to 2 weeks after doses of decoquinate were missed. In general, clinical signs during relapse were mild, compared with initial episodes, but dogs were treated with TCP if fever or leukocytosis were evident. Gametocytes were detected in blood smears of 2 dogs 3, 6, and 8 months after initial diagnosis. These dogs were treated with imidocarb dipropionate (5 mg/kg, IM) twice (14 days apart), 8 months after initial diagnosis, and parasitemia resolved. Organisms were detected in muscle biopsy specimens 18 months after initial diagnosis; both dogs are presently doing well and are being treated with decoquinate. None of the dogs in group 2 developed proteinuria, muscle wasting, severe cachexia, or evidence of renal disease, as observed in group-1 dogs. Two dogs that had advanced disease (severe glomeru-

lonephropathy) at the time treatment was initiated did not experience reversal of muscle wasting or proteinuria with treatment.

Of the 27 dogs in group 2, 22 are still alive and free of clinical signs of disease. Two dogs were lost to follow-up at 7 and 9 months because of motor vehicle accidents; these dogs were receiving decoquinate and did not have clinical signs of hepatozoonosis at the time of their deaths. Three dogs died as a result of hepatozoonosis; 1 dog was euthanatized by the referring veterinarian after the owners prematurely discontinued treatment, whereas the other 2 dogs had advanced disease (severe glomerulonephropathy) at the time treatment was initiated and died 2 and 4 months, respectively, after initiation of treatment. Eleven group-2 dogs are presently without clinical signs and not receiving medication; their mean survival time is 39 ± 8 months (range, 27 to 53 months). Mean duration of decoquinate administration in these dogs was 13.7 ± 6 months (range, 3 to 26 months). In 2 of these dogs, organisms were not detected in muscle biopsy specimens obtained 12 and 18 months after the initial diagnosis; muscle biopsies were not performed in the other 9 dogs. Eleven dogs are still receiving decoquinate twice daily (mean duration of administration, 20 ± 8 months; range, 6 to 43 months). In 6 of these dogs, cysts of *H. americanum* were seen by microscopic examination of skeletal muscle specimens 14 to 18 months after the initial diagnosis. Although cyst numbers and inflammatory infiltrate were substantially decreased from that detected in biopsy specimens obtained before treatment, continuation of decoquinate administration was recommended for at least 6 more months. Twenty-one dogs in group 2 have exceeded 24 months survival time, resulting in a survival rate of at least 84% for dogs treated with TCP followed by decoquinate.

Survival was significantly ($P < 0.001$) different between groups 1 and 2 (Fig 1). Dogs that received decoquinate clearly had greater survival time, compared with dogs in group 1 that did not receive decoquinate. Median survival time in group 1 was approximately 12 months, whereas median survival time for group 2 cannot be estimated because of the number of dogs that were still alive at the time of data analysis. Most of these dogs were censored from the survival curves, because they remained alive (n = 22) or were lost to follow-up (2).

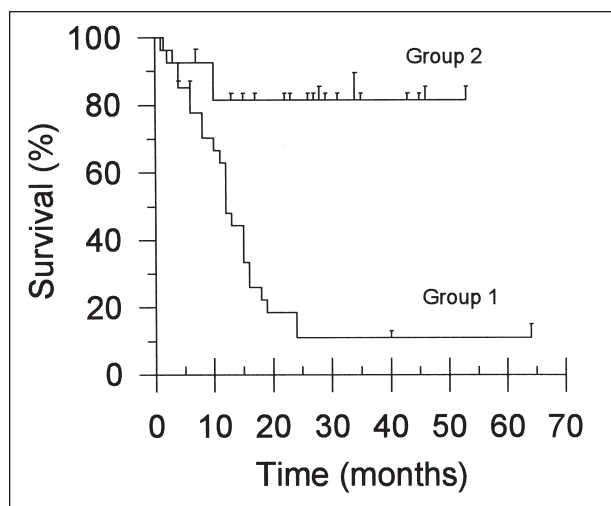


Figure 1—Kaplan-Meier survival curves for dogs that received short-term treatment (group 1; $n = 26$) or long-term treatment (group 2; 27) for hepatozoonosis. Treatment was initiated at time 0. Crossed ticks indicate censored times of survivors. The curves are significantly ($P < 0.001$) different.

Discussion

Analysis of this series of cases reveals further evidence that *H americanum* infection is an emerging tick-borne disease in the southern United States that may cause a classic clinical syndrome that includes fever, leukocytosis, cachexia, myalgia, stiffness, and ocular discharge. Findings in dogs in group 1 typify the problems encountered in attempting to treat dogs with this disease. Despite an initial positive response to antiprotozoal treatment, these dogs relapsed repeatedly, resulting in chronic debilitation and, typically, death or euthanasia.

Recent investigations into the life cycle and tissue stages of *H americanum* have helped to explain the pathogenesis of hepatozoonosis. After a dog ingests an infected tick, infective sporozoites are released from oocysts in the tick's hemocoel to penetrate the dog's gastrointestinal tract and enter blood or lymphatic circulation. These sporozoites individually enter an unidentified host cell (also referred to as a nurse cell) that provides a protected environment in which intracellular merogony (asexual reproduction of the organism) may occur.²⁴ Rupture of the meront and disintegration of the cyst wall result in an intense inflammatory response accompanied by substantial angiogenesis at the site of the pyogranulomatous inflammation. Phagocytized zoites enter the bloodstream through the walls of these vessels.²⁵ At this point, it seems plausible that the zoites may either become circulating gamonts that are available for ingestion by the tick host or merozoites that are to be distributed throughout the dog's tissues to repeat the cycle of asexual reproduction, although this phase of the life cycle has not been confirmed experimentally. Evidence strongly suggests, however, that a single infecting episode may result in prolonged infection that is most likely perpetuated by repeated asexual cycles. One infected tick may contain > 100 oocysts, each able to produce hundreds of infective sporozoites.^{15,h} Ingestion of a single tick, probably during grooming, may therefore cause prolonged infec-

tion in dogs characterized by waxing and waning fever, signs of pain, and leukocytosis as asexual cycles are repeated.

The drug combination TCP has been used to treat toxoplasmosis, another intracellular protozoal infection that affects dogs and cats.²⁶ Oral administration of clindamycin may cause anorexia, vomiting, or diarrhea in some animals,²⁷ especially at high doses, but was not associated with signs of gastrointestinal tract problems in the dogs in the study reported here. Trimethoprim-sulfonamide and pyrimethamine are synergistic²⁶ and inhibit folic-folinic acid metabolism in parasites to a greater extent than in mammalian cells. Bone marrow suppression may develop with prolonged use and may be corrected by adding folinic acid (5.0 mg/d) to the animal's diet. Folinic acid supplementation was not required in the dogs in our study, because evidence of bone marrow suppression was not detected.

Initial response to treatment in affected dogs occurs when antiprotozoal treatment kills merozoites, thereby removing the stimulus for intense pyogranulomatous inflammation. Apparently, no treatment is able to eliminate the developing encysted meronts in their protected intracellular environment. After initial treatment, dogs enter a period of remission that persists until sufficient asexual cycles have been completed to result in substantial pyogranulomatous inflammation, which causes clinical signs. Duration before relapse is variable and may depend on the number of infective sporozoites ingested at the time of infection or perhaps on the dog's immune response. It is likely that the 3 dogs in group 1 that recovered from *H americanum* infection without receiving long-term treatment had a low number of infective sporozoites and a strong immune response against the parasite. In dogs that relapse, the intervals between relapses become shorter as the asexual cycle of the organism is repeated. The resultant chronic inflammation causes progressive cachexia, muscle wasting, and glomerulonephritis. Dysproteinemias may develop and cause decreased serum albumin concentration and increased synthesis of inflammatory proteins. Amyloidosis has been reported in dogs that have died from chronic hepatozoonosis.¹⁷

The key to successful treatment of dogs with hepatozoonosis appears to be prevention of continuing cycles of asexual reproduction, thereby inhibiting subsequent release of merozoites and development of pyogranulomatous inflammation. Decoquinat is a quinilone anticoccidial agent approved for use in cattle,²⁸ sheep,²⁹ goats,³⁰ rabbits,³¹ and chickens.³² It is used as a feed additive to prevent intestinal coccidiosis. Decoquinat acts on the sporozoite stage of coccidial organisms by preventing their development via inhibition of electron transport in the parasite's mitochondria.^{33,34} Decoquinat is classified as a coccidiostat, but at higher concentrations it is coccidiocidal.³⁵

We chose decoquinat in an attempt to arrest development of *H americanum* merozoites after they are released from meronts and because of its reported efficacy against *Toxoplasma gondii*³⁶ and *Neospora caninum*,³⁵ protozoal organisms that also undergo schizogony in tissues. Decoquinat prevents abortion in ewes

that are experimentally infected with *Toxoplasma* organisms³⁶ and kills intracellular *N. caninum* tachyzoites in cell culture.³⁵ Decoquinat also has a wide safety margin. Safety studies conducted by the manufacturer found no toxic effect in dogs at dosages of 15 mg/kg (6.8 mg/lb) for 13 weeks, 1,000 mg/kg (454.5 mg/lb) for 13 weeks, 200 µg/g in the diet for 2 years, or 1,000 µg/g in the diet for 2 years.³⁷ Decoquinat is not effective for treatment of animals with coccidiosis, because it has no effect on adult coccidia. It is effective in preventing coccidiosis by arresting development of sporozoites in intestinal cells. Similarly, dogs with hepatozoonosis that experience relapse should be treated with TCP first, to kill merozoites in the tissues, followed by decoquinat, to arrest developing zoites as they are released from mature meronts.

On the basis of extended survival time, excellent quality of life, and decreased number and severity of clinical relapses, administration of decoquinat appeared to be an effective adjunctive treatment for *H. americanum* infection in dogs. Large numbers of merozoites probably overwhelm the dog's immune system. Treatment with decoquinat may reduce the number of infective organisms, thereby allowing the dog's natural immunity to become protective with time. Decoquinat is not effective in reducing clinical signs associated with acute relapses or in clearing gametocytes from circulation. Combination treatment with TCP for 14 days is recommended if dogs have fever or leukocytosis. Decoquinat must be given daily to prevent development of merozoites and continued asexual reproduction.

It is unknown how long decoquinat should be administered to dogs infected with *H. americanum*. Because we detected organisms in skeletal muscle biopsy specimens 18 months after the initial diagnosis, we presently recommend continuous treatment for 2 years. The drug is safe, and no adverse effects were seen in any of the dogs in our study. Decoquinat is available from feed stores in 50-lb bags (27.2 g/lb). The dosage used in this report was 0.5 to 1.0 teaspoon/10 kg (22 lb), mixed in the food twice daily.

In the study reported here, we did not attempt to evaluate the effectiveness of imidocarb for treating dogs with *H. americanum* infection. Imidocarb is the treatment of choice for dogs with *H. canis* infection.^{4,5,9,10,12} Two dogs in our series were treated with imidocarb during a relapse 8 months after the initial diagnosis of *H. americanum* infection. Despite the fact that parasitemia was cleared, organisms were found in skeletal muscle 10 months later in both dogs.

Toltrazuril, which induced excellent clinical response initially in treated dogs, is no longer available for clinical use in the United States. In 1 study,³⁸ voles treated with toltrazuril were protected from death after experimentally induced hepatozoonosis, but the drug was ineffective in achieving complete elimination of parasites. Similar results were seen in the dogs in our study.

Although no treatment is effective in eliminating *H. americanum* from infected dogs, treatment with TCP for 2 weeks, followed by long-term administration of decoquinat, resulted in increased survival time and excellent quality of life. If treatment is initiated early in

the course of disease, the prognosis appears to be good for long-term survival. Decoquinat was not effective in dogs that had advanced disease with glomerulonephropathy at the time treatment was initiated. Effective tick control is also necessary to prevent reinfection of susceptible hosts in endemic areas and is important in limiting the spread of disease.

^aImizol, imidocarb dipropionate, Schering-Plough, Kenilworth, NJ.

^bSigmastat 2.0 Jandel Scientific, San Rafael, Calif.

^cBaycox, Bayer Inc, Shawnee, Kan.

^dDi-Trim, Syntex Animal Health, West Des Moines, Iowa.

^eAntirobe, The Upjohn Co, Don Mills, ON, Canada.

^fDaraprim, pyrimethamine, Burroughs Wellcome Co, Research Triangle Park, NC.

^gDeccox, decoquinat, Alpha Pharma Inc, Fort Lee, NJ.

^hVincent-Johnson NA. Canine hepatozoonosis: description of the causative organism. MS thesis, Department of Small Animal Surgery and Medicine, Auburn University, AL, 1996.

References

1. Bentley CA. Preliminary note on a leukocytozoon of the dog. *Br Med J* 1905;1:988.
2. Murata T, Shiramizok, Hara Y, et al. First case of *Hepatozoon canis* infection of a dog in Japan. *J Vet Med Sci* 1991;53:1097-1099.
3. Baneth G, Shkap V, Presenty B-Z, et al. *Hepatozoon canis*: the prevalence of antibodies and gametocytes in dogs in Israel. *Vet Res Commun* 1996;20:41-46.
4. Baneth G, Weigler B. Retrospective case-control study of hepatozoonosis in dogs in Israel. *J Vet Intern Med* 1997;11:365-37.
5. McCully RM, Basson PA, Bigalke RD, et al. Observations on naturally acquired hepatozoonosis of wild carnivores and dogs in the Republic of South Africa. *Onderstepoort J Vet Res* 1975;42:117-134.
6. Novilla MN, Kwapein RP, Peneyra RS. Occurrence of canine hepatozoonosis in the Philippines, in *Proceedings. Helminthol Soc Washington* 1977;44:98-101.
7. Rajamanickam C, Weisenhutter E, Zin FM. The incidence of canine haematozoa in peninsular Malaysia. *Vet Parasitol* 1984;17:151-157.
8. Fischer S, Hartman K, Gothe R. *Hepatozoon canis*: eine importierte parasitäre infektion bei hunden. *Tierarztl Prax* 1994;22:172-180.
9. Jauregui LE, Lopez GM. Canine hepatozoonosis. *Vet Int* 1995;7:30-38.
10. Kontos V, Koutinas A. Canine hepatozoonosis: a review of 11 naturally occurring cases. *Bull Helen Vet Med Soc* 1990;41:73-81.
11. Craig TM. Hepatozoonosis. In: Green CE, ed. *Clinical microbiology and infectious diseases of the dog and the cat*. Philadelphia: WB Saunders Co, 1998;458-465.
12. Ogunkoya AB, Adyanju JB, Aliv YO. Experiences with the use of imizol in treating canine blood parasites in Nigeria. *J Small Anim Pract* 1981;22:775-777.
13. Craig TM, Smallwood JE, Knauer KW, et al. *Hepatozoon canis* infection in dogs: clinical, radiologic, and hematologic findings. *J Am Vet Med Assoc* 1978;173:967-972.
14. Vincent-Johnson NA, Macintire DK, Lindsay DS, et al. A new hepatozoon species from dogs: description of the causative agent of canine hepatozoonosis in North America. *J Parasitol* 1997;83:1165-1172.
15. Mathew JS, Ewing SA, Panciera RJ, et al. Experimental transmission of *Hepatozoon americanum* Vincent-Johnson et al, 1997 to dogs by the Gulf Coast tick *Amblyomma maculatum* Koch. *Vet Parasitol* 1998;80:1-14.
16. Panciera RJ, Gatto RT, Crystal MA, et al. Canine hepatozoonosis in Oklahoma. *J Am Anim Hosp Assoc* 1997;33:221-225.
17. Macintire DK, Vincent-Johnson NA, Dillon AR, et al. Hepatozoonosis in dogs: 22 cases (1989-1994). *J Am Vet Med Assoc* 1997;210:916-922.
18. Gossett KA, Gaunt SD, Aja DS. Hepatozoonosis and ehrlichiosis in a dog. *J Am Anim Hosp Assoc* 1985;21:265-267.
19. Barton CL, Russo EA, Craig TM, et al. Canine hepatozoonosis: A retrospective study of 15 naturally occurring cases. *J Am Anim Hosp Assoc* 1985;21:125-134.

20. Vincent-Johnson NA, Macintire DK, Bareth G. Canine hepatozoonosis: pathophysiology, diagnosis, and treatment. *Compend Contin Educ Pract Vet* 1997;19:51–65.
21. Craig TM, Jones LP, Nordgren RM. Diagnosis of *Hepatozoon canis* by muscle biopsy. *J Am Anim Hosp Assoc* 1984;20:301–303.
22. Matthews DE, Farewell VT. *Using and understanding medical statistics*. 3rd ed. New York: Karger, 1996;64–83.
23. Lang TA, Secic M. *How to report statistics in medicine*. Philadelphia: American College of Physicians, 1997;137–146.
24. Panciera RJ, Ewing SA, Mathew JS, et al. Observations on tissue stages of *Hepatozoon americanum* in 19 naturally infected dogs. *Vet Parasitol* 1998;78:265–276.
25. Panciera RJ, Ewing SA, Mathew JS, et al. Canine hepatozoonosis: comparison of lesions and parasites in skeletal muscle of dogs experimentally or naturally infected with *Hepatozoon americanum*. *Vet Parasitol* 1999;82:261–272.
26. Greene CE. Antiprotozoal therapy. In: Greene CE, ed. *Clinical microbiology and infectious diseases of the dog and the cat*. Philadelphia: WB Saunders Co, 1998;827.
27. Greene CE, Cook JP, Mahaffey EA. Clindamycin for treatment of *Toxoplasma polymyositis* in a dog. *J Am Vet Med Assoc* 1985;187:631–634.
28. Fitzgerald PR, Mansfield ME. Effects of intermittent and continuous administration of decoquinate on bovine coccidiosis in male calves. *Am J Vet Res* 1989;50:961–964.
29. Foreyt WJ. Coccidiosis and cryptosporidiosis in sheep and goats. *Vet Clin North Am Food Anim Pract* 1990;6:655–670.
30. Foreyt WJ, Hancock D, Wescott RB. Prevention and control of coccidiosis in goats with decoquinate. *Am J Vet Res* 1986;47:333–335.
31. Mercier P. Use of decoquinate in the control of coccidiosis in rabbits during fattening. *Bulletin-des-GTV* 1997;1:89–94.
32. Perry EA, Long PL. The extraintestinal stages of *Eimeria tenella* and *E. maxima* in the chicken. *Vet Parasitol* 1987;25:9–17.
33. Fry M, Hudson AT, Randall AW, et al. Potent and selective hydroxynaphthoquinone inhibitors of mitochondrial electron transport in *Eimeria tenella* (Apicomplexa:coccidia). *Biochem Pharmacol* 1984;33:2115–2122.
34. Wang CC. Inhibition of respiration of *Eimeria tenella* by quinolone coccidiostats. *Biochem Pharmacol* 1976;25:343–349.
35. Lindsay DL, Butler JM, Blagburn BL. Efficacy of decoquinate against *Neospora caninum* tachyzoites in cell cultures. *Vet Parasitol* 1997;68:35–40.
36. Buxton D, Brebner J, Wright S, et al. Decoquinate and the control of experimental ovine toxoplasmosis. *Vet Rec* 1996;138:434–436.
37. Alpharma Animal Health. *Safety and toxicity studies*. Atlanta: Rhone-Poulenc Animal Nutrition, 21 CFR Ch 1 Sec 558.195, Decoquinote. Available at <http://www.alpharma.com/ahd/index.html>. Accessed Sep 6, 2000.
38. Krampitz HE, Haberkorn A. Experimental treatment of *Hepatozoon* infections with the anticoccidial agent toltrazuril. *J Vet Med Sci* 1988;35:131–137.