

Coronavirus-associated epizootic catarrhal enteritis in ferrets

Bruce H. Williams, DVM, DACVP; Matti Kiupel, MS, Dr med vet; Keith H. West, DVM, PhD;
James T. Raymond, DVM, DACVP; Christopher K. Grant, DVM, PhD; Lawrence T. Glickman, VMD, DrPH

Objective—To characterize clinical signs and lesions and identify the etiologic agent associated with epizootic catarrhal enteritis in domestic ferrets.

Design—Cross-sectional study.

Animals—119 ferrets with epizootic diarrhea of presumed viral cause and 5 control ferrets.

Procedure—Clinical records and biopsy or necropsy specimens of ferrets with presumed epizootic catarrhal enteritis were reviewed. Immunohistochemical staining for coronavirus antigen was performed on paraffin-embedded tissues from approximately 10% of affected ferrets to identify viral antigen and determine its distribution. Transmission electron microscopy was performed on fecal samples and sections of jejunum. Virus isolation studies as well as immunofluorescent tests for other similar viruses were performed.

Results—Characteristic microscopic lesions consistent with intestinal coronavirus infection (vacuolar degeneration and necrosis of villus enterocytes; villus atrophy, fusion, and blunting; and lymphocytic enteritis) were consistently detected in affected ferrets. Coronavirus particles were identified in feces and jejunal enterocytes by use of transmission electron microscopy. Immunohistochemical staining of jejunal sections revealed coronavirus antigens. Antigen staining was not detected in healthy ferrets or ferrets with other gastrointestinal tract diseases. Virus isolation was unsuccessful, and other similar viruses were not detected.

Conclusions and Clinical Relevance—Results strongly implicate a coronavirus as the causative agent of epizootic catarrhal enteritis in ferrets. Diagnosis may be made on the basis of a combination of historical, clinical, and microscopic findings. (*J Am Vet Med Assoc* 2000;217:526–530)

In March of 1993, a novel diarrheal disease affecting domestic ferrets (*Mustela putorius furo*) was reported by ferret breeders and pet owners along the east coast of the United States. Within 1 week, epizootics of diarrhea that caused rapid dehydration developed in ferret breeding and rescue facilities in Virginia, Maryland, Pennsylvania, and Wisconsin. The disease was charac-

terized as having high morbidity and low mortality with initial signs of lethargy, inappetence, and vomiting. Subsequently, profuse bright green diarrhea with high mucus content developed, often affecting 100% of ferrets in each facility. Disease severity in individuals was highly variable; older ferrets had more severe signs, whereas young ferrets had mild or subclinical infection. Since that time, this disease has been diagnosed throughout the United States and in several other countries, affecting ferrets in breeding and rescue facilities as well as pet ferrets, resulting in substantial economic loss and emotional distress. The disease was named **epizootic catarrhal enteritis (ECE)** after study at the Armed Forces Institute of Pathology on the basis of similarities to a diarrheal disease of mink (epizootic catarrhal gastroenteritis).¹

In ECE of ferrets, as in epizootic catarrhal gastroenteritis of mink, coronavirus-like particles were seen in feces, and a combination of atrophic and inflammatory enteric lesions characteristic of chronic coronavirus infection was commonly detected in ferrets with long-standing disease. The purpose of the study reported here was to characterize clinical signs and lesions and identify the etiologic agent associated with ECE in domestic ferrets. We hypothesized that a coronavirus was the causative agent.

Materials and Methods

Study population—Medical records of ferrets with non-specific enteritis diagnosed between March 1993 and July 1999 on the basis of histologic examination of biopsy or necropsy specimens were reviewed at the Armed Forces Institute of Pathology and AccuPath Inc. Criteria for inclusion in the study included a clinical history of diarrhea, lack of a definitive cause of the disease, and one or more of the following microscopic lesions: vacuolar degeneration and necrosis of villus enterocytes; villus atrophy, fusion, and blunting; and lymphoplasmacytic enteritis characterized by a subjective increase in number of intraepithelial lymphocytes. Of 171 reviewed cases, 110 met study criteria. In addition, 10 ferrets from a large breeding colony affected by an epizootic diarrheal disease were submitted to Purdue University for examination. After necropsy and microscopic examination, 9 of these ferrets met study criteria and were included in the study.

Medical records were reviewed for history, clinical findings, and results of necropsy and laboratory tests. Because many of the medical records consisted primarily of pathology reports, complete clinicopathologic data were often not available. Biopsy and necropsy specimens were retrieved for histologic, immunohistochemical, electron microscopic, and immunofluorescent studies as well as virus isolation. Specimens from 5 control ferrets that did not meet study criteria were also obtained.

Histologic preparation—Tissues were fixed in neutral-buffered 10% formalin, embedded in paraffin, sectioned at 7

From the Department of Veterinary Pathology, Armed Forces Institute of Pathology, Washington, DC, 20306-6000 (Williams); the Animal Disease Diagnostic Laboratory, (Kiupel, Raymond) and the Department of Veterinary Pathobiology (Kiupel, Raymond, Glickman), Purdue University, West Lafayette, IN, 47906; Prairie Diagnostic Services, 52 Campus Dr, Rm 1608, Saskatoon, SK, Canada S74 5B4 (West); and Custom Monoclonals International, 813 Harbor Blvd, Ste #284, West Sacramento, CA 95691-2201 (Grant).

µm on a microtome, and stained with H&E for examination by use of light microscopy.

Immunohistochemical studies—Formalin-fixed paraffin-embedded tissues from 15 ferrets were selected for immunohistochemical evaluation. Two staining protocols and 2 antibodies were used. Following deparaffinization, 2 histologic slides of affected small intestine from each of 10 ferrets examined at the Armed Forces Institute of Pathology were washed in automation buffer^a with 10% acetone and 0.15% 23-lauryl ether^b and immersed in 3.0% hydrogen peroxide in methanol for 10 minutes to block endogenous peroxidase activity. After washing with automation buffer, slides were incubated in 0.05% protease XIV^c for 20 minutes at 42 C. Nonspecific antibody binding was blocked with 4% normal goat serum. Immunostaining was performed by overnight incubation at 4 C with monoclonal antibody 7-3^d (dilutions, 1:8,000 and 1:16,000) that had been produced against feline infectious peritonitis virus (this antibody also has cross-reactivity to canine and porcine coronavirus in formalin-fixed tissue) and biotinylated goat anti-mouse secondary antibody^e (dilution, 1:400). Staining was completed by use of a peroxidase-labeled avidin-biotin complex^f followed by diaminobenzidine as a chromogen substrate. After a final washing in automation buffer, sections were counterstained with H&E.

Following deparaffinization, 2 histologic slides of affected small intestine from each of 5 ferrets examined at Purdue University were washed in a mixture of 1 L of phosphate-buffered saline solution and 50 µl Tween 20^g (pH, 7.4) and immersed in 3.0% hydrogen peroxide for 10 minutes to block endogenous peroxidase activity. After washing with distilled water, slides were incubated in 10-mM EDTA/NaOH buffer (pH, 8.0) in a microwave oven (600 W) for 10 minutes and acclimatized at 20 C for 60 minutes. Nonspecific antibody binding was blocked with 2% normal goat serum. Monoclonal antibody FCV3-70^h (this antibody reacts specifically with feline, canine, and porcine coronaviruses in paraffin-embedded tissue^{2,3}) was applied at a dilution of 1:100 followed by a 1:500 dilution of a biotinylated goat anti-mouse secondary antibodyⁱ for overnight incubation at -4 C. Antibody binding was localized with a peroxidase-labeled avidin-biotin complex^j and stained with vector red alkaline phosphatase substrate.^k After washing in distilled water, sections were counterstained with Mayer's hematoxylin, dehydrated, cleared, and mounted in epoxy resin.^l Negative antibody control slides were prepared by staining tissue sections with isotype murine monoclonal control antibodies in both protocols.

Transmission electron microscopy—Specimens of small intestine from 2 affected ferrets from the large breeding colony were fixed sequentially in neutral-buffered 10% formalin and 4% glutaraldehyde and osmium tetroxide, embedded in epoxide resin, sectioned with an ultramicrotome, and stained with lead citrate and uranyl acetate. Sections were examined and photographed by use of a transmission electron microscope.^m

Fecal samples from 9 ferrets from the large breeding colony were diluted to approximately 5% with deionized water and centrifugedⁿ at 10,000 rpm for 5 minutes. The supernatant was removed and centrifuged at 20,000 rpm for 40 minutes; the resulting supernatant was discarded. A solution of 3 drops of 3% phosphotungstic acid, 1 drop of 0.1% bovine serum albumin, and enough deionized water to fill the appropriate number of spots on the spot plate was prepared, and 1 spot was pipetted into the tube to resuspend the pellet. The resuspended material was pipetted into a nebulizer and sprayed on grids; spraying was repeated 30 to 40 times on each grid. The nebulizer was removed, and grids were

examined and photographed by use of a transmission electron microscope.^m

Virus isolation—Fecal extracts and tissue homogenates of liver, lung, and intestine from 9 acutely infected ferrets from the large breeding colony were passed through a 1-µm millipore filter and inoculated into the following cell cultures: MV-1-LU, HRT-18, DK-5966, CRSK, and A72-163.^o Identical inoculations were performed on cell cultures treated with trypsin and untreated cell cultures.

Immunofluorescence—Specimens of small intestine from 9 ferrets from the large breeding colony were snap frozen with solid CO₂; 6-µm cryosections were cut, mounted on cover slips, air-dried, and fixed with acetone. After washing with Tris buffer (pH, 8.7), sections were incubated with fluorescein isothiocyanate-conjugated antibodies against canine distemper virus,^p canine parvovirus 2,^p canine coronavirus,^p canine herpesvirus,^p bovine coronavirus,^p bovine rotavirus,^p porcine rotavirus,^q porcine hemagglutinating encephalomyelitis virus,^q and porcine transmissible gastroenteritis virus,^p at a dilution of 1:500 for 30 minutes at 20 C in a humid chamber. Unbound stain was removed by washing with Tris buffer. Sections were counterstained with Evans blue in Tris buffer (dilution, 1:10,000), mounted in glycerol, and examined by use of ultraviolet light microscopy.

Results

Historical and clinicopathologic data—Mean and median age of ferrets with ECE was 4.18 and 4.0 years, respectively. Because medical records were often incomplete, meaningful interpretation of other data was not possible.

Breeding colony outbreak—Ten ferrets examined at Purdue University were submitted during a widespread outbreak of ECE in a large breeding colony. The disease spread from cage to adjacent cage but was also detected at more distant locations within 48 hours of appearance of the initial cases. Once clinical signs were noticed in ferrets in a given area, the disease progressed during a period of several weeks to affect ferrets in all cages within the same building. Initial attempts to contain the disease by use of protective clothing and restricted movement of ferret caretakers were unsuccessful. Palliative treatments such as administration of broad-spectrum antimicrobials and SC administration of fluids were used, depending on severity of clinical signs. Morbidity was initially limited to adult ferrets; mortality rate in most buildings was < 5%. Within several weeks the epizootic subsided, although loose mucoid feces, without other clinical signs, were intermittently noticed in otherwise healthy young ferrets.

Gross lesions—Gross lesions in ferrets with acute ECE were characterized by bright green diarrhea with high mucus content and hyperemia of affected portions of the small intestine. Ferrets examined at a later stage of disease had thinning of the intestinal wall with loss of villi, and the lumen contained grainy material described as resembling bird seed.

Microscopic lesions—Affected ferrets had diffuse lymphocytic enteritis only (n = 40), characterized by variable numbers of intraepithelial lymphocytes, or

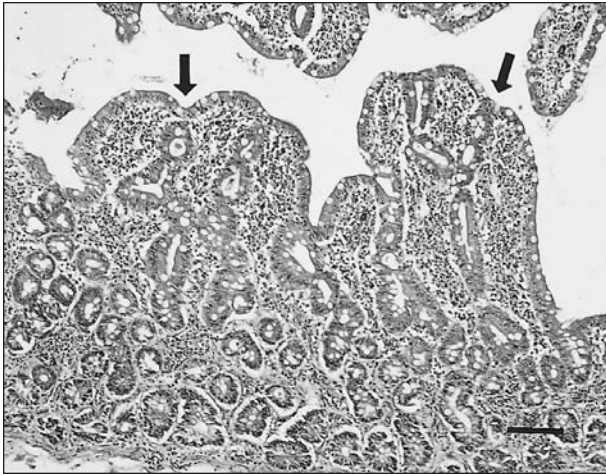


Figure 1—Photomicrograph of a section of jejunum from a ferret with chronic epizootic catarrhal enteritis. Notice characteristic fusion and blunting of villi (arrows) and prominent lymphocytic enteritis causing expansion of the lamina propria of the mucosa. H&E stain; bar = 17.5 μ m.

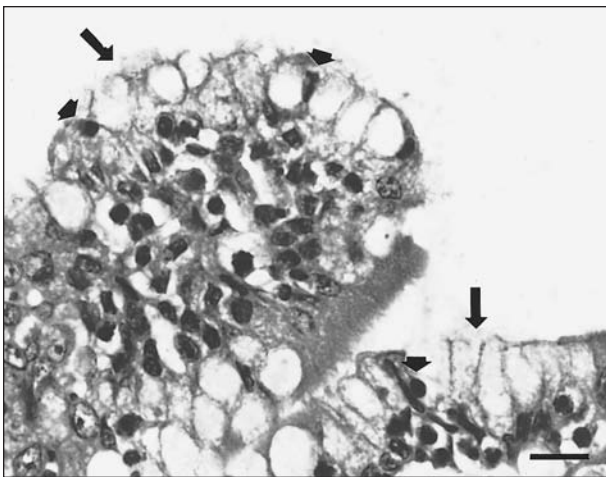


Figure 2—Photomicrograph of a section of jejunum from a ferret with acute epizootic catarrhal enteritis. Notice characteristic vacuolar degeneration of villus enterocytes (arrows) and intraepithelial lymphocytes (arrowheads). H&E stain; bar = 70 μ m.

had lymphocytic enteritis as well as villus atrophy, fusion, and blunting (Fig 1 [36]), vacuolar degeneration and necrosis of the apical epithelium (Fig 2 [15]), or a combination of all these lesions (15). Lymphocytic enteritis, villus lesions, and diffuse mucosal necrosis with granulation tissue formation and bacteria were detected in 4 ferrets. Villus atrophy, fusion, and blunting was detected without other lesions in 3 ferrets and with vacuolar epithelial degeneration and necrosis only in 2 ferrets. Control ferrets had normal findings or lesions associated with other diseases.

Immunohistochemical staining—Positive results of immunohistochemical procedures were detected in 6 of 10 specimens from the Armed Forces Institute of Pathology by use of monoclonal antibody 7-3 and in 4 of 5 specimens from Purdue University by use of monoclonal antibody FCV3-70. Positive labeling for coronavirus ranged from staining of focal scattered villus enterocytes to staining of extensive numbers of entero-

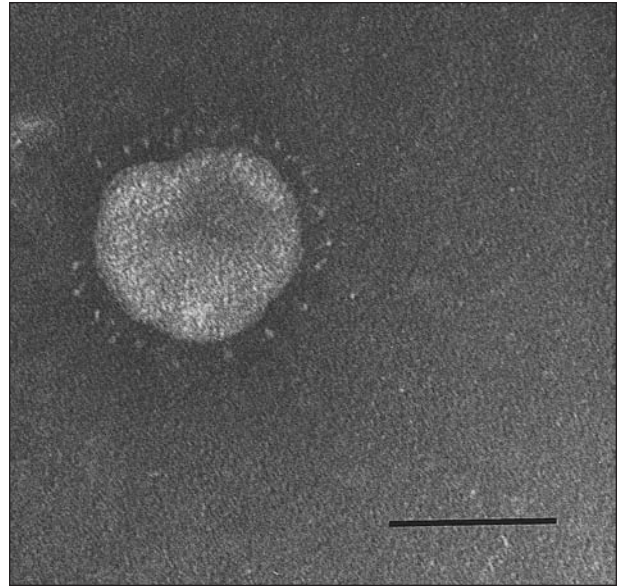


Figure 3—Transmission electron photomicrograph of fecal preparation from a ferret with epizootic catarrhal enteritis. Notice the coronavirus-like particle, approximately 120 nm in diameter, characterized by a regularly spaced array of 20-nm-long pin-shaped peplomers. Unstained; bar = 72 nm.

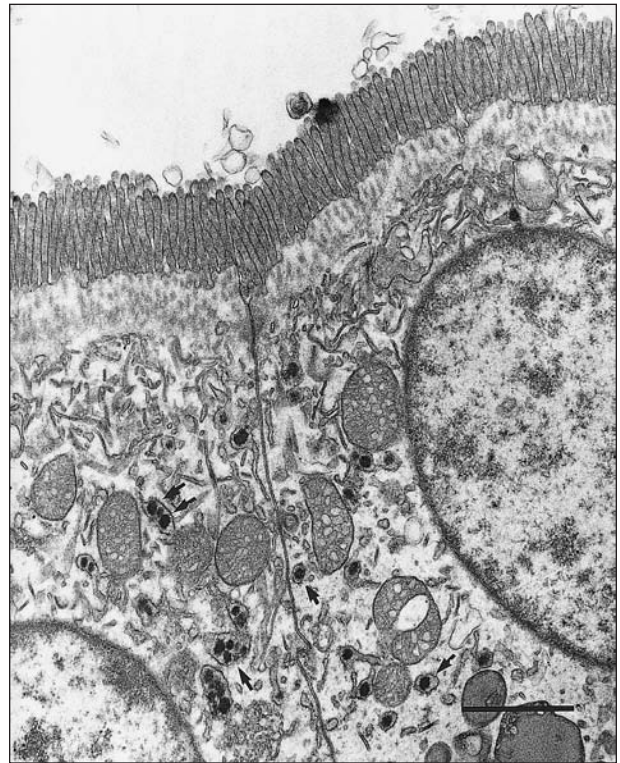


Figure 4—Transmission electron photomicrograph of a section of jejunum of a ferret with epizootic catarrhal enteritis. Notice highly pleomorphic virions (arrows), approximately 120 nm in diameter, in cytoplasmic vacuoles of apical enterocytes. Lead citrate and uranyl acetate stain; bar = 1 μ m.

cytes throughout the length of the villus. Results were negative for specimens from 5 control ferrets that were healthy or had intestinal diseases that were not caused by viruses.

Immunofluorescent and virus isolation studies—

Results of direct fluorescent antibody tests on frozen sections of intestine were negative for canine distemper virus, canine parvovirus 2, canine coronavirus, canine herpesvirus, bovine coronavirus, bovine rotavirus, porcine rotavirus, porcine hemagglutinating encephalomyelitis virus, and porcine transmissible gastroenteritis virus. No viruses were isolated from intestine, spleen, or liver specimens.

Electron microscopy—Coronavirus-like particles, approximately 120 nm in diameter, were observed by use of transmission electron microscopy in fecal samples from 9 ferrets with ECE (Fig 3). Virions were characterized by an evenly spaced array of 20-nm pin-shaped peplomers distributed around the periphery.

Transmission electron microscopy of selected sections of jejunal mucosa from 2 ferrets revealed highly pleomorphic virions, approximately 120 nm in diameter, in cytoplasmic vacuoles of apical enterocytes (Fig 4). Similar virions were found at the cell surface. The brush border of multiple apical enterocytes was degenerate or absent. Affected cells had degranulated endoplasmic reticulum, contained large numbers of intracytoplasmic vacuoles, or were shrunken.

Discussion

Epizootic catarrhal enteritis in ferrets is characterized by outbreaks of green mucoid diarrhea and microscopic findings of lymphocytic enteritis accompanied by villus atrophy, fusion, and blunting and vacuolar degeneration or necrosis of the apical epithelium. Results of the study reported here strongly support the hypothesis that a coronavirus is the etiologic agent of ECE.

The pathogenesis and clinical progression of this condition is similar to enteritis caused by coronaviruses in other species. Infected ferrets often have lethargy and anorexia as initial clinical signs that are evident within 48 to 72 hours after exposure. Vomiting (which may or may not be reported by owners) is the first sign of gastrointestinal tract disease in most ferrets.⁴ Vomiting subsides within hours, and a characteristic profuse green watery-to-mucoid diarrhea ensues. The mucoid nature of the feces in the early stages of this disease is a characteristic finding in ECE and has been described in enteric coronavirus infections in other species.^{5,6} In addition to the characteristic gross and microscopic lesions detected in the study reported here, mesenteric lymph nodes are often enlarged, with moderate to substantial paracortical and follicular hyperplasia being a prominent microscopic finding.

The hypersecretory phase of uncomplicated ECE often resolves within 5 to 7 days in healthy young ferrets, and a subsequent period of maldigestion or malabsorption of widely varying duration may develop.⁴ During the malabsorptive phase of the disease, feces have a characteristic grainy appearance attributable to undigested fats and proteins. Microscopic examination of feces may reveal undigested fat droplets or starch granules but is unreliable, because results are insensitive, imprecise, and may be complicated by increased gastrointestinal transit time in affected ferrets and vari-

able diet composition. Microscopic lesions in jejunal biopsy specimens during this time consist of a combination of villus shortening and widespread lymphocytic enteritis characterized by prominent increases in numbers of intraepithelial lymphocytes and total numbers of lymphocytes within the intestinal submucosa and lymphoid follicles.

The disease often can be correctly diagnosed solely on the basis of characteristic historical findings and clinical signs.⁴ Careful examination of the clinical history will often reveal initial exposure to an asymptomatic ferret (often a kit) 48 to 72 hours prior to the onset of clinical signs.

Clinicopathologic findings are generally nonspecific and attributable to substantial dehydration and inanition in acutely affected ferrets. Inanition causes increased serum activity of alanine aminotransferase and alkaline phosphatase attributable to mobilization of peripheral fat stores to the liver, with resultant hepatocellular swelling.⁴ Leukocytosis may develop in ferrets with concurrent bacterial infections or gastric ulceration. Mild hypoalbuminemia may be the result of a combination of enteritis and malabsorption in chronically affected ferrets. Definitive diagnosis in ferrets with equivocal clinical histories may be accomplished by microscopic examination of intestinal biopsy or necropsy specimens that have characteristic lesions.⁴

Because of the inherent difficulty of propagating coronaviruses in vitro, definitive diagnosis of coronavirus infection in animals is difficult and often frustrating. In acute phases of disease, coronavirus-like particles may be identified by electron microscopic examination of feces. The term "coronavirus-like particle" is used to describe pleomorphic particles ranging in size from 60 to 220 nm with morphology consistent with coronavirus particles, when results of other tests are negative or unavailable.⁷ In chronic stages of the disease, virions may still be intermittently shed in the feces; however, their concentration may be below that necessary for identification. Definitive diagnosis may require alternative diagnostic methods such as viral antigen-specific immunohistochemistry or in-situ hybridization.

Coronaviruses are pleomorphic single-stranded RNA viruses that affect numerous animal species. In several species, including dogs,^{5,8,9} cats,^{2,3,10,11} pigs, cattle, rabbits,¹² mice, rats, poultry, and possibly humans,⁷ coronaviruses are responsible for enteric infection, diarrhea and, in some species, wasting and death. The *Coronavirus* genus contains 4 antigenic groups that contain several species and serotypes. The strong immunoreactivity identified with the monoclonal antibodies used in the study reported here suggests that this particular coronavirus belongs to *Coronavirus* antigenic group 1, a mammalian group containing the coronaviruses that cause transmissible gastroenteritis in pigs, feline infectious peritonitis in cats, and enteritis in dogs.¹³

In most domestic species, enteric infection by coronaviruses results in self-limiting diarrhea. The virus infects mature villus epithelial cells, and subsequent necrosis of these cells results in villus blunting and fusion. Diarrhea is most likely caused by substan-

tial decrease in fluid absorption (passive secretory diarrhea) caused by villus shortening as well as maldigestion caused by loss of brush border enzymes.

Transmission and epidemiologic features of ECE in naive populations are similar to enteric coronaviral infections in other animal species, particularly epizootic catarrhal gastroenteritis in mink.¹ Features include low morbidity in kits, high transmissibility, and low overall mortality rate (< 5%) unless infection is complicated with concurrent bacterial infections or other diseases. Older ferrets with concurrent diseases such as insulinoma, adrenal-associated endocrinopathy, and long-standing gastric infection with *Helicobacter mustelae* often have more severe clinical signs and higher mortality than younger ferrets.⁴ Concurrent bacterial infections have been recognized as an associated risk factor for increased mortality in coronaviral infections.⁹ Early outbreaks of disease similar to ECE developed immediately after ferret shows in which large numbers of ferrets were congregated, and transmission of virus by contaminated handlers could occur. Seasonal increases in outbreaks of ECE, as may occur with coronavirus infection in cattle,¹⁴ have not been reported in ferrets.

Treatment of affected ferrets has been reported⁴ and includes supportive measures such as oral, SC, or IV administration of fluids and electrolytes and oral administration of antimicrobials. If malabsorption develops, oral administration of prednisone and provision of highly digestible nutritional supplements may be beneficial.

^aBiomedica, Foster City, Calif.

^bBrij 35, ICN Aurora, Ohio.

^cSigma Chemical Co, St Louis, Mo.

^dSmithKline Beecham Animal Health, Exton, Pa.

^eSouthern Biotechnology and Assoc Inc, Birmingham, Ala.

^fVectastain ABC Elite, Vector, Burlingame, Calif.

^gSigma Chemical Co, St Louis, Mo.

^hCustom Monoclonals International, West Sacramento, Calif.

ⁱVector Laboratories, Burlingame, Calif.

^jVectastain AK 5001, Vector Laboratories, Burlingame, Calif.

^kVector, SK 5100, Vector Laboratories, Burlingame, Calif.

^lDPX, Fort Washington, Pa.

^mJoel JEM-1000CX, Peabody, Ma.

ⁿEppendorf 5415c, Fischer Scientific, Pittsburg, Pa.

^oAmerican Type Culture Collection, Rockville, Md.

^pAmerican Bioresearch, Sevierville, Tenn.

^qNational Veterinary Services Laboratory, Ames, Iowa.

References

1. Gorham JR, Evermann JF, Ward A. Detection of coronavirus-like particles from mink. *Can J Vet Res* 1990;54:383–384.
2. Kipar A, Kremendahl J, Addie DD, et al. Fatal enteritis associated with coronavirus infection in cats. *J Comp Pathol* 1998;119:1–14.
3. Kipar A, Bellmann S, Kremendahl J, et al. Cellular composition, coronavirus antigen expression and production of specific antibodies in lesions in feline infectious peritonitis. *Vet Immunol Immunopathol* 1998;65:243–257.
4. Williams BH. Epizootic catarrhal enteritis: a novel diarrheal disease in the ferret (*Mustela putorius furo*), in *Proceedings*. 8th Annu Small Mammal Conf, Baltimore, 1997.
5. Keenan KP, Jervis HR, Marchwicki RH, et al. Intestinal infection of neonatal dogs with canine coronavirus 1-71: studies by virologic, histologic, histochemical, and immunofluorescent techniques. *Am J Vet Res* 1976;37:247–256.
6. Shen DT, Gorham JR, Larsen AE, et al. Reviewing the transmission of epizootic catarrhal gastroenteritis. *Vet Med* 1984;79:1501–1504.
7. Glass RI. Other viral agents of gastroenteritis. In: Blaser MJ, ed. *Infections of the gastrointestinal tract*. New York: Raven Press, 1995;1059–1060.
8. Tennant BJ, Gaskell RM, Gaskell CJ. Studies on the epidemiology of canine coronavirus. *Vet Rec* 1993;132:7–11.
9. Hoskins J. Canine viral enteritis. In: Green CE, ed. *Infectious diseases of the dog and cat*. 3rd ed. Philadelphia: WB Saunders Co, 1998;45–47.
10. Dea S, Roy RS, Elazhary MA. Coronavirus-like particles in the feces of a cat with diarrhea. *Can Vet J* 1982;23:153–155.
11. Pedersen NC, Black JW, Boyle JF. Pathogenic differences between various feline coronavirus isolates. *Adv Exp Med Biol* 1984;173:365–380.
12. Eaton P. Preliminary observations on enteritis associated with a coronavirus-like agent in rabbits. *Lab Anim* 1984;18:71–74.
13. Holmes KV, Lai MMC. Coronaviridae: the viruses and their replication. In: Fields BN, ed. *Fundamental virology*. 3rd ed. Philadelphia: Lippincott-Raven Inc, 1996;541–542.
14. Collins JK, Riegal CA, Olson JD, et al. Shedding of enteric coronavirus in adult cattle. *Am J Vet Res* 1987;48:361–365.