

## What Is Your Diagnosis?

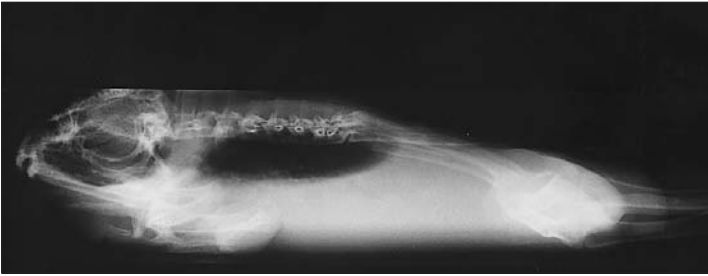
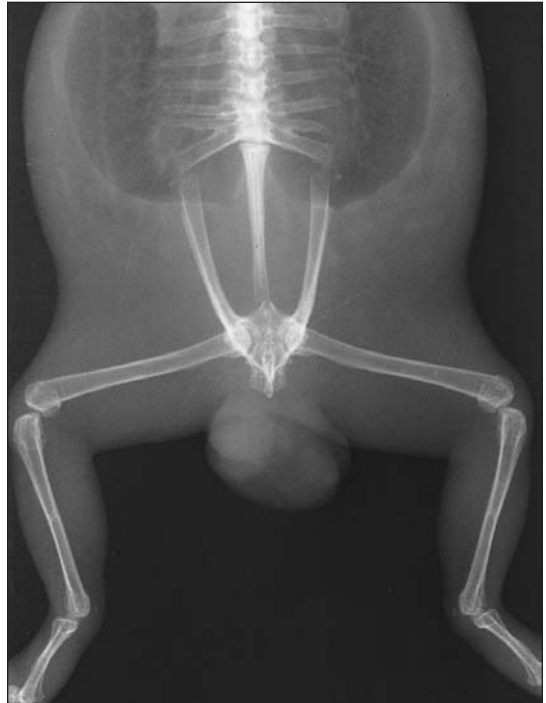


Figure 1—Lateral horizontal beam (left) and dorsoventral (right) radiographic views of a mature male South African bullfrog evaluated because of a cloacal mass.



### History

A mature male South African bullfrog (*Pyxicephalus adspersus*) was evaluated because of a 3-day history of a red fleshy mass protruding from the cloaca. The mass was filled with fluid and reducible with gentle manual palpation. It also had a soft-tissue projection within its interior. No other abnormalities were detected during physical examination. Survey radiographs were obtained (Fig 1).

Determine whether additional imaging studies are required, or make your diagnosis from Figure 1—then turn the page ▶

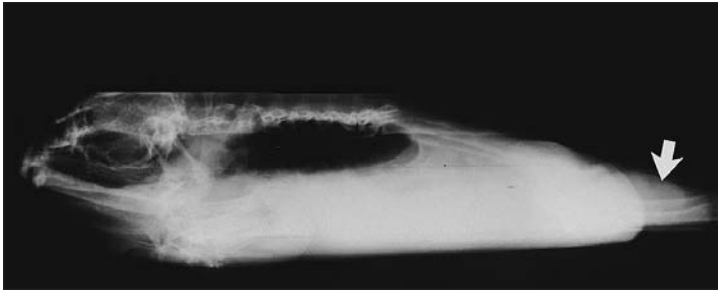
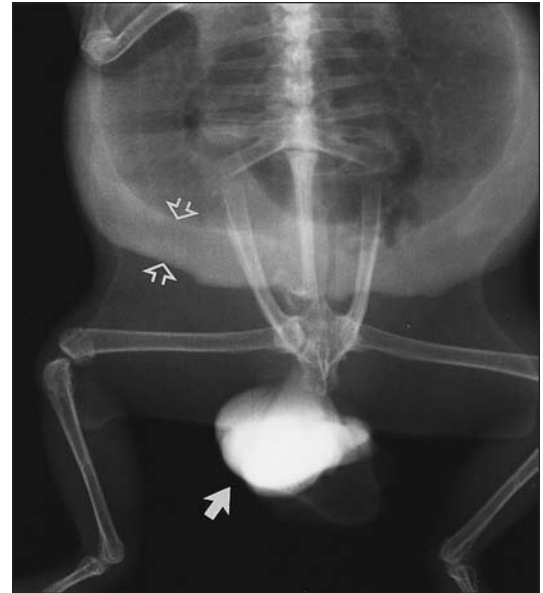

Figure 2—Lateral horizontal beam (left) and dorsoventral (right) radiographic views of the frog described in Figure 1, obtained after injection of 3 ml of contrast material into the mass. Contrast material is evident within the mass (solid arrow) and continuing into the coelomic cavity (open arrows).



## Diagnosis

**Radiographic diagnosis**—A 4-cm mass protruding from the dorsal area of the cloaca.

## Comments

Differential diagnoses for the mass included prolapsed colon, cloaca, or bladder or perineal hernia. To our knowledge, there have only been anecdotal accounts of perineal hernias in amphibians. Cloacal, bladder, and intestinal prolapses have been described in reptiles such as iguanas, tortoises, boids, and crocodylians.<sup>1-4</sup> In these species, prolapses have been associated with dystocia, constipation, gastrointestinal tract obstruction, cystitis, urolithiasis, nematode infestation, and malnutrition.

To better delineate the mass, contrast radiography was performed. Three milliliters of contrast material<sup>a</sup> was injected into the mass with a 25-gauge needle, and radiographs were obtained. Contrast material was evident within the mass and in the coelomic cavity lateral and distal to the lungs, suggesting that the mass and the coelomic cavity were connected (Fig 2).

On the basis of radiographic findings, the diagnosis was perineal hernia. The owner elected to euthanize the frog. Necropsy revealed a 50 × 45 × 20-mm thin-walled sac protruding dorsally over the colon and cloacal orifice, both of which were intact. Serous pink fluid and 1 leaf of the right fat body with its associated vascular pedicle were detected within the sac. Histologic examination revealed degeneration and necrosis of fat cells in the fat bodies and the intestinal

wall. Generalized peritonitis was also evident. Necropsy findings supported the radiographic diagnosis of perineal hernia. Pathogenesis of the hernia in this frog was not clear. However, the owner had administered hormones to stimulate breeding, and we speculate that the hormones may have caused excessive straining and hernia formation.

<sup>a</sup>Renografin 60, Squibb Diagnostics, Princeton, NJ.

1. Bennett AR. Cloacal prolapse. In: Mader DR, ed. *Reptile medicine and surgery*. Philadelphia: WB Saunders Co, 1996;355-358

2. Naylor L. Treatment of cloacal prolapse in the estuarine crocodile, in *Proceedings*. Meet Aust Bident Herpetol Soc 1990;449-451.

3. Bodri MS, Sadanaga KK. Circumcostal cloacapexy in a python. *J Am Vet Med Assoc* 1991;198:297.

4. Bennett RA. Uterine prolapse caused by cystic calculus in a California desert tortoise (*Gopherous agassizi*), in *Proceedings*. Annu North Am Vet Conf 1993;7:766.

This report was submitted by Gregory J. Fleming, DVM, and Ramiro Isaza, DVM, MS, DACZM; from the Department of Clinical Sciences, College of Veterinary Medicine, Kansas State University, Manhattan, KS 66506.