

What Is Your Diagnosis?

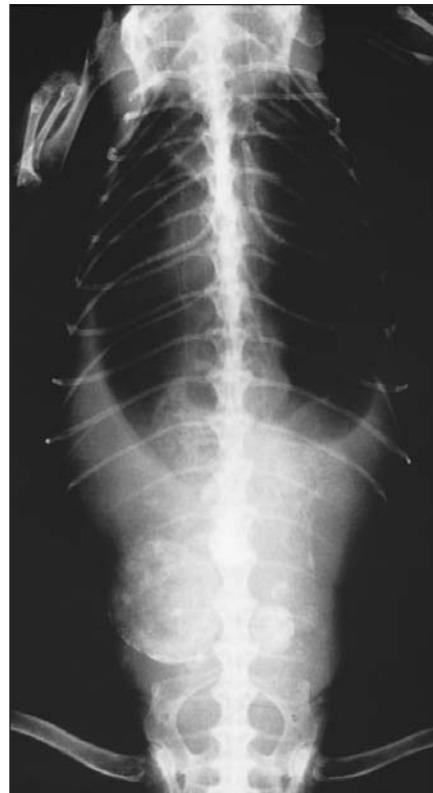
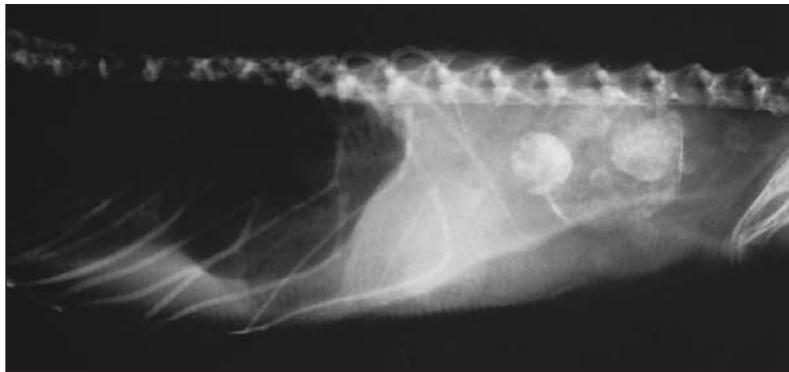
Figure 1—Lateral (left) and dorsoventral (right) radiographic views of a 5-year-old iguana with anorexia and signs of depression.

History

A 5-year-old 2.5-kg (5.5-lb) male iguana (*Iguana iguana*) was evaluated because of anorexia and signs of depression of 2 weeks' duration. The iguana was housed in a 55-gallon aquarium with a focal hot spot and an incandescent bulb to provide heat and ultraviolet light, and was fed a variety of greens and mixed vegetables supplemented at times with vitamins and minerals. On physical examination, the lizard was emaciated, severely lethargic, weak, and moderately dehydrated. A generalized lack of muscle tone was detected, but the skeleton was rigid. A firm, irregular, lobular mass was palpated in the caudal region of the coelom just cranial to the pelvis. Results of CBC and plasma biochemical analyses revealed leukocytosis (18,000 WBC/ μ l; reference range, 1,700 to 15,000 WBC/ μ l) with heterophilia (12,600 heterophils/ μ l; reference range, 85 to 8,250 heterophils/ μ l), hypocalcemia (5.2 mg/dl; reference range, 8 to 12 mg/dl), and hyperphosphatemia (12.4 mg/dl; reference range, 3.5 to 7.0 mg/dl). Whole body radiographs were obtained (Fig 1).

Determine whether additional imaging studies are required, or make your diagnosis from Figure 1—then turn the page ▶

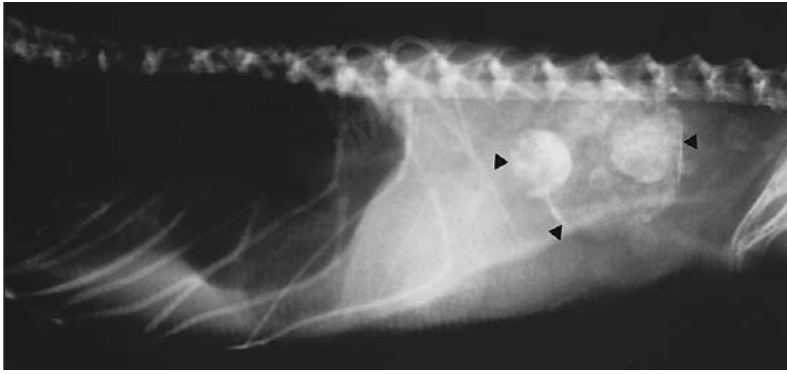
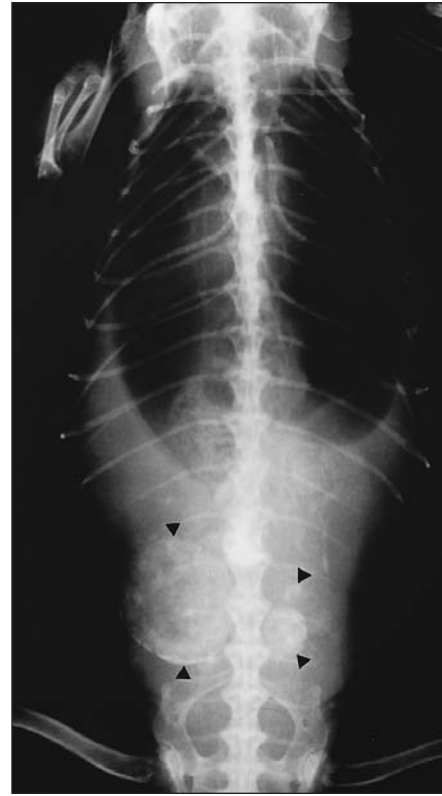


Figure 2—Same radiographic views as in Figure 1. Several masses of various sizes and radiopacities are evident in the caudal region of the coelom (arrowheads).



Diagnosis

Radiographic diagnosis—Multiple, discrete, spherical masses of various sizes and radiopacities in the caudal region of the coelom (Fig 2).

Comments

The radiographic appearance of these masses was consistent with mineral rather than metallic properties. Differential diagnoses for such masses in the caudal region of the coelom of iguanas include cystic calculi, infectious granulomas, neoplasia, and gastrointestinal tract ingesta. However, neoplasia was unlikely, because neoplastic masses in reptiles are not typically radiopaque unless the skeleton is involved. Cystic calculi in iguanas most often appear as single radiopaque lesions with multiple concentric layers.^{1,2} The masses in the iguana of this report had a mottled radiopacity consistent with mineralization, but were more radiolucent than a typical urolith and lacked concentric layers. In addition, these lesions were evident dorsolaterally in the caudal region of the coelom and extended to the level of the vertebrae, a location more consistent with kidneys than urinary bladder. The colon is the only portion of the gastrointestinal tract in this region of the coelom; however, we did not detect radiographic evidence that these masses were within the colon.

The location and radiographic appearance of these lesions along with results of CBC and plasma biochemical analyses were consistent with a diagnosis of renal granuloma that resulted in renal disease or renal disease that resulted in mineralization of the renal parenchyma. An inverse plasma calcium-to-phosphorus concentration ratio, such as that detected in the iguana of this report, is the best indicator of renal disease in reptiles.^{1,3} Metastatic mineralization is also commonly associated with renal disease in iguanas.⁴ We attributed the high WBC count to infection. Although renal tumors can develop in reptiles, most renal masses are abscesses or granulomas rather than tumors.⁴ Contrast cystography or ultrasonography could have been used to confirm the diagnosis; however, the owner elected to proceed with exploratory surgery.

At celiotomy, both kidneys were large and contained multiple, firm, round masses throughout the parenchyma that varied from 5 to 50 mm in diameter. The remaining renal parenchyma was swollen, pale, and firm, and a diagnosis of advanced renal disease was made. Because of the poor prognosis, the owner elected to euthanize the iguana. At necropsy, the kidneys were firm and difficult to cut, suggesting fibroses, and the masses were hard and appeared granular on the cut surface. Histologic evaluation of the kidneys was not performed, but examination of impression smears of renal parenchyma revealed a large number of toxic heterophils and azurophils and multiple colonies of gram-negative rod-shaped bacteria. These findings were consistent with infectious granuloma.

¹Boyer, TH. Clinicopathologic findings in twelve cases of renal failure in *Iguana iguana* (abstr), in *Proceedings*. Assoc Reptil Vet 1996;3:113.

1. Barten SL. Biology: lizards. In: Mader DR, ed. *Reptile medicine and surgery*. Philadelphia: WB Saunders Co, 1996:47–61.

2. Barten SL. Differential diagnosis by symptoms: lizards. In: Mader DR, ed. *Reptile medicine and surgery*. Philadelphia: WB Saunders Co, 1996:324–332.

3. Campbell TW. Clinical pathology. In: Mader DR, ed. *Reptile medicine and surgery*. Philadelphia: WB Saunders Co, 1996:248–257.

4. Done LB. Neoplasia. In: Mader DR, ed. *Reptile medicine and surgery*. Philadelphia: WB Saunders Co, 1996:125–141.

This report submitted by Stephen L. Barten, DVM; from the Vernon Hills Animal Hospital, 1260 Butterfield Rd, Mundelein, IL 60060.