

# Clinical, bacteriologic, serologic, and pathologic features of infections with atypical *Taylorella equigenitalis* in mares

Jonathan B. Katz, DVM, MS; Lawrence E. Evans, DVM, PhD, DACT; David L. Hutto, DVM, PhD, DACVP; Linda C. Schroeder-Tucker, MS; Ann M. Carew, BS; J. Michael Donahue, PhD; Dwight C. Hirsh, DVM, PhD

**Objective**—To characterize clinical, serologic, bacteriologic, cytologic, and pathologic endometrial responses of mares to 2 donkey-origin atypical bacterial isolates resembling *Taylorella equigenitalis*.

**Design**—Prospective in vivo study.

**Animals**—10 healthy mares.

**Procedure**—Mares in estrus (2/group) were inoculated by intrauterine infusion with 2 isolates of classic *T equigenitalis* or 2 isolates of atypical *Taylorella* sp or were sham-inoculated. Bacteriologic, serologic, clinical, uterine, cytologic, and pathologic endometrial responses were assessed 4, 11, 21, 35, and 63 days after inoculation and on day 111 in mares with positive culture results on day 63.

**Results**—One atypical isolate failed to cause infection. The second atypical isolate and both classic *T equigenitalis* isolates induced similar transient metritis and cervicitis. Both classic isolates and 1 atypical isolate induced anti-*T equigenitalis* complement-fixing antibodies detectable at day 11. Classic isolates and an atypical isolate provoked intense neutrophilic endometritis followed by a resolving, subacute, neutrophilic-mononuclear endometrial response. The atypical isolate and classic isolates were recovered from the uterus, clitoral fossa, or clitoral sinus of one or both exposed mares for as long as 111 days.

**Conclusions and Clinical Relevance**—Atypical *Taylorella* sp infections should be considered as a differential diagnosis of equine infertility in US-origin mares, even those not exposed to stallions from countries where contagious equine metritis occurs. The origins and prevalence of atypical *Taylorella* sp infection in US horses and donkeys are undetermined. (*J Am Vet Med Assoc* 2000;216:1945–1948)

**C**ontagious equine metritis (CEM) is a sexually transmitted disease of Equidae resulting from infection with the bacterium *Taylorella equigenitalis*.<sup>1,2</sup> Stallions are often persistent carriers of *T equigenitalis* and do not develop clinical signs, whereas mares are usually transiently infected and have substantial purulent metritis and cervicitis during the acute stage of infection. Although the resulting infertility is usually

From the National Veterinary Services Laboratories, USDA, Animal and Plant Health Inspection Service, Ames, IA 50010 (Katz, Hutto, Schroeder-Tucker, Carew); the Department of Veterinary Clinical Sciences, College of Veterinary Medicine, Iowa State University, Ames, IA 50011 (Evans); Livestock Disease Diagnostic Center, University of Kentucky, Lexington, KY 40546 (Donahue); and the Department of Veterinary Pathology, Microbiology, & Immunology, School of Veterinary Medicine, University of California, Davis, CA 95616 (Hirsh).

temporary, mares may also become carriers of *T equigenitalis*; historically, the infection spreads rapidly following its introduction, causing substantial economic damage in valuable equine breeding populations.<sup>1-3</sup> Since the early 1980s, many nations, including the United States, have required strict regulatory testing of mares and stallions considered for importation in an effort to prevent introduction of CEM. This testing includes repeated bacteriologic and serologic testing of mares, bacteriologic testing of stallions, and bacteriologic and serologic testing of sentinel mares bred to those stallions.<sup>1,2</sup> Although CEM was diagnosed in the United States in the late 1970s, the disease was subsequently eradicated and has not occurred in the United States since that time.<sup>2</sup> In addition, *T equigenitalis* has not been isolated from US-origin Equidae since that time.

In late 1997, the National Veterinary Services Laboratories (NVSL) confirmed the identity of a bacterial isolate from a donkey jack in California as *T equigenitalis*, although colony morphology, growth rate, and immunofluorescence characteristics differed slightly from those of reference and recent European-origin *T equigenitalis* isolates. In early 1998, similar atypical isolates were confirmed from 2 jacks and mares bred to them in Kentucky. In both instances, the primary isolates were referred to the NVSL by state livestock disease diagnostic laboratories after detection by microbiologic and serologic testing during routine regulatory testing of the jacks.<sup>a,b</sup> Subsequent epidemiologic investigation did not reveal foreign contacts for any of the animals involved and did not detect epidemiologic connection between the animals in Kentucky and California. Clinical disease was not observed in any of the infected animals.

The 2 isolates were confirmed as *T equigenitalis* on the basis of their cultural and biochemical properties, cell wall fatty acid composition, and reactivity with an anti-*T equigenitalis* polyclonal fluorescent antibody conjugate. The new isolates, however, uniformly were slower growing than classic *T equigenitalis* isolates and did not react with 2 specific anti-*T equigenitalis* monoclonal fluorescent antibody conjugates. Sequence analyses of the DNA encoding their 16S ribosomal RNA confirmed that these isolates were closely related but not identical to numerous classic *T equigenitalis* isolates.<sup>a,b</sup> The new species name, *T asinigenitalis*, has been proposed for the classification of this newly discovered donkey-origin *Taylorella* sp.<sup>a</sup>

The unexpected and apparently independent emergence of 2 similar donkey-origin atypical *Taylorella* isolates within a population of Equidae pre-

sumed free of CEM for many years prompted the study reported here. The objective of the study reported here was to characterize clinical, serologic, bacteriologic, cytologic, and pathologic endometrial responses of mares exposed to these 2 isolates. Additional mares were exposed to 2 classic *T equigenitalis* isolates for comparison.

## Materials and Methods

**Horses and inoculations**—Ten healthy 2- to 4-year-old mares were brought into estrus by cloprostenol<sup>f</sup> treatment. Two mares, serving as controls, received an intrauterine infusion of 20 ml of sterile Eugon broth (7% CO<sub>2</sub>; 37 C; without streptomycin) used to grow the *Taylorella* organisms infused into the other mares. A second pair of mares each received 10<sup>6</sup> viable classic *T equigenitalis* maintained at the NVSL since receipt from Great Britain (ECMO isolate) in 1979. A third pair of mares was similarly infused with 10<sup>6</sup> viable classic *T equigenitalis* isolated from a German (GER isolate) stallion in 1997. The fourth and fifth pairs of mares received the atypical Kentucky (KY isolate) and California (CA isolate) donkey isolates, respectively, by use of 20-ml intrauterine infusions of Eugon medium containing 10<sup>6</sup> viable bacteria. The use of 2 mares/isolate was necessary as a result of space, biosecurity, cost, and experimental complexity considerations. This sample size allowed for clinical comparison of several isolates under identical experimental conditions but precluded a statistical approach to group comparisons.

**Diagnostic procedures**—All mares were evaluated 7 days prior to and at intervals following intrauterine infusion. The external genitalia of each mare was visually evaluated, followed by speculum examination of the vagina and external cervical os. The endometrium, clitoral fossa, and clitoral sinuses were then swabbed separately<sup>4,†</sup> for bacteriologic recovery of *Taylorella* organisms by use of selective and non-selective media.<sup>4</sup> Endometrial swab specimens were also used to prepare smears for cytologic examination, and endometrial biopsy specimens were procured and placed in neutral-buffered 10% formalin. Ten-milliliter blood samples were obtained and the derived sera used for analysis of anti-*T equigenitalis* antibody activity as measured by the complement fixation (CF) test.<sup>5</sup> All procedures were repeated on all mares on postinoculation day (PID) 4, 11, 21, 35, and 63. Mares with positive culture results at PID 63 were evaluated by bacteriologic culture again at PID 111.

Swab specimens cultured on selective and nonselective media were incubated at 37 C in 7% CO<sub>2</sub> for up to 10 days. Colonies with characteristics typical of *Taylorella* sp were further tested for catalase, cytochrome oxidase, and alkaline phosphatase activity; colonies with positive results were tested for additional biochemical properties of *T equigenitalis* by use of a commercial biochemistry test strip.<sup>4,8</sup> Final positive confirmation was attained by use of fluorescent antibody examination with monoclonal and monospecific polyclonal *T equigenitalis* antibody conjugates.<sup>6,b</sup> Colony counts on culture plates were scored as follows: 1+, 1 to 15 colonies/plate; 2+, 16 to 50 colonies/plate; and 3+, > 50 colonies/plate. Endometrial cytologic smears were stained with Wright-Giemsa stain and examined by use of bright-field microscopy. Endometrial biopsy specimens were processed by use of standard methods, stained with H&E, and examined by use of bright-field microscopy. Serum CF titers against CEM were expressed as the reciprocal of the highest 4-fold serial dilution that completely fixed complement. Clinical appraisal included observation for cloudy or purulent cervical or vaginal discharge, streaking of the external cervical os caused by inflammation, and transrectal palpation of the ovaries and uterus for evidence of induration, fluid

accumulation, or disturbances in the expected length and progress of normal cyclic changes associated with estrus.

## Results

Six of the 10 mares in the study became infected with *Taylorella* sp. The 2 sham-inoculated mares and the 2 mares exposed to the CA isolate did not become infected, as judged by lack of seroconversion, lack of recovery of *Taylorella* sp from uterus, clitoral fossa, or clitoral sinus, lack of microscopic endometrial lesions, minimal transitory (PID 4 to 11) neutrophilic responses to intrauterine infusions detected by cytologic examination, and lack of clinical signs of infection.

**Bacteriologic culture**—At PID 4 and 11, *Taylorella* sp were cultured from all 3 sampling sites of all mares exposed to the ECMO, GER, and KY *Taylorella* isolates. Colony counts of uterine swab specimens were scored 2+ or 3+ in all mares, whereas counts for clitoral fossa and sinus swab specimens were more variable (1+ to 3+). At PID 21 and 35, one of the mares inoculated with the GER isolate had positive results (1+) for culture of clitoral sinus swab specimens alone; culture results were negative thereafter. The second mare in this group had positive culture results (3+) for all 3 sites at PID 21, positive results for clitoral fossa and sinus swab specimens until > PID 35, and positive results (1+ to 2+) for uterine swab specimens through PID 111. Specimens from the 2 mares inoculated with the ECMO isolate yielded much fewer (1+ to 2+) colonies and only intermittently at any given site, including the uterus. After PID 35, one of these mares had consistent negative culture results, whereas specimens from the second mare yielded organisms (1+) only from the clitoral fossa at PID 63 and the uterus at PID 111.

Similarly, specimens from the 2 mares inoculated with the KY isolate only yielded colony counts of 1+ to 2+ after PID 11. One of these mares shed bacteria (1+) through PID 111 but only from the uterus, whereas the other mare had positive culture results for all locations at PID 21 but positive results (1+) only for the clitoral sinus at PID 35 and, thereafter, uniformly negative culture results. Isolated *Taylorella* sp were of the same phenotype (classic or atypical) as were inoculated into each mare.

**Serologic results**—All 6 infected mares seroconverted (CF titer  $\geq$  1:4) by PID 11; mares inoculated with ECMO and GER isolates had titer of 1:64, and mares inoculated with the KY isolate had titer of 1:16. Mares inoculated with ECMO and GER isolates maintained 1:64 titers at PID 21, whereas both mares inoculated with the KY isolate had titers that increased to 1:32. Thereafter, titers waned rapidly, and by PID 63, seronegative results were detected for both mares inoculated with the GER isolate and 1 mare inoculated with the KY isolate; the second mare inoculated with the KY isolate and both mares inoculated with the ECMO isolate had positive CF titers of only 1:4.

**Cytologic and histologic results**—Lesions were qualitatively similar in all 6 infected mares, regardless of isolate. Acute lesions (those detected from PID 4 to 11) consisted of moderate numbers of neutrophils and

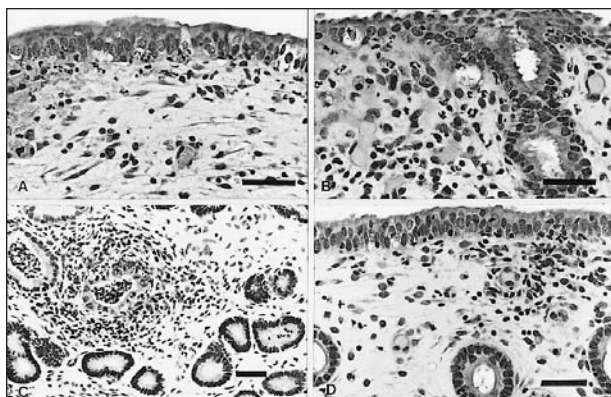


Figure 1—Photomicrographs of sections of endometrial biopsy specimens collected from mares exposed by intrauterine infusion to *Taylorella equigenitalis* or atypical *Taylorella* isolates. H&E stain; bars = 40  $\mu$ m. A—Tissue obtained 4 days after intrauterine infusion with *T. equigenitalis*. Notice small to moderate numbers of subepithelial and intraepithelial neutrophils. B—Tissues obtained 4 days after intrauterine infusion with an atypical *Taylorella* isolate. Notice small to moderate numbers of subepithelial and intraepithelial neutrophils. C—Tissue obtained 21 days after intrauterine infusion with *T. equigenitalis*. Notice clumps of necrotic neutrophils within glandular lumina and periglandular aggregates of neutrophils and mononuclear cells. D—Tissues obtained 21 days after intrauterine infusion with an atypical *Taylorella* isolate. Notice focal subepithelial aggregate of mononuclear cells and small numbers of neutrophils.

small numbers of eosinophils within the endometrial epithelium and the superficial portion of the stratum compactum (Fig 1A and B). This correlated well with results of cytologic examination, which revealed an intense neutrophilic response from PID 4 to 11. In all mares except 1 mare inoculated with the GER isolate, cytologic evidence of neutrophilic inflammation became negligible by PID 21. In histologic specimens obtained at PID 21, however, neutrophils persisted in the superficial endometrium and were mixed with lesser numbers of plasma cells and lymphocytes (Fig 1C and D). By PID 35 to 63, endometrial inflammatory responses in most of these 6 mares consisted primarily of mild, superficial mononuclear cell infiltrates. However, 1 mare inoculated with the ECMO isolate and 1 mare inoculated with the KY isolate, both of which had positive culture results through PID 111, had pronounced chronic inflammation consisting of perivascular and periglandular aggregates of lymphocytes, plasma cells, and a few neutrophils. Overall, 3 of the 4 mares inoculated with the classic type ECMO and GER *Taylorella* isolates maintained some degree of superficial endometrial inflammation throughout the entire experimental period, as did 1 mare inoculated with the KY isolate.

**Clinical findings**—All mares exposed to the GER and ECMO isolates developed cloudy vaginal and cervical discharges and intense cervical reddening by PID 4; at that time, signs were virtually absent in the mares exposed to the KY isolate. By PID 11, however, mares exposed to the KY isolate developed cervicitis, and both mares had cloudy vaginal discharge and wet, matted tails. By PID 11, only the 4 mares inoculated with the ECMO and GER isolates had palpably indurated uterine walls. Cervicitis and uterine induration persisted in 1 of the mares inoculated with the GER strain and

both mares inoculated with the ECMO strain through PID 21. One of the mares inoculated with the KY isolate had slight uterine induration only at PID 21, and by PID 35, all mares were clinically normal and remained so for the balance of the experimental period. Both control mares and the 2 mares exposed to the CA isolate maintained normal cyclic ovarian and uterine estrus rhythms during the experimental period. Each of the 6 infected mares, however, returned to estrus prematurely at least once during the first 21 days after inoculation. After PID 35, these mares also maintained normal cyclic estrus rhythms.

## Discussion

Contagious equine metritis was first diagnosed as an infectious cause of equine infertility in Europe in the late 1970s and was first reported in the United States in 1978.<sup>1,3</sup> Regulatory testing and hygienic procedures rapidly controlled and eliminated the disease from the United States in the early 1980s.<sup>1,2</sup> Despite continuous serologic and bacteriologic surveillance of high-risk breeding Equidae and Asinidae in the United States since that time, there was no evidence of *T. equigenitalis* infections in domestic equids until late 1997. The discovery of 2 apparently epidemiologically independent atypical *Taylorella* isolates in male donkeys at that time was an unexpected consequence of regulatory testing.

Although the number of mares used in the study reported here was small and not appropriate for statistical analyses, certain findings were clinically important. Mares were infused with  $10^6$  viable *Taylorella* organisms, which, by historical standards of previous CEM studies, was only a modest challenge inoculation.<sup>7-9</sup> Nevertheless, both classic-type isolates and the atypical KY isolate clearly established infections that persisted in some mares for at least 111 days after inoculation. *Taylorella equigenitalis* isolates do vary in pathogenicity and are somewhat pleomorphic in colonial morphology following animal passage.<sup>8-11</sup> In our study, recovered atypical KY isolates were, however, of a uniformly small colony phenotype. In the 1980s, small-colony variants of classic *T. equigenitalis* were observed and were pathogenic, but they could be recovered in either large or small colony form after animal passage.<sup>9</sup> Detailed antigenic and molecular genetic analyses were not performed on those earlier variants, but such analyses and the apparently stable colony phenotype of the recently discovered atypical *Taylorella* isolates suggest that these isolates may not simply be variants of a classic *T. equigenitalis* organism introduced into US domestic Equidae.<sup>11,12,a,b</sup>

The atypical KY isolate has been transmitted from jacks to mares by natural service, whereas attempts to transmit the CA donkey isolate to mares by artificial insemination have failed.<sup>a</sup> This is consistent with the inability to infect mares with the CA isolate in the study reported here and merits further investigation to determine whether mares are, in fact, relatively refractory to infection with this isolate, compared with other isolates.

Clinically, mares exposed to the KY isolate responded several days later and with less intensity



than the 4 mares exposed to the classic *T. equigenitalis* isolates. However, both mares inoculated with the KY isolate did develop abnormal vaginal and cervical discharges, cervicitis, and shortened estrus cycles; 1 mare also had palpable transient uterine induration. Cytologic and histologic examinations revealed inflammation and supported the presumption that this isolate may induce at least transient fertility impairment in exposed mares. Consistent with results of previous studies of experimental CEM infections, results of our study indicated that all infected mares became clinically normal rapidly, although pathologic and serologic changes lingered for variable periods after clinical recovery.<sup>7,8,13,14</sup> Importantly, *Taylorella* sp were recovered throughout the entire 111-day experimental period from one of each pair of mares inoculated with the KY, ECMO, and GER isolates.

Results of the study reported here indicate that one of the recently isolated genetically and antigenically atypical *Taylorella* isolates will infect mares at estrus, inducing clinical, serologic, and pathologic changes that closely resemble classic CEM. The origin, distribution, and prevalence of these atypical organisms in US Equidae and Asinidae are unknown. Despite continued routine regulatory testing for CEM, further bacteriologic or serologic evidence of atypical *Taylorella* infections has not been detected since 1998. The United States is still currently considered CEM-free, but veterinary practitioners, educators, and regulatory personnel should be aware that these atypical donkey-origin *Taylorella* isolates may still exist within the United States.

<sup>a</sup>Jang SS, School of Veterinary Medicine, University of California, Davis, Calif: Personal communication, 1998.

<sup>b</sup>Donahue M, Livestock Disease Diagnostic Center, University of Kentucky, Lexington, Ky: Personal communication, 1998.

<sup>c</sup>Estrumate, Bayer Corp, Shawnee Mission, Kan.

<sup>d</sup>Type 1 Calgiswab, Spectrum Laboratories, Houston, Tex.

<sup>e</sup>Transystem Transport Swabs, Copan Diagnostics Inc, Corona, Calif.

<sup>f</sup>Accu-culshure Uterine Culture System, Accu-med Inc, Pleasantville, NY.

<sup>g</sup>API ZYM Test Strip 20 NE, bioMerieux SA, Marcy l'étoile, France.

<sup>h</sup>Institut Pourquier, Montpellier, France.

## References

1. Swerczek TW. Contagious equine metritis. In: Buisch WW, Hyde JL, Mebus CA, eds. *Foreign animal diseases*. Richmond, Va: United States Animal Health Association, 1992;160–170.
2. Timoney PJ. Contagious equine metritis. *Comp Immunol Microbiol Infect Dis* 1996;19:199–204.
3. Swerczek TW. The first occurrence of contagious equine metritis in the United States. *J Am Vet Med Assoc* 1978;173:405–407.
4. Mackintosh ME. Contagious equine metritis. In: *Office of international epizootics manual of recommended diagnostic techniques and requirements for biological products for list A and B diseases 1990*. Vol II. Paris: Office International Des Epizooties, 1990;1–5.
5. Croxton-Smith P, Benson JA, Dawson FLM, et al. A complement fixation test for antibody to the contagious equine metritis organism. *Vet Rec* 1978;103:275–278.
6. Gradinaru DA, Helmer JM, Klein F. Production and characterization of monoclonal antibodies against *Taylorella equigenitalis*. *Vet Res* 1997;28:65–76.
7. Rommel FA, Sahu SP. Contagious equine metritis: antibody response of experimentally infected pony mares. *Vet Immunol Immunopathol* 1981;2:201–213.
8. Rogerson BA, Condson RJ, Baker J, et al. Experimental infection of mares with *Hemophilus equigenitalis*. *Aust Vet J* 1984;61:392–395.
9. Sahu SP, Weber S. Contagious equine metritis: effect of intrauterine inoculation of tiny colony forms in pony mares. *Vet Rec* 1982;110:250–251.
10. Hitchcock PJ, Brown TM, Corwin D, et al. Morphology of three strains of contagious equine metritis organism. *Infect Immun* 1985;48:94–108.
11. Thoresen SI, Jenkins A, Ask E. Genetic homogeneity of *Taylorella equigenitalis* from Norwegian trotting horses revealed by chromosomal DNA fingerprinting. *J Clin Microbiol* 1995;33:233–234.
12. Matsuda M, Miyazawa T, Anzai T. Detection of a common genotype among strains of *Taylorella equigenitalis* isolated from Thoroughbred horses in Japan between 1994 and 1996. *J Basic Microbiol* 1999;2:127–130.
13. Benson JA, Dawson FLM, Surront DS, et al. Serological response in mares affected by contagious equine metritis. *Vet Rec* 1977;102:277–280.
14. Sahu SP, Rommel FA, Fales WH, et al. Evaluation of various serotests to detect antibodies in ponies and horses infected with contagious equine metritis bacteria. *Am J Vet Res* 1983;44:1405–1409.