

Open-chest cardiopulmonary resuscitation through a transdiaphragmatic approach in dogs: a cadaveric study to describe the surgical approach and manipulations

Jinsu Kang, DVM, PhD^{1*} , and F. A. Mann, DVM, MS, DACVS, DACVECC² 

¹Department of Veterinary Surgery, College of Veterinary Medicine, Kyungpook National University, Daegu, Korea

²Department of Veterinary Medicine and Surgery, College of Veterinary Medicine, University of Missouri, Columbia, MO

*Corresponding author: Dr. Kang (jskang@knu.ac.kr)

OBJECTIVE

To describe the detailed surgical procedure for open-chest CPR (OC-CPR) through a transdiaphragmatic (TD) approach during planned laparotomy and to evaluate the procedure time and damage to organs.

ANIMALS

7 mixed-breed canine cadavers.

METHODS

The procedure was divided into 3 stages. Durations for each of the 3 stages of the procedure and total time from diaphragmatic incision to the end of Rumel tourniquet application were recorded. Subjective assessment of ease of procedures and postprocedural physical evaluation of thoracoabdominal organs were also performed.

RESULTS

Mean time from diaphragmatic incision to pericardiotomy was 15.1 seconds (SD, 4.0). Performing 10 cardiac compressions took 12.0 seconds (SD, 1.8). Dissection of the aorta and application of a Rumel tourniquet took 130.4 seconds (SD, 52.2). The mean total time from start of first procedure to end of last procedure was 157.6 seconds (SD, 21.5). The mean length of diaphragmatic incision was 11.5 cm (SD, 2.2). Lung laceration was identified in one dog, and liver laceration was identified in another dog. The mean ease of pericardiotomy was 10, and application of a Rumel tourniquet was 4 (SD, 1.9). There was no instance of abdominal organs moving into the thoracic cavity during the procedure in any of the dogs.

CLINICAL RELEVANCE

Resuscitation techniques during TD OC-CPR can be performed with acceptable timing and effort, except for aortic Rumel tourniquet application, which was difficult and time consuming. Avoidable damage to thoracoabdominal organs can occur.

Keywords: open-chest cardiopulmonary resuscitation, transdiaphragmatic approach, canine, pericardiotomy, rumel tourniquet

Open-chest CPR (OC-CPR) through an emergent thoracotomy was the standard of care for cardiopulmonary arrest (CPA) in the early 20th century.¹ The 2020 American Heart Association Guidelines for Cardiopulmonary Resuscitation and Emergency Cardiovascular Care state that OC-CPR may be recommended or considered for specific indications.²

Similarly, the recommendations from the 2012 Reassessment Campaign on Veterinary Resuscitation guidelines state that OC-CPR should be considered for dogs in cases of ineffective of closed-chest CPR (CC-CPR) efforts, pericardial effusion, pleural space disease, and thoracic wall trauma.^{3,4}

Traditionally, in dogs and cats, OC-CPR has been performed through a lateral thoracotomy at the fourth, fifth, or sixth intercostal space (ICS).^{5,6} However, OC-CPR through a transdiaphragmatic (TD) approach has been described and can be performed either during abdominal surgical procedures⁵ or as a stand-alone approach.⁷ The TD approach

Received April 15, 2024

Accepted June 27, 2024

Published online July 11, 2024

doi.org/10.2460/ajvr.24.04.0109

© 2024 THE AUTHORS. Published by the American Veterinary Medical Association as an Open Access article under Creative Commons CCBY-NC license.

avoids complications such as laceration of lateral thoracic vessels and rib fractures secondary to overzealous retraction with a rib retractor that can occur through ICS thoracotomy.^{8,9} Experimentally, cardiac index, mean arterial blood pressure, and carotid artery blood flow are increased with a TD approach compared to CC-CPR in dogs.¹⁰

Despite these findings, few veterinarians perform OC-CPR because of technical difficulties, cost of successful resuscitation, and risk for significant organ damage.⁹ The TD approach uses a ventral midline laparotomy, which is more familiar to many veterinarians than ICS thoracotomy. However, there is a lack of veterinary literature describing the detailed process of OC-CPR through a TD approach.

This study describes the detailed surgical procedure for OC-CPR through a TD approach during planned laparotomy and provides instructions for performing this method. Additionally, we measured the time for this procedure and evaluated the organ damage during the procedure.

Methods

Specimens

Seven canine cadavers were acquired for this study. These dogs were procured from animal shelters and euthanized for shelter management reasons unrelated to this study. The Institutional Animal Care and Use Committee did not require approval for research performed on cadavers. Body weight, size, apparent breed, approximate age, sex, body condition score,¹¹ and maximal chest circumference were recorded for each cadaver. The sizes of the dogs were divided according to the adult body weight classification,¹² and the ages of the dogs were assessed using dental evaluation.¹³

The experiments on 4 cadavers were conducted on the morning following euthanasia. Three cadavers were procured frozen and stored at 5 °C for 1 week. To accelerate thawing, cadavers were placed outside the cooler at room temperature (approx 22 °C) for a few hours.

Description of procedure

The experiments on the 7 specimens were conducted over a period of 2 weeks. All procedures were performed by the same investigator (JK), referred to below as the resuscitator. The resuscitator's hand size was a 7.0 surgical glove size. Prior to conducting the study, the investigators reviewed the method of a TD approach, pericardiectomy, internal cardiac compression, and aortic occlusion using a Rumel tourniquet^{6,7,9} and then practiced on 2 adult feline cadavers and 1 canine cadaver acquired from similar sources as the study subjects. The Rumel tourniquet was premade with a piece of silastic tubing placed over the tips of mosquito hemostatic forceps.⁶ Umbilical tape was used as the encircling portion, and the outer diameter of the silastic tubing was 8 mm, with an inner diameter of 6 mm. The silastic tubing was preplaced on the forceps before grasping the umbilical tape for the purpose of easily transferring over the ends of the tape.

All dogs were positioned in dorsal recumbence. To simulate a planned laparotomy situation, the cadavers were shaved of hair from 10 cm cranial to the xiphoid to caudal to the brim of the pelvis and lateral to the mammary glands to at least the level of the ventral border of the ribs. A skin incision was made starting 5 cm cranial to the xiphoid and extending caudally to the brim of the pelvis using a #10 scalpel blade. After making a stab incision in the linea alba with the scalpel, Mayo scissors were used to extend the linea alba incision from xiphoid to pubis. The falciform ligament was transected using Mayo scissors at its origin on the ventral midline.

To begin TD OC-CPR, a stab incision was made in the left ventral pars sternalis with tissue forceps and a scalpel blade. Reflecting the emergency when a single resuscitator performs the procedure, no retraction instruments were used. The incision was made adjacent to the sternum to minimize inadvertent trauma to the thoracic organs (eg, heart or lung) (**Figure 1**). The curved incision was extended paracostally with Mayo scissors close to the ribs, large enough for the resuscitator to pass a flat hand into the thorax for internal cardiac compressions (Figure 1).

For the pericardiectomy, the phrenicopericardial ligament was grasped and retracted caudally with the thumb and index finger of the left hand (Figure 1), and Metzenbaum scissors were used to perforate the pericardium at its apex. Then, 1 of the blades of the Metzenbaum scissors was inserted to extend the pericardial incision ventral to the phrenic nerve (Figure 1). The ventral edge of the diaphragmatic incision was lifted upward using the left hand while entering the right hand through the diaphragmatic incision to grasp the heart (Figure 1). To minimize finger damage to the heart, the hand was cupped around the heart (**Figure 2**), and direct compression of the heart was performed 10 times using a one-handed technique, and the ideal rate of compressions was 100 to 120 per minute.⁴

After completing the heart compressions, the left caudal lung lobe was retracted cranially with the left hand to visualize the thoracic portion of the descending aorta (**Figure 3**). Using curved mosquito hemostatic forceps in the right hand, the connective tissue around the descending aorta was penetrated immediately cranial to the diaphragm, and umbilical tape was grasped with the jaws of the curved mosquito hemostatic forceps (Figure 3). After passing the umbilical tape around the aorta (Figure 3), both ends of the umbilical tape were then grasped with the tips of the mosquito hemostatic forceps, and the silastic tubing (premade Rumel tourniquet) was slid over both ends of the umbilical tape and down toward the aorta (Figure 3). The mosquito hemostatic forceps were then reset onto the umbilical tape strands against the silastic tubing to tighten the umbilical tape around the aorta, maintaining the aorta in a collapsed position (Figure 3).

Procedure durations

The TD OC-CPR procedure was divided into 3 stages to measure the total duration and amount

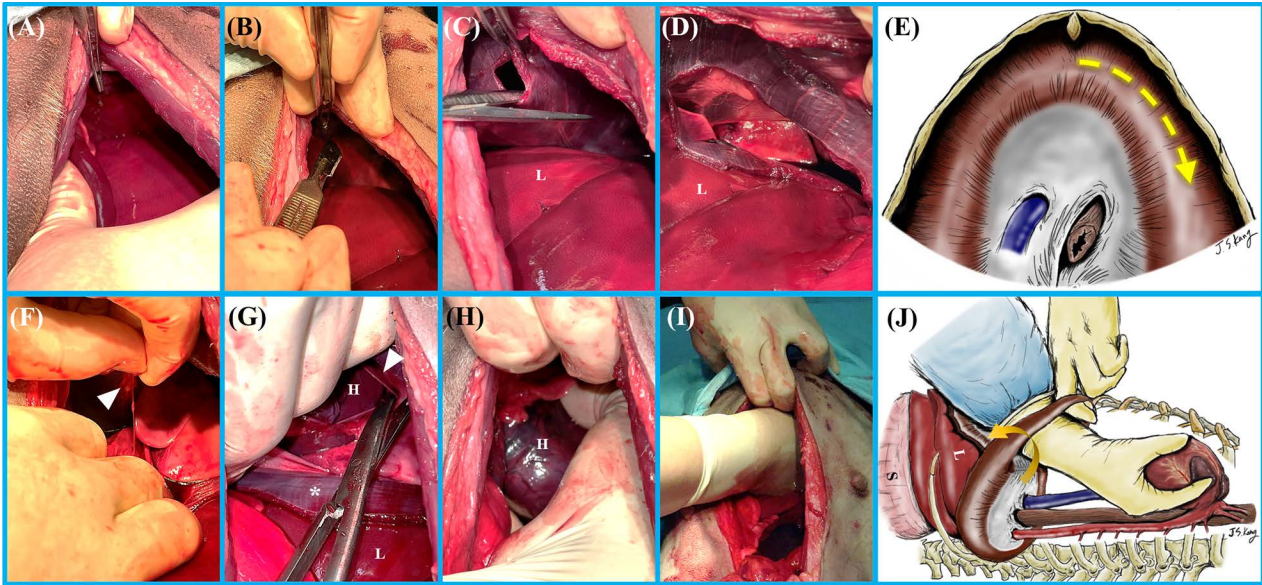


Figure 1—The procedure of open-chest cardiopulmonary resuscitation through a transdiaphragmatic approach in a canine cadaver. A and B—The stab incision was made in the left ventral pars sternalis with tissue forceps and a scalpel blade. C and D—The incision was made adjacent to the sternum and extended paracostally with Mayo scissors close to the ribs, large enough for the resuscitator to pass a flat hand into the thorax for cardiac compressions. E—The course of the left diaphragmatic incision. F—The phrenicopericardial ligament (white arrowhead) was grasped and retracted caudally with the resuscitator’s left hand. G—Using Metzenbaum scissors, the pericardium was perforated at its apex, and the pericardial incision extended to grasp the heart. H and I—The ventral edge of the diaphragmatic incision was retracted upward with the left hand while passing the right hand through the diaphragmatic incision to grasp the heart. J—One-handed cardiac compression with the liver and stomach under the reflected diaphragmatic flap (curved arrow). The white arrowheads indicate phrenicopericardial ligament. H = Heart. L = Liver. S = Stomach. *Costal part of diaphragm.

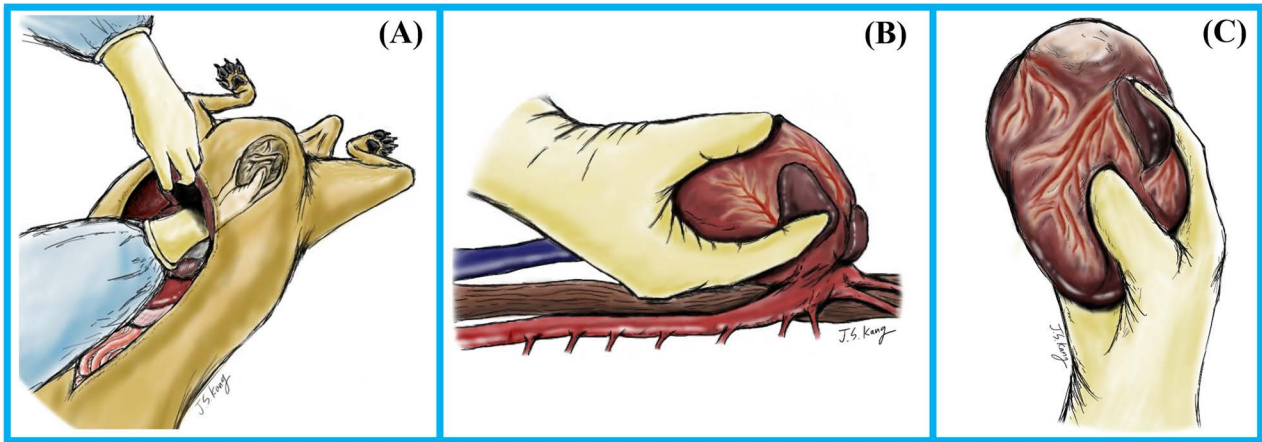


Figure 2—One-handed technique for open-chest cardiopulmonary resuscitation through a transdiaphragmatic approach in dogs. A–C—The right hand is cupped around the heart to directly compress the heart while avoiding inadvertent penetration of the heart muscle with fingertips.

of time for each stage. All procedural durations were measured with a continuously running stopwatch in a mobile phone (iPhone 12 Pro; Apple Inc). For consistency, all time measurements were conducted by the same recorder (FAM). No interruptions occurred between the 3 stages. The first stage was the process from the initiation of the diaphragmatic incision to the finish of the pericardiotomy. At the initiation of the diaphragmatic incision, the resuscitator said “start” to the recorder, who initiated the stopwatch.

After the pericardiotomy was performed and the heart was grasped, the resuscitator said “stop,” and the recorder pressed the “lap button” to record the time. The second stage consisted of 10 manual cardiac compressions. The beginning of this stage was at the previous “stop” and continued until the resuscitator said “stop” to indicate the end of the last compression, at which time the recorder pressed the “lap button” to record this time. The third stage began immediately after the last cardiac compression

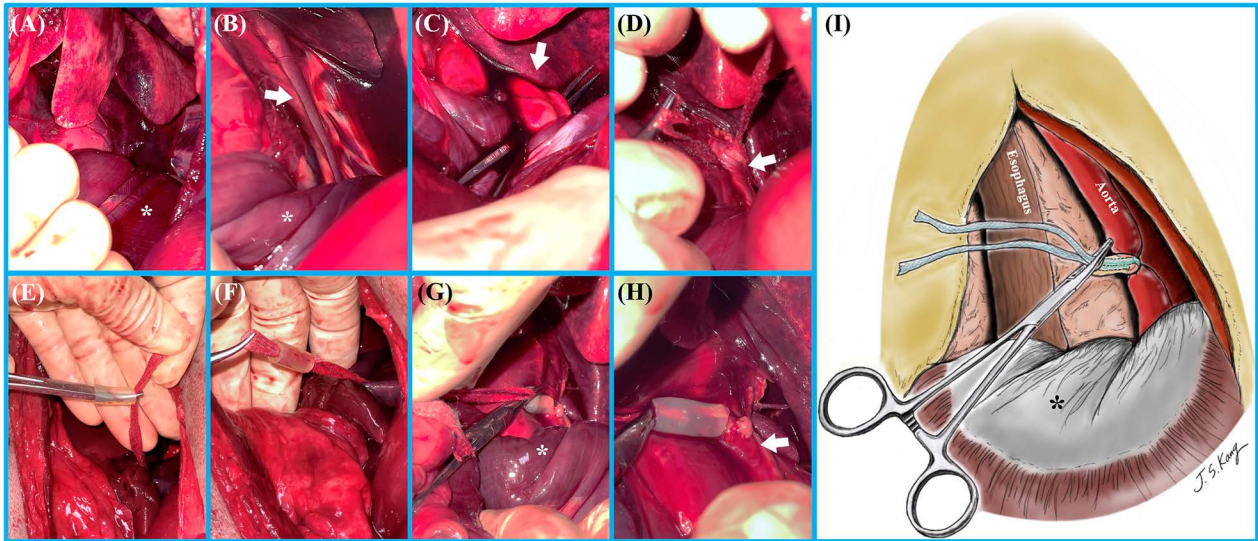


Figure 3—The procedure for occluding the intrathoracic aorta using a custom-made Rumel tourniquet during open-chest cardiopulmonary resuscitation through a transdiaphragmatic approach in a canine cadaver. A–B—The left caudal lung lobe was retracted cranially with the left hand to visualize the descending aorta. C—Using a curved mosquito hemostatic forceps, the connective tissue around the descending aorta immediately cranial to the diaphragm was penetrated. D—Umbilical tape was grasped with the jaws of the forceps and passed around the aorta. E—A Rumel tourniquet was made with a 2-cm length of silastic tubing (outer diameter, 6.5 mm; inner diameter, 3 mm) slipped onto the end of mosquito hemostatic forceps, which would eventually grasp umbilical tape. F–H—Both ends of the umbilical tape were grasped with the jaws of the custom-made Rumel tourniquet, and the silastic tubing was slid down both ends of the umbilical tape toward the aorta. I and J—The mosquito hemostatic forceps was reset onto the umbilical tape strands against the silastic tubing to maintain the aorta in a collapsed position. K—The final Rumel tourniquet application. The white arrows indicate aorta. *Costal part of diaphragm.

and was the isolation of the aorta and the application of a Rumel tourniquet. After finishing this stage, the resuscitator said “stop” to the recorder, which was the end of the entire procedure.

Intraprocedural and postprocedural evaluations

During the procedure, when the abdominal organs moved into the thoracic cavity, the resuscitator informed the recorder of the occurrences, and the total number of occurrences was recorded. At the end of the timed procedures, the resuscitator subjectively assessed the ease of 2 procedures (pericardiotomy and application of a Rumel tourniquet) using a 1 to 10 scale, with 10 being the easiest and 1 being the most difficult.

After measuring the length of the diaphragmatic incision, a scalpel was used to make bilateral cranial-caudal incisions at the mid portion of the thorax. Then, a pruning shear was used to cut the ribs, allowing the ventral portion of the thorax to be retracted cranially, exposing the thoracic and abdominal organs. The following organs were then assessed for damage: heart; lung, esophagus, phrenic nerve, aorta, caudal vena cava, liver, and stomach. Then, to evaluate the lung for evidence of laceration, endotracheal intubation was performed, and the endotracheal tube cuff was inflated. Then, tap water was poured into the thoracic cavity, and the lungs were inflated using a bag-valve resuscitator as the thoracic cavity was checked for air bubbles. Other

organs were visually assessed and palpated to look for damage.

Data analysis

An a priori power analysis was not performed. Descriptive statistics were generated for body weight, body condition score, circumference of chest, surgical time, incision length of diaphragm, and ease of procedure (pericardiotomy and application of a Rumel tourniquet). Numerical data are presented as mean \pm standard deviation unless otherwise stated. All data calculations were performed using SPSS, version 26.0 (IBM Corp).

Results

Signalment data

The mean body weight of the 7 dogs in this study was 23.1 kg (SD, 4.2). According to the classification based on body weight, 3 large-sized dogs and 4 medium-sized dogs were used.¹² All 7 dogs were mixed-breed adult males (**Table 1**).

Procedural durations

The mean time interval from diaphragmatic incision to pericardiotomy was 15.1 seconds (SD, 4.0). The 10 cardiac compressions took 12.0 seconds (SD, 1.8). Dissection of the aorta and application of a Rumel tourniquet took 130.4 seconds (SD, 52.2). The mean total procedural duration was 157.6 seconds (SD, 21.5).

Table 1—Body weight, size, signalment, body condition score, and thoracic circumference of canine cadavers (n = 7) used for open-chest cardiopulmonary resuscitation through a transdiaphragmatic approach.

Cadaver number	Body weight (kg)	Size (small, medium, large) ^a	Apparent breed	Approximate age ^b	Sex	Body condition score (1–9)	Maximal chest circumference (cm)
1	25.5	Large	Mixed breed	Adult	Male	5	61.0
2	15.5	Medium	Mixed breed	Adult	Male	5	53.0
3	22.4	Medium	Mixed breed	Adult	Male	6	59.0
4	20.6	Medium	Mixed breed	Adult	Male	5	57.5
5	25.7	Large	Mixed breed	Adult	Male	6	59.5
6	23.7	Medium	Mixed breed	Adult	Male	6	60.0
7	28.1	Large	Mixed breed	Adult	Male	7	59.5
Mean value (SD)	23.1 (4.2)	—	—	—	—	5.7 (0.8)	58.5 (2.6)

^aBreed size classification according to the adult body weight (small, < 15 kg; medium, 15 to 25 kg; large, > 25 kg).¹² ^bAge of cadavers was assessed using dentition.¹³

Intraprocedural and postprocedural evaluations

There were no instances of abdominal organs moving into the thoracic cavity during the procedure in any of the dogs. The ease of pericardiectomy was 10 in all dogs. The mean ease of Rumel tourniquet application was 4 (SD, 1.9). The mean diaphragmatic incision length was 11.5 cm (SD, 2.2; n = 6 due to absence of the diaphragm incision measurement in dog number 3). A lung laceration was identified in dog number 1, and a liver laceration was identified in dog number 4. The liver injury of dog number 4 was measured to be less than 1 cm.

Discussion

This study describes the technique of OC-CPR through a TD approach and evaluated some of its procedural components. To simulate OC-CPR during CPA as it would occur during standard laparotomy, all the procedures were performed using basic surgical instruments. Furthermore, considering the limited surgical space and the difficulty in visualizing the area for cardiac compressions, the feasibility of a single surgeon performing this procedure was assessed.

The diaphragm was incised in a curved shape along the ribs and used as a retractor to minimize the obstruction of visualization by the abdominal organs moving into the thoracic cavity. In particular, the procedure of dissecting the aorta for the application of a Rumel tourniquet was facilitated by manually supporting the incised diaphragm surrounding the abdominal organs. Containing the abdominal organs beneath the incised diaphragm allowed the procedure to be performed without visual obstruction of the surgical field.

This study assumed the occurrence of CPA during planned laparotomy and began time measurement at the beginning of the diaphragmatic incision. As a result, it is not possible to adequately compare the duration of resuscitative techniques in this study with a previous study⁹ that began time evaluation with the skin incision. Regardless of method, the speed of resuscitative techniques is likely influenced by resuscitator experience. As the experiments progressed in this study, the total procedure time

decreased, and the procedural duration for the initially conducted specimen (cadaver number 1) was more than two-fold longer than for the last specimen (cadaver number 7). The average veterinarian might expect a longer duration of resuscitative procedures because the infrequency of CPA during laparotomy will not provide as quick a learning curve as occurred in this cadaver study.

Cardiac compression can be performed using 1 hand, between 2 hands, or between the internal chest wall and a hand.¹⁴ In this study, the resuscitator used one hand to hold and retract the ventral edge of the diaphragmatic incision upward to enhance visibility while using the other hand to perform cardiac compressions. However, if the heart is not small enough to grasp with 1 hand, it can be squeezed between 2 hands. In the two-handed method, a “hinged clapping” motion from the palms to the fingertips compressing the heart from the apex to the aortic root is preferred.^{14,15} At least 1 study has shown that the two-handed technique can be more beneficial than providing cardiac compression with the one-handed technique.¹⁴ However, the use of both hands may be limited by factors such as patient size, heart size, patient conformation, the entry site into the thoracic cavity, and the availability of appropriate instruments, such as rib retractors, during thoracotomy approaches.¹⁴ The size of the resuscitator’s hands may also determine whether the one- or two-handed technique is appropriate. Therefore, it is recommended to consider situational factors when deciding which technique to choose.

Massaging an empty heart is ineffective and cannot restore circulation, but once adequate cardiac filling is achieved, the ejection fraction during direct cardiac massage can be as high as 60%.¹⁶ Initial aortic crossclamping during CPR is performed to maximize perfusion to the brain, heart, and lungs and increase coronary and cerebral perfusion pressures.^{7,16} Also, crossclamping of the descending aorta just above the diaphragm reduces bleeding from intraabdominal or lower extremity injuries.¹⁶ Furthermore, in cases where abdominal arterial injuries have occurred, there is also a possibility that aortic occlusion could limit additional hemorrhage and provide a relatively bloodless field for the operating surgeon.¹⁷ However, aortic crossclamp time should be minimized, and

slow removal and reperfusion of the abdominal viscera should be initiated as soon as hemostasis in the abdomen is achieved.¹⁶ To validate the effects of aortic crossclamping demonstrated in veterinary medicine, further clinical research is needed to investigate the impact of aortic crossclamping on the success of CPR and the effects of aortic clamp time on the cardiovascular system. Establishing the effectiveness of aortic occlusion is warranted to justify the time spent performing this maneuver.

Lung trauma is a potential complication in OC-CPR via lateral thoracotomy and is a significant contributor to morbidity in human medicine.¹⁸ Lung injury can result in the need for additional surgeries, prolonged surgical time, and an increased risk of perioperative complications that can be life threatening in an already severely compromised patient.⁹ Lung injury is presumed to occur due to the close proximity of the lung to the incision site and the requirement for rapid access to the thoracic cavity.⁹ To avoid lung injury in this study, the resuscitator grasped the diaphragm with thumb forceps and pulled it toward the abdomen before puncturing the diaphragm with a scalpel. Lung laceration occurred in the first cadaver but none of the others, suggesting that resuscitator experience and familiarity with this surgical anatomy could play a factor in lung injury. Liver laceration occurred in 1 case (case number 4). The liver laceration is presumed to have occurred due to the inadvertent release of the instruments used to hold the diaphragm during the scalpel stab incision. As such, it appears that the stab incision of the diaphragm is the portion of the TD OC-CPR procedure most prone to inducing complications. Due to the limitations of the cadaveric study, it is not possible to assess the effect of bleeding or other consequences of organ injuries. However, the observed liver injury was small, less than 1 cm, and it is speculated to be a minor injury that could be controlled with various hemostatic methods (eg, gelatin foam, digital pressure) rather than requiring additional surgical intervention in a clinical situation.

This study evaluated the feasibility of utilizing a transected diaphragm during temporary aortic occlusion to minimize the movement of abdominal organs into the thoracic cavity during temporary aortic occlusion compared to the existing literature on TD OC-CPR.⁹ Additionally, it aimed to provide a detailed description of the TD OC-CPR procedure to better explain it to clinical veterinarians.

This study had some limitations. First, the number of specimens was limited, and there was no control group. Further research should be conducted to compare the safety and efficacy of various cardiac compression techniques using a TD approach. Second, because stored cadavers were used for this study, it was not possible to evaluate the various conditions that may occur in acutely deceased and resuscitated dogs. Evaluating the effects of organ movement and bleeding on the procedure cannot be accurately evaluated in cadaveric dogs. Third, in this study, no experiment was performed on small-breed dogs and giant-breed dogs. In small-breed dogs, it is

possible that only the one-handed technique may be feasible, and in extremely small-sized dogs, there is a possibility that the entire 1 hand may not pass into the thoracic cavity. Therefore, it may be necessary to consider alternative methods of cardiac compression other than the ones described above. Similarly, in giant-breed dogs, the one-handed technique may be inadequate, and use of a two-handed technique should be considered. In the future, further original studies are needed to determine which method is most effective for dogs of different sizes. Fourth, unlike CC-CPR, surgical procedures are involved in OC-CPR, necessitating familiarity with the basic surgical instruments and regional anatomy. Since the entire intrathoracic anatomy cannot be seen during pericardiectomy in a TD approach, it is important to have a sufficient understanding of the surrounding anatomical structures and to exercise appropriate caution to prevent injury that could be problematic if resuscitation is successful. Fifth, the timings to different CPR interventions via the TD approach were not compared to a lateral thoracotomy approach. To assess the effectiveness of the TD OC-CPR approach more objectively, it is necessary to investigate the time difference between the TD approach and the lateral thoracotomy approach with multiple investigators.

In conclusion, resuscitation techniques during TD OC-CPR can be performed with acceptable timing and effort, except for aortic Rumel tourniquet application, which was difficult and time consuming. The TD OC-CPR approach described here is a feasible option for cases of CPA during abdominal surgical procedures, although damage to thoracoabdominal organs can occur. The primary aim of this study was to describe the detailed surgical procedure for the OC-CPR through a TD approach. The initial incision in the diaphragm seems to be the point of most caution to avoid inadvertent organ injury. This study suggests that using the incised diaphragm as a retractor can be helpful in minimizing the interference of abdominal organs moving into the thoracic cavity, thereby reducing visual obstruction and potential delays in resuscitative efforts. Furthermore, it was confirmed that a single veterinary practitioner can perform the OC-CPR through a TD approach without significant difficulty. Additional clinical research is needed to evaluate the safety and efficacy of this procedure, along with guidelines for compression techniques specific to dogs of different sizes.

Acknowledgments

None reported.

Disclosures

The authors have nothing to disclose. No AI-assisted technologies were used in the generation of this manuscript.

Funding

The authors have nothing to disclose.

ORCID

J. Kang  <https://orcid.org/0000-0001-5501-7983>
F.A. Mann  <https://orcid.org/0000-0001-6181-0216>

References

1. Safar P. On the history of modern resuscitation. *Crit Care Med.* 1996;24(suppl 2):3S-S11. doi:10.1097/00003246-199602000-00044
2. Panchal AR, Bartos JA, Cabañas JG, et al. Part 3: adult basic and advanced life support: 2020 American heart association guidelines for cardiopulmonary resuscitation and emergency cardiovascular care. *Circulation.* 2020;142(16)(suppl 2):S366-S468. doi:10.1161/CIR.0000000000000916
3. Rozanski EA, Rush JE, Buckley GJ, Fletcher DJ, Boller M; RECOVER Advanced Life Support Domain Worksheet Authors. RECOVER evidence and knowledge gap analysis on veterinary CPR. Part 4: advanced life support. *J Vet Emerg Crit Care.* 2012;22(suppl 1):S44-S64.
4. Fletcher DJ, Boller M, Brainard BM, et al. RECOVER evidence and knowledge gap analysis on veterinary CPR. Part 7: clinical guidelines. *J Vet Emerg Crit Care.* 2012;22(suppl 1):S102-S131.
5. Haskins SC. Cardiopulmonary-cerebral resuscitation (CPCR). In: Macintire DK, Drobatz KJ, Haskins SC, Saxon WD, eds. *Manual of Small Animal Emergency and Critical Care Medicine.* 2nd ed. John Wiley & Sons; 2012 :21-29.
6. Warang AM, Mann FA, Middleton JR, Wagner-Mann C, Branson K. Comparison of left fourth and fifth intercostal space thoracotomy for open-chest cardiopulmonary resuscitation in dogs. *J Vet Emerg Crit Care.* 2021;31(3):331-339. doi:10.1111/vec.13059
7. Wierenga JR, Crosse KR. Open-chest cardiopulmonary cerebral resuscitation. In: Burkitt Creedon JM, Davis H, eds. *Advanced Monitoring and Procedures for Small Animal Emergency and Critical Care.* 2nd ed. Wiley-Blackwell; 2023:271-280.
8. McIntyre RL, Hopper K, Epstein SE. Assessment of cardiopulmonary resuscitation in 121 dogs and 30 cats at a university teaching hospital (2009-2012). *J Vet Emerg Crit Care.* 2014;24(6):693-704.
9. Jack MW, Wierenga JR, Bridges JP, Baltzer WI, Crosse KR. Feasibility of open-chest cardiopulmonary resuscitation through a transdiaphragmatic approach in dogs. *Vet Surg.* 2019;48(6):1042-1049. doi:10.1111/vsu.13234
10. Rieder C, Crawford B, Iliopoulos J, Thomas JH, Pierce GE, Hermreck AS. A study of the techniques of cardiac massage with the abdomen open. *Surgery.* 1985;98(4):824-830.
11. Laflamme D. Development and validation of a body condition score system for dogs. *Canine Pract.* 1997;22:10-15.
12. Mila H, Grellet A, Feugier A, Chastant-Maillard S. Differential impact of birth weight and early growth on neonatal mortality in puppies. *J Anim Sci.* 2015;93(9):4436-4442.
13. Sutton LK, Byrd JH, Brooks JW. Age determination in dogs and cats. In: Brooks JW, ed. *Veterinary Forensic Pathology.* Vol 2. Springer; 2018:151-163. doi:10.1007/978-3-319-67175-8_11
14. Spoerke NJ, Trunkey DD. Emergency department thoracotomy. In: Cameron JL, Cameron AM, eds. *Current Surgical Therapy.* 10th ed. Elsevier Saunders; 2011:906-909.
15. Cothren CC, Moore EE. Emergency department thoracotomy. In: Feliciano DV, Mattox KL, Moore EE, eds. *Trauma.* 6th ed. McGraw-Hill; 2008:245-259.
16. Pust GD, Namias N. Resuscitative thoracotomy. *Int J Surg.* 2016;33(Pt B):202-208. doi:10.1016/j.ijsu.2016.04.006
17. Seamon MJ, Pathak AS, Bradley KM, et al. Emergency department thoracotomy: still useful after abdominal exsanguination? *J Trauma.* 2008;64(1):1-7. doi:10.1097/TA.0b013e3181606125
18. Jones KM, Menaker J. Emergent resuscitative thoracotomy, open cardiac massage, and aortic occlusion. In: Ganti L, ed. *Atlas of Emergency Medicine Procedures.* Springer; 2016:163-169. doi:10.1007/978-1-4939-2507-0_26