

# Preliminary experience with robotic cholecystectomy illustrates feasibility in a canine cadaver model

Nicole Buote, DVM, DACVS<sup>1\*</sup>; Antoine Chalon, PhD<sup>2,3</sup>; Jérôme Maire, DVM<sup>2,4</sup>; Nicolas Berte, MD<sup>5</sup>; Nguyen Tran, PhD<sup>2,3</sup>; Charles Mazeaud, MD<sup>6</sup>

<sup>1</sup>Department of Clinical Sciences, Soft Tissue Surgery, College of Veterinary Medicine, Cornell University, Ithaca, NY

<sup>2</sup>Velvet Innovative Technologies, Nancy, France

<sup>3</sup>Nancy School of Surgery, Université de Lorraine, Vandoeuvre-lès-Nancy, France

<sup>4</sup>Veterinary Polyclinic, Vetonimo, Vandoeuvre-lès-Nancy, France

<sup>5</sup>Department of Pediatric Surgery, CHRU Nancy, Université de Lorraine, Nancy, France

<sup>6</sup>Department of Urology, CHRU Nancy Brabois University Hospital, IADI-UL-INSERM (U1254), Vandoeuvre-lès-Nancy, France

\*Corresponding author: Dr. Buote (njb235@cornell.edu)

Received April 6, 2023

Accepted July 10, 2023

doi.org/10.2460/ajvr.23.04.0069

## OBJECTIVE

To evaluate the feasibility and describe the relevant differences between robotic cholecystectomy (RC) and laparoscopic cholecystectomy in a canine model.

## SAMPLE

Canine cadavers (n = 4) weighing between 30 and 42 kg.

## METHODS

Dogs were positioned in dorsal recumbency. A surgical robot was used to perform the RC and was placed at the cranial aspect of the surgical table. One 12-mm and 3 8-mm robotic ports and 1 5-mm laparoscopic port were placed as needed to perform the RC. The specific steps of the procedure were described and timed. Perceived differences between psychomotor skills between robotics and laparoscopy were noted.

## RESULTS

RC was successful in all dogs, but minor intraoperative complications did occur during the manipulation of the gallbladder in 1 dog. The median length of time for ports to be appropriately docked was 19.5 minutes, and the median procedure time was 119.5 minutes. Psychomotor skills specific to robotics can be learned during this procedure.

## CLINICAL RELEVANCE

Robotic cholecystectomy is feasible. RC allowed for experience with the different psychomotor skills utilized with robotic instrumentation and may be an appropriate training procedure for veterinary surgeons wishing to gain basic experience with robotic instrumentation.

**Keywords:** robotic surgery, cholecystectomy, surgical simulation, training model

Robotic surgery has been performed in human medicine since the 1980s<sup>1-3</sup> but is only in its infancy in veterinary medicine. Even though most procedures are attempted in animal models before being performed on human patients, the expense of surgical robots and their instrumentation has excluded veterinary patients from these advanced techniques until recently.<sup>4,5</sup> In human surgery, robotic instrumentation is most commonly used for urogenital, bariatric, cardiovascular, orthopedic, and oropharyngeal procedures.<sup>6-12</sup> While adult patients most commonly reap the benefits of robotic surgery, pediatric patients are beginning to realize the advantages of

these innovative machines as well, improving the possibility for veterinary applications.<sup>13,14</sup> The major advantages of robotic surgery include the versatility of a 3-D field of view, which is beginning to be used in laparoscopy, and enhanced dexterity in instrumentation with improved degrees of freedom and articulation.<sup>15</sup> These improvements combined with the standard magnification and illumination seen with laparoscopy allow for precise suturing and enhanced dissection in tight spaces.<sup>15</sup> There are also benefits to surgeons regarding musculoskeletal injuries and ergonomics.<sup>16-19</sup> These advantages can lead to improved surgical outcomes and increased

productivity as surgeons are not absent from work due to injuries.<sup>20-22</sup> The limitations of robotics are not trivial. The cost of the surgical robot, surgeon console (SC), and simulators for training and the physical space requirements are considerable. Robotic instrumentation is also unique in that there is a maximum number of uses per device, monitored by computer software. This negates the typical veterinary tactic of indefinite resterilization. As with any new surgical skill, a learning curve will also need to be overcome, but human studies have illustrated a steep learning curve in robotics<sup>23-25</sup> and recent work in veterinary medicine has shown similar results with robotic simulators.<sup>26</sup>

Laparoscopic cholecystectomy (LC) has gained popularity in veterinary medicine due to decreased patient morbidity.<sup>27-29</sup> Robotic cholecystectomy (RC) has been described in human medicine<sup>30,31</sup> and was chosen as an ideal procedure for veterinary robotic training due to familiarity with the procedural steps, the ability to convert to laparoscopic or open approaches if needed, and a readily available caseload once clinical implementation begins. When introducing novel instrumentation, beginning with procedures well known to the surgeon is helpful as was done when laparoscopy sterilization procedures began in earnest in veterinary medicine.<sup>32,33</sup> Our study objectives were 2-fold. First, to evaluate the feasibility of RC in a canine model by using a commercially available surgical robot. Second, to identify the relevant differences between RC and LC.

## Methods

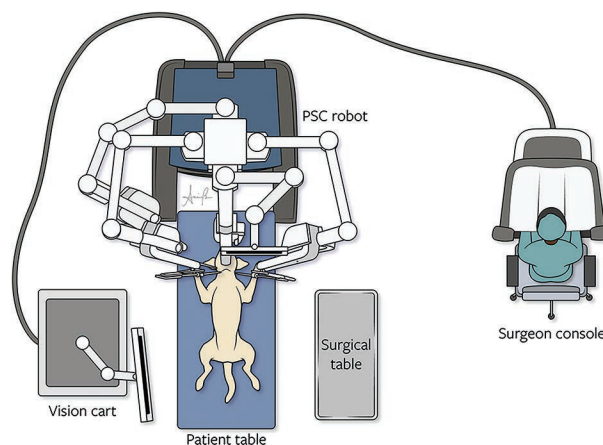
### Animals

Four large-breed canine cadavers from dogs euthanized for reasons unrelated to the current study were donated to the institution where the study was performed for use in research between April 1, 2022, through May 1, 2022. This laboratory specializes in laparoscopic and robotic surgery training and research and has French government approval for animal experimentation. All procedures followed the NIH *Guidelines of the Guide for the Care and Use of Laboratory Animals* and were in accordance with French legislation (Ministerial Authorization No. C54-547-5). Consent for body donation was signed by owners, and permission to transport the bodies was granted by the relevant authorities. Cadavers were thawed at room temperature before use for a median of 60 hours (range, 48 to 72 hours). Two large-breed dogs euthanized for reasons unrelated to the current study were included after the initial study to gather comparison data on LC.

### Operating room, surgical equipment, port placement, and docking for RC

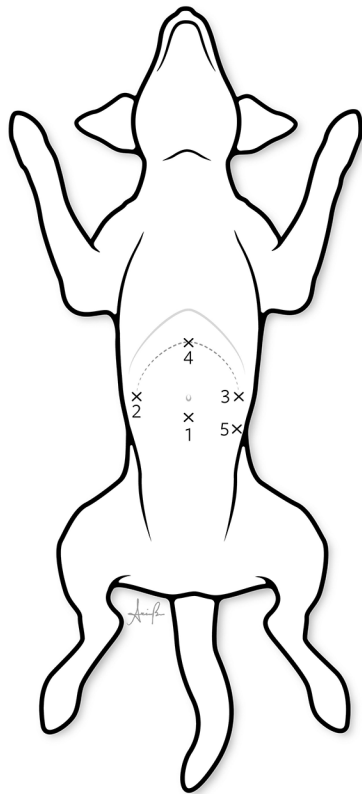
The components of the Da Vinci Surgical System include the SC, vision cart (VC), and the patient-side cart (PSC). The PSC used for this study was a 4-armed Da Vinci Si Surgical Robot (Intuitive Surgical, Inc), which was placed at the head of the surgical table. The SC, which controls the instrumentation and

visualization of the operative field, was positioned out of the operative field to the left side of the patient. The VC, which contained the optical light source, electrosurgical unit, and optical integration unit, was also placed out of the operative field to the right side of the patient table. The PSC was the only component docked within the surgical field and was covered in sterile drapes. A surgical instrument table for the assistant was placed directly to the left of the patient table (**Figure 1**). Dogs were positioned in dorsal recumbency in left oblique 1 (15° to 20°) and reverse Trendelenburg position (15°). Once dogs were positioned, the PSC was moved into position and the 12-mm 30° robotic telescope (Intuitive Surgical, Inc) was white and 3-D balanced. All ports were placed by 1 surgeon (N Buote), but a surgical assistant was present as needed to perform instrument switches and manipulate a laparoscopic instrument. Initial port access for the camera was performed via the modified Hasson technique for a 12-mm optical cannula (Bladeless Trocar Versaport; Medtronic Covidien) at a 2-cm subumbilical position (port 1), and the abdomen was insufflated to 10 mm Hg. The first robotic arm was moved into position and attached or “docked” to the port requiring appropriate seating of the robotic arm flanges to engage the port rim and lock into place. The telescope camera component was placed into the port and locked into the arm of the robot.



**Figure 1**—Diagram of equipment placement in the surgical suite for robotic cholecystectomy. PSC = Patient side cart.

Next, 3 8-mm robotic instrument ports were placed under visualization in the following locations to create an inverted “U” caudal to the rib cage (**Figure 2**): right paracostal 8 cm laterally to umbilicus (port 2), left paracostal 8 cm laterally to umbilicus (port 3), and 2 cm caudal to xiphoid (port 4). This placement was based on authors’ (AC, N Buote, CM) experience with robotic cholecystectomy. A black line along the shaft of these ports (Intuitive Surgical, Inc) designated the appropriate depth of the port to avoid inappropriate pressure or movement of the port against the body wall during the



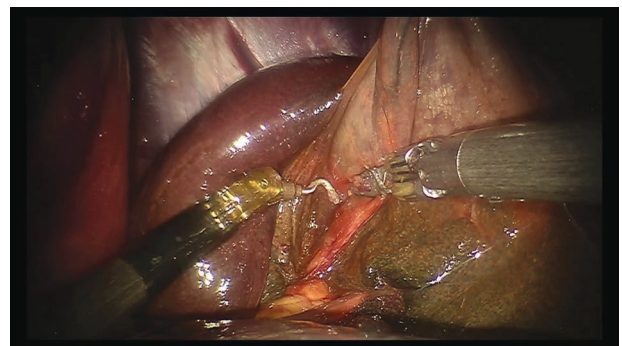
**Figure 2**—Diagram of port placement for robotic cholecystectomy. Port 1 (12 mm) = Camera port. Port 2 to 4 (8 mm) = Robotic instrument ports. Port 5 (5 mm) = Laparoscopic instrument port.

procedure and to ensure a static pivot point for the robotic arm. A 5-mm laparoscopic port (Medtronic Covidien) was placed 3 cm caudal to port 3 if needed (port 5). All ports were docked to robotic arms and placed through a range of motion to ensure conflicts did not occur and appropriate cannula depth was achieved. The left lateral port (port 3) arm was adjusted by swinging the arm as lateral as possible to decrease conflicts between the camera port (port 1) and the xiphoid port (port 2), which were more medially placed over the midline of the patient.

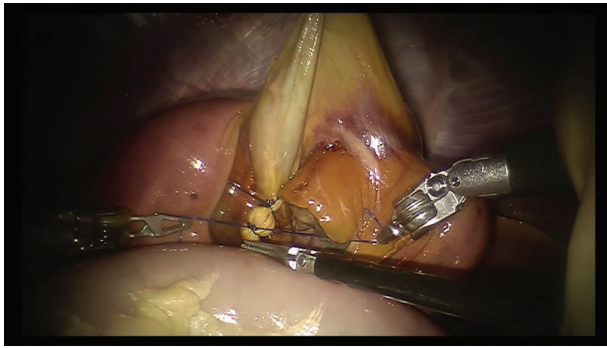
### Surgical procedure

RC was performed in all cases by a single surgeon with over 17 years of experience in laparoscopy and over 1,000 hours of experience with a robotic simulator (Mimic DV Trainer; Surgical Science). The veterinary surgeon had no prior experience with a Da Vinci surgical robot but was advised by human physicians with a combined experience level of 3 decades. A brief exploration was performed, and transection of any obvious adhesions was performed with robotic scissors or monopolar L-hook through ports 2 or 3. Robotic instrumentation used included Maryland bipolar forceps, a permanent monopolar L-hook cautery, Prograsp forceps, monopolar curved Metzenbaum scissors, and large needle drivers (Intuitive Surgical). Laparoscopic instrumentation included Maryland dissectors and curved

Metzenbaum scissors (Karl Storz), which were used to bring the suture into the abdomen and cut the suture after ligation. The complete specific steps of the procedure and times for each step were recorded (**Supplementary Table S1**). Initially, the robotic grasping forceps were placed through port 4 to grasp and elevate the apex of the gallbladder in a ventral and cranial direction toward the diaphragm. Once the visualization of the cystic and common bile duct was optimized, the grasping instrument was locked in place on the infundibulum of the gallbladder by the surgeon at the SC by using the clutch function to switch activity to 1 of the other ports. A robotic monopolar L-hook cautery was initially placed in port 2 and fenestrated grasping forceps through port 3 by the surgical assistant, and dissection of the cystic duct was performed (**Figure 3; Supplementary Video S1**). Dissection of the cystic duct within Calot's triangle continued proximally until visualization of the first hepatic duct entering the common bile duct. Instruments were exchanged as needed for safe dissection. Robotic large needle drivers were then placed in port 3, and a 6-cm length of 3-0 vicryl was placed into the abdomen through the laparoscopic port (port 5) by the surgical assistant. This suture was used to double-ligate the cystic duct proximally. An additional suture was used to place a single ligature distally, and the cystic duct was then transected between the most distal suture and the middle suture (**Figure 4; Supplementary Video S2**). The gallbladder was subserosally dissected from liver parenchyma with a combination of robotic Metzenbaum scissors used with or without monopolar cautery and Prograsp grasping forceps. In 2 cases, the gallbladder was released by the instrument in port 4 and the cystic duct was grasped to aid in dissection. In the other 2 cases, the gallbladder was dissected with the original grasping forceps in place. Once dissection was complete, the instrument was removed from port 3, and the robotic arm was undocked and moved laterally. A sample retrieval bag (Inzii Universal Retrieval System; Applied Medical) was placed into port 3 within the abdomen and used to remove the gallbladder.



**Figure 3**—Intraabdominal photograph of robotic monopolar L-hook cautery placed through port 2 and robotic fenestrated grasping forceps through port 3 for dissection of the cystic duct during a robotic cholecystectomy. Photographs are from cadavers of 4 client-owned dogs euthanized for unrelated reasons between April 1 and May 1, 2022.



**Figure 4**—Intraabdominal photograph of double suture cystic duct ligation. Robotic fenestrated grasping forceps were placed in port 2, robotic large needle drivers were placed in port 3, and a laparoscopic Maryland dissector was placed in port 5.

All instruments and the camera were removed, and the ports were undocked. Finally, the PSC was moved away from the patient table and the body wall and skin closed routinely.

### Assessment of differences between RC and LC

The RC procedure was divided into subprocess procedures based on a previous study,<sup>5</sup> for comparison between laparoscopic and robotic interventions (**Table 1**). Difficulty compared to laparoscopy for each step was measured subjectively by the primary author (N Buote) as 1 = easier than laparoscopy, 2 = same as laparoscopy, and 3 = harder than laparoscopy. When a specific step had no laparoscopic approximate, the difficulty of that step was determined based on a Likert score (1 = very easy, 2 = moderately

easy, 3 = medium, 4 = difficult, 5 = very difficult). The time each step required was recorded and reported in median and range. Specific robotic skills learned during the procedure were recorded (**Table 2**).

LC in the 2 canine cadavers was performed as previously described by Mayhew et al.<sup>27</sup>

**Table 2**—Skills applied during robotic cholecystectomy

|   |
|---|
| Robotic-specific skills   |
| Positioning PSC   |
| Placing robotic ports (appropriate depth)   |
| Docking robotic ports to arms   |
| Verifying adequate range of movement of robotic arms (avoiding conflict)          |
| Switching robotic instrumentation during procedure                                |
| Adjusting SC for ergonomic use (height of arm rest, position of foot pedals, etc) |
| Use of master grips   |
| Clutching (switching between instruments)   |
| Use of electrocautery and bipolar sealing   |
| Skills performed differently from LC due to instrumentation differences           |
| Small space dissection with larger instruments                                    |
| Knot tying technique  |

## Results

### Cadavers

Four canine cadavers were acquired for RC. Dogs weighed a median of 36 kg (range, 30 to 42). Breeds included 1 each of Mastiff, Sheepdog, German Shepherd, and mixed breed. One was an intact female, and 3 were intact males. The ages of the dogs were a median of 10 years (range, 9 to 12). Two canine cadavers were acquired for LC. Dogs weighed 28 and 32 kg. Breeds included 1 Labrador

**Table 1**—Important surgical differences between robotic and laparoscopic cholecystectomy

| Step   | Robotic process  | Robotic subprocess definitions                                | Median RC time (min), range | LC times (min)                           | Difficulty difference* |
|--|--|---|-----------------------------|--|------------------------|
| Prep of operative field                          | Surgical Robot setup                                   | <b>PSC positioned at head of table</b>                        | 5 (3–7)                     | NA                                       | 0, 3                   |
|  | Initiation of console, ensuring robot is docked safely | <b>Appropriate docking of the robotic arms to ports</b>       | 5 (3–6)                     | NA                                       | 0, 3                   |
|  |  | <b>Verifying adequate range of motion to all arms</b>         | 14.5 (10–20)                | NA                                       | 0, 4                   |
| Dissection of cystic duct and ligature placement | Grasp gallbladder fundus                               | Grasping of gallbladder fundus and locking of instrument      | 4 (2–5) <sup>+</sup>        | NA                                       | 0, 2                   |
|  | Expose cystic duct                                     | Retraction of liver parenchyma with robotic instrumentation   | 1 (0.5–4 min)               | Retraction with fan retractor/cobra 7, 8 | 1                      |
|  |  | Dissection of cystic duct in Calot's space                    | 6 (3.5–8)                   | 13, 18                                   | 1                      |
|  |  | Ligation of cystic duct with encircling suture                | 10 (5–13)                   | 12, 14                                   | 1                      |
| End procedure                                    |  | <b>Robot undocked and movement of PSC from surgical table</b> | 4.5 (4–6)                   | NA                                       | 0, 2                   |

LC = Laparoscopic cholecystectomy. NA = Not applicable. PSC = Patient side cart. RC = Robotic cholecystectomy.

\*Difficulty difference compared to laparoscopy (0–5; subjective difficulty score: 0 = not performed in laparoscopy, 1 = easier than laparoscopy, 2 = same as laparoscopy, and 3 = harder than laparoscopy); if procedure not performed in laparoscopy (bolded), second number denotes difficulty of procedure by Likert score (1 = very easy, 2 = moderately easy, 3 = medium, 4 = difficult, and 5 = extremely difficult). <sup>+</sup>Procedure required less than 30 seconds to perform.

and 1 mixed breed. One was a spayed female, and 1 was an intact male. The ages of the dogs were 10 and 12 years.

### **Operating room, surgical equipment, port placement, and docking for RC**

The robotic components were set up as previously described without complication. Positioning the PSC to the appropriate location was considered medium on the difficulty scale even though it was located within the surgical room. For all robotic ports to be placed and docked to the robotic arms, a median of 13.5 minutes (range, 10 to 15) and 5 minutes (range, 3 to 6), respectively, was required. Times for total port placement (10 minutes for the first case and 6 minutes for the fourth case) and docking (6 minutes for the first case and 3 minutes for the fourth case) improved over time. Verifying the appropriate range of motion for the robotic arms required the longest time out of all the robotic processes at a median of 14.5 minutes (range, 10 to 20).

### **Surgical procedure**

Two out of 4 cadavers had adhesions from the liver or gallbladder to each other, the stomach, or the mesentery, which were successfully transected with electrocautery or sharp dissection. The times recorded included the dissection of adhesions. One cadaver had a moderate hemoperitoneum upon entrance into the abdomen (time recorded did not include suction of peritoneal fluid for this patient). Blood was evacuated, and the procedure proceeded uneventfully. The first procedure utilized 2 assisting laparoscopic ports placed at the right side 2.5 cm cranial to robotic port for placement of a fan retractor (Medtronic Covidien) and on the left side 4 cm caudal to robotic port for a Maryland dissector. The following 3 procedures utilized 1 assistant laparoscopic port only. Instrument exchange was performed successfully by the assistant or primary surgeon for each part of the procedure. Complication occurred in 1 dog when a gallbladder sustained a minor tear during the final stages of dissection, which was successfully compressed between the jaws of a grasping forceps. This was accomplished by the surgeon at the console by using the robotic Maryland bipolar forceps in port 3 to compress the leak while the ProGrasp forceps holding the gallbladder were released. Then, the ProGrasp forceps grasped the gallbladder at the leak site and resumed elevating the gallbladder. Times for all subprocesses of the RC are reported elsewhere (Supplementary Table S1). The median total surgery time for RC was 119.5 minutes (range, 109 to 131). The added median total time for parts of the procedure unique to robotic surgery was 33 minutes (range, 22 to 44).

Neither of the laparoscopic cases had adhesions or other abdominal disease present on entrance into the abdomen. Both procedures utilized 4 ports, and 1 procedure required subxiphoid placement of a cobra liver retractor. No intraoperative complications occurred, but difficulty retracting the liver in 1 case prolonged surgical times. Times for all subprocesses

of the LC are reported elsewhere (Supplemental Table S1). The total surgery times for LC were 75 and 81 minutes.

### **Assessment of differences between RC and LC**

Aspects of the RC that are unique to robotics include positioning of the PSC, use of the SC for instrument manipulation, robotic arm positioning, and docking and undocking the robot (Tables 1 and 2). Movement of the PSC to the appropriate location at the head of the table was considered medium on the difficulty scale due to unfamiliarity with the mechanics. Docking of the robotic arms to the ports and positioning of the arms were considered difficult as well, and modifying the arm positioning so that they did not conflict and had maximal flexibility was the most difficult step noted during the robotic procedure. Adjustment of the surgeon to the SC for instrument manipulation was considered moderately easy; however, the lack of haptic feedback present with laparoscopy required adaptation to ensure excessive force was not applied to the body wall or tissues.

The ability to park or lock an instrument during the RC was considered extremely helpful for the dissection of the cystic duct and gallbladder. The articulation of the robotic instruments also allowed for them to be used as dissectors and retractors from both port 2 and port 3, which obviated the need for additional assisting ports. The visualization of the cystic duct was enhanced by the 3-D camera as well as the articulating instruments. The articulation and increased degrees of freedom afforded by robotic instrumentation allowed for precise dissection around the cystic duct and suture placement. These advantages meant that certain aspects of the RC were considered easier than LC (Table 1). Forward progress of the RC did require specific attention to be paid to cues from the SC and visual or auditory cues of instrument conflicts, which was considered medium difficulty during these 4 procedures. Undocking the robotic arms from the ports and moving the PSC away from the surgical table was considered moderately easy.

### **Discussion**

RC was feasible in this canine model. The procedure was performed in all cases by a surgeon with experience in laparoscopy and robotic simulation training, which may have affected the difficulty scores reported in this study. The authors hope the data collection tool used in this report could be utilized in future studies with a larger number of surgeons as access to robotic devices increases. All procedures were completed, but 1 gallbladder did sustain a manageable tear during dissection. This was the only major procedural complication that occurred and has been reported in LC procedures as well.<sup>29</sup> Occasional instrument collisions and robotic arm conflicts were also noted, which required time to address. The median time for performance of the RC (119.5 minutes; range, 109 to 131) was consistent

with reported LC (108 to 124 minutes; range, 55 to 210 minutes).<sup>28,29</sup> The primary author also performed 2 laparoscopic cholecystectomies in a canine cadaver model after completion of this study, and times were 75 and 81 minutes. These times are hard to compare to in this case as the surgeon has many years of laparoscopic experience but limited robotic experience. The first clinical report<sup>27</sup> of LC in 2008 described a mean surgical duration for the first 4 dogs being 165 minutes compared to the last 2 dogs' mean surgical duration of 95 minutes. Just as there is equipment setup with laparoscopy, the additional port and docking setup time (33 minutes) with a robotic surgery should also be considered when transitioning these procedures to live animals. Longer procedure times, including setup of laparoscopic instrumentation, are often cited as a disadvantage of LC over open cholecystectomy but as clinicians become more familiar with this equipment and docking procedures, these times will most likely decrease. In human medicine, docking is reportedly less than 5 minutes for most procedures.<sup>34</sup>

Multiple procedural differences between LC and RC were identified, and certain aspects of RC were found to be more challenging than LC. The equipment involved in robotic surgery is novel to the veterinary setting, so adaptation must occur. Familiarity with laparoscopic instrumentation and the surgical procedure of cholecystectomy was helpful but aspects of robotic surgery are dissimilar.<sup>35</sup> Positioning of the PSC, docking the robot arms to the ports, and arm positioning were found to be the most challenging steps of the RC, as these are the steps that require unique 3-D assessment and practice with the instrumentation. Movement of the PSC by motorized controls to the appropriate location at the head of the table was considered medium on the difficulty scale, as it is a 500-kg machine and minor location adjustments are challenging. Docking of the robotic arms to the ports was also considered medium difficulty. This task required the robotic arms to be attached appropriately to the ports as well as the ports to be placed at the appropriate depth within the patient. This step is crucial in avoiding excessive force and movement at the skin or body wall-port interface. Appropriate port placement is critical in decreasing robotic arm conflict during procedures. Modifying the arm positioning to prevent conflict was the most difficult step noted because these precise adjustments required consideration of all movements necessary for the arms throughout the procedure. The authors recommend moving each arm through the range of motion proposed for the instrument that will be inserted at each site before beginning the procedure to gain insight into potential conflicts. Instrument or arm collisions did occur occasionally and were most often noted audibly as there is no haptic feedback with robotic surgery. These collisions can halt the forward progress of the procedure and as familiarity increases these should be less frequent. The use of 5 ports in this series is also different than many laparoscopic procedures, which only use 4. One port was used to retract the gallbladder throughout the procedure,

and 1 was used for the camera/telescope, leaving 2 robotic ports for instrument manipulation. The fifth port was a laparoscopic assist port used for various actions (bringing suture into the abdomen, retraction, etc). This addition of this fifth port is most likely due to the experience level of the surgeon and not due to the shortcomings of the equipment. As veterinary surgeons become more accustomed to robotic surgery, the number of ports needed will most likely decrease as has been seen with laparoscopy. Single port access does exist in the robotic sphere and is another consideration in future research. Another important difference between robotic surgery and laparoscopic is the need for a patient-side assistant for instrument exchange. While laparoscopic procedures also require assistance in the majority of cases, a robotic assistant is at the patient table while the primary surgeon scrubs out to work at the SC. This level of separation from the patient is quite novel to veterinary surgery and will require adaptation.

Certain aspects of the RC were found to be easier than LC. Only 2 instruments can be controlled at the same time; therefore, when a third instrument is within the patient, it is "locked" or frozen in place until the surgeon at the console activates it by utilizing the clutch or "arm-switch" function. The capability to lock an instrument during the RC meant that certain steps, such as dissection of the cystic duct and gallbladder, were considered easier than in traditional LC because the elevated gallbladder was stable. By locking the gallbladder in place, surgeon and assistant fatigue was decreased and the structure can be held stable indefinitely. Improved ergonomics for surgeons and assistants is 1 of the most cited benefits of robotic surgery.<sup>19,20</sup> Improved ergonomics for surgeons leads to decreased work-related musculoskeletal disorders and improved patient outcomes in human medicine and should be considered in veterinary surgery as well. One study<sup>36</sup> that surveyed veterinary surgeons performing laparoscopy routinely found that 40% experienced pain that they attributed to the use of laparoscopic instruments during or after minimally invasive surgery procedures. Importantly, 54% of surgeons experienced the pain at home, 64% had taken painkillers for the pain, and 46% had required other treatment such as physical therapy, chiropractic treatment, or seeing a doctor.<sup>36</sup> The articulation and increased degrees of freedom of robotic instruments also allow for simultaneous use as dissectors and retractors. The improvement of robotic articulated instruments over most articulated laparoscopic instruments is profound. Most articulated laparoscopic instruments are hinged at a larger distance from the tip of the instrument. This decreases the surgeon's ability to place instruments in tight regions and limits the usefulness of these instruments. The EndoWrist technology delivered by robotic instruments allows for an improved range of motion and precise dissection. The flexibility of the instruments and the 3-D view through the SC decreased the difficulty score for many steps during the cholecystectomy. While 3-D cameras are available for laparoscopic towers, they

are not standard yet; the robotic system SC allows for 3-D stereoscopic vision, which is valuable in tight spaces. These advantages may decrease the need for additional ports, therefore eliminating the time needed to place additional ports and the morbidity of those ports. These instruments may also reduce instrument exchanges and overall surgery time. The use of the SC for instrument manipulation during the procedure was found to be easier for the surgeon than the manipulation of straight instruments during LC. This result could be due to many factors. The surgeon performing this procedure had experience with LC and a robotic training simulator in preparation for this project. As of submission, there were no veterinary universities with surgical robots in the United States. This has been remedied recently, and the authors expect widening experience with robotics will improve research on this topic. While the laparoscopic experience was helpful in terms of the steps of a cholecystectomy, multiple reports<sup>37-39</sup> illustrate previous laparoscopic training does not necessarily improve performance on robotic instrumentation. The movements used to manipulate the robotic instrumentation, while novel, are similar to open surgery and more comfortable than straight laparoscopic instrumentation during certain procedural steps. This research provides a potential area for translatable advances in both veterinary and human surgical diseases.

Limitations to this study center on its experimental nature. Challenges present in live animal surgery, such as hemorrhage, peristalsis, inflammation of the gallbladder, and anesthetic concerns, do not exist in a cadaveric model. The cadaveric investigation is a necessary first step when attempting the use of new instrumentation to ensure the safety of live patients. Translation to clinical cases must be done with caution, as not all clinical cases will be a good candidate for robotic surgery and surgeons must be able to convert to laparoscopic or open procedures if deemed in the patient's best interest. Only 4 cadavers were used, and different complications or difficulty scores may have occurred had a larger cohort of animals been used, but the expense of the instrumentation for robotic surgery determined how many procedures could be done. We report a perforation rate of 1 of 4 of our cadavers (25%), but this is most likely due to the experience level of the surgeon with robotic instrumentation and not a true representation of the procedural risks. Robotic instrumentation expiration is determined by a proprietary computer program that tracks the number of times it is used; therefore, the typical reuse strategies of veterinary medicine cannot be applied. The effect of expense on the utilization of robotic surgery in veterinary medicine will be an important factor to investigate in future studies. The objective of this study was not to determine if RC was better than laparoscopic but to compare the steps and identify differences. Only 1 surgeon evaluated the difficulty of RC compared to LC; therefore, the difficulty scores are based on the laparoscopic and robotic experience of this surgeon. This type of evaluation has been published

previously,<sup>5</sup> but evaluation by more surgeons will be pursued when robotic equipment is more readily available. In the future, objective data could be collected such as the number of times instruments are exchanged and the time spent on dissection for multiple cases. The primary author did perform 2 laparoscopic procedures to compare procedural times, but again these comparisons are difficult due to the author's variable experience with the 2 platforms. Future studies are underway comparing novice surgeons on both platforms. The main benefit of robotic surgery lies in the improved ability to suture due to the articulating instruments and SC grip design. LC does not require intensive suturing, so the important benefits of the robotic equipment were not as emphasized as they could be for certain procedures, but many other aspects unique to robotic surgery were experienced.

In conclusion, RC is feasible in a canine model. Experience with laparoscopy was helpful with port placement and familiarity with certain robotic instruments, but multiple differences between the procedures were identified. RC appeared to be an appropriate procedure for a veterinary surgeon to learn the different characteristics of robotic technology. Future studies in live patients should be performed to determine whether there are clinical advantages to RC over LC.

## Acknowledgments

None reported.

## Disclosures

Authors Antoine Chalon, Jérôme Maire, and Nguyen Tran are affiliated with Velvet Innovative Technologies, a private surgical training company, which received a fee to facilitate implementation of this project.

No artificial intelligence-assisted technologies were used in the generation of this manuscript.

## Funding

This project was funded in part by the Cornell University Affinito-Stewart Grant.

## References

1. Young RF. Application of robotics to stereotactic neurosurgery. *Neurol Res*. 1987;9:123-128. doi:10.1080/01616412.1987.11739782
2. Davies BL, Hibberd RD, Coptcoat MJ, Wickham JE. A surgeon robot prostatectomy—a laboratory evaluation. *J Med Eng Technol*. 1989;13:273-277. doi:10.3109/03091908909016201
3. Lane T. A short history of robotic surgery. *Ann R Coll Surg Engl*. 2018;100:5-7. doi:10.1308/rcsann.suppl.5
4. Schlake A, Dell'Oglio P, Devriendt N, et al. First robot-assisted radical prostatectomy in a client-owned Bernese mountain dog with prostatic adenocarcinoma. *Vet Surg*. 2020;49:1458-1466. doi:10.1111/vsu.13448
5. Jamet A, Hubert N, Maire J, Tran N, Hubert J, Mazeaud C. Robot-assisted radical prostatectomy training: description of a canine cadaveric model. *Int J Med Robot*. 2022;18:e2381. doi:10.1002/rcs.2381

6. Thiel DD, Winfield HN. Robotics in urology: past, present, and future. *J Endourol.* 2008;22:825–830. doi:10.1089/end.2007.9830
7. McGuinness LA, Prasad Rai B. Robotics in urology. *Ann R Coll Surg Engl.* 2018;100:38–44. doi:10.1308/rcsann.suppl1.38
8. Truong M, Kim JH, Scheib S, Patzkowsky K. Advantages of robotics in benign gynecologic surgery. *Curr Opin Obstet Gynecol.* 2016;28:304–310. doi:10.1097/GCO.0000000000000293
9. Wang T, Zhang D, Da L. Remote-controlled vascular interventional surgery robot. *Int J Med Robot.* 2010;6:194–201. doi:10.1002/rcs.306
10. Liu HH, Li LJ, Shi B, Xu CW, Luo E. Robotic surgical systems in maxillofacial surgery: a review. *Int J Oral Sci.* 2017;9:63–73. doi:10.1038/ijos.2017.24
11. Navarrete-Arellano M. Robotic-assisted minimally invasive surgery in children. In: Küçük S (ed). *Latest Developments in Medical Robotics Systems.* IntechOpen; 2021:1–31. doi:10.5772/intechopen.96684
12. Navarrete Arellano M, González FG. Robot-assisted laparoscopic and thoracoscopic surgery: prospective series of 186 pediatric surgeries. *Front Pediatr.* 2019;7:200. doi:10.3389/fped.2019.00200
13. Denning NL, Kallis MP, Prince JM. Pediatric robotic surgery. *Surg Clin North Am.* 2020;100:431–443. doi:10.1016/j.suc.2019.12.004
14. Andolfi C, Kumar R, Boysen WR, Gundeti MS. Current status of robotic surgery in pediatric urology. *J Laparoendosc Adv Surg Tech A.* 2019;29:159–166. doi:10.1089/lap.2018.0745
15. Ghezzi TL, Corleta OC. 30 years of robotic surgery. *World J Surg.* 2016;40:2550–2557. doi:10.1007/s00268-016-3543-9
16. Catanzarite T, Tan-Kim J, Whitcomb EL, Meneffee S. Ergonomics in surgery: a review. *Female Pelvic Med Reconstr Surg.* 2018;24:1–12. doi:10.1097/SPV.0000000000000456
17. Wong SW, Ang ZH, Yang PF, Crowe P. Robotic colorectal surgery and ergonomics. *J Robot Surg.* 2022;16:241–246. doi:10.1007/s11701-021-01240-5
18. Monfared S, Athanasiadis DI, Umana L, et al. A comparison of laparoscopic and robotic ergonomic risk. *Surg Endosc.* 2022;36:8397–8402. doi:10.1007/s00464-022-09105-0
19. Shugaba A, Lambert JE, Bampouras TM, Nuttall HE, Gaffney CJ, Subar DA. Should all minimal access surgery be robot-assisted? A systematic review into the musculoskeletal and cognitive demands of laparoscopic and robot-assisted laparoscopic surgery. *J Gastrointest Surg.* 2022;26:1520–1530. doi:10.1007/s11605-022-05319-8
20. Gabrielson AT, Clifton MM, Pavlovich CP, et al. Surgical ergonomics for urologists: a practical guide. *Nat Rev Urol.* 2021;18:160–169. doi:10.1038/s41585-020-00414-4
21. Dalager T, Sogaard K, Bech KT, Mogensen O, Jensen PT. Musculoskeletal pain among surgeons performing minimally invasive surgery: a systematic review. *Surg Endosc.* 2017;31:516–526. doi:10.1007/s00464-016-5020-9
22. AlSabah S, Haddad EA, Khwaja H. The prevalence of musculoskeletal injuries in bariatric surgeons. *Surg Endosc.* 2019;33:1818–1827. doi:10.1007/s00464-018-6460-1
23. Flynn J, Larach JT, Kong JCH, Waters PS, Warriar SK, Heriot A. The learning curve in robotic colorectal surgery compared with laparoscopic colorectal surgery: a systematic review. *Colorectal Dis.* 2021;23:2806–2820. doi:10.1111/codi.15843
24. Vining CC, Skowron KB, Hogg ME. Robotic gastrointestinal surgery: learning curve, educational programs and outcomes. *Updates Surg.* 2021;73:799–814. doi:10.1007/s13304-021-00973-0
25. Power AD, D'Souza DM, Moffatt-Bruce SD, Merritt RE, Kneuert PJ. Defining the learning curve of robotic thoracic surgery: what does it take? *Surg Endosc.* 2019;33:3880–3888. doi:10.1007/s00464-019-07035-y
26. Buote N, Fransson B, Rishniw M, Buote NJ, Fransson B, Rishniw M. Comparison of attempts needed for veterinary students to reach proficiency in a basic and advanced robotic simulator task. *J Vet Med Educ.* 2023;e20220130. doi:10.3138/jvme-2022-0130.
27. Mayhew PD, Mehler SJ, Radhakrishnan A. Laparoscopic cholecystectomy for management of uncomplicated gall bladder mucocele in six dogs. *Vet Surg.* 2008;37:625–630. doi:10.1111/j.1532-950X.2008.00428.x
28. Kanai H, Hagiwara K, Nukaya A, Kondo M, Aso T. Short-term outcome of laparoscopic cholecystectomy for benign gall bladder diseases in 76 dogs. *J Vet Med Sci.* 2018;80:1747–1753. doi:10.1292/jvms.18-0266
29. Scott J, Singh A, Mayhew PD, et al. Perioperative complications and outcome of laparoscopic cholecystectomy in 20 dogs. *Vet Surg.* 2016;45:O49–O59. doi:10.1111/vsu.12534
30. Cadière GB, Himpens J, Gernay O, et al. Feasibility of robotic laparoscopic surgery: 146 cases. *World J Surg.* 2001;25:1467–1477. doi:10.1007/s00268-001-0132-2
31. Vidovszky TJ, Smith W, Ghosh J, Ali MR. Robotic cholecystectomy: learning curve, advantages, and limitations. *J Surg Res.* 2006;136:172–178. doi:10.1016/j.jss.2006.03.021
32. Austin B, Lanz OI, Hamilton SM, Broadstone RV, Martin RA. Laparoscopic ovariectomy in nine dogs. *J Am Anim Hosp Assoc.* 2003;39:391–396. doi:10.5326/0390391
33. Devitt CM, Cox RE, Hailey JJ. Duration, complications, stress, and pain of open ovariectomy versus a simple method of laparoscopic-assisted ovariectomy in dogs. *J Am Vet Med Assoc.* 2005;227:921–927. doi:10.2460/javma.2005.227.921
34. Kubat E, Eisenberg D, Wren SM. Multiport and single-site robotic cholecystectomy. In: Fong Y, Woo Y, Hyung WJ, Lau C, Strong VE (eds). *The SAGES Atlas of Robotic Surgery.* Springer International Publishing; 2018:233–248.
35. Huang Y, Chua TC, Maddern GJ, Samra JS. Robotic cholecystectomy versus conventional laparoscopic cholecystectomy: a meta-analysis. *Surgery.* 2017;161:628–636. doi:10.1016/j.surg.2016.08.061
36. Jones ARE. A survey of work-related musculoskeletal disorders associated with performing laparoscopic veterinary surgery. *Vet Surg.* 2020;49:O15–O20. doi:10.1111/vsu.13400
37. Panait L, Shetty S, Shewokis PA, Sanchez JA. Do laparoscopic skills transfer to robotic surgery? *J Surg Res.* 2014;187:53–58. doi:10.1016/j.jss.2013.10.014
38. Sundelin MO, Paltved C, Kingo PS, Kjölhede H, Jensen Jb. The transferability of laparoscopic and open surgical skills to robotic surgery. *Adv Simul (Lond).* 2022;7:26. doi:10.1186/s41077-022-00223-2
39. Zihni A, Ge T, Ray S, et al. Transfer and priming of surgical skills across minimally invasive surgical platforms. *J Surg Res.* 2016;206:48–52. doi:10.1016/j.jss.2016.06.026

## Supplementary Materials

Supplementary materials are posted online at the journal website: [avmajournals.avma.org](http://avmajournals.avma.org).