

# Postmortem evaluation of surgery site leakage by use of in situ isolated pulsatile perfusion after partial liver lobectomy in dogs

Marije Risselada, DVM, PhD; Maximilian M. R. Polyak, MPhil; Gary W. Ellison, DVM, MS; Nicholas J. Bacon, VetMB, MA; James M. Van Gilder, BS; Alastair R. Coomer, BVSc, MS; Kelley E. Thieman, DVM

**Objective**—To evaluate postmortem surgery site leakage by use of in situ isolated pulsatile perfusion after partial liver lobectomies.

**Animals**—10 healthy mixed-breed male dogs.

**Procedures**—Dogs were anesthetized, and 5 surgical techniques (pretied suture loop, energy-based sealer-divider, harmonic scalpel, suction with clip application, or suction with use of a thoracoabdominal stapler) were used to perform 5 partial liver lobectomies in each dog. Dogs were euthanized, and the portal vein and hepatic artery were cannulated and perfused with a modified kidney perfusion machine (pulsatile flow for arterial perfusion and nonpulsatile flow for portal perfusion). Lobectomy sites were inspected for leakage of perfusate, and time until detection of leakage was recorded. The techniques in each dog were ranked on the basis of time until leakage. Time until leakage and rankings for each surgical technique were analyzed by use of an ANOVA.

**Results**—Leakage of perfusate was recorded in 44 lobes at supraphysiologic pressures. Of the 6 lobes without leakage, a pretied suture loop procedure was performed in 5 and a harmonic scalpel procedure was performed in 1. Time until leakage and the ranking differed significantly between the pretied suture loop and the other techniques. Time until leakage and ranking did not differ significantly among the other techniques.

**Conclusions and Clinical Relevance**—Time until leakage of perfusate was greater for the pretied suture loop technique than for the other techniques, and that technique did not fail in 5 of 10 lobes. However, all techniques appeared to be safe for clinical use. (*Am J Vet Res* 2010;71:262–267)

Liver lobectomy is a commonly performed surgery in dogs and humans, and partial lobectomies are performed more commonly than are complete lobectomies.<sup>1,2</sup> Several surgical techniques have been used and advocated. However, the authors are not aware of any studies conducted to evaluate and compare liver lobectomy techniques by monitoring the sites after surgery for potential hemorrhage in dogs or humans. In several clinical studies<sup>3–5</sup> in humans, investigators have reported postoperative biliary leakage and hemorrhage from venules.

Autostapling devices, such as thoracoabdominal staplers<sup>6</sup> or, more recently, endolinear staplers,<sup>7</sup> have commonly been used for performing partial liver lo-

ABBREVIATION	
ACT	Activated clotting time

bectomies. The first description<sup>6</sup> of the use of thoracoabdominal staplers in veterinary medicine was for partial liver lobectomy in dogs. Subsequently, use of thoracoabdominal staplers was compared with use of blunt dissection and ligation for lobectomy in dogs.<sup>8</sup> An alternative to application of a thoracoabdominal stapler across the entire width of a liver lobe is to use parenchymal dissection with the inner tube of the Poole suction tip (skeletonization), followed by application of a clip to each vessel or use of a thoracoabdominal stapler across the remaining vessels.<sup>9</sup>

Other techniques used for liver surgery include procedures involving vessel-sealing devices based on a high-current, low-voltage radiofrequency energy<sup>10,11</sup>; a device based on ultrasonic principles<sup>12</sup>; and pretied endoscopic loops.<sup>13</sup> Energy-based vessel-sealing devices have been compared to evaluate complete closure and sealing time<sup>14</sup> as well as for bursting pressure,<sup>15,16</sup> but each of these studies was conducted on isolated vessels.

In addition to an early study<sup>6</sup> of the use of thoracoabdominal staplers, several reports<sup>17–19</sup> have been published regarding liver lobectomies for use in treatment of several diseases in dogs, but no stud-

Received January 21, 2009.

Accepted April 6, 2009.

From the Department of Small Animal Clinical Sciences, College of Veterinary Medicine, University of Florida, Gainesville, FL 32610-0126 (Risselada, Polyak, Ellison, Bacon, Van Gilder, Coomer, Thieman); and the Transplant Center, Department of Surgery, College of Medicine, Shands at the University of Florida, Gainesville, FL 32608 (Polyak).

Supported by Covidien.

Presented in abstract form at the American College of Veterinary Surgeons Symposium, San Diego, October 2008.

The authors thank Drs. S. E. Kim and K. A. Kirkby for technical assistance.

Address correspondence to Dr. Risselada (RisseladaM@vetmed.ufl.edu).

ies have been conducted to compare results between staplers and energy-based devices. The objective of the study reported here was to perform a postmortem evaluation of 5 surgical techniques for partial liver lobectomy in dogs with regard to leakage after surgery. We also assessed a novel postmortem method that involved isolated pulsatile perfusion for testing hemostasis of liver lobectomies on the basis of studies that have revealed the efficacy of thoracoabdominal stapling devices for use in performing partial hepatectomy. Our hypothesis was that partial liver lobectomies performed by use of a thoracoabdominal stapling device with vascular staples would provide the most secure postsurgical closure.

## Materials and Methods

**Animals**—Ten healthy young mixed-breed male dogs were enrolled in the study. The dogs had been used for teaching of veterinary students in an abdominal surgery laboratory and were enrolled at the completion of that laboratory. Approval for the study was granted by the University of Florida Institutional Animal Care and Use Committee.

**Abdominal surgery laboratory**—Prior to the abdominal surgery laboratory, body weight of each dog was recorded (range, 16.4 to 26.2 kg; mean  $\pm$  SD, 22.9  $\pm$  3.59 kg; median, 24.3 kg). Dogs were premedicated by administration of acepromazine<sup>a</sup> (0.05 mg/kg, IM), and anesthesia was induced by administration of propofol<sup>b</sup> (4 to 6 mg/kg, IV, to effect) and maintained by administration of isoflurane<sup>c</sup> in oxygen. During the abdominal surgery laboratory, all dogs received fluids (lactated Ringer's solution,<sup>d</sup> 10 mL/kg/h, IV) administered via an indwelling catheter inserted in a cephalic vein. Procedures performed on the dogs during the abdominal surgery laboratory were gastrotomy, gastropexy, enterotomy, enterectomy, splenectomy, and liver biopsy by use of the guillotine method. Duration of anesthesia for the surgery laboratory ranged from 642 to 748 minutes (mean  $\pm$  SD, 697.3  $\pm$  33.1 minutes).

**Preparations prior to partial liver lobectomies**—At the conclusion of the surgical laboratory, the anesthetized dogs were enrolled in our partial lobectomy study. Anesthesia was maintained during the study by continued administration of isoflurane in oxygen, and all dogs continued to receive fluids (lactated Ringer's solution, 10 mL/kg/h, IV) throughout the partial lobectomy procedures. Before onset of our study, ACT and rectal temperature were measured in each dog. Heart rate and mean blood pressures (measured noninvasively) were recorded every 15 minutes throughout the study. Anesthetic depth was estimated on the basis of jaw tone, heart rate, respiratory rate, blood pressure, palpebral reflex, and position of the eyes, and vaporizer settings were adjusted accordingly to maintain a surgical plane of anesthesia.

**Partial liver lobectomies**—Five partial liver lobectomies were performed in each dog. Two surgeons certified by the European College of Veterinary Surgeons (MR and NJB) performed all partial lobectomies (5 dogs/surgeon). The distribution and order of the surgeries were assigned in accordance with a 5  $\times$  5 Latin

square design to ensure that each technique was performed twice on the right medial, right lateral, quadrate, left lateral, and left medial liver lobes (total of 10 lobes/technique). Landmarks for the partial lobectomies were determined prior to the study to standardize the techniques between the 2 surgeons. The same technique was used first on every dog; however, the specific order of techniques differed per surgeon (MR vs NJB) and day (Tuesday vs Thursday).

Each surgeon was aided by an assistant; the assistants (ARC, SEK, KAK, and KET) were veterinarians enrolled in a surgical residency program. One additional team member (MMRP) monitored anesthesia during the study. The surgeon performed the 5 partial lobectomies in a dog. The techniques used were a tied suture loop with size 0 glycolide-lactide copolymer suture<sup>e</sup>; a 10-mm-diameter, 20-cm sealer-divider<sup>f</sup>; a 5-mm-wide, ultrasonically activated scalpel (harmonic scalpel)<sup>g</sup>; skeletonization with a Poole suction tip<sup>h</sup> and application of a surgical clip to each vessel (suction + clip); and skeletonization and use of a thoracoabdominal stapler<sup>i</sup> (suction + thoracoabdominal stapler). Then, the assistant remained with that dog to monitor the surgical sites for hemorrhage, while the surgeon moved to the next dog to perform the next set of lobectomies with another assistant. After completion of the partial lobectomies, the widths, heights, and weights of the resected lobes were recorded.

All lobectomy sites were examined until hemorrhage had ceased, as determined by a single observer (GWE) who was not aware of the technique used for each partial lobectomy. After all procedures were performed on all 10 dogs, the anesthetized dogs were then euthanized by administration of a solution of sodium pentobarbital with phenytoin<sup>j</sup> (1 mL/4.5 kg). Euthanasia was performed in accordance with established guidelines.<sup>20</sup>

**Pressure leakage testing**—Following euthanasia of the dogs, the portal vein and hepatic artery of each dog were cannulated with a 20-gauge, over-the-needle IV catheter.<sup>k</sup> Both the arterial and portal system were immediately perfused with saline (0.9% NaCl) solution<sup>d</sup> for 10 minutes prior to pressure testing to prevent blood clots from occluding the intrahepatic vessels; perfusion was achieved by use of a modified kidney perfusion machine.<sup>l</sup> Leakage was then tested by administration of a 0.08% solution of aniline blue dye<sup>m</sup> via pulsatile flow (80 pulses/min; 300 mL/min) through the hepatic artery catheter and administration of a 0.003% solution of black ink (2 ink cartridges<sup>n</sup>/500 mL of saline solution) as a continuous flow (100 mL/min) through the portal vein catheter (Figure 1). The team member who had monitored anesthesia during surgery was responsible for ensuring the perfusion of the cannulated livers was performed correctly.

The lobectomy sites were inspected for leakage of perfusate by 1 surgeon board-certified by the American College of Veterinary Surgeons (GWE) who had not performed any of the partial lobectomies and was not aware of the technique used for each lobe. The portal and systemic pressures were increased by 20 mm Hg every 30 seconds until leakage was first detected. The pressures were maintained constant in a dog after leak-

age of the first lobe was detected until leakage was detected at all 5 surgical sites (ie, lobes) or 60 seconds had elapsed after leakage was detected for the fourth lobe but there was no leakage evident for the fifth lobe. The time until leakage for each lobe was recorded. If leakage was not detected from a specific surgery site, the time until leakage from the fifth surgery site was recorded as the time of leakage from the preceding surgery site that leaked plus 60 seconds. In addition, the techniques for partial lobectomy were ranked in each dog on a scale of 1 to 5, with 1 indicating the first lobe to leak and 5 indicating the last lobe to leak. If 2 lobes appeared to start leaking at the same time, they were assigned the same ranking score, which was the lowest ranking score still available at that time.

**Statistical analysis**—Data were reported as mean  $\pm$  SD. The data were examined for normality by use of the Kolmogorov-Smirnov test. An ANOVA was performed on normally distributed data, and a multiple comparison procedures test (Student-Newman-Keuls method) was then performed to detect significant differences. An ANOVA on ranks (Kruskal-Wallis ANOVA) was performed on nonnormally distributed data. The Dunn test for multiple comparisons was performed after significant differences were detected by use of the aforementioned tests. Significance was defined as values of

$P < 0.05$ . All statistical analyses were performed by use of computer software.<sup>9</sup>

## Results

**Animals**—All 10 dogs were healthy, and no abnormalities were detected during clinical examination prior to induction of anesthesia. The ACT values for the 10 dogs (range, 60 to 123 seconds; mean  $\pm$  SD, 93.4  $\pm$  22.38 seconds; median, 91.5 seconds) were determined at the onset of the study. Eight of 10 dogs had ACT values within the reference range of  $< 120$  seconds; the remaining 2 dogs had values slightly outside the reference range (121 and 123 seconds, respectively). Rectal temperature measured at the onset of the study ranged from 33.9° to 36.2°C (mean, 35.38  $\pm$  0.86°C; median, 35.6°C). During surgery, mean blood pressure ranged from 45 to 75 mm Hg (mean  $\pm$  SD, 63.2  $\pm$  9.3 mm Hg; median, 66 mm Hg). Seven dogs had a mean blood pressure of  $> 60$  mm Hg; mean blood pressure in the remaining 3 dogs was 45, 55, and 55 mm Hg, respectively. Heart rate during surgery ranged from 58 to 115 beats/min (mean, 97.5  $\pm$  16.66 beats/min; median, 99 beats/min). No significant differences were detected among the dogs for any of the variables.

**Surgical procedures**—All surgical procedures were successfully completed on each lobe. No lobes or dogs were excluded from the study. Substantial hemorrhage was detected in 3 dogs. Two dogs had hemorrhage from a vein (pretied suture loop and harmonic scalpel techniques, respectively), and 1 dog had arterial hemorrhage (suction + clip technique). Additional sutures or clips were placed by the primary surgeon performing the partial lobectomy (MR or NJB) to control hemorrhage. Additional clips or sutures were also placed in 3 other dogs during the procedure (suction + thoracoabdominal stapler in 1 dog and harmonic scalpel in 2 dogs) because of arterial bleeding. No hemorrhage was detected at the surgery sites at the time of euthanasia.

**Pressure leakage testing**—Flow was established in all dogs. Leakage from the cannulation sites was not observed during perfusion. Mean  $\pm$  SD pressure at which leakage was detected was 112  $\pm$  32.51 mm Hg for the portal vein and 247  $\pm$  61.83 mm Hg for the hepatic artery. Discoloration of the lobes as a result of perfusion (the lobes appeared black [portal] rather than blue [arterial]) was evident before leakage was detected (Figure 2).

Leakage of perfusate was detected at 44 of 50 lobectomy sites. Of the 6 lobectomies without leakage, a pretied suture loop technique was performed on 5 (3 by 1 surgeon and 2 by the other surgeon) and a harmonic scalpel technique was performed on 1. Time until leakage ranged from 61 to 910 seconds for each of the 5 lobes (Table 1). Of the 6 lobes in which additional sutures or clips were placed to maintain or ensure hemostasis during surgery, only 1 was the first to leak in that dog (harmonic scalpel technique). The remaining 5 were the second lobe to leak (2 lobes for the harmonic scalpel technique) or the fifth lobe to leak (1 lobe each for the suction + clip, suction + thoracoabdominal stapler, and pretied suture loop techniques).

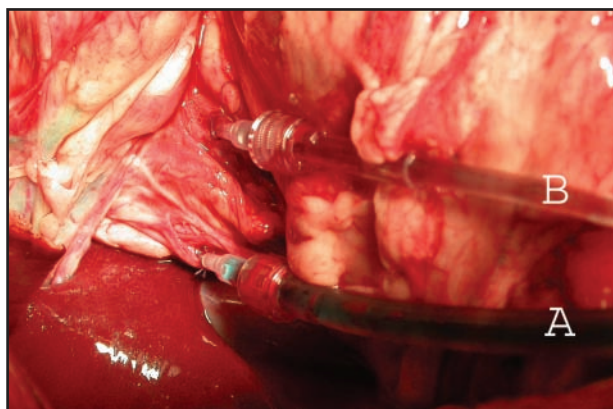


Figure 1—Photograph of the IV cannulae after postmortem insertion in the hepatic artery (A) and portal vein (B) in a representative dog. Notice the blue and black dyes used to perfuse the hepatic artery and portal vein, respectively.

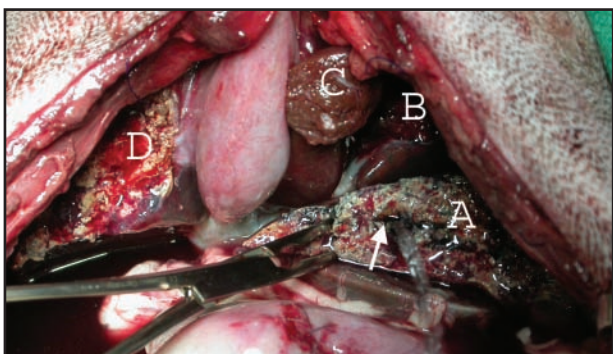


Figure 2—Photograph during pressure leakage testing in a representative dog depicting a central vein leak (white arrow) in the left lateral lobe (A). In the same lobe, notice the discoloration of the resected liver parenchyma, whereas the left medial (B), quadrate (C), and right medial (D) lobes remain unchanged. The right lateral lobe is not visible in this photograph.



When ranking scores were used, the pretied suture loop technique consistently had the highest ranking (Table 2). For 9 dogs, the ranking for that technique was 5. In the remaining dog, the ranking for that technique was 4 because neither the pretied suture loop nor the harmonic scalpel technique leaked; thus, both of those techniques were assigned the same ranking score.

No significant differences were detected among the dogs for width, height, and weight of the resected lobes. There was a significant ( $P = 0.005$ ) difference in time until leakage between the pretied suture loop technique and the 4 other techniques. However, the other 4 techniques did not differ significantly ( $\alpha = 0.05$ ; power = 0.80) for time until leakage. There was a significant ( $P < 0.001$ ) difference in ranking scores between the pretied suture loop technique and the 4 other techniques. No significant differences were detected in ranking scores among the other 4 techniques.

No significant differences were detected among the 10 dogs for median peak portal pressure or median hepatic artery pressure. No association was detected between the values of the mean arterial blood pressure

during surgery and both leakage pressures during perfusion after euthanasia.

## Discussion

Our hypothesis for the study reported here was that use of the thoracoabdominal stapling device would provide the most secure closure and, compared with results for the other 4 techniques, would leak at higher perfusate pressures and have a greater time until leakage. However, during leakage testing by use of this *ex vivo* in situ method, the pretied suture loop technique outperformed the 4 other techniques and did not leak for 5 of 10 lobectomies in which it was used.

For the partial lobectomies performed with a thoracoabdominal stapler, vascular staples with 3 rows of 2.5-mm staples that close to 1 mm were chosen over the more frequently used 3.5-mm staples that close to 1.5 mm in an attempt to obtain the best vascular closure possible. At our veterinary medical teaching hospital, the larger thoracoabdominal staplers are used more frequently because the stapler with the smaller staples does not easily incorporate the entire lobe. However, because the parenchyma was removed from the resection site, the stapler with the smaller staples did fit over the liver lobe.

The pretied suture loop technique is comparable to a circumferential suture technique, except the pretied suture loop technique involves a commercially available pretied loop. The pretied suture loop technique was included in this study because of its potential ease of application. After resection of the lobe, a cuff of tissue (2 to 3 mm) remains distal to the loop, which probably helps prevent leakage.<sup>21</sup> In a recent study<sup>22</sup> of 29 lung biopsies in horses, the authors described ligature slippage in 8 and hemorrhage from a vessel in 1. They also mentioned doubling over of the tissue but described that as a cause for ligature slippage. They also advocated transecting the tissue 1 cm distal to the ligature. We did not observe any slippage of the pretied suture loops but did observe doubling over of tissue in 1 lobe during closure of the pretied suture loop. This lobe was 1 of the 5 lobes in which the pretied suture loop technique was performed that leaked during pressure testing, although it had a ranking score of 5 in that dog. Also, the cuff of tissue that remained distal to the pretied suture loop was < 1 cm for all lobectomies in our study. However, these differences in findings may also be attributable to differences in parenchymal properties between lung and liver tissues.<sup>21</sup>

Use of an extracorporeal perfusion machine enabled us to test the lobectomy sites *in situ*. Moreover, by cannulating both the portal vein and hepatic artery and perfusing both, separate pressure readings could be obtained for each, which mimics the *in vivo* situations of different pressure systems.

Leakage of the surgical sites was detected at pressures exceeding physiologically normal portal and hepatic artery pressures. Flow rates may have appeared to be high, especially the arterial flow, but were necessary to obtain the desired pressures. The obtained pressures would be considered the peak systolic pressure and portal pressure. The leakage pressure was > 10 times the physiologically normal portal pressure (6 to 10 mm Hg)<sup>9</sup>

Table 1—Results of time until leakage\* during postmortem evaluation of surgery site leakage by use of *in situ* isolated pulsatile perfusion after partial liver lobectomy in 10 dogs (n = 10 lobes/technique).

Technique	Median	25th to 75th percentile	Mean ± SD
Suction + thoracoabdominal stapler	207	180.0–410.0	246.4 ± 130.9
Suction + clip	187	183.0–546.0	309.7 ± 318.1
Pretied suture loop	601.5	376.5–601.3	602.0 ± 141.9†
Sealer-divider	301.5	242.0–440.0	372.1 ± 223.6
Harmonic scalpel	407.5	195.3–426.3	386.6 ± 171.4

Values reported are number of seconds.

\*Leakage was detected at 44 of 50 surgery sites (6 lobectomies [5 pretied suture loop and 1 harmonic scalpel] did not leak). Infusion pressures of the perfusate were maintained constant after leakage of the first lobe was detected in each dog. The time until leakage for each lobe was recorded. When leakage from the last lobe was not detected, the time until leakage for the fifth surgery site was recorded as the time until leakage from the fourth surgery site plus 60 seconds. When leakage from the fourth lobe was not detected, the time until leakage for the fourth and fifth surgery sites was recorded as the time of leakage from the third surgery site plus 60 seconds. †Value differs significantly ( $P = 0.005$ ) from the mean value for the other 4 techniques.

Table 2—Results of the ranking scores\* for leakage of perfusate during postmortem evaluation of surgery site leakage by use of *in situ* isolated pulsatile perfusion after partial liver lobectomy in 10 dogs (n = 10 lobes/technique).

Technique	Median	25th to 75th percentile	Mean ± SD
Suction + thoracoabdominal stapler	2	1–3	2.0 ± 1.05
Suction + clip	2	1–4	2.3 ± 1.34
Pretied suture loop	5	5–5	4.9 ± 0.32†
Sealer-divider	3	2–3	2.9 ± 0.34
Harmonic scalpel	3	2–4	2.8 ± 1.22

\*Ranking was scored from 1 (first to leak) to 5 (last to leak). The lobectomy for the harmonic scalpel and the pretied suture loop did not leak in 1 dog, and both techniques were assigned a ranking score of 4 for that dog. †Value differs significantly ( $P < 0.001$ ) from the mean value for the other 4 techniques.

and > 1.6 times the normotensive peak systolic pressure (145 to 155 mm Hg).<sup>23</sup>

Isolating the liver by clamping the vena cava cranial and caudal to the liver would probably have yielded lower leakage pressures, but it does not represent the clinical situation in which blood will take the route of least resistance without being forced through the lobectomy sites. The fact that the solution infused through the portal vein was perfused directly into the liver and had to pass through the entire liver, whereas solution infused through the hepatic artery could potentially bypass the liver, might explain the reason that the leaking lobes appeared black rather than blue.

Hemorrhage from nonligated veins and venules, especially after use of a selective hepatic vascular exclusion (inflow and outflow occlusion) during surgery, is a major cause of postoperative complications described in humans and other animals and would require surgical reintervention.<sup>13,24</sup> The method described in our study was used to test both arterial and venous leakage. Arterial perfusion was included because it represents the high pressure system, whereas portal perfusion was included because it represents the major blood contribution (80%) to the liver.<sup>25</sup> Of the 6 lobes that required additional sutures or clips during surgery, only 1 was the first to leak in that dog (harmonic scalpel technique). Therefore, additional suturing during surgery does not necessarily lead to postoperative complications. The incidence of biliary leakage described in the human literature was not specifically tested and was not detected in the dogs of our study.

The perfusion fluid was saline solution instead of blood. Saline solution is easier to use, less expensive, and more readily available than blood. It also is easier to distinguish the color of the 2 perfusion solutions when saline solution is used as the diluent, and it is easier to distinguish saline solution perfusate from endogenous blood. Although use of blood or a fluid mimicking the viscosity of blood would represent a more natural situation, we believe that use of saline solution represented a good method for evaluating the bursting strength of the surgery sites on the basis that the 5 lobes and techniques were tested against each other in the same dog by use of the same instrumentation and fluids. A fluid of a higher viscosity most likely would not leak at lower pressures and would only leak at higher pressures (a less robust evaluation of bursting strength); therefore, we tested for the earliest leakage possible and still detected it at suprathysiologic pressures. Additionally, investigators in other leakage studies<sup>15,16</sup> on isolated vessels used saline solution to evaluate bursting strength.

Several factors may have influenced the results of this study. Dogs had been anesthetized for several hours prior to starting the study, and this may have negatively influenced blood pressures and ACTs. However, in only a few dogs were mean blood pressure and ACT values outside the reference limits. This postmortem method did not take into account the clotting and healing capacities of the liver. Coagulation may have played a part in the initial cessation of hemorrhage during the resections. However, because the livers were perfused with saline solution before and during pressure testing, it would be less likely that coagulation factors would

have had a major contribution to leakage or nonleakage of the lobes during testing. In typical postoperative clinical situations, clotting factors would still be present, which was not the case in this study. The liver parenchyma in clinically affected patients may differ from the livers of the healthy dogs used in this study. However, this study was specifically designed to test vascular closure without confounding clinical syndromes. Therefore, we believe that this potential difference did not influence the outcome of the perfusion tests.

In the study reported here, comparison of the actual times until leakage was desirable. However, 6 of 50 lobes did not leak, and censoring of that data would have been more inaccurate than incorporation of results for those lobes by use of a predetermined endpoint. Therefore, we evaluated the order of leakage (or failure to leak) as well as the time until leakage, with a designated endpoint (for lobes that did not leak) 60 seconds after detection of leakage in the preceding lobe.

Because of the design used in this study, the influence of lobe size was adequately addressed. The difference for the pretied suture loop procedure was significant for both time until leakage as well as for the rankings. To our knowledge, the study reported here is the first in which dual perfusion in a pressure leakage test method for dogs or humans has been described. It was possible to subject the livers to simultaneous portal and arterial testing to detect failure of the surgery sites. Closure provided by the vascular staples was not the most secure technique. The pretied suture loop device significantly outperformed the other 4 techniques.

Five surgical techniques for partial liver lobectomy in dogs were evaluated for leakage after surgery by use of an in situ postmortem perfusion method in dogs. Four previously described techniques (energy-based sealer-divider, harmonic scalpel, suction + clip, and suction + thoracoabdominal stapler) and 1 new technique (pretied suture loop) were compared. All leakages at the lobectomy sites were detected at suprathysiologic pressures. Lobectomies performed by use of the pretied suture loop technique did not leak in 5 of 10 lobes, which indicated it may be best for clinical use.

- a. Acepromazine maleate, Boehringer Ingelheim Vetmedica Inc, St Joseph, Mo.
- b. Propofol, Abbott, Abbott Park, Ill.
- c. Isoflo, Webster Veterinary, Sterling, Mass.
- d. Baxter Health Corp, Deerfield, Ill.
- e. SurgiTie, size 0 Polysorb, Covidien, Salem, Conn.
- f. LigaSure Atlas, Covidien, Salem, Conn.
- g. Ultracision Harmonic Scalpel, Ethicon Endo-Surgery, Cincinnati, Ohio.
- h. Premium Surgiclip small, Covidien, Salem, Conn.
- i. TA30-V3, Covidien, Salem, Conn.
- j. Euthasol euthanasia solution (390 mg/mL), Virbac AH Inc, Fort Worth, Tex.
- k. Surfash IV catheter, Terumo Medical Corp, Somerset, NJ.
- l. MOX-100, Waters Medical Instruments, Rochester, Minn.
- m. Methyl blue, Sigma Aldrich, St Louis, Mo.
- n. Manuscript Pen Co Ltd, Highley, Shropshire, England.
- o. SigmaStat, version 3.0, Sigma Aldrich, St Louis, Mo.

## References

1. Tobias KM. Surgical stapling devices in veterinary medicine: a review. *Vet Surg* 2007;36:341-349.

2. Bellah JR. Surgical stapling of the spleen, pancreas, liver, and urogenital tract. *Vet Clin North Am Small Anim Pract* 1994;24:375–394.
3. Constant DL, Slakey DP, Campeau RJ, et al. Laparoscopic non-anatomic hepatic resection employing the LigaSure device. *J Soc Laparoendosc Surg* 2005;9:35–38.
4. Saiura A, Yamamoto J, Koga R, et al. Usefulness of LigaSure for liver resection: analysis by randomized clinical trial. *Am J Surg* 2006;192:41–45.
5. Wrightson WR, Edwards MJ, McMasters KM. The role of the ultrasonically activated shears and vascular cutting stapler in hepatic resection. *Am Surg* 2000;66:1037–1040.
6. Lewis DD, Ellison GW, Bellah JR. Partial hepatectomy using stapling instruments. *J Am Anim Hosp Assoc* 1987;23:597–602.
7. Kaneko H, Otsuka Y, Takagi S, et al. Hepatic resection using stapling devices. *Am J Surg* 2004;187:280–284.
8. Lewis DD, Bellenger CR, Lewis DT, et al. Hepatic lobectomy in the dog. A comparison of stapling and ligation techniques. *Vet Surg* 1990;19:221–225.
9. Martin RA, Lanz OI, Tobias KM. Liver and biliary system. In: Slatter D, ed. *Textbook of small animal surgery*. 3rd ed. Philadelphia: Saunders Co, 2006;708–726.
10. Dagher I, Lainas P, Carloni A, et al. Laparoscopic liver resection for hepatocellular carcinoma. *Surg Endosc* 2008;22:372–378.
11. Tepetes K, Christodoulidis G, Spyridakis E, et al. Tissue preserving hepatectomy by a vessel sealing device. *J Surg Oncol* 2008;97:165–168.
12. Royals SR, Ellison GW, Adin CA, et al. Use of an ultrasonically activated scalpel for splenectomy in 10 dogs with naturally occurring splenic disease. *Vet Surg* 2005;34:174–178.
13. Mouiel J, Katkhouda N, Gugenheim J, et al. Possibilities of laparoscopic liver resection. *J Hepatobiliary Pancreat Surg* 2000;7:1–8.
14. Person B, Vivas DA, Ruiz D, et al. Comparison of four energy-based vascular sealing and cutting instruments: a porcine model. *Surg Endosc* 2008;22:534–538.
15. Bubenik LJ, Hosgood G, Vasanjee SC. Bursting tension of medium and large canine arteries sealed with ultrasonic energy or suture ligation. *Vet Surg* 2005;34:289–293.
16. Landman J, Kerbl K, Rehman J, et al. Evaluation of a vessel sealing system, bipolar electrocautery, harmonic scalpel, titanium clips, endoscopic gastrointestinal anastomosis vascular staples and sutures for arterial and venous ligations in a porcine model. *J Urol* 2003;169:697–700.
17. Farrar ET, Washabau RJ, Saunders HM. Hepatic abscesses in dogs: 14 cases (1982–1994). *J Am Vet Med Assoc* 1996;208:243–247.
18. Chanoit G, Kyles AE, Weisse C, et al. Surgical and interventional radiographic treatment of dogs with hepatic arteriovenous fistulae. *Vet Surg* 2007;36:199–209.
19. Schwartz SG, Mitchell SL, Keating JH, et al. Liver lobe torsion in dogs: 13 cases (1995–2004). *J Am Vet Med Assoc* 2006;228:242–247.
20. AVMA. AVMA guidelines on euthanasia. June 2007. Available at: [www.avma.org/issues/animal\\_welfare/euthanasia.pdf](http://www.avma.org/issues/animal_welfare/euthanasia.pdf). Accessed Nov 14, 2009.
21. Risselada M, Ellison GW, Bacon NJ, et al. Comparison of 5 surgical techniques for partial liver lobectomy in the dog for intraoperative blood loss and surgical time. *Vet Surg* 2010;in press.
22. Relave F, Florent D, Leclère A, et al. Evaluation of a thoracoscopic technique using ligating loops to obtain large lung biopsies in standing healthy and heaves-affected horses. *Vet Surg* 2008;37:232–240.
23. Brown S, Atkins C, Bagley R, et al. Guidelines for the identification, evaluation and management of systemic hypertension in dogs and cats. *J Vet Intern Med* 2007;21:542–558.
24. Smyrniotis V, Arkadopoulos N, Kostopanagiotou G, et al. Sharp liver dissection versus clamp crushing technique in liver resections: a prospective study. *Surgery* 2005;137:306–311.
25. Grandage J. Functional anatomy of the digestive system. In: Slatter D, ed. *Textbook of small animal surgery*. 3rd ed. Philadelphia: Saunders Co, 2006;499–521.