

Gentamicin concentrations in synovial fluid obtained from the tarsocrural joints of horses after implantation of gentamicin-impregnated collagen sponges

Kathleen M. Ivester, DVM; Stephen B. Adams, DVM, MS; George E. Moore, DVM, PhD; David C. Van Sickle, DVM, PhD; Timothy B. Lescun, BVSc, MS

Objective—To determine synovial fluid gentamicin concentrations and evaluate adverse effects on the synovial membrane and articular cartilage of tarsocrural joints after implantation of a gentamicin-impregnated collagen sponge.

Animals—6 healthy adult mares.

Procedures—A purified bovine type I collagen sponge impregnated with 130 mg of gentamicin was implanted in the plantarolateral pouch of 1 tarsocrural joint of each horse, with the contralateral joint used as a sham-operated control joint. Gentamicin concentrations in synovial fluid and serum were determined for 120 hours after implantation by use of a fluorescence polarization immunoassay. Synovial membrane and cartilage specimens were collected 120 hours after implantation and evaluated histologically.

Results—Median peak synovial fluid gentamicin concentration of 168.9 µg/mL (range, 115.6 to 332 µg/mL) was achieved 3 hours after implantation. Synovial fluid gentamicin concentrations were < 4 µg/mL by 48 hours. Major histologic differences were not observed in the synovial membrane between control joints and joints implanted with gentamicin-impregnated sponges. Safranin-O fast green stain was not reduced in cartilage specimens obtained from treated joints, compared with those from control joints.

Conclusions and Clinical Relevance—Implantation of a gentamicin-impregnated collagen sponge in the tarsocrural joint of horses resulted in rapid release of gentamicin, with peak concentrations > 20 times the minimum inhibitory concentration reported for common pathogens that infect horses. A rapid decrease in synovial fluid gentamicin concentrations was detected. The purified bovine type I collagen sponges did not elicit substantial inflammation in the synovial membrane or cause mechanical trauma to the articular cartilage. (*Am J Vet Res* 2006;67:1519–1526)

Septic arthritis is a painful and potentially life-threatening condition in horses that develops when trauma, arthrocentesis, surgery, or bacteremia results in colonization of microorganisms in a joint.¹⁻⁵ Bacterial colonization of the synovial tissues elicits a rapid and severe inflammatory response, which results in enzymatic degradation of articular cartilage.¹⁻⁷ The formation of large amounts of fibrin,⁸ proliferation of synovial tissue, and thrombosis of synovial vessels impedes nutrient flow to articular cartilage and shields bacteria from host defenses.^{1,3,5-7,9} A rapid and persistent inflammatory state quickly leads to irreversible damage to the articular cartilage, which predisposes an affected joint to osteoarthritis.

ABBREVIATIONS

MIC	Minimum inhibitory concentration
k _e	Elimination constant
t _{1/2}	Apparent half-life
AUC	Area under the concentration-versus-time curve
GAG	Glycosaminoglycan

The prognosis for return to athletic soundness is guarded when osteoarthritis develops. Rates at which horses return to their preceding degree of performance after receiving treatment for septic arthritis range from 27%^{10,11} to 81%.¹² In 1 retrospective study¹³ of 93 foals with septic arthritis, investigators found that affected Thoroughbred foals were half as likely to race, compared with the results for the general population of foals. Early aggressive treatment is essential to avoid the sequelae of permanent osteoarthritis and persistent lameness that can lead to loss of use or even death.

The goals of treatment of patients with septic arthritis are to eliminate the infective organisms and evacuate the synovial pouch of inflammatory mediators, fibrin, and debris. Mechanical lavage and drainage, debridement, and delivery of antimicrobial agents at effective concentrations form the basis of treatment.^{1-3,8,12,14} For an antimicrobial agent to be effective, it must be delivered to the infected tissues at concentrations capable of inhibiting bacterial growth. It can be difficult to achieve these concentrations by use of systemically administered drugs. The delivery of systemically administered antimicrobials to infected synovial tissues can be hindered by chronic inflammation and thrombosis of the synovium, which results in low intra-articular concentrations.^{3,9,15-18}

Intra-articular concentrations that exceed the in vitro MIC of any causative organisms do not ensure clearance of the infection because of the inoculum effect of large numbers of bacteria, protein binding of antimicrobials, seclusion of bacteria within fibrin and synovial crypts, and a decrease in pH within septic joints.^{1,3,9,14,15,19} Local antimicrobial delivery is used to

Received November 17, 2005.

Accepted March 2, 2006.

From the Departments of Veterinary Clinical Sciences (Ivester, Adams, Lescun), Veterinary Pathobiology (Moore), and Basic Medical Sciences (Van Sickle), School of Veterinary Medicine, Purdue University, West Lafayette, IN 47907.

Address correspondence to Dr. Adams.

overcome these factors during the treatment of patients with septic arthritis.^{1,17,20} One of the most commonly used antimicrobials for local delivery is the aminoglycoside gentamicin. Gentamicin is a concentration-dependent antimicrobial that has a postantimicrobial bactericidal effect proportional to the initial concentration of gentamicin to which the bacteria are exposed.^{16,17,21-25} Because this postantimicrobial bactericidal effect is a result of a nonsaturable ionic interaction between the gentamicin molecule and bacterial cell wall,^{16,22} treatment is aimed at delivering the maximum concentration of gentamicin to the infected joint. For most bacteria cultured from horses in which the isolates are considered to be susceptible to gentamicin, the MIC for the aminoglycoside ranges from 2 to 4 µg/mL.^{9,25,26} Resistance of many pathogens can be overcome by high gentamicin concentrations at the site of infection.^{2,9,21}

Several methods of local antimicrobial delivery have been developed to achieve high concentrations of gentamicin within synovial tissues. Intra-articular injection of gentamicin results in concentrations in synovial fluid that greatly exceed those achieved after IV injection, with a mean peak concentration of gentamicin of 4,745 µg/mL in radiocarpal synovial fluid after a single dose of 150 mg,^{24,25} compared with a concentration of 10.5 µg/mL after IV administration at a dosage of 8 mg/kg.²⁷ Regional limb perfusion of the equine radiocarpal joint with 1,000 mg of gentamicin reportedly can attain a mean peak concentration of 589 µg/mL in synovial fluid.²⁸ Gentamicin-impregnated polymethylmethacrylate beads containing 300 mg of gentamicin implanted into tarsocrural joints of horses have resulted in mean peak gentamicin concentrations in synovial fluid of 27.9 µg/mL.²⁹ Continuous infusion of gentamicin at a rate of 0.17 mg/kg/h into the tarsocrural joints of horses has been achieved by use of a balloon infusion system, with concentrations up to 3,510 µg/mL attained in synovial fluid.⁹

Biodegradable drug delivery systems offer the advantage of sustained release following implantation at the initial time of treatment, without the need for a second surgical procedure to remove the carrier. Purified type I collagen is a natural polymer characterized by its biocompatibility, low antigenicity, and biodegradability.^{16,17} Low immunogenicity of the collagen protein is largely attributable to the high degree of conservation among species.¹⁷ Produced from animal or recombinant sources, purified collagen can be manufactured as films, shields, gels, and sponges. Collagen sponges with gentamicin incorporated uniformly throughout the 3-dimensional matrix are commercially available.¹⁷ Implantation of a purified type I collagen sponge impregnated with 200 mg of gentamicin into a soft tissue wound of a human patient resulted in a peak gentamicin concentration of 170 µg/mL in local tissues.¹⁶ A similar collagen sponge containing 130 mg of gentamicin has been used to treat horses and cattle with septic arthritis, many of which were refractory to conventional treatment.^{14,18,30} Concentrations of gentamicin in synovial fluid after implantation of a gentamicin-impregnated collagen sponge and the effects of the implant on the joint are unknown.

The objective of the study reported here was to determine gentamicin concentrations in synovial fluid during the 120-hour period after implantation of gentamicin-impregnated collagen sponges into the tarsocrural joint of conscious horses and to evaluate any adverse mechanical or inflammatory effects of the implant on the synovial membrane and articular cartilage of the tarsocrural joint. We hypothesized that implantation of a collagen sponge impregnated with 130 mg of gentamicin sulfate would result in peak gentamicin concentrations exceeding 80 µg/mL in the synovial fluid of tarsocrural joints of horses, with gentamicin concentrations maintained at > 4 µg/mL for a period of 72 hours. In addition, we hypothesized that implantation of gentamicin-impregnated collagen sponges would not cause articular cartilage damage or increase synovitis, compared with results for nonimplanted control joints.

Materials and Methods

Animals—Six healthy adult mares (3 Quarter Horses, 2 Standardbreds, and 1 Thoroughbred) ranging from 412 to 560 kg were used in the study. All horses were scheduled to be euthanatized because of other conditions unrelated to the tarsocrural joints. Before inclusion in the study, lack of clinically detectable disease of the tarsocrural joints was confirmed by physical examination and ultrasonographic examination of each tarsus. Horses were confined to box stalls throughout the study. The Purdue University Animal Care and Use Committee approved the study protocol.

Experimental protocol—Horses were restrained in stocks and sedated by administration of xylazine hydrochloride (0.5 mg/kg, IV) and butorphanol tartrate (0.02 mg/kg, IV). The skin overlying both tarsocrural joints was prepared for aseptic cannulation. A 20-gauge needle was introduced into the dorsomedial pouch of a randomly chosen tarsocrural joint in each horse. Three milliliters of joint fluid was collected, and the joint capsule was distended by injection of 60 mL of sterile balanced electrolyte solution.⁴ Three milliliters of 2% mepivacaine hydrochloride was used to desensitize the skin over the plantarolateral pouch of the tarsocrural joint. A skin incision 5 mm in length was made over the plantarolateral pouch with a No. 15 scalpel blade. The incision was extended through the joint capsule by use of a No. 11 scalpel blade. A 5.5-mm arthroscopic trocar sleeve with conical obturator was introduced into the joint.

One collagen sponge (10 × 10 × 0.5 cm) containing 130 mg of gentamicin and 280 mg of purified native bovine collagen^b was divided into 10 rectangular sections, each of which was approximately 2 × 5 cm. The rectangular sections were rolled into small cylinders and inserted into the joint through the arthroscopic cannula by use of a conical obturator in the first horse, whereas the end of a pyramidal trocar ground to a flat tip was used to insert the sponge sections in the remaining 5 horses. All sections of the entire sponge were inserted in this manner, and the arthroscopic cannula was then removed. One or 2 simple-interrupted sutures of 2-0 polypropylene^c were used to close the skin incision.

To create a sham-operated control joint, the entire procedure was repeated on the tarsocrural joint of the contralateral limb but without insertion of the gentamicin-impregnated collagen sponge. Briefly, the cannula was introduced, the obturator removed, joint fluid released, obturator replaced, and cannula removed. The incision was closed as described for the joint in which the collagen sponge was implanted.

After surgery, each horse was returned to its stall. Physical examinations were performed twice daily. When

lameness was observed, horses were administered phenylbutazone at an initial dosage of 4.4 mg/kg, PO, followed by 2.2 mg/kg, PO, every 12 hours. When swelling of either tarsocrural joint was detected, a padded bandage was placed over the tarsocrural region.

All horses were euthanatized by administration of an overdose of barbiturate 120 hours after sponge insertion.

Collection of samples—Samples of synovial fluid were collected from both tarsocrural joints of each horse immediately before (time 0) and 3, 6, 12, 24, 36, 48, 72, 96, and 120 hours after insertion of the gentamicin-impregnated collagen sponge. Three to 4 mL of synovial fluid was collected aseptically from each joint by arthrocentesis of the dorsomedial pouch of the tarsocrural joint with a 20-gauge needle. All samples of synovial fluid were placed in evacuated tubes containing EDTA. Tubes were centrifuged at $2,700 \times g$ at 4°C for 30 minutes, and synovial fluid was immediately transferred to plastic collection tubes and frozen at -20°C until analysis.

Blood samples were collected from all horses immediately before (time 0) and 12, 24, 48, 72, 96, and 120 hours after insertion of the gentamicin-impregnated collagen sponge. Serum was harvested and stored at -20°C until analysis.

Measurement of gentamicin concentrations in synovial fluid and serum samples—Concentration of gentamicin was determined in synovial fluid obtained from treated and control joints at each time point. Serum concentrations of gentamicin were determined immediately before (time 0) and 12, 24, 48, 72, 96, and 120 hours after sponge insertion.

Gentamicin concentrations were determined by use of a fluorescence polarization immunoassay.⁴ Calibration curves were established by use of 6 human serum standards as described elsewhere.^{9,26} Coefficients of variation for equine synovial fluid spiked with gentamicin concentrations of 2,000, 500, 200, 50, 20, and 5 $\mu\text{g/mL}$ were 8.7%, 5.4%, 7.7%, 5.2%, 5.5%, and 2.5%, respectively.⁹ Test samples of synovial fluid obtained from the horses of the study reported here were diluted 1:1 with buffer solution,⁶ which was followed by a 1:10 dilution repeated as needed until the measured concentration was within the range of the assay (0 to 10 $\mu\text{g/mL}$).

Pharmacokinetic analysis—Pharmacokinetic analyses were performed as described elsewhere.⁹ Briefly, the gentamicin concentration in synovial fluid-versus-time curve was constructed for each treated joint. The value for k_e was calculated as the slope of the natural logarithm of the gentamicin concentration-versus-time curve. The $t_{1/2}$ of gentamicin in synovial fluid was calculated by use of the following equation:

$$t_{1/2} = 0.693/k_e$$

Clearance of gentamicin from synovial fluid—The AUC was calculated from the gentamicin concentration in synovial fluid-versus-time curve by use of the trapezoidal method. Clearance of gentamicin from synovial fluid was calculated by dividing the total dose of gentamicin by the AUC.

Gross evaluation of the tarsocrural joints and collection of specimens—After horses were euthanatized, each tarsocrural joint was examined by use of a systematic dissection technique described elsewhere.²⁰ Dissection began at the dorsomedial surface, and the soft tissues and joint capsule of the dorsal aspect of the tarsus were reflected laterally. The plantar pouch was approached from the lateral aspect of the tarsus. Specimens of synovial membrane for histologic evaluation were obtained from 4 sites (dorsomedial, dorsolateral, palmaromedial, and palmarolateral aspects of the joint; all specimens were obtained from locations adjacent to the surgical incision). These tissue samples were fixed in neutral-

buffered 10% formalin, processed for routine histologic examination, sectioned on a rotary microtome, and stained with H&E stain for histologic examination. Sections presumed, on the basis of histologic examination, to contain residual implant were stained with Gomori trichrome stain to identify collagen.

Two osteochondral specimens were obtained from the lateral trochlea of the talus (1 from the dorsal aspect and 1 from the plantar aspect). These specimens were fixed in neutral-buffered 10% formalin, decalcified in citrate-buffered formic acid, processed for histologic examination, embedded in a mixture of low-polymer plastic and paraffin, sectioned, and stained with H&E and safranin-O fast green stains for histologic and histochemical examination.

Evaluation of synovial membrane—All specimens were evaluated histologically by the investigators, who did not have knowledge of treatment allocations for each specimen. Specimens were evaluated by use of a grading system described elsewhere.²⁰ Four categories were scored (proliferation of synovial intimal cells and villi, evidence and location of fibrin, number and location of mononuclear cells, and number and location of neutrophils), with each category scored on a scale of 0 to 3 (0, no proliferation or component not detected; 1, mild amounts of proliferation, inflammatory infiltrate, or fibrin accumulation; 2, moderate amounts of proliferation, inflammatory infiltrate, or fibrin accumulation; or 3, severe amounts of the predominant histologic feature). Sum of the scores for the 4 categories was calculated for each site (maximum score of 12 for each site; maximum score of 48 for each joint). Evidence of hemorrhage, blood clots, or bacteria was also recorded but not graded.

Evaluation of articular cartilage—Articular cartilage of the osteochondral specimens was stained with safranin-O fast green stain and scored by use of a scale described elsewhere.²⁰ Specimens were scored for each of 3 separate zones (superficial, intermediate, and deep) on a scale of 0 to 3 (0, no staining of matrix; 1, mild staining of matrix; 2, moderate staining of matrix; and 3, maximal staining of matrix). Sections of tracheal cartilage served as positive control samples for staining of GAGs by the safranin-O fast green stain.

Articular cartilage of the osteochondral specimens was stained with H&E stain and evaluated histologically. Abnormalities such as surface fibrillation, erosions, cluster formation, and chondrocytic death were recorded.

Statistical analysis—For continuous and ordinal data, median values were compared by use of the Wilcoxon signed rank test for paired samples. Values of $P < 0.05$ were considered significant. Calculations were performed by use of statistical software.^f

Results

Clinical observations—All horses tolerated cannulation of the tarsocrural joint while sedated and with local analgesia. By 12 hours after insertion, all joints implanted with the gentamicin-impregnated collagen sponge were warm and had mild amounts of periarticular edema and effusion. Despite apparent mild effusion, arthrocentesis of joints implanted with the gentamicin-impregnated collagen sponge consistently yielded fluid less readily than did control joints for the initial 24 hours after implantation.

In all horses, mild lameness coincided with effusion and periarticular swelling. Lameness was characterized by full bearing of weight with a slightly shortened cranial phase of the stride and decreased height of the arc of the foot flight during walking. Lameness

resolved within 12 hours after initiation of phenylbutazone administration. Three horses developed periarticular edema of the sham-operated control joint 36 to 72 hours after surgery. Padded bandages were maintained on all swollen tarsi (all treated joints and control joints of the aforementioned 3 horses with periarticular edema). Throughout the study, all horses maintained a typical attitude and appetite and had values for temperature, pulse rate, and respiratory rate that were within the respective reference ranges.

Gentamicin concentrations in synovial fluid and serum and pharmacokinetic analysis—Peak gentamicin concentration in synovial fluid obtained from joints implanted with the gentamicin-impregnated collagen sponge was detected 3 hours after implantation, with the range and median values for peak concentration of 115.6 to 332.0 $\mu\text{g/mL}$ and 168.9 $\mu\text{g/mL}$, respectively. By 24 hours after implantation, the gentamicin concentration of 2 of 6 treated joints had decreased to $< 4 \mu\text{g/mL}$. By 36 hours after implantation, 4 of 6 treated joints had gentamicin concentrations $< 4 \mu\text{g/mL}$, and by 48 hours, gentamicin concentrations in synovial fluid obtained from all joints implanted with gentamicin-impregnated collagen sponges were $< 4 \mu\text{g/mL}$ (Figure 1).

Pharmacokinetic variables were calculated (Table 1). Analysis of the concentration-versus-time curve revealed a bimodal elimination rate, with rapid elimination between 3 and 12 hours (Figure 1).

Gentamicin concentrations in synovial fluid obtained from sham-operated control joints ranged from 0 to 0.92 $\mu\text{g/mL}$, with range and median values for the peak concentration of 0.24 to 0.92 $\mu\text{g/mL}$ and 0.48 $\mu\text{g/mL}$, respectively. Median gentamicin concentrations in synovial fluid were significantly greater for treated joints than for control joints at 48 ($P = 0.028$) and 72 ($P = 0.028$) hours after implantation, but not at 96 ($P = 0.052$) or 120 ($P = 0.092$) hours after implantation. Serum concentrations of gentamicin remained $< 0.5 \mu\text{g/mL}$ at all time points during the study.

Gross evaluation of joints—Necropsy revealed that all joints had hemorrhage and edema extending from the synovial surface to the fibrous portion of the joint capsule at the arthrocentesis site of the dorsomedial joint pouch, regardless of treatment group. Gross examination did not reveal differences between treated and sham-operated control joints, except for the synovium of the plantar joint pouch. All joints implanted with the gentamicin-impregnated collagen sponges had a red, delicate, fibrous material adherent to the plantaromedial synovium. No defects in articular cartilage were grossly evident.

Evaluation of synovial membrane—Histologic scores were determined by examination of H&E-stained sections and expressed as total score and as a percentage of maximum possible score per joint. The most consistent histologic findings were mild proliferation of synovial cells (range, 0 to 2) and mild infiltration of mononuclear cells into the subintima (range, 0 to 2). No significant ($P = 0.2$) difference was found between treatment and control joints at any of the 4 sites examined. Histologic scores did not differ signifi-

cantly ($P = 0.28$) between the joints implanted with gentamicin-impregnated collagen sponges and the sham-operated control joints (Figure 2). Examination of H&E-stained sections of synovial membranes obtained from the plantar joint pouch of each joint implanted with a gentamicin-impregnated collagen sponge revealed a homogenous, eosinophilic substance that was variably populated with WBCs and RBCs. Examination of sections stained by use of Gomori trichrome stain confirmed this material was collagen (which presumably was remnants of the implant) surrounded by a proteinaceous, fibrinous layer more heavily populated with predominantly macrophages (Figure 3). A differential count of the nucleated cells within the collagen remnant revealed macrophages to be the predominant cell type, with polymorphonuclear cells accounting for $< 35\%$ of counted cells in all samples.

All specimens of synovial membrane obtained from the dorsomedial aspect of the joints had subsynovial hemorrhage. Clot formation was visible on the synovial surface of the control joint of 1 horse. In another horse, implant material was microscopically apparent in the joint implanted with the gentamicin-impregnated collagen sponge.

Histologic examination of synovial membrane obtained from the dorsolateral joint pouch revealed implant material in one of the joints implanted with a gentamicin-impregnated collagen sponge. All specimens of synovial membrane obtained from the plantarolateral joint pouch had subsynovial hemorrhage. In most of these specimens, the hemorrhage was severe. Implant material was seen at the plantarolateral site in all joints treated by insertion of gentamicin-impregnated collagen sponges. In 2 specimens (the control joint of 1 horse and the joint implanted with a gentamicin-impregnated collagen sponge in another horse), we detected large focal areas of intense infiltration with macrophages and polymorphonuclear cells, which appeared to be in response to the incision.

Examination of the specimens of synovial membrane obtained from the plantaromedial joint pouch

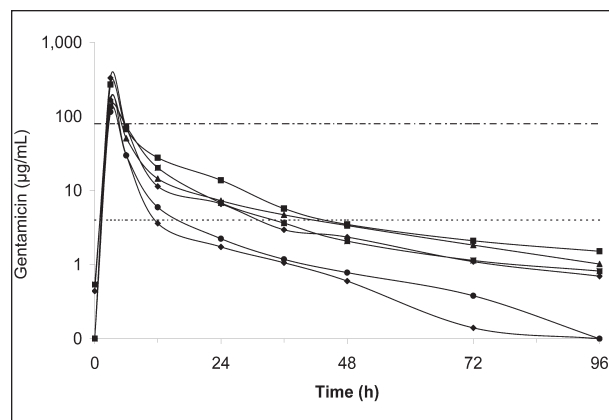


Figure 1—Gentamicin concentrations in samples of synovial fluid obtained from a tarsocrural joint of 6 horses at various time points after implantation of a gentamicin-impregnated collagen sponge. Each sponge contained 130 mg of gentamicin sulfate. Each symbol represents results for 1 horse. Notice that horizontal lines indicate concentrations of 4 $\mu\text{g/mL}$ (dotted line) and 80 $\mu\text{g/mL}$ (dotted and dashed line). Time 0 = Time of implantation.

Table 1—Values for pharmacokinetic variables after implantation of gentamicin-impregnated collagen sponges into a tarsocrural joint in each of 6 horses.

Variable	Minimum	Maximum	Median	Mean	SD
$k_e\alpha$ (1/h)	0.21	0.42	0.29	0.30	0.08
$t_{1/2}\alpha$ (h)	1.67	3.26	2.39	2.42	0.62
$k_e\beta$ (1/h)	0.03	0.05	0.03	0.04	0.01
$t_{1/2}\beta$ (h)	13.08	23.10	19.85	18.94	3.72
AUC ([mg·h)/mL)	1.24	3.62	1.88	2.12	0.95
Clearance from synovial fluid (mL/min)	1.24	3.62	1.88	2.12	0.95
Peak gentamicin concentration ($\mu\text{g}/\text{mL}$)					
Serum	0.07	0.32	0.24	0.23	0.09
Synovial fluid					
Treated joints	138.2	332.0	168.9	194.64	83.90
Control joints*	0.40	0.92	0.58	0.61	0.21

*Control joints were the contralateral tarsocrural joint in each horse subjected to a sham operation to simulate implantation of collagen sponges.

$k_e\alpha$ = The k_e for gentamicin from synovial fluid for the period 3 to 12 hours after implantation of the gentamicin-impregnated collagen sponge. $t_{1/2}\alpha$ = The $t_{1/2}$ of gentamicin from synovial fluid for the period 3 to 12 hours after implantation of the gentamicin-impregnated collagen sponge. $k_e\beta$ = The k_e for gentamicin from synovial fluid for the period 12 to 96 hours after implantation of the gentamicin-impregnated collagen sponge. $t_{1/2}\beta$ = The $t_{1/2}$ of gentamicin from synovial fluid for the period 12 to 96 hours after implantation of the gentamicin-impregnated collagen sponge.

revealed remnants of the collagen sponge at the synovial surface of 4 horses. A specimen of synovial membrane from the plantaromedial pouch of the control joint was not obtained for the initial horse because this site for collection was added only after dissection and examination of the treated joint.

Evaluation of articular cartilage—

Examination of H&E-stained specimens revealed a small area of mild superficial fibrillation of the articular cartilage of the dorsolateral and plantarolateral trochleas in the sham-operated control and treated joints of 2 horses. Formation of focal, mild, superficial chondrocytic clusters was evident in the control joints of 3 horses. A similar pattern of chondrocytic clusters was also detected in the treated joint of one of those horses.

Intensity of staining with safranin-O fast green stain for the dorsolateral trochlea did not differ significantly ($P = 0.086$) between treated joints implanted with gentamicin-impregnated collagen sponges and sham-operated control joints. However, scores for intensity of staining with safranin-O fast green stain for the plantarolateral trochlea of joints implanted with gentamicin-impregnated collagen sponges were significantly ($P = 0.023$) higher, compared with scores for the sham operated control joints. Intensity of staining of the matrix with safranin-O fast green stain did not differ significantly ($P = 0.18$) between the dorsolateral trochlea and plantarolateral trochlea sites.

Discussion

Analysis of our results indicates that when implanted in the tarsocrural joint of horses, gentamicin-impreg-

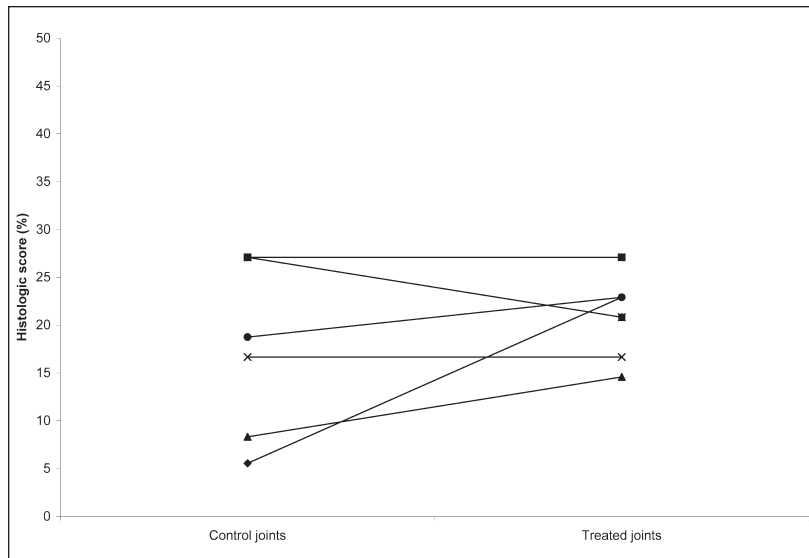


Figure 2—Percentage of maximum possible histologic score (maximum possible score for each joint, 48) for specimens of synovial membrane obtained from the tarsocrural joints of 6 horses 120 hours after implantation of a gentamicin-impregnated collagen sponge (treated joints) or sham operation (control joints). Each horse is represented by a line connecting the histologic score of the control joint with the histologic score of the treatment joint. Histologic scores did not differ significantly ($P = 0.28$) between control and treated joints.

nated collagen sponges rapidly elute gentamicin, achieving concentrations in synovial fluid ranging from 115.6 to 332.0 $\mu\text{g}/\text{mL}$ by 3 hours after implantation. Collection of synovial fluid samples earlier than 3 hours after implantation may have revealed even higher concentrations. After 3 hours, gentamicin concentrations rapidly decreased, with clearance from synovial fluid comparable to that for direct intra-articular injection of gentamicin.²⁵

The partially closed, porous, gentamicin-impregnated collagen sponge used in the study reported here provides an initial burst of gentamicin release followed by a prolonged secondary and tertiary release when implanted in closed soft tissue spaces.¹⁶ We did not find such a pattern of release when implanted in the tar-

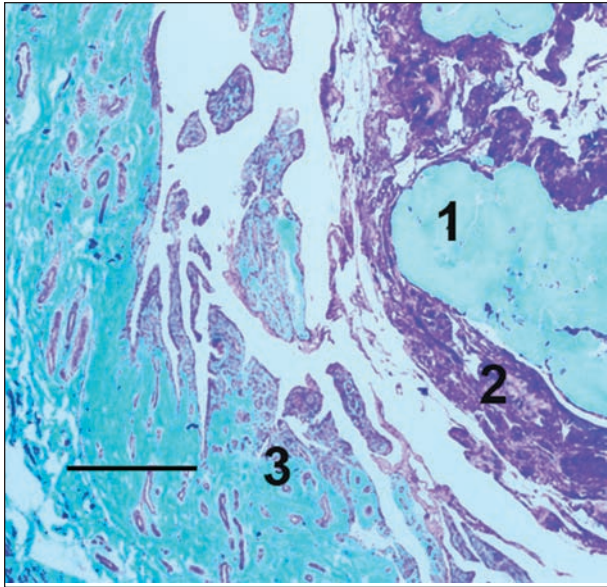


Figure 3—Photomicrograph of a section of synovial membrane obtained from the plantarolateral joint pouch of the tarsocrural joint of a horse 120 hours after implantation of a gentamicin-impregnated collagen sponge. The remnant of the collagen sponge is evident as homogenous blue staining (1) on a background of eosinophilic protein (2) adjacent to normal synovial villi (3). Gomori's trichrome stain; bar = 500 μ m.

socrural joint of horses. The large size of the tarsocrural joint, continual production of synovial fluid, and composition of the fluid within the joint may have accelerated degradation of the collagen sponge and elution of gentamicin, compared with results for nonarticular closed soft tissue spaces. Degradation of the collagen sponge could be expected to be even more rapid in the face of effusion and degradative enzymes that accompany infection of the joint.

Detection of small quantities of gentamicin in the control joints was expected.⁹ The peak gentamicin concentration in synovial fluid obtained from the control joints was detected between 3 and 6 hours after implantation, which suggests that the true peak gentamicin concentration in serum may have been prior to this time frame and, therefore, may have been missed in the study reported here. To minimize the risk of adverse systemic effects, trough serum concentrations of gentamicin < 2 μ g/mL are recommended.²⁶ By 12 hours after implantation, serum concentrations of gentamicin remained < 0.5 μ g/mL, which verified a trough serum concentration substantially less than the target trough concentration.

Gentamicin was detected in 4 synovial fluid samples obtained at time 0 (ie, before insertion of the gentamicin-impregnated collagen sponge). Other closely related aminoglycosides, such as sagamicin, sisomicin, and netilmicin, can artificially increase the concentration of gentamicin detected by the fluorescence polarization immunoassay.³¹ Mares used in the study reported here were all part of a university herd and had not received gentamicin or other medications within the 9 months preceding their inclusion in this study. Values measured by the assay for samples collected at time 0 were all \leq 0.27 μ g/mL, the lower limit at which the

assay can distinguish gentamicin concentrations from 0 with 95% confidence. The small amount of gentamicin reported in these samples reflects limitations of the fluorescence polarization immunoassay, the high degree of variability in this assay, and evidence of false-positive results. The fluorescence polarization immunoassay used in this study is an automated system that requires human serum standards provided by the manufacturer for calibration. Composition of equine synovial fluid and equine serum may alter the specificity of the assay.

Purified type I bovine collagen caused minimal inflammatory reactions in tarsocrural joints of horses and thus appears suitable for intra-articular drug delivery. Inflammatory changes in the synovial membrane were mild in treated joints implanted with gentamicin-impregnated collagen sponges and sham-operated control joints, with no significant difference between treated and control joints.

Because loss of GAG from the cartilage matrix is considered an early indication of cartilage damage,³² GAG content was compared between treatment and control joints by staining osteochondral specimens with the safranin-O fast green stain, an indirect indicator of proteoglycan content. Sections of articular cartilage examined did not have evidence of loss of safranin-O fast green staining in the matrix of treated joints, nor was there evidence of increased surface fibrillation or erosion of articular cartilage in joints implanted with the gentamicin-impregnated collagen sponges. Surprisingly, staining of the matrix of the articular cartilage of the plantarolateral trochlea of the talus was greater in joints treated by implantation with the gentamicin-impregnated collagen sponges. It is possible that the collagen may have elicited an increase in the production of GAGs through participation in the complex feedback mechanisms of cartilage matrix homeostasis. Bovine chondrocytes in cell cultures supplemented with type I or II collagen hydrolysate respond with an increase in production of type II collagen, which indicates the potential for collagen fragments to act as peptide anabolic cytokines.³³

Alternatively, gentamicin may prevent the loss of GAG from articular cartilage. In 1 study,³⁴ investigators reported a decrease in the percentage of GAG that was lost from equine articular cartilage explants treated with gentamicin (10 mg/mL), compared with results for control explants.

By 120 hours after implantation, gentamicin-impregnated collagen sponges were grossly visible only in the form of red, delicate, fibrous material adhered to the synovial surface of the plantar joint pouch. This material was histologically confirmed to be remnants of the implant by use of Gomori trichrome stain, which revealed homogeneously condensed collagen variably populated with macrophages, neutrophils, and RBCs. Detection of the RBCs suggested that the cellular population was a result, at least in part, of entrapment of cells contained within the synovial fluid, rather than purely a result of infiltration of inflammatory cells into the implants. This entrapment of synovial fluid within the implant may explain the initial increased difficulty in obtaining fluid from tarsocrural joints implanted

with the gentamicin-impregnated collagen sponges. Intra-articular administration of gentamicin and arthrocentesis can induce synovitis.^{19,20,24} On the basis of results of the study reported here, we were unable to discern between effects on the joints attributable to gentamicin or collagen.

It is interesting that all horses had a consistent onset of lameness, which was evident during walking at 12 hours after implantation, considering the low degree of inflammation apparent during histologic examination of the synovial membranes. The most striking finding during physical examination at 12 hours after implantation was mild periarticular edema. The acute lameness may have been a reflection of a transient synovitis in reaction to the implant. Alternatively, the lameness may have been related to the trauma incurred during cannulation of the joint, rather than to the sponge itself. Although the contralateral joint was cannulated to serve as a sham-operated control joint, less trauma was incurred because the arthroscopic cannula was introduced into the joint, the trocar removed and then replaced, and the cannula withdrawn. During insertion of the collagen sponges, repeated introduction and withdrawal of the trocar and the longer duration of the procedure may have elicited greater periarticular inflammation of the treated joints. This lameness and periarticular edema would not be expected to pose a problem in clinically affected horses because the lameness and edema resolved promptly after application of padded bandages and administration of phenylbutazone, treatments that are both likely to be instituted as part of any plan for treatment of patients with septic arthritis.

Horses used in the study reported here tolerated cannulation of the plantarolateral pouch of the tarsocrural joint without the need for general anesthesia. Introduction of the gentamicin-impregnated collagen sponges into the joints was greatly facilitated by modification of the trocar. The flat tip of the modified trocar allowed the cylinder-shaped sponge implants to be pushed easily through the trocar sleeve, which minimized surgery time. However, the need to cut the sponge into multiple pieces, which were then rolled to form small cylinders, remained a time-consuming procedure.

On the basis of pharmacokinetics of gentamicin in synovial fluid determined in the study reported here, our first hypothesis was rejected. Although intra-articular implantation of the gentamicin-impregnated collagen sponge did provide an initial peak concentration of gentamicin > 80 µg/mL, the implant did not offer sustained gentamicin concentrations within the synovial fluid. On the basis of these results, implantation of the gentamicin-impregnated collagen sponge does not offer any advantage over direct intra-articular injection of gentamicin into the joint. Our second hypothesis was accepted because the purified type I collagen sponge did not increase synovitis or result in mechanical trauma to the articular cartilage.

Collagen implants remain an attractive mode for intra-articular drug delivery. Manipulation of the collagen matrix during processing allows for production of a number of implants with differing patterns of drug

release. Changes in pressure, temperature, humidity, collagen concentration, and drug concentration during production of implants can achieve specific kinetics for drug release.^{16,17} Absorbable diffusion barriers, such as an additional layer of collagen or another biodegradable polymer, can be used to further tailor the drug release pattern. A gentamicin-impregnated collagen implant, shaped to allow ease of insertion through an arthroscopic cannula, could be designed specifically for intra-articular use. Ideally, such an implant would provide an initial burst of gentamicin release, as was detected for the current gentamicin-impregnated collagen sponge, which would be followed by a relatively constant synovial fluid concentration of gentamicin that would be higher than the MIC for common pathogens. Alternatively, an implant with alternating layers of gentamicin-impregnated collagen and an absorbable diffusion barrier could be designed to provide repeated bursts of gentamicin into the synovial fluid at 24-hour intervals, which would exploit the postantibiotic effect of the aminoglycosides with daily, transient peak concentrations.

-
- a. Lactated Ringer's Irrigation, B Braun Medical Inc, Irving, Calif.
 - b. Garamycin implant, Fulford Ltd, Schering-Plough International Inc, Mumbai, India.
 - c. Prolene, Ethicon Inc, Somerville, NJ.
 - d. TDx analyzer, Abbott Diagnostics Inc, Abbott Park, Ill.
 - e. X SYSTEMS dilution buffer, Abbott Diagnostics Inc, Abbott Park, Ill.
 - f. STATA, version 8.2, StataCorp, College Station, Tex.
-

References

1. McIlwraith CW. Diseases of joint, tendons, ligaments, and related structures. In: Stashak TS, ed. *Adams' lameness in horses*. Philadelphia: Lippincott Williams & Wilkins, 2002;459–588.
2. Schneider RK. Orthopedic infections. In: Auer JA, Stick JA, eds. *Equine surgery*. Philadelphia: WB Saunders Co, 1999;727–736.
3. McIlwraith CW. Treatment of infectious arthritis. *Vet Clin North Am Large Anim Pract* 1983;5:363–379.
4. Schneider RK, Bramlage LR, Moore RM, et al. A retrospective study of 192 horses affected with septic arthritis/tenosynovitis. *Equine Vet J* 1992;24:436–442.
5. Bertone AL. Infectious arthritis. In: McIlwraith CW, Trotter GW, eds. *Joint disease in the horse*. Philadelphia: WB Saunders Co, 1996;397–409.
6. Meijer MC, Van Weeren PR, Rijkenhuizen ABM. Clinical experiences of treating septic arthritis in the equine by repeated joint lavage: a series of 39 cases. *J Vet Med A Physiol Pathol Clin Med* 2000;47:351–365.
7. Spiers S, May SA, Harrison LJ, et al. Proteolytic enzymes in equine joints with infectious arthritis. *Equine Vet J* 1994;26:48–50.
8. Orsini JA. Strategies for treatment of bone and joint infections in large animals. *J Am Vet Med Assoc* 1984;185:1190–1193.
9. Lescun TB, Adams SB, Wu CC, et al. Continuous infusion of gentamicin into the tarsocrural joint of horses. *Am J Vet Res* 2000;61:407–412.
10. Schneider RK, Bramlage LR, Mecklenburg LM, et al. Open drainage, intra-articular and systemic antibiotics in the treatment of septic arthritis/tenosynovitis in horses. *Equine Vet J* 1992;24:443–449.
11. LaPointe JM, Laverty S, LaVoie JP. Septic arthritis in 15 Standardbred racehorses after intra-articular injection. *Equine Vet J* 1992;24:430–434.
12. Wright IM, Smith MRW, Humphrey DJ, et al. Endoscopic surgery in the treatment of contaminated and infected synovial cavities. *Equine Vet J* 2003;35:613–619.
13. Steel CM, Hunt AR, Adams PLE, et al. Factors associated with prognosis for survival and athletic use in foals with septic

- arthritis: 93 cases (1987–1994). *J Am Vet Med Assoc* 1999; 215:973–977.
14. Summerhays GES. Treatment of traumatically induced synovial sepsis in horses with gentamicin-impregnated collagen sponges. *Vet Rec* 2000;147:184–188.
 15. Bertone AL, Jones RL, McIlwraith CW. Serum and synovial fluid steady-state concentrations of trimethoprim and sulfadiazine in horses with experimentally induced infectious arthritis. *Am J Vet Res* 1988;49:1681–1687.
 16. Ruszczak Z, Friess W. Collagen as a carrier for on-site delivery of antibacterial drugs. *Adv Drug Deliv Rev* 2003;55:1679–1698.
 17. Friess W. Collagen—biomaterial for drug delivery. *Eur J Pharm Biopharm* 1998;45:113–136.
 18. Hirsbrunner G, Steiner A. Treatment of infectious arthritis of the radiocarpal joint of cattle with gentamicin-impregnated collagen sponges. *Vet Rec* 1998;142:399–402.
 19. Stover SM, Pool RR. Effect of intra-articular gentamicin sulfate on normal equine synovial membrane. *Am J Vet Res* 1985; 46:2485–2491.
 20. Lescun TB, Adams SB, Wu CC, et al. Effects of continuous intra-articular infusion of gentamicin on synovial membrane and articular cartilage in the tarsocrural joint of horses. *Am J Vet Res* 2002;63:683–687.
 21. Moore RD, Lietman PS, Smith CR. Clinical response to aminoglycoside therapy: importance of the ratio of peak concentration to minimal inhibitory concentration. *J Infect Dis* 1987;155:93–99.
 22. Jackson GG, Lolans VT, Daikos GL. The inductive role of ionic binding in the bactericidal and postexposure effects of aminoglycoside antibiotics with implications for dosing. *J Infect Dis* 1990;162:408–413.
 23. Godber LM, Walker RD, Stein GE, et al. Pharmacokinetics, nephrotoxicosis, and in vitro antibacterial activity associated with single versus multiple (three times) daily gentamicin treatments in horses. *Am J Vet Res* 1995;56:613–618.
 24. Lloyd KCK, Stover SM, Pascoe JR, et al. Synovial fluid pH, cytologic characteristics, and gentamicin concentration after intra-articular administration of the drug in an experimental model of infectious arthritis in horses. *Am J Vet Res* 1990; 51:1363–1369.
 25. Lloyd KC, Stover SM, Pascoe JR, et al. Plasma and synovial fluid concentrations of gentamicin in horses after intra-articular administration of buffered and unbuffered gentamicin. *Am J Vet Res* 1988;49:644–649.
 26. Sojka JE, Brown SA. Pharmacokinetic adjustment of gentamicin dosing in horses with sepsis. *J Am Vet Med Assoc* 1986; 189:784–789.
 27. Doherty TJ, Novotny MJ, Desjardins MR, et al. Gentamicin concentrations in body fluids of adult horses following high-dose administration, in *Proceedings*. 40th Annu Meet Am Assoc Equine Pract 1994;113–114.
 28. Whitehair KJ, Blevins WE, Fessler JF, et al. Regional perfusion of the equine carpus for antibiotic delivery. *Vet Surg* 1992;21:279–285.
 29. Farnsworth KD, White NA, Robertson J. The effect of implanting gentamicin-impregnated polymethylmethacrylate beads in the tarsocrural joint of the horse. *Vet Surg* 2001;30:126–131.
 30. Zulauf M, Jordan P, Steiner A. Fenestration of the abaxial hoof wall and implantation of gentamicin-impregnated collagen sponges for the treatment of septic arthritis of the distal interphalangeal joint in cattle. *Vet Rec* 2001;149:516–518.
 31. Jolley ME, Stroupe SD, Wang CHJ, et al. Fluorescence polarization immunoassay I. Monitoring aminoglycoside antibiotics in serum and plasma. *Clin Chem* 1981;27:1190–1197.
 32. McIlwraith CW. General pathobiology of the joint and response to injury. In: McIlwraith CW, Trotter GW, eds. *Joint disease in the horse*. Philadelphia: WB Saunders Co, 1996;40–70.
 33. Oesser S, Seifert J. Stimulation of type II collagen biosynthesis and secretion in bovine chondrocytes cultured with degraded collagen. *Cell Tissue Res* 2003;311:393–399.
 34. McCarthy HE, Singer ER, Davies Morel CG. The effect of sodium heparin on equine articular cartilage. *Vet J* 2001;162:73–79.