

In vitro evaluation of canine and feline calcium oxalate urolith fragility via shock wave lithotripsy

Larry G. Adams, DVM, PhD; James C. Williams Jr, PhD; James A. McAteer, PhD; Erin K. Hatt BS; James E. Lingeman, MD; Carl A. Osborne, DVM, PhD

Objective—To test the hypothesis that feline calcium oxalate uroliths are intrinsically more resistant to comminution via shock wave lithotripsy (SWL) than canine calcium oxalate uroliths through comparison of the fragility of canine and feline uroliths in a quantitative in vitro test system.

Sample Population—Calcium oxalate uroliths (previously obtained from dogs and cats) were matched by size and mineral composition to create 7 pairs of uroliths (1 canine and 1 feline urolith/pair).

Procedure—Uroliths were treated in vitro with 100 shock waves (20 kV; 1 Hz) by use of an electrohydraulic lithotripter. Urolith fragmentation was quantitatively assessed via determination of the percentage increase in projected area (calculated from the digital image area of each urolith before and after SWL).

Results—After SWL, canine uroliths ($n = 7$) fragmented to produce a mean \pm SD increase in image area of $238 \pm 104\%$, whereas feline uroliths (7) underwent significantly less fragmentation (mean image area increase of $78 \pm 97\%$). The post-SWL increase in fragment image area in 4 of 7 feline uroliths was $< 50\%$, whereas it was $> 150\%$ in 6 of 7 canine uroliths.

Conclusions and Clinical Relevance—Results indicate that feline calcium oxalate uroliths are less susceptible to fragmentation via SWL than canine calcium oxalate uroliths. In some cats, SWL may not be efficacious for fragmentation of calcium oxalate nephroliths or ureteroliths because the high numbers of shock waves required to adequately fragment the uroliths may cause renal injury. (*Am J Vet Res* 2005;66:1651–1654)

In vitro studies and clinical experience in humans have revealed that uroliths of different major mineral composition have differential susceptibility to comminution via shock wave lithotripsy (SWL).¹⁻³ Some urolith types are easier to fragment than others. In an in vitro study¹ to investigate the fragility of various nephroliths in humans by use of SWL, the fragmentation of nephroliths of different composition was ranked; nephroliths composed of uric acid were the

easiest to fragment, followed (with increasing difficulty) by those composed of hydroxyapatite, calcium oxalate monohydrate, brushite, struvite, and cystine. However, naturally occurring uroliths have significant variability in their fragility (coefficient of variation for human nephroliths is approx 60%), and human uroliths of the same composition may differ dramatically (eg, > 10 -fold difference) in the number of shock waves needed for complete breakage.¹ Unfortunately, a predictable model to assess the basis for urolith fragility has not been identified.

Although we have had good success with fragmentation of calcium oxalate nephroliths and ureteroliths in dogs via SWL by use of an unmodified, first-generation, waterbath-type lithotripter,^{4,3a} calcium oxalate uroliths in cats have been more difficult to fragment via SWL by use of the same lithotripter. In 1 study,⁵ attempts to fragment calcium oxalate nephroliths and ureteroliths via SWL failed in 4 of 5 cats. One potential explanation for the inability to fragment the ureteroliths in those cats is that impacted ureteroliths are more difficult to fragment than nephroliths or nonimpacted ureteroliths.^{6,7} Impacted ureteroliths may not be surrounded by a sufficient amount of urine for cavitation bubbles to form on the near side of the urolith. Because cavitation bubble activity contributes to urolith breakage,⁸ the lack of urine around impacted ureteroliths may decrease the efficiency of shock wave-induced comminution of ureteroliths. Nonetheless, we have had better success with fragmentation of impacted ureteroliths in dogs than in cats, using the same lithotripter.⁵ Therefore, the purpose of the study reported here was to test our hypothesis that feline calcium oxalate uroliths are intrinsically more resistant to comminution via SWL than canine calcium oxalate uroliths through comparison of the fragility of canine and feline uroliths in a quantitative in vitro test system.

Materials and Methods

Uroliths formed by dogs and cats that were composed of 100% calcium oxalate monohydrate (designated COM

Received August 9, 2004.

Accepted November 10, 2004.

From the Department of Veterinary Clinical Sciences, School of Veterinary Medicine, Purdue University, West Lafayette, IN 47907-1277 (Adams); Department of Anatomy and Cell Biology, Indiana University School of Medicine, Indianapolis, IN 46202-5120 (Williams, McAteer, Hatt); Methodist Hospital Institute for Kidney Stone Disease, 1801 N Senate Blvd Suite 220, Indianapolis, IN 46202 (Lingeman); and the Minnesota Urolith Center, Department of Small Animal Clinical Sciences, College of Veterinary Medicine, University of Minnesota, Saint Paul, MN 55108 (Osborne).

Supported by National Institutes of Health grants DK43881 and DK55674.

Presented in part at the Annual Veterinary Medical Forum of the American College of Veterinary Internal Medicine, Charlotte, NC, June 2003. The authors thank Lisa Ulrich for retrieval and pairing of the uroliths from the Minnesota Urolith Center.

Address correspondence to Dr. Adams.

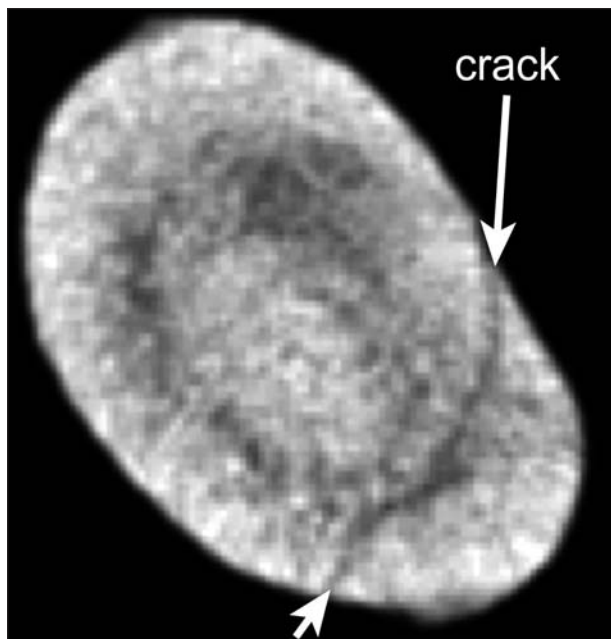


Figure 1—Micro-computed tomographic image of a calcium oxalate monohydrate (COM) urolith obtained from a cat. Notice that this urolith has a preexisting crack (arrows); because of the crack, this urolith and its paired canine urolith (matched on the basis of size and composition) were both excluded from the shock wave lithotripsy (SWL) fragmentation study.

uroliths), 100% calcium oxalate dihydrate (designated COD uroliths), or both calcium oxalate monohydrate and calcium oxalate dihydrate (designated COM-COD uroliths) were retrieved from collections at the Minnesota Urolith Center. The uroliths were matched by size and composition to create 10 pairs of uroliths (1 canine and 1 feline urolith/pair). The mean maximum diameter for the feline and canine uroliths was 3.9 ± 1.3 mm and 4.1 ± 1.5 mm, respectively.

Uroliths were evaluated via micro-computed tomography (micro-CT)^b to exclude those with preexisting cracks (Figure 1).⁹ Three pairs of uroliths were excluded from further study because of preexisting cracks; thus, there were 4 COD urolith pairs, 2 COM urolith pairs, and 1 COM-COD urolith pair for evaluation via in vitro fragmentation. The area of digital images of the uroliths was obtained by scanning uroliths on a flatbed optical scanner prior to SWL. Uroliths were hydrated in saline (0.9% NaCl) solution for 4 days and then treated with 100 shock waves (20 kV; 1 Hz) by use of a research electrohydraulic lithotripter that had the same acoustic output as the unmodified, first-generation, waterbath-type lithotripter. Urolith fragments were scanned, and the increases in digital image area of fragments were compared with the area of uroliths before shock wave exposure (Figure 2). To validate the size pairing, the sizes of canine and feline uroliths prior to fragmentation were compared by use of an unpaired *t* test. The difference in the percentage increase in digital surface area of uroliths following SWL between canine and feline uroliths was compared by use of an unpaired *t* test. For all comparisons, a value of $P < 0.05$ was considered significant.

Results

Prior to fragmentation, there was no significant ($P = 0.82$) difference between the size of canine and feline uroliths, as determined by use of an unpaired *t* test. After SWL, significantly ($P < 0.02$, by unpaired *t* test) less fragmentation was observed in feline uroliths,

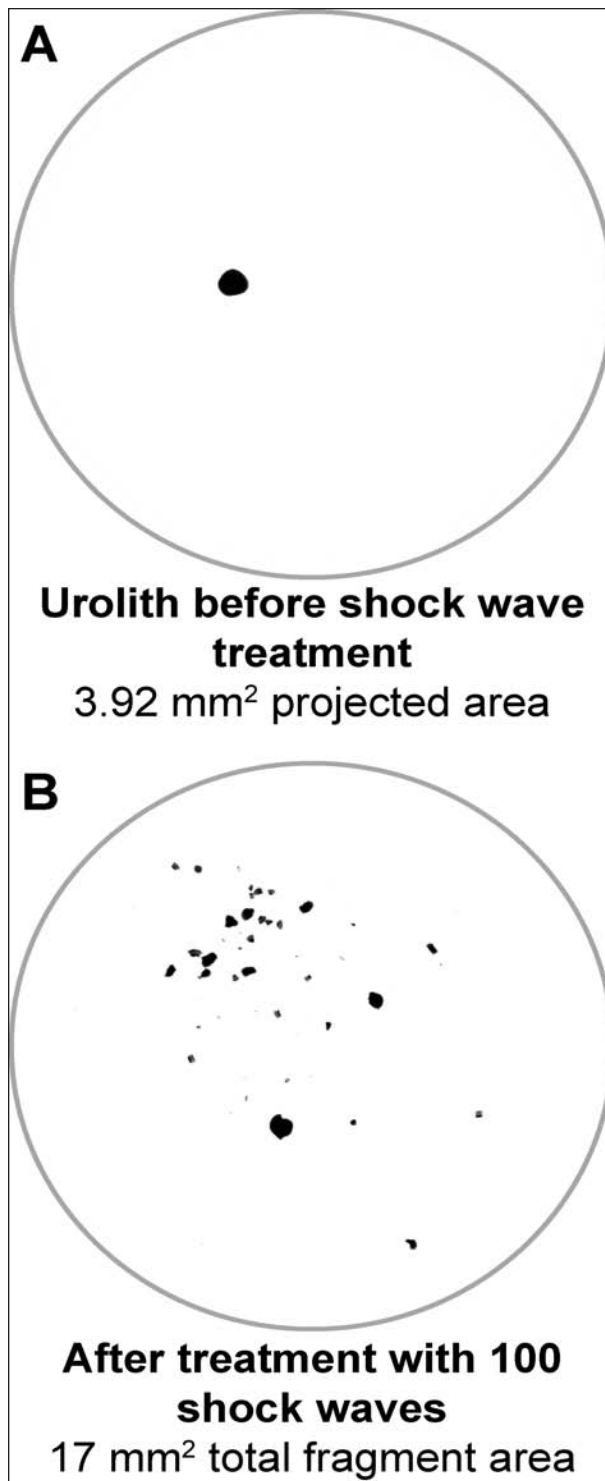


Figure 2—Representative digital image of a calcium oxalate urolith from a dog before (A) and after SWL (B). Notice the increased image surface area after fragmentation via SWL. For this urolith, the percentage increase in area was $100 \cdot (17 - 3.92) \cdot (3.92)^{-1} = 334\%$.

compared with that which occurred in canine uroliths (Figure 3). Canine uroliths ($n = 7$) fragmented with a resultant mean increase in image area of $238 \pm 104\%$, whereas feline uroliths (7) fragmented with a resultant mean increase in image area of $78 \pm 97\%$. The increase

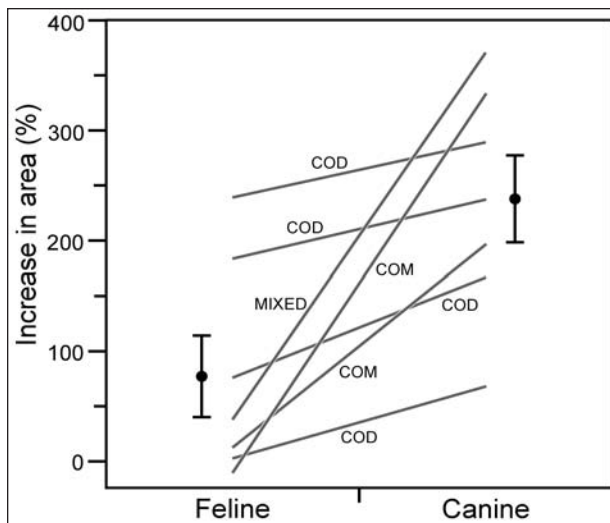


Figure 3—Comparison of the magnitude of increased area of digital images of fragments of paired canine and feline calcium oxalate uroliths after SWL (treatment with 100 shock waves). Each line represents a feline-canine pair of known composition; symbols and bars to the left and right of the plots represent the mean \pm SD increase in area (%) for feline and canine uroliths, respectively. Canine uroliths were fragmented more readily ($P < 0.02$) than were feline uroliths. COD = Calcium oxalate dihydrate. MIXED = Uroliths containing both COM and COD.

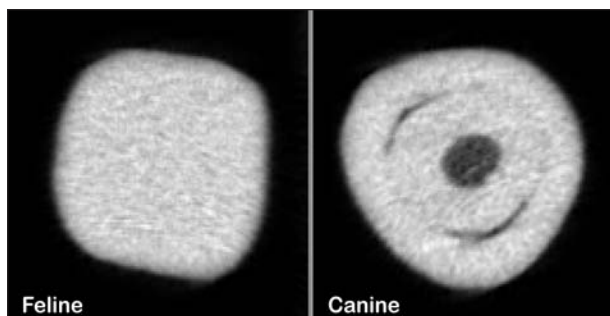


Figure 4—Micro-computed tomographic images (obtained before SWL) of paired COM uroliths (approx 2 mm in diameter) collected from a cat and a dog. Notice the x-ray lucent core and lamellar structure of the canine urolith. After treatment with 100 shock waves, the feline urolith did not break, whereas the canine urolith fragmented easily (results displayed in Figure 2).

in image area after fragmentation was $< 50\%$ in 4 of 7 feline uroliths, whereas the increase of image area after fragmentation was $> 150\%$ in 6 of 7 canine uroliths. In our paired-design study, feline uroliths were consistently more difficult to fragment than canine uroliths.

Comparison of the micro-CT images of the uroliths revealed that some canine uroliths had more internal structure (visible inhomogeneities) than the corresponding paired feline uroliths. Comparisons of the micro-CT images of the canine COM and COM-COD uroliths with those of their corresponding paired feline uroliths revealed that canine uroliths had more CT-visible internal structure, including obvious x-ray lucent regions or more obvious lamellar structure, than did the corresponding paired feline uroliths (Figure 4). Such structural differences were not apparent between the paired COD uroliths, and the micro-CT images of feline COD uroliths were indistinguishable from the corresponding canine COD uroliths.

Discussion

These in vitro data confirm the clinical observation that feline calcium oxalate uroliths are less susceptible to fragmentation via SWL than canine calcium oxalate uroliths. This has important clinical implications for treatment of nephroliths and ureteroliths in cats. At present, obstructive ureteroliths in cats are most often managed by use of microsurgical techniques with intensive pre- and postoperative care.¹⁰ Shock wave lithotripsy might be an alternative to surgical management of ureteroliths, provided that safe and effective protocols for SWL in cats can be established. The results of the present in vitro study suggest that SWL has been ineffective in some cats because feline calcium oxalate uroliths are more resistant to fragmentation than uroliths obtained from dogs. Therefore, for SWL treatment to be successful in cats, greater numbers of shock waves than have been used in successful treatment of uroliths in dogs would be required.

Although it was initially thought that clinical applications of SWL did not cause renal injury, results of recent studies¹¹⁻¹⁸ indicate that SWL does cause considerable renal injury, the severity of which is dependent on the number and voltage of the applied shock waves. The effects of shock wave treatment on renal function and structure in cats has only been studied in limited numbers of cats that received relatively low doses of shock waves. Gonzalez et al⁶ reported that exposure of the left kidneys of 4 adult, non-stone-bearing cats to shock waves generated by second-generation, dry lithotripter^d did not result in significant change in glomerular filtration rate (GFR). In that study, GFR was assessed before and 2 weeks after delivery of 2,000 to 2,400 shock waves (24 kV; 1 Hz) to only the left kidney of each cat. Renal ultrasonography performed 1 and 14 days after shock wave treatment did not reveal any morphologic changes in the treated kidneys, compared with the untreated kidneys. However, because many of the changes in renal function occur within the first hours after shock wave treatment,^{13,15,17} evaluation of GFR 14 days after shock wave treatment is not adequate to assess shock wave-induced changes in renal function in cats. Clinically relevant decreases in GFR could occur in the first 24 to 48 hours after shock wave therapy.

We previously evaluated the safety of shock wave treatment in 3 non-stone-bearing adult cats, using an unmodified, first-generation, waterbath-type lithotripter.⁵ Bilateral shock wave treatments resulted in functional and morphologic changes that were proportional to the number of shock waves administered to the kidney. After treatment of the left kidney (1,500 shock waves [14 kV; 2 Hz]) and right kidney (1,000 shock waves [14 kV; 2 Hz]) in each cat, mean GFR decreased by approximately 33% and 25% 1 and 4 days after shock wave treatment, respectively.⁵ Similarly, 3 of 5 stone-bearing cats that were treated by use of the same lithotripter had clinically relevant increases in serum creatinine concentration 12 to 24 hours after SWL.⁵ On the basis of the limited scope of these prior safety studies and the fact that feline calcium oxalate uroliths are more resistant to fragmentation via SWL,

additional studies are needed to establish the safety of shock wave treatment of the kidneys of cats, including the assessment of the effects on renal function and structure after treatment with high numbers of shock waves.

The greater fragility of canine uroliths, compared with feline uroliths, could be a result of microstructural differences. In the present study, such differences were detected between micro-CT images (obtained before SWL treatment) of some of the paired feline and canine uroliths; canine uroliths typically had an x-ray lucent core and obvious lamellation that was not detected in the paired feline uroliths. Such layering could facilitate establishment of internal fracture planes, resulting in greater shock wave-induced comminution of the canine uroliths. Computer modeling of shock wave propagation through laminated stones has determined that there is reflection of multiple tensile waves at the crystal-to-matrix boundaries.³ Reflected tensile waves may contribute to internal spalling damage and layer separation, which could account for greater comminution of laminated uroliths.³ Spalling refers to the fragmentation of uroliths via layer separation. However, although there were no obvious micro-CT differences between paired COD uroliths, canine COD uroliths were more easily fragmented than the feline COD uroliths in the present study. This observation prompts the question whether the difference in fragility between canine and feline uroliths might be attributable to differences in the organic matrix component of the uroliths of these 2 species.¹⁹ Further studies designed to detect differences in the organic matrix of canine and feline calcium oxalate uroliths are needed to answer this question. Such interspecies comparison, in which mineral type is not the determining factor, could provide a unique opportunity to investigate whether other features (eg, urolith structure or the composition of the organic matrix) play an important role in urolith fragility.

-
- a. Dornier HM3 lithotripter, Dornier, Marietta, Ga.
 - b. Scanco micro-CT 20 instrument, Scanco Medical AG, Bassersdorf, Switzerland.
 - c. Gonzales A, Labato MA, Solano M, et al. Evaluation of the safety of extracorporeal shock-wave lithotripsy in cats (abstr). *J Vet Intern Med* 2002;16:376.
 - d. Dornier MFL-5000, Dornier, Marietta, Ga.
-

References

1. Williams JC Jr, Saw KC, Paterson RF, et al. Variability of renal stone fragility in shock wave lithotripsy. *Urology* 2003;61:1092–1096.
2. Dretler SP. Special article: calculus breakability—fragility and durability. *J Endourol* 1994;8:1–3.
3. Zhong P, Preminger GM. Mechanisms of differing stone fragility in extracorporeal shockwave lithotripsy. *J Endourol* 1994;8:263–268.
4. Block G, Adams LG, Widmer WR, et al. Use of extracorporeal shock wave lithotripsy for treatment of spontaneous nephrolithiasis and ureterolithiasis in five dogs. *J Am Vet Med Assoc* 1996;208:531–536.
5. Adams LG, Senior DF. Electrohydraulic and extracorporeal shock-wave lithotripsy. *Vet Clin North Am Small Anim Pract* 1999;29:293–302.
6. Mueller CS, Wilbert D, Thueroff JW, et al. Extracorporeal shock wave lithotripsy of ureteral stones: clinical experience and experimental findings. *J Urol* 1986;135:831–834.
7. Paterson RF, Kim SC, Kuo RL, et al. Shock wave lithotripsy of stones implanted in the proximal ureter of the pig. *J Urol* 2005;173:1391–1394.
8. Pishchalnikov YA, Sapozhnikov OA, Bailey MR, et al. Cavitation bubble cluster activity in the breakage of kidney stones by lithotripter shockwaves. *J Endourol* 2003;17:435–446.
9. Zarse CA, McAteer JA, Tann M, et al. Helical computed tomography accurately reports urinary stone composition using attenuation values: in vitro verification using high-resolution micro-computed tomography calibrated to fourier transform infrared microspectroscopy. *Urology* 2004;63:828–833.
10. Kyles AE, Stone EA, Gookin J, et al. Diagnosis and surgical management of obstructive ureteral calculi in cats: 11 cases (1993–1996). *J Am Vet Med Assoc* 1998;213:1150–1156.
11. Newman R, Hackett R, Senior D, et al. Pathologic effects of ESWL on canine renal tissue. *Urology* 1987;29:194–200.
12. Blomgren PM, Connors BA, Lingeman JE, et al. Quantitation of shock wave lithotripsy-induced lesion in small and large pig kidneys. *Anat Rec* 1997;249:341–348.
13. Connors BA, Evan AP, Willis LR, et al. The effect of discharge voltage on renal injury and impairment caused by lithotripsy in the pig. *J Am Soc Nephrol* 2000;11:310–318.
14. Evan AP, Willis LR, Lingeman JE, et al. Renal trauma and the risk of long-term complications in shock wave lithotripsy. *Nephron* 1998;78:1–8.
15. Evan AP, Willis LR, Connors B, et al. Shock wave lithotripsy-induced renal injury. *Am J Kidney Dis* 1991;17:445–450.
16. Shao Y, Connors BA, Evan AP, et al. Morphological changes induced in the pig kidney by extracorporeal shock wave lithotripsy: nephron injury. *Anat Rec* 2003;275A:979–989.
17. Willis LR, Evan AP, Connors BA, et al. Effects of extracorporeal shock wave lithotripsy to one kidney on bilateral glomerular filtration rate and PAH clearance in minipigs. *J Urol* 1996;156:1502–1506.
18. Willis LR, Evan AP, Connors BA, et al. Relationship between kidney size, renal injury, and renal impairment induced by shock wave lithotripsy. *J Am Soc Nephrol* 1999;10:1753–1762.
19. Escolar E, Bellanato J. Analysis of feline urinary calculi and urethral plugs by infrared spectroscopy and scanning electron microscopy. *Vet Rec* 2003;152:625–628.