

# Experimental induction of bacterial gastritis and gastric ulcer disease in gnotobiotic swine inoculated with porcine *Helicobacter*-like species

Steven Krakowka, DVM, PhD; D. Michael Rings, DVM, MS; John A. Ellis, DVM, PhD

**Objective**—To determine whether 2 isolates of recently isolated swine-origin *Helicobacter pylori*-like bacteria are pathogenic in pigs and compare the signs of gastric disease induced by these isolates with those detected in *H pylori*- and *Helicobacter heilmannii*-infected pigs.

**Animals**—36 neonatal gnotobiotic pigs.

**Procedure**—Groups of separately housed pigs were inoculated orally with swine-origin *Helicobacter*-like isolates 2662 or 1268, *H pylori* (human gastric pathogen), or a gastric homogenate from gnotobiotic swine containing *H heilmannii*. Noninoculated pigs were used as control animals. Clinical signs and development of homologous and heterologous antibodies against *Helicobacter* organisms were assessed. After euthanasia, gastric tissues were examined grossly and microscopically; *Helicobacter* organisms were detected by use of Warthin-Starry and immunohistochemical stains.

**Results**—Both porcine *Helicobacter*-like isolates colonized the stomachs of swine. Isolate 2662 was highly pathogenic; in 13 isolate 2662-inoculated pigs, gastroesophageal ulcerations developed in 9 and ulceration of the gastric glandular mucosa was detected in 5. Histologically, inflammatory gastritis consisting of multifocal to diffuse lymphocytic and plasmacytic cellular infiltrates and lymphoid follicle formation in the gastric lamina propria accompanied bacterial colonization of the gastric compartment. In contrast, *H heilmannii* was minimally pathogenic in that only modest inflammatory cell infiltrates were seen. Gastroesophageal or mucosal ulcers were not evident in pigs inoculated with *H heilmannii*.

**Conclusions and Clinical Relevance**—These data indicate that swine-origin *H pylori*-like bacteria can be pathogenic in pigs and suggest that porcine gastric disease may be mediated, in part, by colonization of the stomach by swine-origin *H pylori*-like bacteria. (*Am J Vet Res* 2005;66:945–952)

*Helicobacter pylori* is a primary gastric pathogen in humans<sup>1</sup> and causes what is often described as the most prevalent infectious disease in the world; the

Received November 10, 2004.

Accepted January 10, 2005.

From the Departments of Veterinary Biosciences (Krakowka) and Veterinary Clinical Sciences (Rings), College of Veterinary Medicine, The Ohio State University, Columbus, OH 43210; and the Department of Veterinary Microbiology, College of Veterinary Medicine, University of Saskatchewan, Saskatoon, SK S7N 5B4, Canada (Ellis).

Supported in part by Capricorn Research and Development.

The authors thank Judith Dubena, Amy Davis, Susan Ringler, Michelle Newkirk, and Carrie Rhodes for technical assistance.

Address correspondence to Dr. Ellis.

organism was first identified in 1984 from patients with a clinical diagnosis of gastritis.<sup>2</sup> Prior to this, the stomach was widely regarded as an inhospitable environment for microbial colonization and the possibility that gastroduodenal ulcer disease was a manifestation of gastric bacterial infection was not entertained. Today, it is beyond dispute that *H pylori* is the etiologic agent of chronic superficial (active) type B gastritis<sup>3-7</sup> and non-steroidal anti-inflammatory drug-independent gastroduodenal ulcer disease.<sup>1,5,8-10</sup> Development of intestinal-type gastric carcinoma<sup>11-14</sup> and lymphoma of the gastric mucosa-associated lymphoid tissue<sup>15-17</sup> is strongly associated with *H pylori* infections. As well, atrophic gastritis and resultant achlorhydria in humans are now thought to represent the last stages in the progression of persistent lifelong colonization by *H pylori*.<sup>9</sup> Almost 20% of the US population < 20 years of age is infected with *H pylori*; this proportion reaches 50% by 60 years of age.<sup>1</sup> *Helicobacter pylori* is a gram-negative, microaerophilic, urease-positive, small, curved rod-shaped bacterium that possesses several unusual characteristics related to its gastric ecological niche. The hallmark for the members of the *Helicobacter* genus is expression of urease enzyme; the presence of this enzyme and its activity in the hydrolysis of urea form the basis of presumptive tests (eg, the urea breath test and others) for gastric colonization. The organism colonizes the layer of mucus in the cardiac and antral portions of the stomach, and infection is presumed to be lifelong.

Early attempts to reproduce disease with *H pylori* were frustrated because commonly used laboratory animal species were found to be highly resistant to gastric colonization with *H pylori*. Experimental models of *H pylori*-induced gastritis in animals have since been developed.<sup>18-25</sup> Prominent among these is the use of young gnotobiotic pigs for investigation of acute bacterial gastritis.<sup>18</sup> Gnotobiotic pigs are monogastric omnivores with gastric anatomic and physiologic features that most closely resemble those of humans<sup>26,27</sup>; moreover, these pigs are susceptible to colonization with many different *H pylori* strains via oral inoculation.<sup>18,26,27</sup> Lewis antigenic arrays expressed on human mucoproteins and cell-surface glycoproteins are thought to be binding receptors for *H pylori* bacterial lipopolysaccharide and other surface glycoproteins.<sup>28</sup> Unlike gastric tissues of other laboratory animal species except primates, gastric tissues of pigs are Lewis antigen-positive,<sup>29</sup> a finding that provides a convenient explanation for the ease of colonization by *Helicobacter heilmannii* in these animals.

Of the domestic animal species, swine are the most commonly affected with clinically important gastric

ulcers.<sup>30,31</sup> That *Helicobacter*-like bacterial infections are contributors to gastric disease in pigs, including ulceration of the gastric pars esophagea (or **gastroesophageal ulceration** [GEU]), is an attractive hypothesis and is plausible given the known effects of *H pylori* infection in humans and the gastric similarities between these 2 species. In modern intensive production systems, the development of ulcers and erosions of the nonglandular esophageal (cardiac) gastric lining and antral gastric mucosa is a common and serious disease problem in pigs.<sup>30</sup> The reported prevalence of GEU in pigs is 5% to 100%, and death losses from gastric hemorrhages may be as high as 3% or more<sup>30,31</sup>; sublethal economic losses are also substantial. In pigs, ulceration of the gastric pars esophagea and mucosa is attributed to reflux of acidic gastric contents onto the unprotected pars esophagea.<sup>32,33</sup> Development of excessive gastric acid content is multifactorial and thought to be largely due to a combination of an excess production of hydrochloric acid by parietal cells and luminal hydrolysis of luminal carbohydrate, both coupled with a loss of pH gradient in the stomachs of swine fed a finely ground, low-roughage, high-carbohydrate diet. There is the widespread, albeit undocumented, belief that social stress associated with close confinement and exposure to other infectious diseases and airborne pollutants (eg, dust and ammonia), particularly when combined with genetic selection for pigs with accelerated body growth and lean body phenotypes, promotes ulcerogenesis in pigs.<sup>30</sup> Objective proof for this belief has been difficult to obtain. Under current intensive swine production operations, any or all of these mechanisms of stress and gastric hyperacidity may be contributing factors.

An infective bacterial component to porcine ulcer disease and GEU was first suggested in reports<sup>34-37</sup> that associated gastric *Gastrospirillum* (*Helicobacter*)-like organisms, initially named *Gastrospirillum suis* and subsequently renamed *H heilmannii*, with a high incidence of ulcer disease in swine in slaughterhouses. Similar or identical microbes are commonly found in other carnivores such as dogs,<sup>38-40</sup> cats,<sup>41-43</sup> and cheetahs.<sup>44,45</sup>

Experimental pathogenesis studies<sup>46,47</sup> involving *H heilmannii* in target species are hampered by the fact that this agent is not ordinarily amenable to culture in artificial media. Results of recent work have confirmed the high incidence of *H heilmannii* in swine,<sup>37</sup> and some investigators have associated *H heilmannii* colonization with development of porcine GEU.<sup>35-37,48</sup> However, attempts to reproduce porcine GEU and mucosal ulcer disease with murine-passaged *H heilmannii* were unsuccessful.<sup>49</sup> Furthermore, the gastric niche for *H heilmannii* appears to be predominately the gastric pits and parietal cells of the acid-secreting gastric fundus, both uncommon sites of ulceration in swine. Moreover, most swine that are colonized by *H heilmannii* are ulcer-free, suggesting that the contribution of *H heilmannii* to the development of porcine gastric ulcer disease is indirect at best.

Previously, we reported<sup>50</sup> the recovery of 2 isolates of *Helicobacter*-like bacteria that were morphologically and antigenically distinct from *H heilmannii* from the

gastric mucosa of swine. The purposes of the present study were to determine whether these 2 isolates of *Helicobacter*-like bacteria are pathogenic in pigs and compare the signs of gastric disease induced by these isolates with signs that develop in *H pylori*- and *H heilmannii*-infected pigs.

## Materials and Methods

**Gnotobiotic swine**—Thirty-six gnotobiotic neonatal pigs from portions of 7 litters were used in this study.<sup>27</sup> In brief, pigs were derived from 7 sows purchased from a local pork producer. After epidural administration of lidocaine (20 mL of a 2% solution), a Cesarean section was performed on each sow and the gravid uterus was exteriorized, severed from its abdominal attachments, and placed into a transfer tank filled with chlorine disinfectant. The sows were immediately euthanized via electrical stunning (transcranial route) and exsanguination. Piglets were removed from each uterus and stimulated to breathe; after resection of the umbilici, the neonates were transferred into sterile pen-tub isolation units containing 6 separate partitions. The pigs were fed a sows' milk replacement diet and infant formula fortified with iron 3 to 4 times daily until they were euthanized by use of an IV injection of sodium barbital solution at 35 days of age. Animals were maintained in accordance with The Ohio State University Institutional Animal Care and Use Committee approval of the specific protocol for this study.

**Bacterial inocula**—Pure cultures of *H heilmannii* were obtained from parietal cell suspensions initially obtained from *H heilmannii*-infected nude mice, as described.<sup>51</sup> In brief, *H heilmannii* was separated from other bacterial species and microbial contaminants through exploitation of the affinity of this bacterium for the canalicular system of parietal cells. Isolated parietal cells were frozen in aliquots as starting material. The *H heilmannii* isolate was passaged twice in gnotobiotic mice by use of *H heilmannii*-laden gastric homogenates (confirmed by examination of Warthin-Starry-stained cytospin preparations of the homogenates). A single passage of *H heilmannii* was performed in 2 gnotobiotic pigs, and the infective inoculum was maintained by further passages of infected porcine gastric homogenates (10% [wt/vol]) in 2 gnotobiotic pigs. The infective homogenate was divided into 2-mL volumes and frozen (−70°C) until used for in vivo studies.

Pure cultures (fourth passage and beyond) of porcine *Helicobacter*-like isolates 1268 and 2662 were recovered from 2 young conventionally raised swine, as described.<sup>50</sup> For in vivo inoculations, isolates were expanded in *Brucella* broth. At 3 days of age, 10<sup>9</sup> organisms (2-mL volume) recovered during log-phase growth were orally administered to each pig. As infection controls, 9 gnotobiotic pigs were each orally administered 2 mL of *Brucella* broth containing *H pylori* strain 26695 adapted for optimal growth in swine<sup>52</sup> and similarly prepared. Uninfected control pigs received either *Brucella* broth alone or were not inoculated. To exclude inadvertent contamination among inoculation groups, each group was separately housed in gnotobiotic isolation units. The distribution of pigs by bacterial inoculation group was as follows: 13 pigs from 4 different litters were orally inoculated with isolate 2662 at 3 days of age, 5 pigs from 1 litter were inoculated orally with isolate 1268 at 3 days of age, 6 pigs from 1 litter were inoculated orally with *H heilmannii*-containing gastric homogenates at 5 (n = 3) or 21 days of age (3), 9 pigs from 4 litters were inoculated orally with *H pylori* strain 26695 at 3 days of age, and 3 pigs from 2 litters were used as uninfected controls.

**Assessment of pathologic changes**—After euthanasia, a standardized procedure for collection and evaluation of gas-

tric tissues from pigs was used. Food was withheld from pigs for 12 hours and they were heavily sedated by use of ketamine HCl (1.0 mL [20 mg/kg], IM) prior to removal from the isolation units. After collection of a blood sample to provide serum, the pigs were euthanized by use of an IV injection of 2.0 mL of sodium barbital (100 mg/kg). The stomach of each pig was exteriorized; after ligation of the esophagus and proximal portion of the duodenum, the stomach and its contents was removed. The stomachs were aseptically opened by dissection along the greater and lesser curvatures, and half of each stomach was excised for quantitative microbial culture of the gastric mucosa. Pertinent gross findings in the remaining half of the stomach (ie, subjective assessments of submucosal edema, amount of luminal mucus, presence and extent of lymphoid follicles, and erosions or ulcers if present) were recorded by one of the investigators (SK), and photographs of ulcerative lesions, if present, were obtained (SK). In the absence of ulcers, sections of the cardiac portion of the stomach (including the pars esophagea), fundus, antrum, and the region of the pylorus and proximal portion of the duodenum were collected for microscopic evaluation. Suspected ulcerative and erosive lesions in the pars esophagea and gastric mucosa were transected such that the surface containing the ulcers or erosions was available for microtome sectioning from the face of the paraffin section blocks. Gastric samples were immersed in 10 volumes of 10% phosphate-buffered formalin for at least 24 hours prior to further processing. Formalin-fixed gastric mucosa samples were dehydrated in graded alcohols, processed for histologic evaluation, and embedded in paraffin blocks by standard methods. Five-micrometer section replicates were stained with H&E for morphologic evaluation, Warthin-Starry stains to detect organisms, and commercial rabbit anti-*H pylori*-specific antisera<sup>a</sup> via indirect immunohistochemical processes, essentially as described.<sup>53</sup> To assess antigenic relationships recognized by infection-induced immune T cells, both 24- and 48-hour ID skin tests were performed via ID inoculation of 10 µg of either *H pylori* or isolate 2662 sonicates in 100 µL of saline (0.9% NaCl) solution into the external aspect of the pinna (ear) of some of the pigs, 24 to 48 hours prior to euthanasia.

**Microbiologic assessments**—After derivation of germfree litters and at intervals thereafter until pigs were euthanized, isolation units were screened for extraneous microbial contaminants via aerobic and anaerobic microbial culture of swabs from feed pans, feces, and isolation units. Bacterial contaminants were not identified. For preparation of inocula, organisms were cultured in *Brucella* broth (2.8% [wt/vol]) with fetal calf serum (10% [vol/vol]) and harvested in the log-phase growth. Bacterial enumeration was accomplished by use of a hemocytometer, and counts were adjusted to 10<sup>8</sup> microbes/2 mL/pig. Assays for bacterial urease, catalase, and oxidase activities and motility were performed as described.<sup>18,27</sup> For quantitative determination of the number of bacterial CFUs per gram of gastric mucosa in inoculated pigs, the mucosa was separated from the underlying tunica muscularis in tissue samples, weighed, and homogenized in 10% (wt/vol) *Brucella* broth; 10-fold dilutions were plated in duplicate onto blood agar plates, which were examined after 4 days' incubation at 37°C and 95% humidity in an atmosphere of 10% carbon dioxide, 5% oxygen, and 85% nitrogen. In addition to stomach mucosa, multiple areas of the gastrointestinal tract were also cultured for organisms in 5 of the piglets inoculated with isolate 2662. Porcine reisolates were identified as *Helicobacter* spp on the basis of gram-staining properties, morphologic features of colonies, urease and catalase enzyme activities, and immunoreactivity with both monospecific antisera against *H pylori* collected from infected gnotobiotic swine and commercially available *H pylori*-specific rabbit antisera.

**Assessment of serum antibody responses by ELISA**—Microtiter plate ELISAs were constructed by use of *H pylori* sonicates and *Helicobacter*-like isolates 1268 and 2662 (100 to 500 µg of bacterial sonicates in basic bicarbonate coating buffer [pH, 9.0]) as antigen, essentially as described.<sup>27</sup>

## Results

**Clinical signs**—An occasional transient (24-hour) episode of anorexia has been detected in some *H pylori*-infected gnotobiotic swine,<sup>18,27</sup> and there were similar findings in 2 of 13 pigs inoculated with isolate 2662 in the present study. This was determined chiefly through the presence or absence of a liquid diet in the feeding pans at the time of subsequent feedings; the residual amount of feed never exceeded 20% of the original volume. Among the pigs that became transiently anorexic, there was no apparent relationship between this clinical sign and the experimental group or day after inoculation. Uninfected control pigs maintained a normal appetite throughout the study. Aside from this transient anorexia, inoculation of gnotobiotic swine with porcine *Helicobacter* spp was clinically inapparent and no overt differences in size, weight, or demeanor were noted among inoculated pigs and uninfected control animals.

**Gross findings**—Gross lesions of gastric disease (GEU, glandular mucosal ulcers, lymphoid follicles [particularly along the lesser curvature of the stomach], excess luminal mucus, and mucosal edema) typical of infection with *Helicobacter* organisms in gnotobiotic pigs<sup>18,27,49,54</sup> were detected in most of the isolate 2662-inoculated and *H pylori*-inoculated gnotobiotics (Table 1). Ulceration of the pars esophagea was identified in 9 of 13 pigs inoculated with isolate 2662 (Figure 1); similar ulceration was identified in 5 of 9 piglets inoculated with *H pylori* and 2 of 5 piglets inoculated with isolate 1268. None of the 6 *H heilmannii*-inoculated or the 3 uninfected control pigs developed GEU. In addition, small ulcers of the glandular gastric mucosa were detected in 1 of 5 isolate 1268-inoculated and 4 of 13 isolate 2662-inoculated pigs (Figure 2). No ulcers of the glandular gastric mucosa were detected in the control, *H pylori*-inoculated, and *H heilmannii*-inoculated pigs. Ulcers varied in size from microscopic to approximately 0.5 cm and involved from 10% to 50% of the pars esophagea. Enlargement of gastric lymph nodes was detected in many of the *Helicobacter* spp-inoculated pigs as well.

**Histologic findings**—Histologic findings confirmed that the GEU detected in the isolate 2662- and *H pylori*-inoculated pigs was erosive and ulcerative in nature (Figure 3). With the exception of 1 isolate 1268-inoculated pig, penetrating ulcers of the gastric glandular mucosa were identified histologically only in pigs that had been orally inoculated with isolate 2662. In addition to gastric mucosal ulcers, microulceration of the proximal portion of the duodenum was detected in 1 isolate 2662-inoculated pig (Figure 4). Signs of gastric inflammation (eg, presence of lymphocytic and plasmacytic inflammatory cell infiltrates and mucosal lymphoid follicle formation) were most prominent in isolate 2662-inoculated pigs. These inflammatory

Table 1—Pathologic and microbiologic findings (number of pigs with finding/number of pigs examined) in 36 young gnotobiotic pigs inoculated with swine-origin *Helicobacter*-like gastric isolates 2662 or 1268,<sup>50</sup> *Helicobacter heilmannii*, or *Helicobacter pylori* strain 26695, compared with findings in uninfected control pigs.

Finding	Inoculation group				Uninfected control pigs(3)
	Isolate 2662 (n = 13)	Isolate 1268 (5)	<i>H pylori</i> (9)	<i>H heilmannii</i> (6)	
Grossly evident mucosal ulcers	4/13	1/5	0/9	0/6	0/3
Grossly or histologically evident gastroesophageal ulceration*	9/13	2/5	5/9	0/6	0/3
Histologically evident mucosal microulcer	5/13	1/5	0/9	0/6	0/3
Lymphocytic-plasmacytic mucosal inflammation	13/13	2/5	8/9	5/6	1/3†
Lymphoid follicles in the antrum and lesser curvature of the stomach	13/13	0/5	6/9	2/6	0/3
<i>Helicobacter</i> organisms obtained via culture and isolation (No. or range of bacterial CFUs/g of gastric mucosa)	13/13 ( $< 10^3$ to $6.6 \times 10^6$ )	1/5 ( $< 10^2$ )	3/3 ( $3.0 \times 10^4$ to $> 6.0 \times 10^6$ )	ND	0/3
<i>Helicobacter</i> organisms detected in gastric tissues by use of Warthin-Starry stain	12/13	0/5	ND	6/6	0/3
<i>Helicobacter</i> organisms detected immunohistochemically in gastric tissues	9/9	2/5	ND	3/3	ND
Seroconversion against <i>H pylori</i> detected via ELISA	13/13	0/5	ND	0/6	0/3
Detectable response to <i>H pylori</i> in an ID skin test	4/5	4/5	7/9	ND	0/3
Detectable response to isolate 2662 in an ID skin test	4/5	ND	ND	5/6	ND

Not all pigs in each group were examined for each finding.  
 \*Specifically, ulceration of the pars esophagea. †Focal lymphocytic inflammatory cell infiltrates were detected in the cardiac portion of the stomach of 1 piglet in this group.  
 ND = Not done.

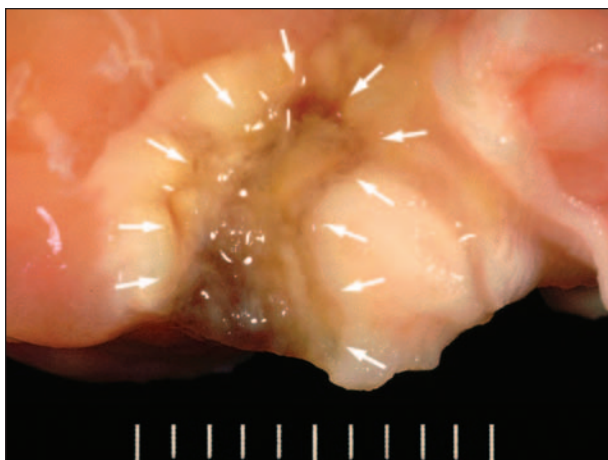

Figure 1—Photograph of the gross appearance of ulceration of the pars esophagea in a gnotobiotic pig inoculated 32 days previously with *Helicobacter*-like isolate 2662.<sup>50</sup> The margins of the ulcer crater are delineated by white arrows. Scale = 2 cm.

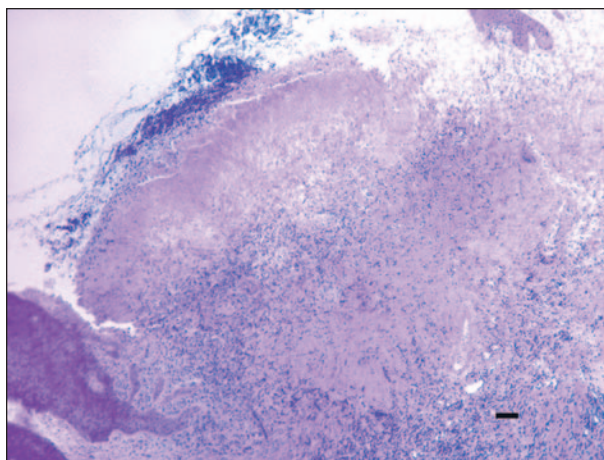


Figure 2—Photomicrograph of a section of the nonglandular pars esophagea of a gnotobiotic pig inoculated 32 days previously with *Helicobacter*-like isolate 2662. Notice the erosive and ulcerative lesion in the mucosa. A portion of unaffected lining epithelium of the pars esophagea is included at the left of the photomicrograph. H&E stain; bar = 70  $\mu$ m.

lesions were most noticeable in the lesser curvature of the stomach near the nonglandular cardiac portion of the stomach, in the antral mucosa, anterior to the gastric pylorus, and distal to the fundus (Figure 5). Pigs inoculated with either isolate 1268 or *H heilmannii* had minimal evidence of inflammation in the gastric mucosa; only 2 of 5 isolate 1268-inoculated pigs had any inflammatory cell infiltrates, and none of these pigs had lymphoid follicles. Gastric lymph nodes from many of the isolate 2662- and *H pylori*-inoculated pigs were highly cellular and had developing lymphoid follicles suggestive of an induced local immune or inflammatory response in the stomachs of these animals.

Examination of the remaining tissues revealed no remarkable findings.

**Microbiologic and immunologic assessments—** All 13 pigs inoculated with isolate 2662 and 3 of 9 pigs inoculated with *H pylori* were used for quantitative recovery of bacteria. In the isolate 2662-inoculated pigs, the level of infection varied from recovery after restreaking (approx equivalent to  $10^3$  bacterial CFUs/g) to  $> 6 \times 10^6$  bacterial CFUs/g. There was no apparent association between the amount of bacteria isolated and either the size or number of ulcers. *Helicobacter-*

like bacteria were recovered from 1 of 5 pigs inoculated with isolate 1268 and from none of the control pigs. No attempt was made to recover *H heilmannii* from the *H heilmannii*-inoculated swine.

Use of the Warthin-Starry stain on tissue sections confirmed gastric infection with *Helicobacter* organisms in the *Helicobacter*-inoculated pigs. Organisms that had morphologic features consistent with those of *H pylori* (ie, small curved rods with occasional gull-wing replicative forms) were identified extracellularly in gastric tissues from 12 of 13 pigs inoculated with isolate 2662 but not in tissues from isolate 1268-inoculated pigs (Figure 6). In the former, bacteria were most abundant in the cardiac portion of the stomach (adjacent to the pars esophagea), the lesser curvature of the stomach, and the gastric antrum; organisms were scarce or nonexistent in the fundus. Tissues from all 6 pigs inoculated with *H heilmannii* contained Warthin-Starry-stained microbes. *Helicobacter heilmannii* were easily distinguished from *H pylori* or isolate 2662 by their size (3-fold longer) and unique spiral appearance.

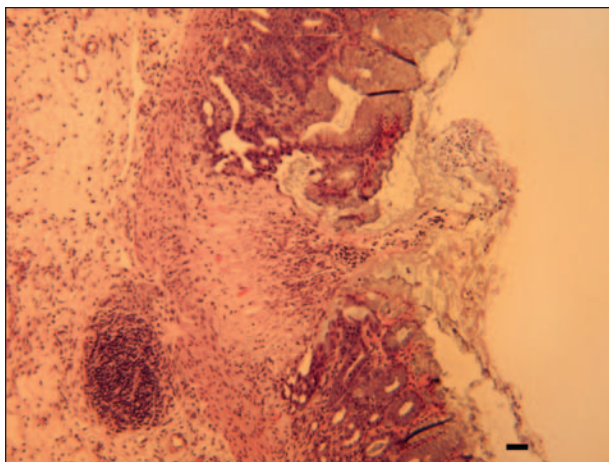


Figure 3—Photomicrograph of a section of the cardiac portion of the stomach of a gnotobiotic pig inoculated 32 days previously with *Helicobacter*-like isolate 1268.<sup>30</sup> Notice the presence of a microulcer in the mucosa. H&E stain; bar = 35  $\mu$ m.

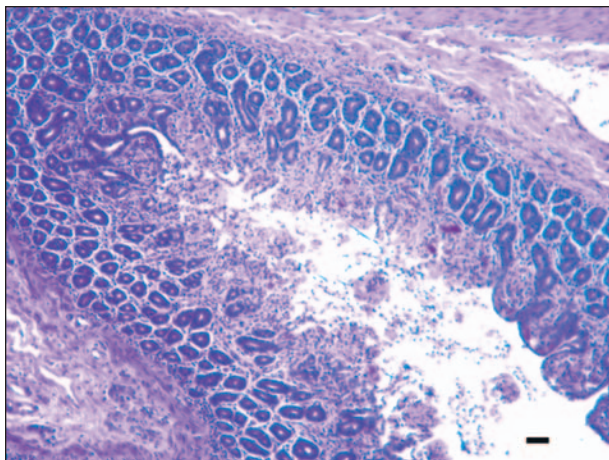


Figure 4—Photomicrograph of a section of the proximal portion of the duodenum in a gnotobiotic piglet inoculated 32 days previously with *Helicobacter*-like isolate 2662. Notice the presence of a microulcer and the blunting and fusion of the duodenal villi. H&E stain; bar = 70  $\mu$ m.

Although some *H heilmannii* microbes were located in the cardiac portion of the stomach, most were in the gastric pits of the fundus. Immunostaining for *Helicobacter* organisms yielded positive results when replicate sections of gastric tissues from isolate 2662-inoculated pigs were stained with rabbit anti-*H pylori* antiserum in an immunohistochemical assay (Figure 7). Bacteria that reacted with this reagent were identified in gastric sections from 9 of 9 pigs inoculated with isolate 2662, 2 of 5 pigs inoculated with isolate 1268, and 3 of 3 from pigs inoculated with *H heilmannii*. These reagents reacted weakly with isolate 1268 and strongly with the other microbes. Compared with results of microbial culture and reisolation, both the Warthin-Starry staining method and immunohistochemical assay were insensitive techniques for identification of *Helicobacter*-like bacteria in porcine tissues; gastric tissues from stomachs that contained  $< 10^6$  recoverable bacterial CFUs/g were frequently identified as negative for the bacteria by use of those techniques.<sup>27</sup>

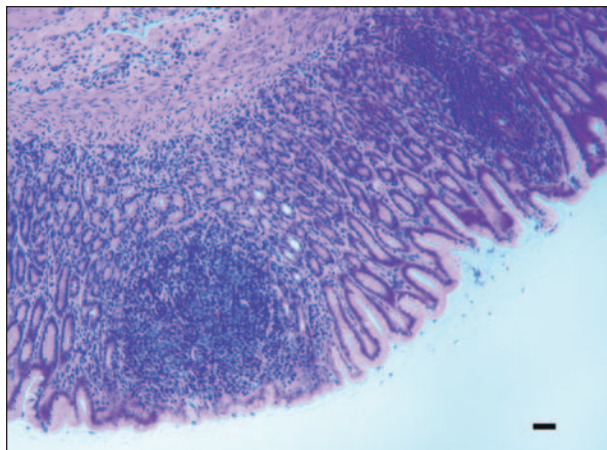


Figure 5—Photomicrograph of a section of the gastric antral mucosa of a gnotobiotic pig inoculated 32 days previously with *Helicobacter*-like isolate 2662. Notice the gastric inflammation-associated lymphoid follicles that are contained within the mucosa and not obviously associated with draining lymphatics. H&E stain; bar = 35  $\mu$ m.

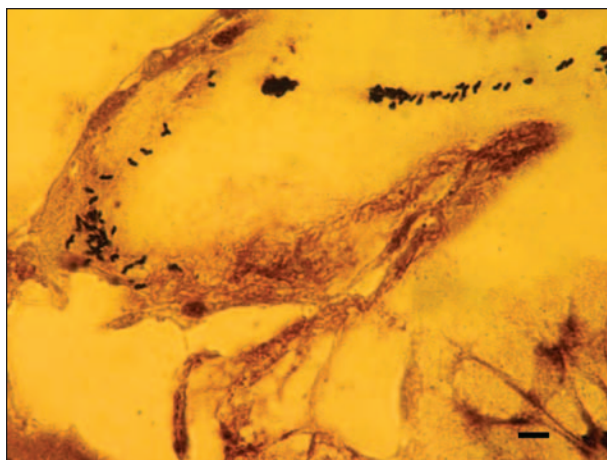


Figure 6—Photomicrograph illustrating the morphologic appearance of *Helicobacter*-like isolate 2662 in the mucus layer of the gastric antral mucosa from the stomach of a gnotobiotic piglet inoculated 32 days previously with that isolate. Warthin-Starry silver stain; bar = 14  $\mu$ m.

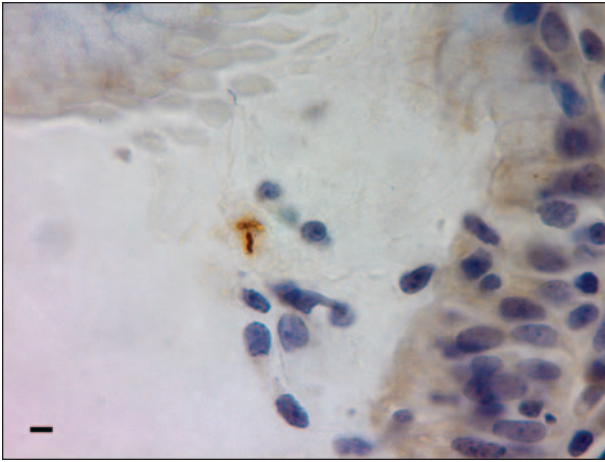


Figure 7—Photomicrograph illustrating the reaction of *Helicobacter*-like isolate 2662 with rabbit *Helicobacter pylori*-specific polyclonal antisera in an antral mucosal section from the stomach of a gnotobiotic pig inoculated 32 days previously with isolate 2662. Immunohistochemical staining was developed with horseradish peroxidase-conjugated goat anti-rabbit IgG and 3,3',5,5'-tetramethylbenzidine. Bar = 7  $\mu$ m.

In 5 of the isolate 2662-inoculated gnotobiotics, microbial culture and reisolation of the organisms were also performed in tissue samples collected from throughout the gastrointestinal tract (esophagus to rectum). Trace amounts of isolate 2662 were recovered in the proximal portion of the duodenum of 2 of these 5 pigs and in the ileum and jejunum of 1 of the 5 pigs; there were no histologic lesions in these tissues (data not shown). Trace amounts of *Helicobacter*-like organisms were recovered via microbial culture from only 1 of 5 isolate 1268-inoculated pigs; this pig had GEU but no gastric mucosal ulcers. Because *H heilmannii* is not amenable to culture on artificial media, we relied on examination of tissue sections stained with Warthin-Starry stain to confirm gastric colonization with this agent.

Sera obtained from all pigs immediately prior to euthanasia were evaluated for homologous and heterologous antibodies against the *Helicobacter* spp via ELISAs. All serum samples from the 13 isolate 2668-inoculated pigs reacted to both *H pylori* and isolate 2668 antigens, whereas none of the serum samples from *H heilmannii*- and isolate 1268-inoculated pigs reacted with these same antigens. Convalescent sera from isolate 1268-inoculated pigs reacted only with isolate 1268-origin ELISA antigen.

A subset of pigs from each inoculation group was evaluated via ID skin tests involving ID inoculation of 10 mg of either *H pylori* or isolate 2662 sonicates into the external aspect of the ear, 24 or 48 hours prior to euthanasia. In ID skin tests involving *H pylori* sonicates, histologic evaluation of skin test sites revealed dermal delayed-type hypersensitivity responses to skin test antigens in 4 of 5 pigs inoculated with isolate 2662, 4 of 5 pigs inoculated with isolate 1268, and 7 of 9 pigs inoculated with *H pylori*. The dermis and subcutaneous tissues contained mononuclear cell infiltrates with a scattering of neutrophils and eosinophils typical of delayed-type hypersensitivity responses to bacterial proteins (Figure 6). The same 4 pigs inocu-

lated with isolate 2662 also responded to isolate 2662 sonicates, as did 5 of 6 pigs inoculated with *H heilmannii* (Table 1). There was no observable histologic difference between ID skin test sites when either source of bacterial sonicate was used.

## Discussion

The objective of the present study was to assess the pathogenic potential of swine-origin *Helicobacter*-like isolates in gnotobiotic pigs and compare the signs of gastric disease induced by these isolates with clinical signs that develop in *H pylori*- and *H heilmannii*-inoculated gnotobiotics. Of the 2 isolates, our data indicate that isolate 2662 is more pathogenic. As described,<sup>50</sup> isolate 2662 is similar to human-origin *H pylori*. Compared with the other inoculation groups, a greater proportion of pigs inoculated with isolate 2662 had erosions and ulcers of the gastric pars esophagea; in this group, 9 of 13 pigs had GEU, compared with 5 of 9 pigs inoculated with *H pylori*, 2 of 5 pigs inoculated with isolate 1268, and 0 of 3 pigs inoculated with *H heilmannii*. However, the incidence of ulceration in the glandular mucosa was more important. Although *H pylori* will cause mucosal ulcers on occasion,<sup>54</sup> mucosal ulcers were detected in 5 of 13 pigs inoculated with isolate 2662 in the present study. In addition, an ulcer in the proximal portion of the duodenum was detected in one of the pigs in this inoculation group. This incidence of true gastric mucosal ulceration was unexpected and exceeds that associated with *H pylori* (a known human and porcine gastric ulcerogen) in either humans<sup>1</sup> or swine.<sup>54</sup> It is noteworthy that *H heilmannii*, a microbe associated with the development of GEU and ulcer disease in pigs by other investigators,<sup>35-37,48,54</sup> induced neither GEU nor gastric mucosal ulceration in pigs inoculated with this agent in the present study.

In *H pylori* infection in both humans and gnotobiotic swine,<sup>8,10,18,27,55,56</sup> the developing inflammatory response in the gastric mucosa to gastric bacterial colonization is predominately lymphocytic with well-developed lymphoid follicles in the antral and cardiac portions of the stomach. These gastric inflammatory lesions are distinct from the porcine Peyer's patchlike structures previously identified in porcine gastric cardiac mucosa.<sup>55</sup> Gastric mucosal neutrophilic infiltrates, either in the mucosa or within the gastric pits, were not seen in isolate 2662-inoculated piglets. Although it was not quantitated in the present study, the intensity of the inflammation in the cardiac and antral portions of the stomach was most evident in pigs inoculated with isolate 2662 and least evident in the pigs inoculated with isolate 1268. As reported previously,<sup>49</sup> *H heilmannii*-associated nonsuppurative inflammation is modest in gnotobiotics infected with that agent alone. Also, as detected in *H pylori* infection in humans and in infected gnotobiotic pigs transferred from isolation units into a conventional environment,<sup>26,27</sup> gastric infection with *Helicobacter* organisms appears to be persistent despite the development of vigorous antibody and T-cell-mediated responses to bacterial antigens.

The role of the *Helicobacter*-like isolates in the pathogenesis of GEU in conventionally reared pigs has not yet been defined. Our data suggest that gastric col-

onization with *Helicobacter*-like gastric microbes may be a critical factor in the initiation of gastric ulcer disease in pigs. From this assumption, it follows that GEU in pigs may actually be an infectious bacterial disease, rather than a disease caused by consumption of high-carbohydrate diets or modern swine production methods. An unpublished ELISA serologic survey performed by our group, in which > 1,000 serum samples from conventionally reared pigs (weanling to adult stages) were evaluated, revealed that pigs begin the process of seroconversion against isolate 2662 antigens at 5 to 6 weeks of age; by adulthood, > 80% of the pigs have IgG-isotype antibodies against *H pylori* and isolate 2662, as determined via an ELISA. Although it is possible that this high incidence of infection could be due, in part, to colonization and subsequent cross-reactivity with *H heilmannii*, it is noteworthy that no sera from the gnotobiotic pigs inoculated with *H heilmannii* in the present study reacted in ELISAs to *H pylori* and isolate 2662 antigens, even when these sera were tested for activity by use of IgM isotype-specific secondary reagents.<sup>50</sup> In that study,<sup>50</sup> 2 faint bands were distinguished via western blot immunoassays when convalescent sera from *H heilmannii*-inoculated pigs were tested against *H pylori* and isolate 2662.

The contributions of diet to the pathogenesis of GEU in pigs are undeniable.<sup>30,33</sup> The evidence for gastric luminal acid-mediated damage of the pars esophagea is strong, and the fact that the diet can be specifically manipulated to decrease the incidence of GEU in pigs argues strongly for the role that diet plays in promoting gastric ulcerogenesis. In pigs, the general strategy for management of GEU and gastric mucosal ulceration is centered around prevention of acidic reflux into the pars esophagea by provision of diets that are coarsely ground and limiting the consumption of fermentable carbohydrates.<sup>30</sup> This approach represents a compromise between providing a diet that promotes optimal growth and weight gain among pigs during the fattening period of production and the prevention of GEU. The interactions of diet formulation, dietary carbohydrate content (chiefly as corn, cornstarch, and corn byproducts), and certain species of gastric microbes (eg, the *Helicobacter* organisms and the carbohydrate-fermenting commensals such as *Bacillus* and *Lactobacillus* spp<sup>40</sup>) with the development of GEU in pigs maintained under conventional management conditions remain to be determined. If an infectious component of gastric ulcer disease in pigs is established, then specific measures such as specific antimicrobial treatments, targeted probiotics, and vaccines containing *H pylori*-like or other relevant bacterial antigens could be developed to prevent or control bacterial gastritis. In this manner, producers would be provided with additional methods for the control of GEU and mucosal ulcer disease in pigs.

- a. Rabbit antisera against *Helicobacter pylori*, Novacastra Vision Biosystems, Norwell, Mass, and DakoCytomation Inc, Carpinteria, Calif.

## References

1. *Helicobacter pylori* in peptic ulcer disease. *NIH Consensus Statement* 1994;12:1-17.
2. Marshall BJ, Warren JR. Unidentified curved bacilli in the stomach of patients with gastritis and peptic ulceration. *Lancet* 1984;1:1311-1314.
3. Sipponen P, Hyvarinen H. Role of *Helicobacter pylori* in the pathogenesis of gastritis, peptic ulcer and gastric cancer. *Scand J Gastroenterol Suppl* 1993;196:3-6.
4. Moss S, Calam J. *Helicobacter pylori* and peptic ulcers: the present position. *Gut* 1992;33:289-292.
5. Peterson WL. *Helicobacter pylori* and peptic ulcer disease. *N Engl J Med* 1991;324:1043-1047.
6. Prichard PJ, Yeomans ND. *Helicobacter pylori* and duodenal ulcer. *J Gastroenterol Hepatol* 1991;6:177-178.
7. Sipponen P. *Helicobacter pylori* and chronic gastritis: an increased risk of peptic ulcer? A review. *Scand J Gastroenterol* 1991;26:6-10.
8. Blaser MJ. Hypotheses on the pathogenesis and natural history of *Helicobacter pylori*-induced inflammation. *Gastroenterology* 1992;102:720-726.
9. Leung KM, Hui PK, Chan WY, et al. *Helicobacter pylori*-related gastritis and gastric ulcer. A continuum of progressive epithelial degeneration. *Am J Clin Pathol* 1992;98:569-574.
10. Wyatt JL. Histopathology of gastroduodenal inflammation: the impact of *Helicobacter pylori*. *Histopathology* 1995;26:1-15.
11. Nomura A, Stemmermann GN, Chyou P-H, et al. *Helicobacter pylori* infection and gastric carcinoma among Japanese Americans in Hawaii. *N Engl J Med* 1991;325:1132-1136.
12. Parsonnet J, Vandersteen D, Goates J, et al. *Helicobacter pylori* infection in intestinal and diffuse-type gastric adenocarcinomas. *J Natl Cancer Inst* 1991;83:640-643.
13. Forman D, Newell DG, Fullerton F, et al. Association between infection with *Helicobacter pylori* and risk of gastric cancer: evidence from a prospective investigation. *Br Med J* 1991;302:1302-1305.
14. Sipponen P. *Helicobacter pylori* infection—a common worldwide environmental risk factor for gastric cancer? *Endoscopy* 1992;24:424-426.
15. Eid S, Stolte M, Fischer R. *Helicobacter pylori* gastritis and primary gastric non-Hodgkins lymphomas. *J Clin Pathol* 1994;47:436-439.
16. Hussell T, Isaacson PG, Crabtree JE, et al. The response of cells from low-grade B-cell gastric lymphomas of mucosa-associated lymphoid tissue to *Helicobacter pylori*. *Lancet* 1993;342:571-574.
17. Rodriguez LV, Hansen S, Gelb A, et al. *Helicobacter pylori* and gastric lymphoma: a nested case-control study. *Acta Gastro-Enterol (Belg)* 1993;56(suppl):47.
18. Krakowka S, Morgan DR, Kraft WO, et al. Establishment of gastric *Campylobacter pylori* infection in the neonatal piglet. *Infect Immun* 1987;55:2789-2796.
19. Lambert JR, Borromeo M, Pinkard KJ, et al. Colonization of gnotobiotic piglets with *Campylobacter pyloridis*—an animal model. *J Infect Dis* 1987;155:1344.
20. Fox JG, Cabot EB, Taylor NS, et al. Gastric colonization of *Campylobacter pylori* subsp *mustelae* in ferrets. *Infect Immun* 1988;56:2994-2996.
21. Euler AR, Zarenko GE, Moe JB, et al. Evaluation of two monkey species (*Macaca mulatta* and *Macaca fascicularis*) as possible models for human *Helicobacter pylori* disease. *J Clin Microbiol* 1990;28:2285-2290.
22. Marchetti MB, Arico D, Burrioni N, et al. Development of a mouse model of *Helicobacter pylori* infection that mimics human disease. *Science* 1995;267:1655-1658.
23. Baskerville A, Newell DG. Naturally occurring chronic gastritis and *C pylori* infection in the Rhesus monkey: a potential model for gastritis in man. *Gut* 1988;29:465-472.
24. Dubois A, Fiala N, Heman-Ackah LM, et al. Natural gastric infection with *Helicobacter pylori* in monkeys: a model for spiral bacteria infection in humans. *Gastroenterology* 1994;106:1405-1417.
25. Engstrand L, Gustavsson S, Jorgensen A, et al. Inoculation of barrier born pigs with *Helicobacter pylori*: a useful animal model for gastritis type B. *Infect Immun* 1990;58:1763-1768.
26. Bertram TA, Krakowka S, Morgan DR. Gastritis associated with infection by *Helicobacter pylori*: comparative pathology in humans and swine. *Rev Infect Dis* 1991;13:S714-S722.
27. Krakowka S, Eaton KA. *Helicobacter pylori* infection in gno-

- tobiotic piglets: a model of human gastric bacterial disease. In: Tumbleson M, Schook L, eds. *Advances in swine in biomedical research II*. New York: Plenum Press, 1996;779–810.
28. Vandenbroucke-Grauls CM, Appelmelk BJ. *Helicobacter pylori* LPS: molecular mimicry with the host and role in autoimmunity. *Ital J Gastroenterol Hepatol* 1998;30:259–260.
  29. Appelmelk BJ, Negrini R, Moran AP, et al. Molecular mimicry between *Helicobacter pylori* and the host. *Trends Microbiol* 1997;5:70–73.
  30. O'Brien JJ. Gastric ulcers. In: Leman AD. *Diseases of swine*. 6th ed. 1986;680–691.
  31. Embaye H, Thomlinson JR, Lawrence TLJ. Histopathology of oesophagogastric lesions in pigs. *J Comp Pathol* 1990;103:253–264.
  32. Argenzio RA, Southworth M. Sites of organic acid production and absorption in the gastrointestinal tract of the pig. *Am J Physiol* 1975;228:454–462.
  33. Argenzio RA, Eisemann J. Mechanisms of acid injury in pig gastroesophageal mucosa. *Am J Vet Res* 1996;57:564–573.
  34. Queiroz DM, Rocha GA, Mendes EN, et al. A spiral microorganism in the stomach of pigs. *Vet Microbiol* 1990;24:199–204.
  35. Barbosa AJ, Silva JC, Nogueira AM, et al. Higher incidence of *Gastrospirillum* sp in swine with gastric ulcer of the pars oesophagea. *Vet Pathol* 1995;32:134–139.
  36. Queiroz DM, Rocha GA, Mendes EN, et al. Association between *Helicobacter* and gastric ulcer disease of the pars esophagea in swine. *Gastroenterology* 1996;111:19–27.
  37. Melnichouk SL, Friendship RM, Dewey CE, et al. *Helicobacter*-like organisms in the stomach of pigs with and without gastric ulceration. *Swine Health Prod* 1999;7:201–205.
  38. Henry GA, Long PH, Burns JL, et al. Gastric spirillosis in Beagles. *Am J Vet Res* 1987;48:831–836.
  39. Hanninen ML, Happonen I, Saari S, et al. Culture and characteristics of *Helicobacter bizzozeronii*, a new canine gastric *Helicobacter* sp. *Int J Syst Bacteriol* 1996;36:160–166.
  40. Jalava K, Kaartinen M, Utrianinen I, et al. *Helicobacter salomonis* sp. nov., a canine gastric *Helicobacter* sp. related to *Helicobacter felis* and *Helicobacter bizzozeronii*. *Int J Syst Bacteriol* 1997;47:975–982.
  41. Lee A, Hazell SL, O'Rourke J, et al. Isolation of a spiral-shaped bacterium from the cat stomach. *Infect Immun* 1998;56:2843–2850.
  42. Jalava K, On SLW, Vandamme PAR, et al. Isolation and identification of *Helicobacter* spp. from canine and feline gastric mucosa. *Appl Environ Microbiol* 1998;64:3998–4006.
  43. Eaton KA, Dewhirst FE, Paster BJ, et al. Prevalence and varieties of *Helicobacter* species in random-source and pet dogs; animal and public health implications. *J Clin Microbiol* 1996;34:3165–3170.
  44. Eaton KA, Radin MJ, Kramer L, et al. Epizootic gastritis in cheetahs associated with gastric spiral bacilli. *Vet Pathol* 1993;30:55–63.
  45. Eaton KA, Radin MJ, Kramer L, et al. Gastric spiral bacilli in captive cheetahs. *Scand J Gastroenterol* 1991;26:38–42.
  46. Heilmann KL, Borchard F. Gastritis due to spiral shaped bacteria other than *Helicobacter pylori*: clinical, histological and ultrastructural findings. *Gut* 1991;32:137–140.
  47. Solnick JV, O'Rourke J, Lee A, et al. An uncultured gastric spiral organism is a newly identified *Helicobacter* in humans. *J Infect Dis* 1993;168:379–385.
  48. Roosendaal R, Vos JH, Roumen T, et al. Slaughter pigs are commonly infected by closely related but distinct gastric ulcerative lesion-inducing gastrospirilla. *J Clin Microbiol* 2000;38:2661–2664.
  49. Krakowka S, Eaton KA, Rings DM, et al. Production of gastroesophageal erosions and ulcers (GEU) in gnotobiotic swine monoinfected with fermentative commensal bacteria and fed high carbohydrate diet. *Vet Pathol* 1998;35:274–282.
  50. Krakowka S, Ringler SR, Flores J, et al. Isolation and preliminary characterization of a novel *Helicobacter* species from swine. *Am J Vet Res* 2005;66:938–944.
  51. Eaton KA, Ringler S, Krakowka S. Isolation of pure populations of *Helicobacter heilmannii*-like bacteria. In: Newell DG, Ketley JM, Feldman RA, eds. *Campylobacters, helicobacters, and related organisms*. New York: Plenum Press, 1996;25–31.
  52. Akopyants NS, Eaton KA, Berg DE. Adaptive mutation and cocolonization during *Helicobacter pylori* infection of gnotobiotic piglets. *Infect Immun* 1994;63:116–121.
  53. Krakowka S, Eaton KA. *Helicobacter pylori*-specific immunoglobulin synthesis in gnotobiotic piglets: evidence for the induction of mucosal immunity in the stomach. *Vet Immun Immunopathol* 2002;88:173–182.
  54. Krakowka S, Eaton KA, DM Rings. Occurrence of gastric ulcers in gnotobiotic piglets colonized by *Helicobacter pylori*. *Infect Immun* 1995;63:2352–2355.
  55. Green WB, Eaton KA, Krakowka S. Porcine gastric mucosa associated lymphoid tissue (MALT): stimulation by colonization with the gastric bacterial pathogen, *Helicobacter pylori*. *Vet Immunol Immunopathol* 1997;56:119–131.
  56. Stolte M, Eidt S. Lymphoid follicles in antral mucosa: immune response to *Campylobacter pylori*? *J Clin Pathol* 1989;42:1269–1271.