

# Assessment of erythrocyte morphologic abnormalities in mallards with experimentally induced zinc toxicosis

Mary M. Christopher, DVM, PhD; Mahrokh P. Shoostari, MS; Jeffrey M. Levensood, PhD

**Objective**—To describe and quantify morphologic abnormalities in RBCs of mallards (*Anas platyrhynchos*) with experimentally induced zinc toxicosis.

**Animals**—120 female mallards.

**Procedure**—Farm-raised mallards (6 to 8 months old) were used in the study. On day 0, 60 ducks received shot pellets orally by gavage (mean dose of zinc, 0.97 g); another 60 ducks underwent the same procedure without administration of pellets. On day 15, Romanowsky-stained blood smears were prepared from 53 control and 45 zinc-treated ducks (smears were examined retrospectively). In each smear, 200 RBCs were examined and numbers of erythrocytes with abnormal size, shape, or color were expressed as a percentage. Results were compared with PCV values and zinc dose.

**Results**—Mean PCV value was lower in all zinc-treated ducks, compared with control ducks, and was lower in zinc-treated ducks that died or were euthanized before day 30 because of severe clinical disease, compared with those that survived. Zinc-treated ducks that survived had a high percentage of polychromatophilic RBCs, and those that died before day 30 had high percentages of hypochromic RBCs, fusiform RBCs, and RBC nuclear abnormalities. There was no correlation between PCV value or RBC morphologic abnormalities and dose of zinc.

**Conclusions and Clinical Relevance**—In ducks with severe zinc-induced hemolysis, findings indicated that functional iron deficiency may impair the effectiveness of the erythroid regenerative response and contribute to death. Erythrocyte nuclear abnormalities were consistent with mild dyserythropoiesis. These findings may be applicable to effects of other metal toxicoses and regenerative anemias in birds. (*Am J Vet Res* 2004;65:440–446)

In animals, the acute toxic effects of zinc on erythrocytes that lead to RBC destruction and hemolytic anemia have been described. Rats that are fed a diet containing a high concentration of zinc have marked erythrocyte fragility and short life span of RBCs.<sup>1</sup> Zinc toxicosis in dogs results in acute, highly regenerative

hemolytic anemia, associated occasionally with spherocytes or Heinz bodies that suggest immune-mediated or oxidative mechanisms of hemolysis.<sup>2,3</sup> A gray-headed chachalaca<sup>4</sup> and a macaw<sup>5</sup> with zinc toxicosis had evidence of extravascular hemolysis, and cockatiels<sup>6</sup> that ingested excess zinc developed greenish droppings and anemia with evidence of erythroid regeneration. Mallards given zinc pellets orally also developed hemolytic anemia, with increased polychromasia and numbers of immature RBCs consistent with a regenerative response to accelerated RBC destruction.<sup>7</sup>

In addition to the direct and destructive effects of zinc on RBCs, interactions between high dietary zinc concentration and iron metabolism and utilization also may result in anemia. Results of studies in rats,<sup>8-12</sup> chickens,<sup>13-17</sup> and Japanese quail<sup>18</sup> indicate that ingestion of excess dietary zinc interferes with intestinal iron absorption and impairs iron utilization; the toxic effects of excess dietary zinc are more apparent in iron-deficient animals. Zinc also can indirectly affect iron mobilization through interference with copper absorption and metabolism.<sup>10,16,18,19</sup> Ceruloplasmin, a copper-containing protein that controls the rate of release of iron from macrophages and mitochondria, is required to ensure the availability of iron for use by immature RBCs engaged in heme synthesis. In rats, the effects of excess dietary zinc on iron and copper metabolism are variable and appear to depend on the concentration of zinc ingested in the diet, duration of administration of zinc, and other factors.<sup>10,20</sup> In ducks and chicks, zinc-induced anemia may develop despite supplementation of the diet with iron.<sup>7,13,15</sup> Although the precise nature of the interactions between zinc and iron remain to be clarified, the net results of excess dietary zinc on iron absorption and metabolism are ineffective or faulty hematopoiesis and anemia.<sup>1,15,19</sup> Limitations in iron uptake or utilization for hemoglobin synthesis could impair or limit the erythroid regenerative response to zinc-induced RBC hemolysis and exacerbate the anemia.<sup>1,19</sup>

Morphologic features of RBCs often provide information regarding the underlying cause of anemia. In dogs, the effect of zinc on RBCs may result in the formation of Heinz bodies, which suggests an oxidative mechanism,<sup>3</sup> whereas the development of hypochromic microcytic RBCs is characteristic of iron deficiency.<sup>21</sup> In association with zinc toxicosis, poikilocytosis (presence of abnormally shaped RBCs) has been reported in rats<sup>1</sup> and ducks<sup>7</sup> but specific RBC morphologic abnormalities have not been described nor has their relation to anemia or zinc dosage been fully evaluated. We hypothesized that morphologic features

Received June 2, 2003.

Accepted August 15, 2003.

From the Department of Pathology, Microbiology, and Immunology (Christopher) and the Veterinary Medical Teaching Hospital (Shoostari), School of Veterinary Medicine, University of California, Davis, CA 95616; and the Center for Wildlife Ecology, Illinois Natural History Survey, 607 E Peabody Dr, Champaign, IL 61820 (Levensood).

The authors thank Dr. Michael Fry for technical assistance and Dr. Philip Kass for statistical advice.

Address correspondence to Dr. Christopher.

of RBCs might provide evidence of the underlying mechanism of zinc-induced anemia in ducks.

The purpose of this study was to describe and quantify morphologic abnormalities in RBCs of mallards with experimentally induced zinc toxicosis. In addition, the associations among the amount of zinc absorbed via the intestinal tract, PCV values, the percentages of abnormal RBCs, and death were investigated.

## Materials and Methods

Blood smears prepared during an investigation<sup>7</sup> of zinc-intoxication in mallard ducks (*Anas platyrhynchos*) were evaluated microscopically in this study. Briefly, the 30-day study (preceded by a 20-day acclimatization period) involved 120 female farm-raised mallards (6 to 8 months old). Sixty ducks received a single oral dose of zinc (mean dose, 0.97 g) in the form of shot pellets administered by gavage on day 0 prior to blood collection. The remaining 60 ducks were used as controls; these ducks underwent the same gavage procedure on the same day as zinc-treated ducks but did not receive pellets. The shot pellets consisted of 98% zinc and 2% tin, with no other metals considered detectable (< 0.1% each). Although the zinc-treated ducks all received the same initial dose, the amount of zinc absorbed by each bird was calculated from the weight of shot administered minus the weight of shot recovered from the gizzard during necropsy. The study followed institutional and US guidelines for animal care and use; ducks with severe clinical disease (eg, those that had difficulty standing and moving to the extent that access to water and food was impeded) were euthanized by decapitation by a staff veterinarian and examined via necropsy. Ducks that survived to day 30 were similarly euthanized and necropsied following blood collection.

From treated and control birds, blood samples were collected via venipuncture of the ulnar vein into 2 heparinized microhematocrit capillary tubes (50  $\mu$ L each) for PCV determination on days 0 (just prior to zinc administration), 15, and 30 (just prior to euthanasia). On day 15, an additional 3.0 mL of blood was collected; 1.0 mL of this sample was transferred to tubes containing EDTA<sup>a</sup> for use in the preparation of blood smears. The remaining 2.0 mL was used for biochemical analyses, as reported elsewhere.<sup>7</sup> When possible, 3.0 mL of blood also was collected just prior to euthanasia of ducks with severe clinical disease. Smears prepared on glass microscope slides were air-dried and stained with a Romanowsky stain.<sup>b</sup>

Blood smears were available for retrospective evaluation from 53 control ducks and 45 zinc-treated ducks. The smears were examined microscopically by 1 investigator (MPS) who was unaware of the ducks' treatment. For each smear, 200 RBCs were examined; the number of immature RBCs, the number of RBCs with abnormal shape or color (classified as polychromic

or hypochromic), and the number of RBCs with nuclear abnormalities were recorded and expressed as a percentage. In replicate evaluations of a subset of 10 smears (1 from each of 5 control and 5 zinc-treated ducks), the percentage counts differed by < 1% to 4%. Abnormalities seen rarely (ie, those detected in < 1% of RBCs) were noted but not included in the calculated percentages. Erythrocytes with > 1 abnormality (ie, abnormal shape and abnormal color) were counted only once but included in > 1 category of RBC abnormalities.

**Statistical analyses**—Because the RBC data obtained were not normally distributed, all results were analyzed by use of nonparametric tests. Data obtained for control and zinc-treated ducks were compared by use of a Mann-Whitney test for unpaired comparisons; findings for control ducks, zinc-treated ducks that died or were euthanized before day 30 as a result of severe clinical disease, and zinc-treated ducks that survived to day 30 were compared by use of Kruskal-Wallis ANOVA with Mann-Whitney post hoc comparisons. Comparisons between RBC abnormalities and PCV values or zinc dose were made by use of least squares linear regression analysis. Values of  $P < 0.05$  were considered significant.

## Results

All 60 control ducks survived to day 30, and no adverse events were noted. Blood smears were available from 53 control ducks. Seventeen of 60 zinc-treated ducks died or were euthanized between days 8 and 15; blood smears from day 15 were available for 2 of these ducks. Twelve zinc-treated ducks died or were euthanized between days 16 and 27; blood smears from day 15 were available for all of these ducks, and PCV values for 4 of these ducks were obtained just prior to euthanasia. Clinical signs in zinc-treated ducks included ataxia, anorexia, pallor, and dark or bright green, foul-smelling diarrhea. During necropsy examination of the gizzards of zinc-treated ducks, the weight of undissolved shot pellets was measured. By calculation, the mean  $\pm$  SD amount of zinc dissolved (and presumed to have been absorbed) by zinc-treated ducks that died or were euthanized before day 30 was 0.535  $\pm$  0.276 mg, whereas those that survived to day 30 had dissolved 0.858  $\pm$  0.124 mg.

Only PCV values for ducks from which blood smears were evaluated were analyzed in this study. On day 15, mean PCV value for zinc-treated ducks that survived to day 30 was significantly ( $P < 0.001$ ) lower than that of control ducks but significantly higher than that of zinc-treated ducks that died before day 30 (Table 1). On day 30, mean PCV in zinc-treated ducks

Table 1—Mean and median (range) values of PCV in mallards receiving a single dose of zinc (mean dose, 0.97 g zinc) by oral gavage of shot pellets (day 0) or receiving oral gavage without shot pellets (controls)

Day	Control group (n = 53)		Zinc-treated group				P value
	Mean $\pm$ SD	Median (range $\ddagger$ )	Died* (n = 14)		Alive $\ddagger$ (n = 31)		
	Mean $\pm$ SD	Median (range $\ddagger$ )	Mean $\pm$ SD	Median (range $\S$ )	Mean $\pm$ SD	Median (range $\ddagger$ )	
Day 0	50.1 $\pm$ 4.6 <sup>a</sup>	50.0 (40.5–60.9)	50.6 $\pm$ 3.1 <sup>a</sup>	50.0 (46.0–57.0)	49.8 $\pm$ 4.4 <sup>a</sup>	50.0 (39.4–58.0)	0.870
Day 15	47.3 $\pm$ 5.3 <sup>a</sup>	48.0 (39.0–54.2)	31.9 $\pm$ 11.8 <sup>b</sup>	29.0 (13.0–47.0)	44.6 $\pm$ 5.3 <sup>c</sup>	46.0 (33.3–53.7)	< 0.001
Day 30	49.9 $\pm$ 3.5 <sup>a</sup>	50.0 (43.8–57.2)	19.0 $\pm$ 6.7 <sup>b</sup>	18.0 (13.0–27.0)	48.3 $\pm$ 4.7 <sup>a</sup>	50.0 (36.4–55.5)	< 0.001

\*Died or euthanized before day 30 after treatment as a result of severe clinical disease. PCV values for 4 ducks euthanized between days 16 and 27 are reported on day 30.  $\ddagger$ Alive at day 30 after treatment.  $\S$ Range represents 2.5 to 97.5 percentiles for control and zinc-treated ducks that remained alive at 30 days after treatment.  $\S$ Range represents the minimum to maximum values for zinc-treated ducks that died or were euthanized before day 30 after treatment.

<sup>a,b,c</sup>Mean values with different superscript letters are significantly ( $P < 0.05$ ) different across rows.

Table 2—Type of RBC abnormalities and number of mallards affected after receiving a single dose of zinc (mean dose, 0.97 g zinc) by oral gavage of shot pellets (day 0) or receiving oral gavage without shot pellets (controls)

Morphologic features of RBCs on day 15 after treatment	No. of mallards affected		
	Control group (n = 53)	Zinc-treated group	
		Died* (14)	Alivet (31)
Immature	13	12	17
Polychromatophilic	53	14	31
Hypochromic‡	2	12	4
Fusiform shape§	2	9	3
Nuclear abnormalities	0	6	0

\*Died or euthanatized before day 30 after treatment as a result of severe clinical disease. †Alive at day 30 after treatment. ‡Most hypochromic cells were also slightly polychromatophilic. §Most fusiform cells were hypochromic, polychromatophilic, or both.

Table 3—Mean and median (range) percentages of RBC abnormalities in mallards after receiving a single dose of zinc (mean dose, 0.97 g zinc) by oral gavage of shot pellets (day 0) or receiving oral gavage without shot pellets (controls)

Morphologic features of RBCs on day 15 after treatment	Zinc-treated group (n = 45)							P value
	Control group (n = 53)		Died* (14)		Alivet† (31)			
	Mean ± SD	Median (range‡)	Mean ± SD	Median (range§)	Mean ± SD	Median (range‡)		
Immature	0.17 ± 0.32 <sup>a</sup>	0 (0–1.1)	3.82 ± 4.49 <sup>b</sup>	2.5 (0–10.5)	1.19 ± 1.93 <sup>c</sup>	0.5 (0–7.3)	< 0.001	
Polychromatophilic	7.60 ± 2.97 <sup>a</sup>	7.5 (2.9–14.5)	8.86 ± 7.66 <sup>b</sup>	7.3 (0.5–18.5)	10.63 ± 5.32 <sup>c</sup>	8.5 (4.8–26.3)	0.022	
Hypochromic	0.02 ± 0.10 <sup>a</sup>	0 (0–0.5)	12.64 ± 14.24 <sup>b</sup>	9.5 (0–55.5)	0.34 ± 0.92 <sup>c</sup>	0 (0–3.2)	< 0.001	
Fusiform	0.02 ± 0.10 <sup>a</sup>	0 (0–0.5)	4.36 ± 7.25 <sup>b</sup>	2.8 (0–28.0)	0.18 ± 0.64 <sup>c</sup>	0 (0–2.7)	< 0.001	
Nuclear abnormalities	0 <sup>a</sup>	0 (0–0)	0.39 ± 0.63 <sup>b</sup>	0 (0–2.0)	0 <sup>a</sup>	0 (0–0)	< 0.001	

\*Died or euthanatized before day 30 after treatment as a result of severe clinical disease. †Alive at day 30 after treatment. ‡Range represents 2.5 to 97.5 percentiles for control and zinc-treated ducks that remained alive at 30 days after treatment. §Range represents the minimum to maximum values for zinc-treated ducks that died or were euthanatized before day 30 after treatment.  
<sup>a,b,c</sup>Mean values with different superscripts are significantly ( $P < 0.05$ ) different across rows.

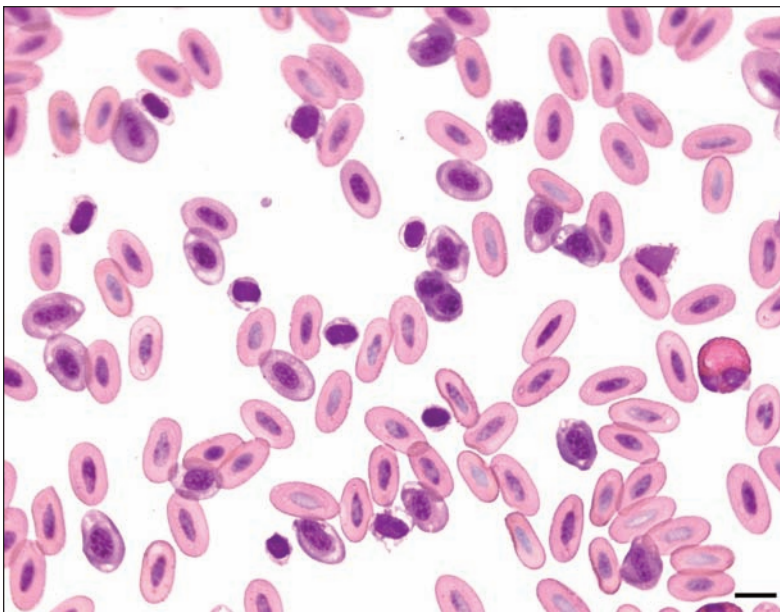


Figure 1—Photomicrograph of a blood smear from a mallard with zinc toxicosis. Several immature RBCs are visible, one of which is binucleated (near center of image). Most cells are normochromic. Notice the irregular focal areas of hypochromasia in certain polychromatophilic and immature RBCs. Wright-Giemsa stain; bar = 10  $\mu$ m.

that survived was not significantly lower than that of control ducks. On day 15, RBC abnormalities were identified in most zinc-treated ducks (Table 2). Compared with findings in control ducks, the percent-

ages of immature ( $P < 0.001$ ), polychromatophilic ( $P = 0.037$ ), hypochromic ( $P < 0.001$ ), and fusiform ( $P = 0.009$ ) RBCs were significantly higher in zinc-treated mallards.

On examination of the blood smears prepared from samples obtained on day 15, zinc-treated ducks that died or were euthanatized before day 30 had a greater percentage of immature RBCs, compared with zinc-treated ducks that survived to day 30 and control ducks; however, zinc-treated ducks that survived to day 30 had a significantly higher percentage of polychromatophilic RBCs, compared with zinc-treated ducks that died or were euthanatized before day 30 and control ducks (Table 3). Immature RBCs were differentiated from polychromatophilic and mature RBCs by their smaller size, rounder nuclei with more open chromatin, and basophilic cytoplasm.<sup>22,23</sup>

Hypochromic RBCs were observed in 12 of 14 ducks that died or were euthanatized before day 30 and in 4 of 31 zinc-treated ducks that remained alive at day 30 (Table 2). Hypochromasia was identified

by decreased color saturation, compared with that of normochromic RBCs. The extent of hypochromasia of RBCs ranged from focal (Fig 1) to diffuse; the most severely affected cells had only a thin rim of cytoplasm



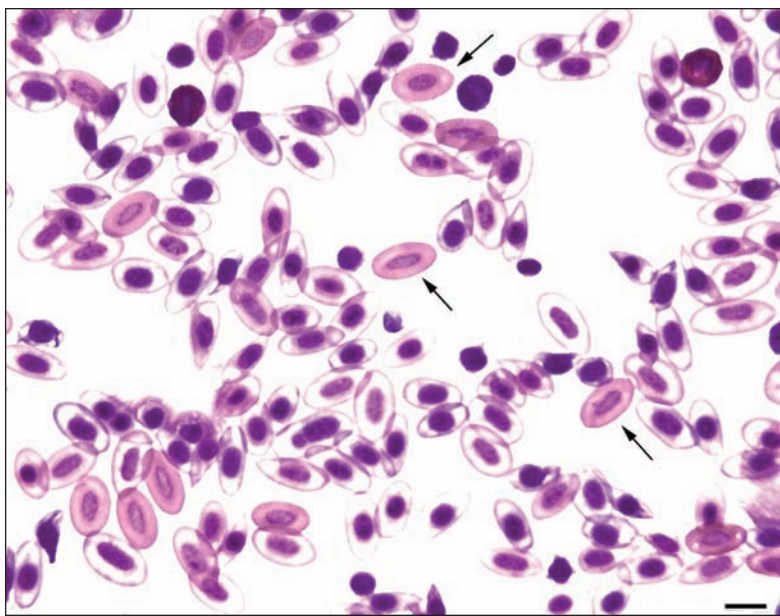


Figure 2—Photomicrograph of a blood smear from a mallard with zinc toxicosis. Most RBCs are severely hypochromic, with only a few normochromic cells (arrows). Notice that the residual cytoplasm of most hypochromic cells is slightly blue, indicating that most hypochromic cells are also polychromatophilic. Wright-Giemsa stain; bar = 10  $\mu$ m.

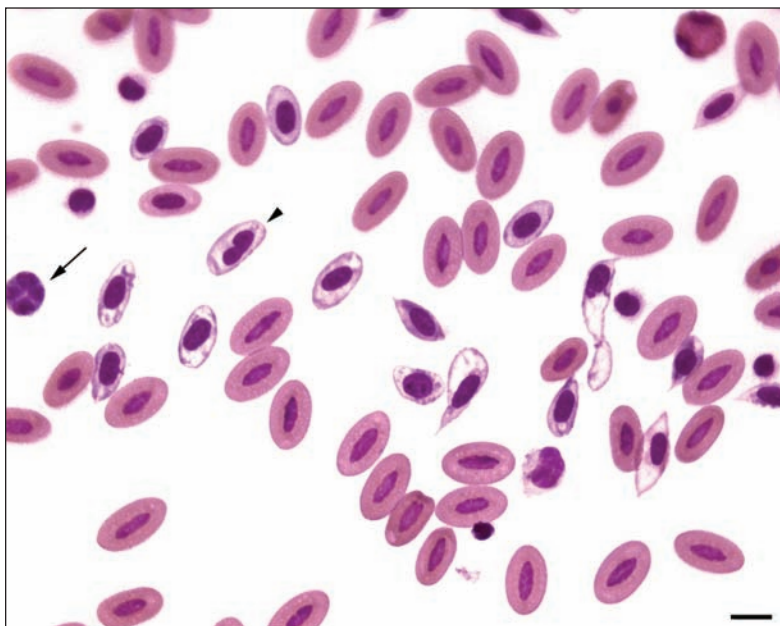


Figure 3—Photomicrograph of a blood smear from a mallard with zinc toxicosis. Notice several hypochromic, polychromatophilic RBCs, some of which are fusiform, elongated, and have folded cytoplasm or eccentric nuclei. One immature RBC (arrow) has a multinucleated nucleus, and 1 polychromatophilic RBC (arrowhead) has a peanut-shaped nucleus. Wright-Giemsa stain; bar = 10  $\mu$ m.

around the nucleus or periphery (Fig 2). Focal hypochromasia was detected in a low number of immature RBCs. Hypochromic RBCs with eccentric nuclei were observed in 7 zinc-treated ducks that died or were euthanatized before day 30. All but a few hypochromic RBCs also were polychromatophilic, as determined on the basis of the blue color of residual cytoplasm. Zinc-treated ducks that died or were

euthanatized had a significantly higher percentage of hypochromic RBCs, compared with that detected in zinc-treated ducks that survived to day 30 and control ducks.

Shape abnormalities consisted almost exclusively of RBCs that were fusiform with elongated narrow cytoplasm, blunt-pointed ends, or long tapering cytoplasmic tails extending in one or both directions along the long axis of the cell (Fig 3 and 4). A few RBCs appeared dacryocytic. Many fusiform processes were twisted or folded, and most fusiform cells were hypochromic or slightly polychromatophilic. Cytoplasmic fragments were observed rarely. The percentage of fusiform RBCs was significantly higher in zinc-treated ducks that died or were euthanatized before day 30, compared with that detected in zinc-treated ducks that survived to day 30 and control ducks (Table 3).

Nuclear abnormalities were observed only in erythrocytes of zinc-treated ducks that died or were euthanatized before day 30 (Table 3). Nuclear abnormalities consisted of peanut-shaped nuclei and binucleated or multinucleated RBCs in mature polychromatophilic and hypochromic cells (Fig 3 and 4). The percentage of nuclear abnormalities was significantly higher in zinc-treated ducks that died or were euthanatized before day 30, compared with zinc-treated ducks that survived and control ducks (Table 3).

The PCV value in zinc-treated ducks correlated significantly and inversely ( $r = 0.735$ ;  $P < 0.001$ ) with the percentage of hypochromic RBCs. This correlation was stronger ( $r = 0.807$ ;  $P < 0.001$ ) when the percentage of immature RBCs was included. There was no correlation ( $r = 0.157$ ;  $P < 0.001$ ) between PCV value and the percentage of polychromatophilic, non-hypochromic RBCs. There also was no correlation ( $r = 0.218$ ;  $P = 0.302$ ) between PCV value and zinc dose.

Seven zinc-treated ducks that died or were euthanatized before day 30 had the most severe and numerous RBC abnormalities. These ducks had a mean PCV value on day 15 of  $22.1 \pm 5.8\%$ , compared with  $41.7 \pm 6.8\%$  for the other

7 zinc-treated ducks that did not survive and  $44.6 \pm 5.3\%$  for the other 31 zinc-treated ducks that survived to day 30 ( $P < 0.001$ ). The mean amount of zinc dissolved by the 7 severely affected ducks was  $0.62 \pm 0.25$  mg, compared with  $0.45 \pm 0.29$  mg for other zinc-treated ducks that died or were euthanatized and  $0.86 \pm 0.12$  mg for other zinc-treated ducks that survived.

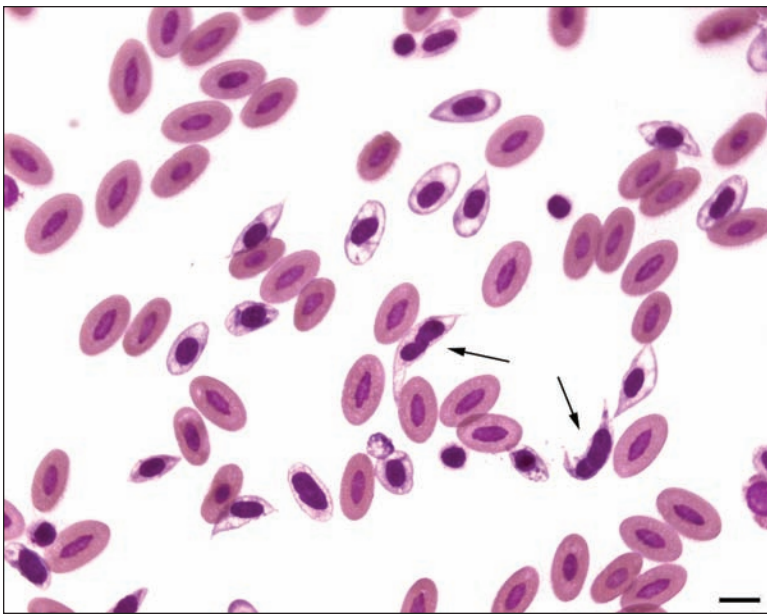


Figure 4—Photomicrograph of a blood smear from a mallard with zinc toxicosis. Several hypochromic, polychromatophilic RBCs and fusiform and dacrycytic (teardrop-shaped) RBCs are visible. Two fusiform cells have elongated, irregular nuclei (arrows). Wright-Giemsa stain; bar = 10  $\mu$ m.

## Discussion

Zinc toxicosis has been the subject of considerable attention in wild birds, domestic poultry, and pet birds. In wild birds, toxic effects of zinc exposure are most likely to develop after ingestion of materials with high zinc composition, such as shot pellets.<sup>24</sup> Zinc toxicosis in aviary or pet birds has resulted from ingestion of galvanized metal from wire mesh cages.<sup>5,6,25</sup> In birds with zinc toxicosis, evidence for hemolysis has included detection of anemia with normal to high numbers of immature RBCs,<sup>6</sup> greenish droppings,<sup>5,6,24</sup> increased splenic erythrophagocytosis (compared with clinically normal birds),<sup>4</sup> and hemosiderin in hepatic Kupffer cells.<sup>4,24</sup> To our knowledge, RBC morphologic abnormalities have not been evaluated or reported previously in association with zinc toxicosis in pet birds or domestic fowl.

The results of the study reported here have confirmed and quantified the regenerative erythropoietic response to hemolytic anemia caused by acute zinc toxicosis in mallards.<sup>7</sup> However, hypochromasia and poikilocytosis were significantly more prominent than polychromasia in ducks with severe clinical disease. Although hypochromasia is not associated with a particular mechanism of hemolysis, it is a morphologic feature associated with iron deficiency and is a finding consistent with iron-restricted anemia caused by the inhibitory effect of zinc on iron uptake and utilization in animals.<sup>1,9,10,13-18</sup> Decreased hemoglobin synthesis and RBC membrane damage (as indicated by the poikilocytosis) likely impaired the effectiveness of the regenerative response, leading to more severe anemia in ducks with the most severe RBC abnormalities. In addition, the impaired oxygen-carrying capacity of hypochromic RBCs likely contributed to hypoxia and death in severely affected birds. In a long-term study<sup>1</sup> of rats fed zinc in sufficient quantities to severely shorten the life

span of RBCs, microcytic hypochromic anemia (characteristic of iron deficiency) developed within 2 to 5 weeks.

Iron deficiency that results from an imbalance between the iron demands of developing erythroid cells and the available supply of iron is referred to as functional iron deficiency.<sup>26</sup> In contrast to iron deficiency caused by nutritional deficit or chronic blood loss, functional iron deficiency develops despite adequate iron stores; this may be a result of interference with iron uptake or utilization by RBCs during hemoglobin synthesis or availability of an inadequate quantity of iron to supply bone marrow demand associated with increased RBC production. Both impaired iron utilization and accelerated erythropoiesis may have played a role in the development of hypochromasia in zinc-treated ducks. Functional iron deficiency especially affects the hemoglobin concentration of polychromatophilic RBCs, as observed in our study. Hemoglobin concentration of reticulocytes and the proportion of hypochromic RBCs correlate strongly with the availability of iron for erythropoiesis in humans and are considered the most useful diagnostic indicators of iron-restricted erythropoiesis.<sup>26,27</sup>

It is known that impaired iron utilization and iron-restricted erythropoiesis develop in animals with zinc toxicosis. Results of 1 study<sup>24</sup> involving zinc-treated ducks indicated that those that died had higher iron concentrations in plasma and kidney and liver tissue, compared with values in ducks that survived the treatment; however, iron concentration in RBCs was decreased in the ducks that died. This finding indicated that iron was sequestered in plasma (as transferrin-bound iron) and tissue, resulting in decreased incorporation into hemoglobin in those birds.<sup>24</sup> Humans with zinc toxicosis develop sideroblastic anemia with ferric iron accumulation in mitochondria of RBCs.<sup>19,28</sup> Rats receiving excess dietary zinc have decreased iron stores and impaired release of iron from ferritin.<sup>1,8,9</sup> Whereas iron administered via IP injection is rapidly incorporated into heme<sup>1</sup> or ferritin,<sup>12</sup> ingestion of diets supplemented with iron does not usually alleviate anemia, which supports the suggestion that zinc interferes with iron absorption via the intestinal tract.<sup>7,11,13,15</sup> Low tissue copper and ceruloplasmin concentrations resulting from excess dietary zinc (as well as other interactions among zinc, copper, and iron) also may limit iron availability and impair heme synthesis and erythropoiesis.<sup>15,16,18,24</sup> In the ducks of this report, a direct effect of zinc on hemoglobin synthesis could not be ruled out, but there was no association between hypochromasia and the dose of zinc received by the ducks. Individual variation in absorption of (and therefore exposure to) the zinc contained in the shot pellets and individual sensitivity to the effects of zinc may have been factors contributing to this lack of correlation and also may have contributed to the variable manifestation of RBC abnormalities in the zinc-treated ducks.

Hypochromasia has been detected in birds with regenerative anemia resulting from other causes, including lead toxicosis and blood loss.<sup>29,30</sup> Both lead and zinc impair heme synthesis, shorten RBC life span, and may directly damage RBCs resulting in hemolysis and anemia.<sup>13,19</sup> In birds with lead toxicosis, hypochromic RBCs have been described as ballooning erythrocytes or as D cells when the pale cytoplasm is eccentric.<sup>29,30</sup> The characteristics of those cells and the hypochromic RBCs observed in severely affected ducks in our study are similar. In birds, inflammation (which can cause iron-restricted anemia) has also been associated with hypochromic RBCs.<sup>22</sup> Furthermore, Newman et al<sup>31</sup> reported that seabirds that were relocated to rehabilitation centers to recover from the effects of oil spills developed anemia; although the anemia was not described as hypochromic, those birds were believed to be responsive to treatment with supplemental iron via injection. Thus, many disorders that accelerate RBC production or limit the rate of incorporation of iron into hemoglobin could alter iron balance and contribute to hypochromic anemia in birds.

In the zinc-treated ducks of the study reported here, poikilocytosis could have resulted from a direct or indirect effect of zinc on RBC membranes. Although the regenerative response detected in these ducks suggested that RBC destruction was ongoing, spherocytes or Heinz bodies (similar to those detected in dogs with zinc toxicosis) were not observed.<sup>23</sup> New methylene blue-stained smears, which are required for the accurate detection of Heinz bodies, were not examined in this study. Because poikilocytosis was associated with hypochromasia in the zinc-treated ducks, it is more likely that zinc-induced iron deficiency contributed to the observed abnormalities in RBC shape. Iron-deficient RBCs are thinner and more fragile than normal RBCs and susceptible to membrane damage, deformation, and fragmentation.<sup>21,28</sup> Poikilocytes are a common feature of anemia associated with iron deficiency of any cause and may contribute to decreased RBC life span. The fusiform RBCs in the zinc-treated ducks of our study resembled dacryocytes, elliptocytes, and other elongated forms of erythrocytes described in humans and other animals with iron deficiency. Leptocytes and folded cells also are detected in animals with iron deficiency, particularly in camelids which, like birds, have ovoid RBCs.<sup>32,33</sup> Rats with zinc toxicosis and microcytic hypochromic anemia had folded leptocytes, knizocytes, and spindle-shaped RBCs (although they were described only as being irregular in shape).<sup>1</sup> Although a spindle-shaped appearance of RBCs from chickens and turkeys can be caused by stretching during blood smear preparation,<sup>34</sup> artifact alone would not explain the large number of poikilocytes observed in smears of blood from zinc-treated ducks, compared with the number detected in smears from control ducks. Microcytosis of RBCs has also been identified as a feature of iron deficiency,<sup>21</sup> but RBC volume was not quantified in the study of this report. Anisocytosis also was not quantified in our study because in birds with regenerative anemia, the difference in RBC diameter between immature and mature RBCs (percentages of which were quantified in the study of this report) was

expected to be greater than the difference between normocytic and microcytic RBCs. Dyserythropoiesis also may affect RBC size and volume.<sup>21,35</sup>

Acquired nuclear abnormalities in mammalian and avian RBCs are usually a result of dyserythropoiesis (defective RBC development) and occasionally develop in markedly accelerated erythropoiesis.<sup>22,35,36</sup> Nuclear abnormalities in RBCs may include multiple Howell-Jolly bodies, fragmented pyknotic nuclei, and  $\geq 2$  nuclei/cell as detected in a low number of ducks in our study. Binucleated RBCs develop transiently and rarely in clinically normal psittacine birds.<sup>23</sup> Although cells with bilobed nuclei have been described as a preparation artifact of avian RBCs,<sup>34</sup> the variety of nuclear abnormalities and the higher percentage of RBCs with nuclear abnormalities in zinc-treated ducks that died, compared with those in control ducks, suggest that the abnormalities observed were not the result of smear preparation technique. To our knowledge, iron deficiency has not been associated with nuclear abnormalities in RBCs, and in the ducks of this report, mild dysplasia of RBCs secondary to direct effects of zinc or accelerated erythropoiesis is more likely.

The findings of our study have illustrated the importance of blood smear evaluation in the assessment of anemia and indicated morphologic evidence for functional iron deficiency in birds with zinc toxicosis. In mallards, decreased hemoglobin synthesis and RBC membrane damage caused by the direct or indirect effects of zinc were associated with severe clinical disease and an impaired regenerative response to hemolysis. The evaluation of iron-limited erythropoiesis in zinc toxicosis as well as its potential role in other metal toxicoses and regenerative anemias in birds remains to be elucidated. Automated analyzers capable of quantifying reticulocyte hemoglobin concentration and low numbers of hypochromic RBCs may be useful in this regard.

<sup>a</sup>Vacutainer tubes, Becton-Dickinson, Franklin Lakes, NJ.

<sup>b</sup>Dip Quick, Jorgensen Laboratories, Loveland, Colo.

## References

1. Settlemire CT, Matrone G. In vivo effect of zinc on iron turnover in rats and life span of the erythrocyte. *J Nutr* 1967;92:159-164.
2. Robinette CL. Zinc. *Vet Clin North Am Small Anim Pract* 1990;20:539-544.
3. Luttgren PJ, Whitney MS, Wolf AM, et al. Heinz body hemolytic anemia associated with high plasma zinc concentration in a dog. *J Am Vet Med Assoc* 1990;197:1347-1350.
4. Droual R, Meteyer CU, Galey FD. Zinc toxicosis due to ingestion of a penny in a gray-headed chachalaca (*Ortalis cinereiceps*). *Avian Dis* 1991;35:1007-1011.
5. Romagnano A, Grindem CV, Degernes L, et al. Treatment of a hyacinth macaw with zinc toxicity. *J Avian Med Surg* 1995;9:185-189.
6. Howard BR. Health risks of housing small psittacines in galvanized wire mesh cages. *J Am Vet Med Assoc* 1992;200:1667-1674.
7. Levensgood JM, Sanderson GC, Anderson WL, et al. Influence of diet on the hematology and serum biochemistry of zinc-intoxicated mallards. *J Wildl Dis* 2000;36:111-123.
8. Abdel-Mageed AB, Oehme FW. The effect of various dietary zinc concentrations on the biological interactions of zinc, copper, and iron in rats. *Biol Trace Elem Res* 1991;29:239-256.
9. Settlemire CT, Matrone G. In vivo interference of zinc with ferritin iron in the rat. *J Nutr* 1967;92:153-158.



10. Storey ML, Greger JL. Iron, zinc and copper interactions: chronic versus acute responses of rats. *J Nutr* 1987;117:1434-1442.
11. Siewicki TC, Syndlowski JS, Vandolah FM, et al. Influence of dietary zinc and cadmium on iron bioavailability in mice and rats; oyster vs. salt sources. *J Nutr* 1986;116:281-289.
12. Coleman CB, Matrone G. In vivo effect of zinc on iron-induced ferritin synthesis in rat liver. *Biochim Biophys Acta* 1969;177:106-112.
13. Bafundo KW, Baker DH, Fitzgerald PR. The iron-zinc interrelationship in chicks as influenced by *Eimeria acervulina* infection. *J Nutr* 1984;114:1306-1312.
14. Pimental JL, Greger JL, Cook ME, et al. Iron metabolism in chicks fed various level of zinc and copper. *J Nutr Biochem* 1992;13:140-145.
15. Parsons CM, Baker DH, Welch CC. Effect of excess zinc on iron utilization by chicks fed a diet devoid of phytate and fiber. *Nutr Res* 1989;9:227-231.
16. Stahl JL, Greger JL, Cook ME. Zinc, copper and iron utilization by chicks fed various concentrations of zinc. *Br Poult Sci* 1989;30:123-134.
17. Blalock TL, Hill CH. Studies on the role of iron in zinc toxicity in chicks. *Biol Trace Elem Res* 1987;17:17-29.
18. Hamilton RP, Fox MRS, Fry BE, et al. Zinc interference with copper, iron and manganese in young Japanese quail. *J Food Sci* 1979;44:738-741.
19. Walsh CT, Sandstead HH, Prasad AS, et al. Zinc: health effects and research priorities for the 1990s. *Environ Health Perspect* 1994;102:5-46.
20. O'Neil MA, Bomford A, Munro HN. Effect of excess dietary zinc on tissue storage of iron in rats. *J Nutr* 1981;111:1969-1979.
21. Harvey JW. Microcytic anemia. In: Feldman BF, Zinkl JG, Jain NC, eds. *Schalm's veterinary hematology*. 5th ed. Philadelphia: Lippincott Williams & Wilkins, 2000;200-204.
22. Campbell TW. *Avian hematology*. 2nd ed. Ames: Iowa State University Press, 1995;3-19.
23. Campbell TW. Normal hematology of psittacines. In: Feldman BF, Zinkl JG, Jain NC, eds. *Schalm's veterinary hematology*. 5th ed. Philadelphia: Lippincott Williams & Wilkins, 2000;1155-1160.
24. Levensgood JM, Sanderson GC, Anderson WL, et al. Acute toxicity of ingested zinc shot to game-farm mallards. *Ill Nat Hist Surv Bull* 1999;36:1-36.
25. Reece RL, Dickson DB, Burrowes PJ. Zinc toxicity (new wire disease) in aviary birds. *Aust Vet J* 1986;63:199.
26. Thomas C, Thomas L. Biochemical markers and hematologic indices in the diagnosis of functional iron deficiency. *Clin Chem* 2002;48:1066-1076.
27. Mast AE, Blinder MA, Lu Q, et al. Clinical utility of the reticulocyte hemoglobin content in the diagnosis of iron deficiency. *Blood* 2002;99:1489-1491.
28. Jandl JH. *Blood*. 2nd ed. Boston: Little, Brown & Co, 1996;289-348.
29. Fudge AM. Avian complete blood count. In: Fudge AM, ed. *Laboratory medicine: avian and exotic pets*. Philadelphia: WB Saunders Co, 2000;9-18.
30. Fudge AM. Disorders of avian erythrocytes. In: Fudge AM, ed. *Laboratory medicine: avian and exotic pets*. Philadelphia: WB Saunders Co, 2000;30-32.
31. Newman SH, Ziccardi MH, Mazet JK, et al. Hematologic changes and anemia associated with captivity and petroleum exposure in sea birds. *Comp Haematol Intl* 1999;9:60-67.
32. Harvey JW. *Atlas of veterinary hematology: blood and bone marrow of domestic animals*. Philadelphia: WB Saunders Co, 2001;28-35.
33. Morin DE, Gary FB, Weiser MG. Hematologic responses in llamas with experimentally-induced iron deficiency anemia. *Vet Clin Pathol* 1993;22:81-85.
34. Bounous DI. Normal avian hematology: chicken and turkey. In: Feldman BF, Zinkl JG, Jain NC, eds. *Schalm's veterinary hematology*. 5th ed. Philadelphia: Lippincott Williams & Wilkins, 2000;1147-1154.
35. Kociba GJ. Macrocytosis. In: Feldman BF, Zinkl JG, Jain NC, eds. *Schalm's veterinary hematology*. 5th ed. Philadelphia: Lippincott Williams & Wilkins, 2000;196-199.
36. Romagnano A, Barnes HJ, Perkins P, et al. Binucleate erythrocytes and erythrocytic dysplasia in a cockatiel, in *Proceedings*. 15th Annu Meet Assoc Avian Vet 1994;83-86.