

## What Is Your Diagnosis?

In collaboration with the American College of Veterinary Radiology

### History

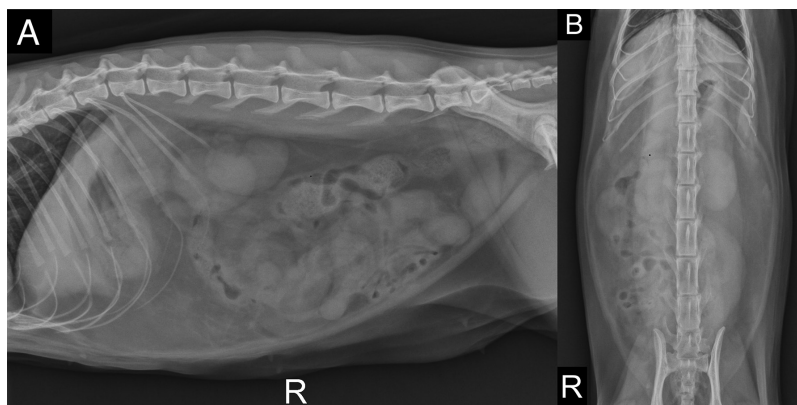
A 3-year-old spayed female domestic shorthair cat was presented for a 1-day history of progressive vomiting, anorexia, and lethargy after vomiting a large trichobezoar. The patient had had a similar occurrence of clinical signs 14 months previously, and abdominal ultrasonography at that time was unremarkable. An exploratory laparotomy and gastrotomy were performed and revealed no clinically important findings. Results from several intestinal biopsies revealed mild plasmacytic lymphocytic enteritis, and the cat's clinical signs resolved with supportive treatment.

On physical examination, the cat was dull but alert and responsive. A CBC and serum biochemical analysis revealed hyperglycemia (224 mg/dL; reference range, 74 to 159 mg/dL), hypercholesterolemia (265 mg/dL; reference range, 65 to 225 mg/dL), high mean corpuscular hemoglobin concentration (17.7 g/dL; reference range, 9.8 to 16.2 g/dL), eosinopenia ( $0.05 \times 10^3$  cells/ $\mu\text{L}$ ; reference range,  $0.17 \times 10^3$  to  $1.57 \times 10^3$  cells/ $\mu\text{L}$ ), and thrombocytopenia ( $85 \times 10^3$  platelets/ $\mu\text{L}$ ; reference range,  $151 \times 10^3$  to  $600 \times 10^3$  platelets/ $\mu\text{L}$ ). Abdominal radiographs were obtained (**Figure 1**).

**Formulate differential diagnoses, then continue reading.**

### Diagnostic Imaging Findings and Interpretation

On radiographic images, serosal detail in the abdomen was diminished, and the stomach contained a small volume of gas and fluid (**Figure 2**). There was segmental moderate to marked small intestinal dilation (17 to 20 mm; reference limit,  $\leq 12$  mm) of the segments within the left midventral to caudal ventral



**Figure 1**—Right lateral (A) and ventrodorsal (B) radiographic images of the abdomen of a 3-year-old spayed female domestic shorthair cat evaluated because of progressive vomiting, anorexia, and lethargy after vomiting a large trichobezoar.

aspect of the abdomen. The remainder of the small intestines contained fluid and gas, without evidence of dilation. The remainder of the abdominal structures appeared radiographically normal. Based on these findings, mechanical obstruction was suspected with concern for focal enteritis, adhesions, and secondary mild peritonitis.

Abdominal ultrasonography was performed. Within the midabdomen, a dilated segment of small intestine containing echogenic material and gas was identified (not shown). This segment had mildly thickened walls and could be followed from the right midabdominal region, across midline, and to the left midabdominal region. The segment appeared constricted on each end between the area of dilation and that of normal diameter and wall thickness on either side. Scant abdominal effusion was noted, and the mesentery surrounding the dilated segment was hyperechoic. All other abdominal structures were unremarkable. Differential diagnoses for these findings included intestinal volvulus, mechanical obstruction secondary to a nonvisible foreign body or mass, intestinal entrapment, and mesenteric entrapment.

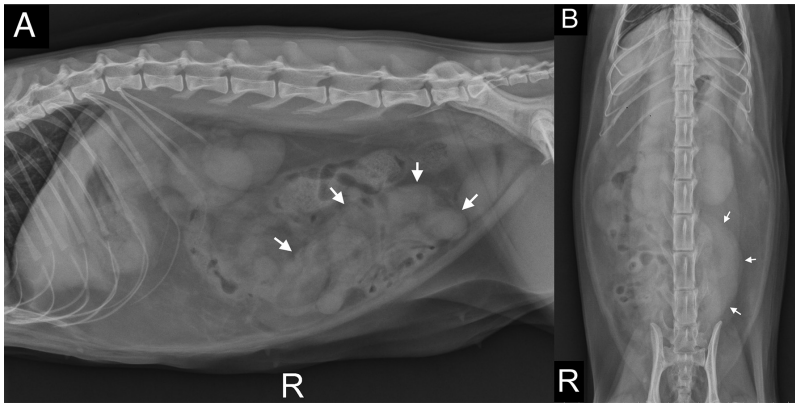
### Treatment and Outcome

An exploratory laparotomy revealed moderate abdominal effusion and numerous adhesions throughout the duodenum and jejunum. The aboral third of the jejunum had a dark purple discoloration

Claire P. J. Whittaker, DVM\*, and Elyshia J. Hankin, DVM, DACVR  
Friendship Hospital for Animals, Washington, DC

\*Corresponding author: Dr. Whittaker (whittakerclairepj@gmail.com)

<https://doi.org/10.2460/javma.20.08.0467>



**Figure 2**—Same images as in Figure 1. There is moderate, segmental dilation of small intestinal loops (arrows) within the left midventral aspect of the abdomen. The dilated small intestine is predominantly fluid filled. Wispy soft tissue opacities are noted throughout the mid and midcranial aspects of the abdomen, supporting potential scant peritoneal effusion.

and no visible peristalsis, and the associated mesentery appeared hemorrhagic. Intestinal adhesions from the aboral aspect of a segment of jejunum aboral to the devitalized portion of intestine appeared to have been causing entrapment of the segment, strangulation, and enlargement likely secondary to a partial jejunal volvulus. The adhesions were broken down, and resection and anastomosis of the distal third of the jejunum were performed. The cat recovered from surgery uneventfully and was discharged 3 days later.

## Comments

Mesenteric volvulus is an uncommon disease associated with a high mortality rate in dogs.<sup>1</sup> It involves partial or complete torsion of the small intestine around the mesenteric root, and patients typically present in ischemic shock from occlusion of the cranial mesenteric artery and vein.<sup>1</sup> The cause for mesenteric volvulus is unknown, but several associations in dogs have been suspected, including trauma, recent gastrointestinal surgery, dietary indiscretion, large or giant breeds, intestinal adhesions, lymphocytic-plasmacytic enteritis, gastric dilatation-volvulus, intestinal parasites, foreign bodies, and gastrointestinal neoplasia.<sup>1,2</sup> Comparably, the cat of the present report had had relatively recent gastrointestinal surgery, a diagnosis of lymphoplasmacytic enteritis, a foreign body (trichobezoar), and intestinal adhesions.

To our knowledge, there have only been 2 other cats with mesenteric volvulus treated successfully with surgery, and both cats had systemic shock and required aggressive fluid therapy and blood transfusions on admission.<sup>3</sup> Interestingly, our patient was presented in stable condition, with a gradual, non-specific history and moderate thrombocytopenia. For one of those previously reported patients,<sup>3</sup> abdominal radiography showed severely dilated and gas-filled small intestines, and abdominal ultrasonography revealed findings similar to those seen in our patient. In

the second previously reported case,<sup>3</sup> abdominal radiography showed dilated and gas-filled loops of small intestine lying parallel to each other. For both of those affected cats, mesenteric volvulus was diagnosed during surgery and both patients recovered.<sup>3</sup> It has been suggested that the prognosis of mesenteric volvulus may be more favorable in cats as opposed to dogs because both cats recovered following antemortem diagnosis and rapid surgical intervention.<sup>3</sup> Similarly, the cat of the present report recovered from surgery and was discharged 3 days later. Unfortunately, our patient was lost to follow-up, but has not returned to our hospital for medical emergencies since.

A study<sup>1</sup> shows that all included dogs that were presented because of acute to peracute abdominal signs and later diagnosed with mesenteric volvulus were also in shock on presentation. Other symptoms included acute to peracute vomiting and abdominal distention, with occasional hematochezia and tenesmus.<sup>1</sup> Radiographic findings were similar to those in cats, with reduced serosal detail and generalized dilation of the small intestines with gas and fluid.<sup>1</sup> In most cases, the top differential diagnosis was intestinal obstruction or paralytic ileus.<sup>1,2,4</sup> Irreversible damage to the intestines can be avoided with rapid surgical intervention, and dogs that benefit from rapid exploratory laparotomy may have greater chances of recovery.<sup>1</sup>

Although a rare disease, mesenteric volvulus should be considered as a differential diagnosis in dogs and cats with radiographic signs suggestive of mechanical obstruction, particularly in patients presenting in systemic shock. Radiographic and ultrasonographic features of segmental mesenteric torsion can mimic mechanical obstruction with associated peritonitis. Dilation of the small intestines with mixed gas and fluid and reduced serosal detail are the most common findings.<sup>1</sup> Mesenteric volvulus is a serious illness; however, the prognosis may be improved in affected dogs and cats if the disease is suspected from imaging and rapid surgical intervention is instituted.

## References

1. Junius G, Appeldoorn AM, Schrauwen E. Mesenteric volvulus in the dog: a retrospective study of 12 cases. *J Small Anim Pract.* 2004;45(2):104-107.
2. Shealy PM, Henderson RA. Canine intestinal volvulus, a report of nine new cases. *Vet Surg.* 1992;21(1):15-19. doi:10.1111/j.1748-5827.2004.tb00211.x
3. Knell SC, Andreoni AA, Denner M, Venzin CM. Successful treatment of small intestinal volvulus in two cats. *J Feline Med Surg.* 2010;12:874-877. doi:10.1016/j.jfms.2010.09.007
4. Cairó J, Font J, Gorraiz J, Martin N, Pons C. Intestinal volvulus in dogs: a study of four clinical cases. *J Small Anim Pract.* 1999;40(3):136-140. doi:10.1111/j.1748-5827.1999.tb03058.x