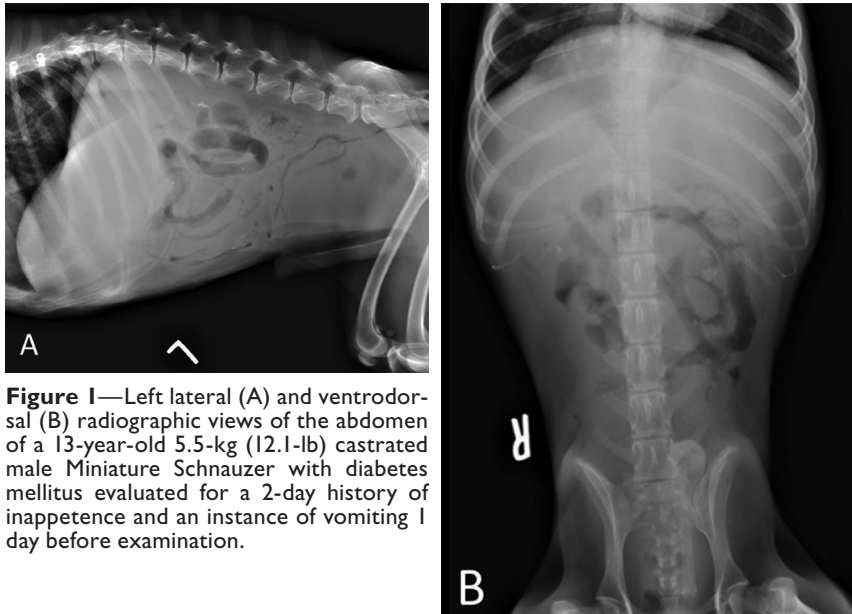




## What Is Your Diagnosis?



**Figure 1**—Left lateral (A) and ventrodorsal (B) radiographic views of the abdomen of a 13-year-old 5.5-kg (12.1-lb) castrated male Miniature Schnauzer with diabetes mellitus evaluated for a 2-day history of inappetence and an instance of vomiting 1 day before examination.

### History

A 13-year-old 5.5-kg (12.1-lb) castrated male Miniature Schnauzer was evaluated for a 2-day history of inappetence and an instance of vomiting 1 day before examination. The owner reported that diabetes mellitus had been diagnosed in the dog 3 years earlier and that since then, the dog had persistent polyuria and polydipsia. In addition, the dog had had an episode of diabetic ketoacidosis, pancreatitis, and a urinary tract infection 6 months before the present examination.

On physical examination, the dog had a grade 3/6 left apical heart murmur. The dog's abdomen had a tucked-up appearance and was tense on palpation, which also elicited signs of pain. Results of 3 repeated measurements of the dog's systolic arterial pressure (196, 185, and 207 mm Hg; reference range, 130 to 180 mm Hg), diastolic arterial pressure (108, 134, and 112 mm Hg; reference range, 60 to 95 mm Hg), and mean arterial pressure (137, 151, and 144 mm Hg; reference range, 70 to 110 mm Hg) with an oscillometric blood pressure monitor indicated systemic hypertension. Electrocardiography revealed runs of  $\geq 10$  ventricular premature contractions that responded to lidocaine (2.0 mg/kg [0.9 mg/lb], IV bolus).

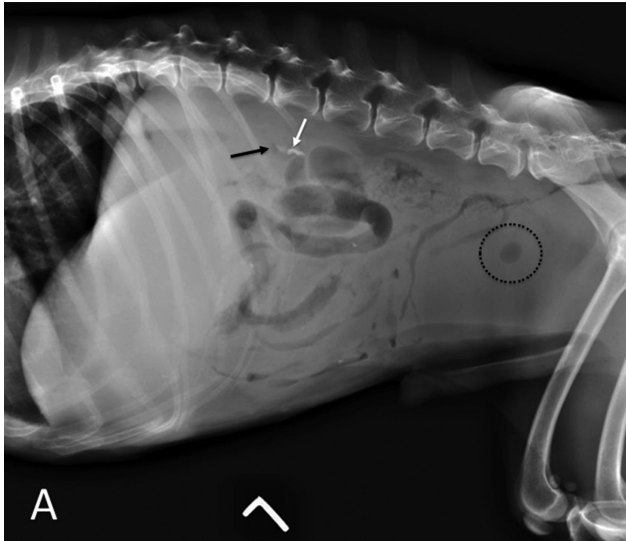
Results of a CBC and serum biochemical analyses indicated a stress leukogram (characterized by neutrophilia [16,830 neutrophils/ $\mu$ L; reference range, 3,500 to 14,200 neutrophils/ $\mu$ L] and absolute eosinopenia [0 eosinophils/ $\mu$ L; reference range, 0 to 1,500 eosinophils/ $\mu$ L]), hyperglycemia (724 mg/dL; reference range, 75 to 125 mg/dL), hyperproteinemia (13.0 g/dL; reference range, 5.5 to 8.0 g/dL), hyperglobulinemia (10.2 g/dL; reference range, 2.1 to 4.3 g/dL), hypercholesterolemia (911 mg/dL; reference range, 140 to 360 mg/dL), hyperphosphatemia (15.2 mg/dL; reference range, 2.5 to 5.0 mg/dL), and hypermagnesemia (3.9 mg/dL; reference range, 1.7 to 2.4 mg/dL) along with high concentration of total bilirubin (6.8 mg/dL; reference range, 0.2 to 0.6 mg/dL) and high activities of alanine aminotransferase (110 U/L; reference range, 10 to 90 U/L) and alkaline phosphatase (430 U/L; reference range, 11 to 140 U/L). However, because of lipemia (4+) and hemolysis (2+), a full biochemical panel could not be obtained from the serum sample. Results of a test to evaluate the dog's pancreatic lipase immunoreactivity were within reference limits. Analysis of a urine sample obtained by cystocentesis revealed a urine specific gravity of 1.028 (reference range; 1.025 to 1.035), proteinuria (3+), glucosuria (4+), pyuria (10 to 25 WBCs/hpf), and hematuria (5 to 10 RBCs/hpf), with many bacteria and moderate numbers of nucleated cell clumps. Bacterial culture of urine yielded *Escherichia coli* and other gram-negative rods.

Abdominal radiography was performed (**Figure 1**).

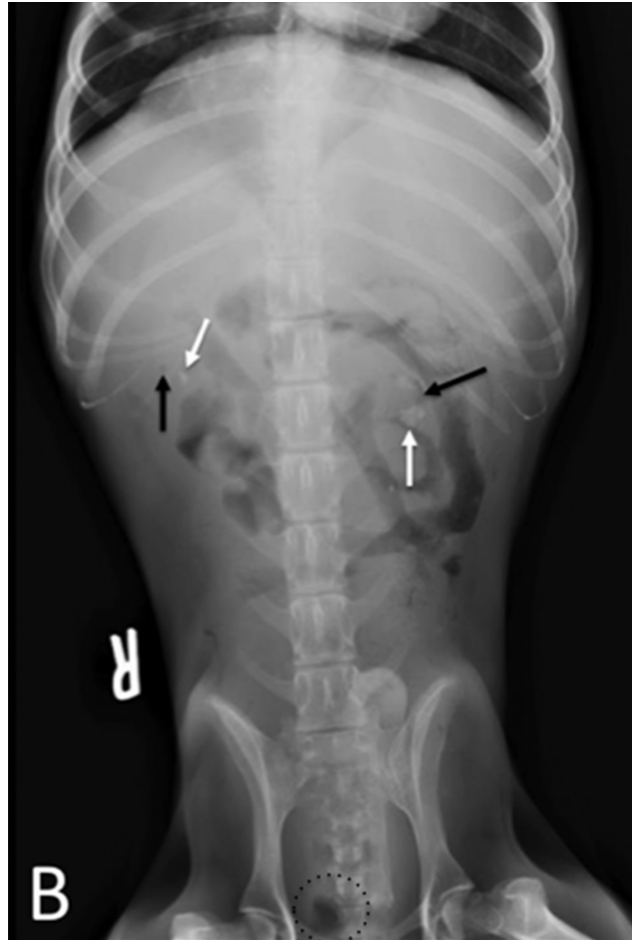
**Determine whether additional imaging studies are required, or make your diagnosis from Figure 1—then turn the page →**

This report was submitted by Christy N. Buckley, DVM; Alison M. Lee, DVM, MS; and Andrew J. Mackin, BVMS, DVSc; from the Department of Clinical Sciences, College of Veterinary Medicine, Mississippi State University, Mississippi State, MS 39762.

Address correspondence to Dr. Lee (aplumley@cvm.msstate.edu).



**Figure 2**—Same images as in Figure 1. Nephroliths (white arrows) and gas (black arrows) surrounding the nephroliths are present bilaterally. In the urinary bladder, a small gas bubble (dotted circle) is present and was considered most consistent with the dog recently undergoing cystocentesis.



## Diagnostic Imaging Findings and Interpretation

Abdominal radiography revealed diffusely poor abdominal serosal detail that limited evaluation of the abdominal organs (**Figure 2**). The intestines appeared to contain heterogenous soft tissue opaque material and gas. Small, angular, sharply marginated, mineral opaque foci were present overlying the renal silhouettes in the presumed regions of the renal pelvises. In addition, small patchy gas lucencies were present surrounding these mineral opaque foci. A small gas bubble was also present in the urinary bladder.

The differential diagnosis list for the decreased serosal detail included fluid (eg, effusion [a pure transudate or an inflammatory or neoplastic modified transudate or exudate], hemorrhage, bile, chyle, or urine), a lack of intra-abdominal fat, peritonitis, or carcinomatosis. The gas lucencies superimposed over the kidneys were thought to be in the small bowel superimposed over the kidneys. The mineral opaque material in both renal pelvises was consistent with nephrolithiasis, and the gas bubble in the urinary bladder was consistent with the recent cystocentesis.

Abdominal ultrasonography revealed irregular renal margins bilaterally, with multiple smoothly marginated concave defects, consistent with chronic renal cortical infarction. In addition, 2 anechoic, thin-walled foci with distal acoustic enhancement were present, consistent with degenerative renal cortical cysts. In both renal pelvises, thin hyperechoic linear structures with strong distal acoustic shadowing as well as echogenic foci with reverberation artifact were noted, consistent with nephroliths and renal pelvic gas, respectively.

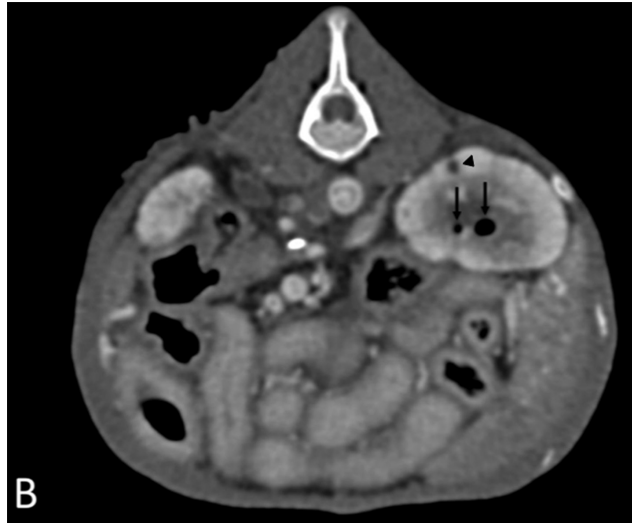
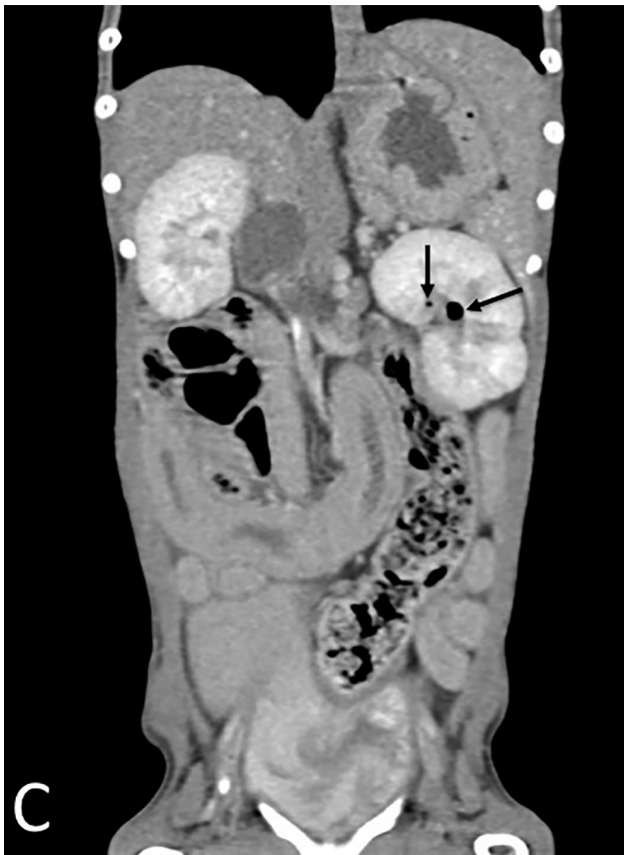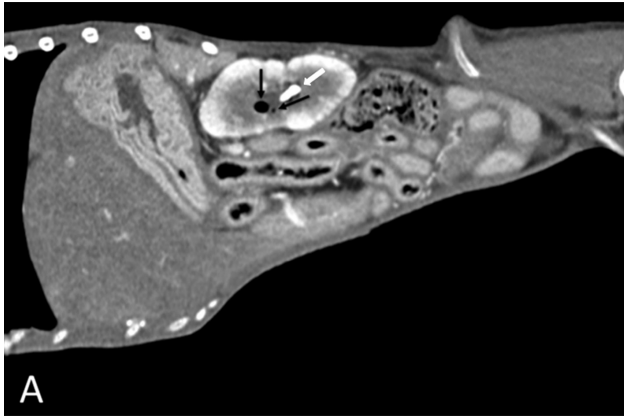
Results of CT confirmed the bilateral presence of small gas bubbles in the renal pelvises (**Figure 3**), mild di-

lation of the renal pelvises, and bilateral ureteral dilation (5.1 mm in diameter on delayed postcontrast images; reference limit,  $\leq 3$  mm<sup>1</sup>). Bilateral emphysematous pyelonephritis (EPN) and nephrolithiasis were diagnosed.

## Treatment and Outcome

The dog was hospitalized, and on the basis of results from bacterial culture of urine and subsequent susceptibility testing, antimicrobial treatment was initiated with enrofloxacin (9.1 mg/kg [4.1 mg/lb], PO, q 24 h) and amoxicillin-clavulonic acid (10.0 mg/kg [4.5 mg/lb], PO, q 12 h). In addition, acetaminophen-codeine (8.0 mg of acetaminophen/kg [3.7 mg/lb] and 1.6 mg of codeine/kg [0.73 mg/lb], PO, q 8 h) was prescribed to control pain, omeprazole (0.8 mg/kg [0.36 mg/lb], PO, q 24 h) was prescribed as a gastroprotectant, maropitant citrate (1.9 mg/kg [0.9 mg/lb], PO, q 12 h) was prescribed to control nausea, and porcine insulin zinc suspension (5 U, SC, q 12 h) was continued at the same dosage to treat the dog's diabetes mellitus.

Three days later, the dog was discharged with the prescribed medications, and the owners were instructed to return the dog in 2 weeks for a recheck bacterial culture of urine. The dog was returned 15 days after discharge and had no signs of nausea, in-



**Figure 3**—Postcontrast sagittal (A), transverse (B), and dorsal (C) plane abdominal CT images in a soft tissue window (window width, 400 HU; window length, 50 HU) at the level of the left renal pelvis of the dog in Figures 1 and 2. In the left kidney, there are 2 round, gas-attenuating, smoothly margined bubbles (black arrows) and a small, irregularly shaped, smoothly margined, mineral-attenuating focus (white arrow; A), consistent with gas bubbles and a nephrolith, respectively, in the renal pelvis. In addition, there is a small, round, fluid-attenuating, thin-walled, smoothly margined structure (arrowhead; B) in the dorsal aspect of the left renal cortex, consistent with a degenerative renal cortical cyst. There are irregular renal cortical margins bilaterally. The dog's right is to the left of the image in panels B and C.

appetence, or abdominal pain. A recheck bacterial culture of urine yielded no growth. Administration of acetaminophen-codeine, omeprazole, and maropitant was discontinued; however, antimicrobial treatment as prescribed was continued for an additional 42 days. Administration of insulin was continued at the same dosage.

On recheck examination 25 days after the diagnosis of bilateral EPN and nephrolithiasis, the dog had persistent, uncontrolled diabetes mellitus, with blood glucose concentration ranging from 431 to 715  $\mu\text{g}/\text{dL}$  and continued clinical signs (polyuria and polydipsia). Therefore, treatment with insulin was increased to 7 U, SC, every 12 hours. Reported results of a recheck examination with the referring veteri-

narian 1 month later indicated that the dog's diabetes mellitus was more controlled (decreased polyuria and polydipsia and a steady body weight) and that there had been no return of any clinical signs associated with pyelonephritis. Given the small size of the nephroliths and the lack of ongoing associated clinical signs, no specific treatment was recommended for the dog's nephrolithiasis.

## Comments

In dogs, EPN is an uncommon urinary tract infection characterized by the presence of gas in the renal collecting system, renal parenchyma, and perirenal tissues.<sup>1</sup> The condition is typically a severe, necrotizing infection of the renal and perirenal tissues and has been reported in dogs, cats, people, and a cow.<sup>1</sup> Clinical signs of EPN are similar to those of other types of pyelonephritis (eg, fever, pyuria, and pain) and may include lethargy and inappetence. Although pyelonephritis is commonly diagnosed on the basis of clinical signs, EPN is diagnosed on the basis of results from diagnostic imaging, including recognition of gas in the collecting ducts or renal parenchyma, combined with clinical evidence of pyelonephritis. Computed tomography is the best imaging modality for characterizing structural aspects of EPN because with CT, the renal and urinary tract architecture can be more fully assessed. In addition, CT allows for full characterization of gas limited to the collecting ducts, versus ex-



tending into the renal parenchyma or further (which carries a worse prognosis and may require a change in treatment protocols), and also allows for classification of the specific type of EPN.<sup>2,3</sup> Radiography and ultrasonography, in combination or alone, are usually performed before CT and can help establish the diagnosis of EPN. However, the diagnosis of EPN on the basis of radiographic examination alone may be difficult or impossible, as was the case in the dog of the present report, because the radiographic appearance of gas in a kidney may be more commonly caused by superimposition of gas-filled bowel. Additional signs, such as enlarged renal pelvic diameter, dilation of the proximal portion of the ureters, and renal abscess formation, may be characterized with ultrasonography or CT.<sup>2,4,5</sup> Similarly, retroperitoneal effusion and hyperechogenicity of adjacent peritoneum that may occur secondary to pyelonephritis and abscess formation can be detected with ultrasonography or CT.<sup>2-4</sup> Changes in renal size or shape that often occur in affected patients may be detected with radiography, ultrasonography, or CT.<sup>2,4</sup>

Although EPN is considered to be an uncommon to rare condition, when it is diagnosed, it is most commonly reported in people and animals with diabetes mellitus.<sup>1,6</sup> Diabetes mellitus is associated with immunosuppression, increased tissue glucose concentrations, and decreased renal blood flow. Although the pathophysiologic processes of infections in animals with EPN remain incompletely understood, it is postulated that the high tissue glucose concentrations and decreased immunity in patients with diabetes mellitus contribute to infection by glucose-fermenting bacteria or yeast.<sup>1,2</sup> Because diabetes mellitus can predispose a patient to pyelonephritis or urinary tract infections, alone or in combination, and such infections can then predispose affected individuals to poor diabetic control and diabetic ketoacidosis, it is important to diagnose and treat these infectious processes early.<sup>4,7</sup>

Diagnosis of EPN is made on the basis of findings from bacterial culture of urine, clinical signs, and diagnostic imaging. Bacterial culture of urine from dogs with EPN typically yields gram-negative organisms. Studies<sup>1,5</sup> show that *E coli* is the most commonly isolated pathogen cultured from affected dogs, with *Staphylococcus* spp being the next most common in animals. *Klebsiella* spp, *Proteus* spp, *Clostridium* spp, and *Aerobacter aerogenes* are also commonly isolated. Optimally, treatment is based on results from bacterial culture of urine and subsequent susceptibility testing. Prognosis for dogs with EPN is good to

guarded, depending on EPN classification (gas in the collecting ducts carries the most favorable prognosis, compared with gas found in the renal parenchyma or perirenal tissues)<sup>1</sup> and whether effective and aggressive treatments are pursued. A study<sup>2</sup> in humans shows that of 5 patients with EPN who underwent medical management with antimicrobial treatment selected on the basis of results from bacterial culture and susceptibility testing, 3 survived. Also, in people with more severe EPN or with renal abscess formation, percutaneous catheter drainage or emergency nephrectomy may be indicated and prognosis is much more guarded, compared with the prognosis for patients with lower classifications of EPN and who have no gas in or extending outside the renal parenchyma.

Emphysematous pyelonephritis is a rare but severe form of pyelonephritis. Dogs with a history of diabetes mellitus, such as the dog in the present report, are predisposed to developing cystitis and pyelonephritis. Forty-six of 48 (95%) human patients with EPN also had diabetes mellitus,<sup>2</sup> and the same disease association is likely in dogs. Therefore, EPN should be considered in dogs with diabetes mellitus that also have concurrent diagnostic imaging evidence of gas overlying or in the kidneys and that are febrile, have pyuria, or show signs of abdominal pain, alone or in combination.

## Acknowledgments

The authors declare that there were no financial or other conflicts of interest.

## References

1. Moon R, Biller BS. Emphysematous cystitis and pyelonephritis in a nondiabetic dog and a diabetic cat. *J Am Anim Hosp Assoc* 2014;50:124-129.
2. Huang JJ, Tseng CC. Emphysematous pyelonephritis: clinico-radiological classification, management, prognosis, and pathogenesis. *Arch Intern Med* 2000;160:797-805.
3. Craig WD, Wagner BJ, Travis MD. Pyelonephritis: radiologic-pathologic review. *Radiographics* 2008;28:255-277.
4. Seiler GS. Kidneys and ureters. In: Thrall DE, ed. *Textbook of veterinary diagnostic radiology*. 7th ed. St Louis: Elsevier, 2018;823-845.
5. Bouillon J, Snead E, Caswell J, et al. Pyelonephritis in dogs: retrospective study of 47 histologically diagnosed cases (2005-2015). *J Vet Intern Med* 2018;32:249-259.
6. Ubee SS, McGlynn L, Fordham M. Emphysematous pyelonephritis. *BJU Int* 2011;107:1474-1478.
7. Dongen AM. Pyelonephritis. In: Ettinger SJ, Feldman EC, Cote E, eds. *Textbook of veterinary internal medicine*. 8th ed. St Louis: Elsevier, 2017;4776-4782.