



What Is Your Diagnosis?

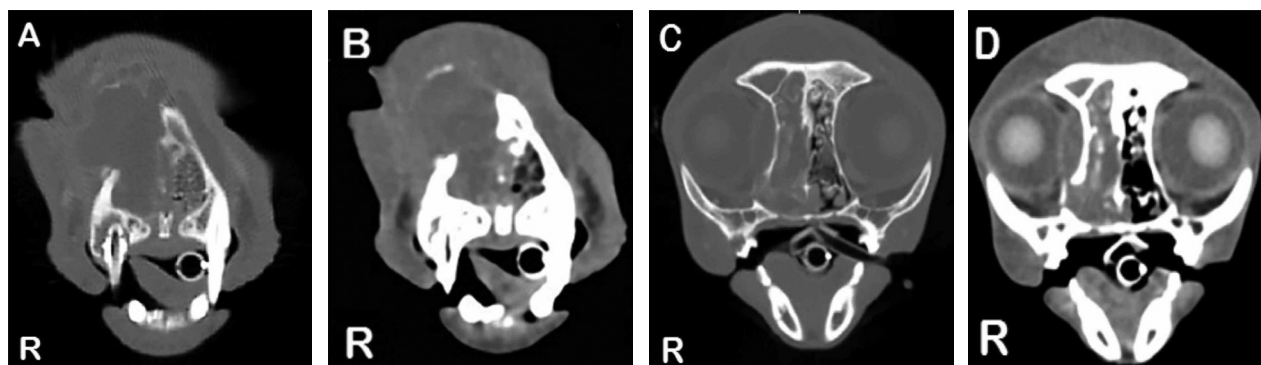


Figure 1—Postcontrast CT views of the skull of a 10-year-old 5.5-kg (12.1-lb) castrated male Maine Coon cat that was referred for evaluation of chronic nasal discharge and facial swelling. A—Transverse CT view of the rostral aspect of the nasal cavity at the level of the right and left maxillary canine teeth; image obtained in a bone algorithm. B—Same transverse CT view as in panel A; image obtained in a soft tissue algorithm. C—Transverse CT view at the level of the orbits; image obtained in a bone algorithm. D—Same transverse CT view as in panel C; image obtained in a soft tissue algorithm. Image acquisition parameters were 120 kV, 101 mA, and slice thickness of 1.3 mm. Iohexol (240 mg of iodine/mL) contrast medium was administered IV (total volume, 11 mL); CT images were displayed to enhance bone (window width, 2500 Hounsfield units [HU]; window level, 250 HU) and to enhance soft tissue (window width, 400 HU; window level, 40 HU).

History

A 10-year-old 5.5-kg (12.1-lb) castrated male Maine Coon cat was referred for evaluation of chronic nasal discharge and facial swelling. The cat was first evaluated 3 months previously for mild right-sided facial swelling, bilateral purulent nasal discharge, and right-sided serous ocular discharge. Treatments in the months prior to referral included oral administration of L-lysine and cephalexin (dosages unknown) and topical application of an ophthalmic solution (type unknown). There was an initial resolution of clinical signs, followed by recurrence. Three days prior to referral, the cat developed hyporexia and progressively worsening recurrence of nasal discharge. Oral administration of doxycycline (dosage unknown) and topical application of an ophthalmic gentamicin solution did not result in clinical improvement.

At the time of hospital admission, the cat had right facial deformity with severe swelling that extended across the midline. There was crusted, purulent discharge covering the right eye, but the corneal surface appeared normal; retropulsion of the right eye was not possible because attempts resulted in signs of pain. Oral examination revealed oligodontia and an increase in tooth mobility, with severe periodontal disease, and a fracture of the right maxillary canine tooth. Auscultation revealed stertor and referred upper airway noise, with obligate open-mouth breathing. Bronchovesicular sounds were normal in all lung fields; a grade 3/6 parasternal systolic murmur was detected.

Hematologic evaluation was performed. Abnormalities included hyperglycemia (171 mg/dL; reference range, 116 to 123 mg/dL), leukocytosis (19.5×10^9 cells/L; reference range, 2.3×10^9 cells/L to 18.4×10^9 cells/L) characterized by neutrophilia (15.4×10^9 cells/L; reference range, 1.4×10^9 cells/L to 11.8×10^9 cells/L) and monocytosis (2.0×10^9 cells/L; reference limit, $\leq 0.6 \times 10^9$ cells/L), and hyperglobulinemia (4.6 g/dL; reference range, 3.1 to 4.1 g/dL).

Thoracic radiography revealed cardiomegaly (vertebral heart score, 8.5; reference limit, < 8.0) with normal pulmonary vasculature and parenchyma. Mild hypertrophy of the left ventricular free wall, with no evidence of left atrial enlargement, was observed by echocardiography.

Computed tomography of the skull was performed with an 8-slice multidetector CT scanner.^a Iohexol (240 mg of iodine/mL) contrast medium was administered IV (total volume, 11 mL); CT images were reconstructed in bone and soft tissue algorithms (**Figure 1**).

Determine whether additional imaging studies are required, or make your diagnosis from Figure 1—then turn the page →

This report was submitted by Maria C. Jugan, MS, DVM; Kristin E. Holland, DVM; Susan Barrett, DVM; and Wm Tod Drost, DVM; from the Department of Veterinary Clinical Sciences, College of Veterinary Medicine, The Ohio State University, Columbus, OH 43210.

Address correspondence to Dr. Jugan (mjugan13@gmail.com).

Diagnostic Imaging Findings and Interpretation

Soft tissue-attenuating material (3.8 X 2.2 X 3.9 cm) with rim contrast enhancement is present within the right nasal cavity (**Figure 2**). There is soft tissue-attenuating material filling the right frontal sinus. The left frontal sinus is abbreviated by cancellous bone (normal variation). The ventral nasal meatus is obstructed bilaterally with soft tissue-attenuating material at this level. On more caudal slices (not shown), soft tissue-attenuating material extends into and obstructs the nasopharynx. Material extends laterally into the right orbit, resulting in right globe displacement. There is lysis of the right nasal conchae, nasal turbinates, maxillary bone, right maxillary teeth (canine tooth, second through fourth premolar teeth, and first molar tooth), ventromedial aspect of the right orbital rim, and cribriform plate (not shown). Additional dental findings include gas within the pulp cavity of the right maxillary canine tooth, root resorption of the right mandibular fourth premolar tooth, supernumerary right maxillary second premolar tooth, and oligodontia (complete findings not shown). Non-contrast-enhancing soft tissue-attenuating material is evident in both frontal sinuses (not shown).

Given the degree of dental and bony destruction, right intranasal neoplasia with obstructed frontal sinuses was the primary differential diagnosis. However, minimal intralesional and rim contrast enhancement of the mass and presence of a canine tooth root emphysematous abscess required consideration of an extensive right nasal and periodontal abscess with secondary osteomyelitis.

Treatment and Outcome

Material was flushed from the nasal cavity and a blind nasal biopsy was performed while the cat was under general anesthesia. Results of cryptococcal antigen latex agglutination serologic testing were negative. An esophageal feeding tube was placed. Histologic evaluation of the nasal tissue specimen revealed multifocal severe neutrophilic to lymphoplasmacytic rhinitis with intralesional cocci, fibrin clots, and fibrinohemorrhagic exudate, which was consistent with an abscess. The cat began receiving buprenorphine to manage signs of pain and empirically prescribed clindamycin (10 mg/kg [4.5 mg/lb], PO, q 12 h) and was discharged from the hospital.

The cat was returned for reevaluation after 3 weeks of antimicrobial treatment. The cat was clini-

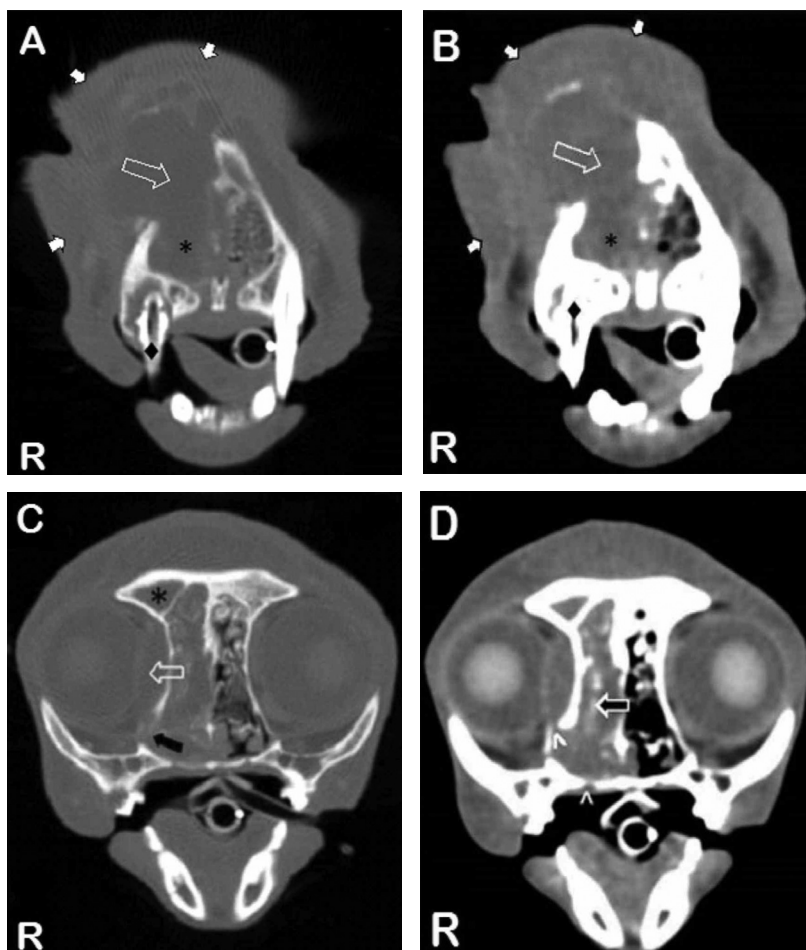


Figure 2—Same CT images as in Figure 1. A and B—Soft tissue-attenuating material (*) is evident within the right nasal cavity with adjacent lysis of the right frontal and maxillary bones (open arrow). The soft tissue-attenuating material causes distortion and extends dorsally into the extranasal soft tissue (white arrows). There is gas within the pulp cavity of the right maxillary canine tooth (diamond). C—There is lysis of the ventromedial aspect of the right orbital rim (black arrow), with soft tissue-attenuating material extending into the orbit and resulting in lateral displacement of the globe (open arrow). Notice the soft tissue-attenuating material that extends dorsally and into the frontal sinus (*). D—Infraorbital rim contrast enhancement (black arrow) is evident. There is multifocal lysis of the adjacent right orbital rim and hard palate (accent marks). Notice in all images the extensive lysis and nearly complete absence of nasal turbinates on the right side.

cally improved with decreased facial swelling, absence of palpable bone deformity, and independent eating (ie, without the esophageal feeding tube). On repeated CT, resolution of the soft tissue-attenuating material within the nasal cavity was evident, revealing atrophy of the nasal turbinates, as well as partial remineralization of the frontal bone, orbit, and cribriform plate. Alveolar bone lysis surrounding the right maxillary canine tooth and gas within the pulp cavity were present, which was consistent with a tooth root abscess.

The cat was returned 2 weeks after repeated CT for dental cleaning and extraction of the right maxillary teeth (third incisor tooth, canine tooth, second through fourth premolar teeth, and first molar tooth), left maxillary second incisor tooth, left mandibular canine tooth,

and right mandibular fourth premolar tooth. Bacteriologic culture of a swab specimen of the affected alveolar bone yielded growth of *Pasteurella multocida*.

At reevaluation 2 weeks following dental cleaning and tooth extractions, the cat had complete resolution of clinical signs and antimicrobial treatment was discontinued. The cat had no recurrence of ocular or nasal discharge at 6 months following dental extractions.

Comments

Diagnosis of a tooth root abscess in cats is typically made by oral examination and dental radiography, with common radiographic signs including surrounding alveolar bone loss and periapical lucency, typically representing granulation tissue.¹ However, given the concern for an invasive process involving the nasal cavity and skull in the cat of the present report, CT was chosen for superior structural discrimination. To our knowledge, this is the first CT description of intranasal disease secondary to a tooth root abscess in a cat. However, CT changes found in the case described in the present report were consistent with those described for a guinea pig, including focal alveolar bone lysis and involvement of the adjacent maxillary bone.² A lytic lesion in association with the caudal aspect of the tooth root on the CT images was consistent with radiographic descriptions of tooth root abscesses.¹ As observed in both the guinea pig² and this cat, lesions may extend beyond the affected tooth. In contrast to findings for the guinea pig, periosteal reaction was not a predominant feature in this cat; bacteriologic culture, however, was not performed in the previous report, and it is likely that infection with different organisms or different degrees of chronicity may result in varied structural changes. Gas within the affected tooth pulp cavity, seen by use of CT, is an uncommon finding. Relative to many cats with dental disease, the CT findings for the cat of the present report were unique in their destructive nature, likely related to chronicity and secondary osteomyelitis from a *P multocida* infection.

Although signs of tooth root abscess were observed, neoplasia was the primary differential diagnosis for this cat because of the additional CT findings of bony lysis involving the orbit, frontal bone, and palate.³⁻⁵ Unilateral bone loss and ipsilateral tooth loss are most common in cats with neoplasia^{3,5}; these findings were also found, however, for the cat of the present report. Changes predictive for neoplasia include unilateral soft tissue opacity with expansive bone destruction,⁴ which were also evident in the CT images presented here. Dental disease is a common concurrent problem in cats with primary nasal disease, affecting more than 50% of cats in 1 study,⁶ but dental disease is a less common cause of predominant signs of nasal disease (4%).⁶ On repeated CT, resolution of lesions, aside from those related to the tooth root abscess, was critical to obtain an accurate diagnosis and treatment for the cat of the present report. The CT imaging series of this cat highlighted the importance of considering dental disease as a potentially treatable differential diagnosis in cats with severe, chronic nasal disease.

Footnotes

- a. LightSpeed Ultra, GE Healthcare, Waukesha, Wis.

References

1. Niemiec BA. Unusual forms of periodontal disease In: *Veterinary periodontology*. Ames, Iowa: John Wiley and Sons, Inc, 2013;91-104.
2. Souza M, Greenacre C, Avenell J, et al. Diagnosing a tooth root abscess in a guinea pig (*Cavia porcellus*) using micro computed tomography imaging. *J Exot Pet Med* 2006;15:274-277.
3. Henderson SM, Bradley K, Day MJ, et al. Investigation of nasal disease in the cat—a retrospective study of 77 cases. *J Feline Med Surg* 2004;6:245-257.
4. Lamb CR, Richbell S, Mantis P. Radiographic signs in cats with nasal disease. *J Feline Med Surg* 2003;5:227-235.
5. O'Brien RT, Evans SM, Wortman JA, et al. Radiographic findings in cats with intranasal neoplasia or chronic rhinitis: 29 cases (1982-1988). *J Am Vet Med Assoc* 1996;208:385-389.
6. Demko JL, Cohn LA. Chronic nasal discharge in cats: 75 cases (1993-2004). *J Am Vet Med Assoc* 2007;230:1032-1037.