

What Is Your Diagnosis?

In cooperation with

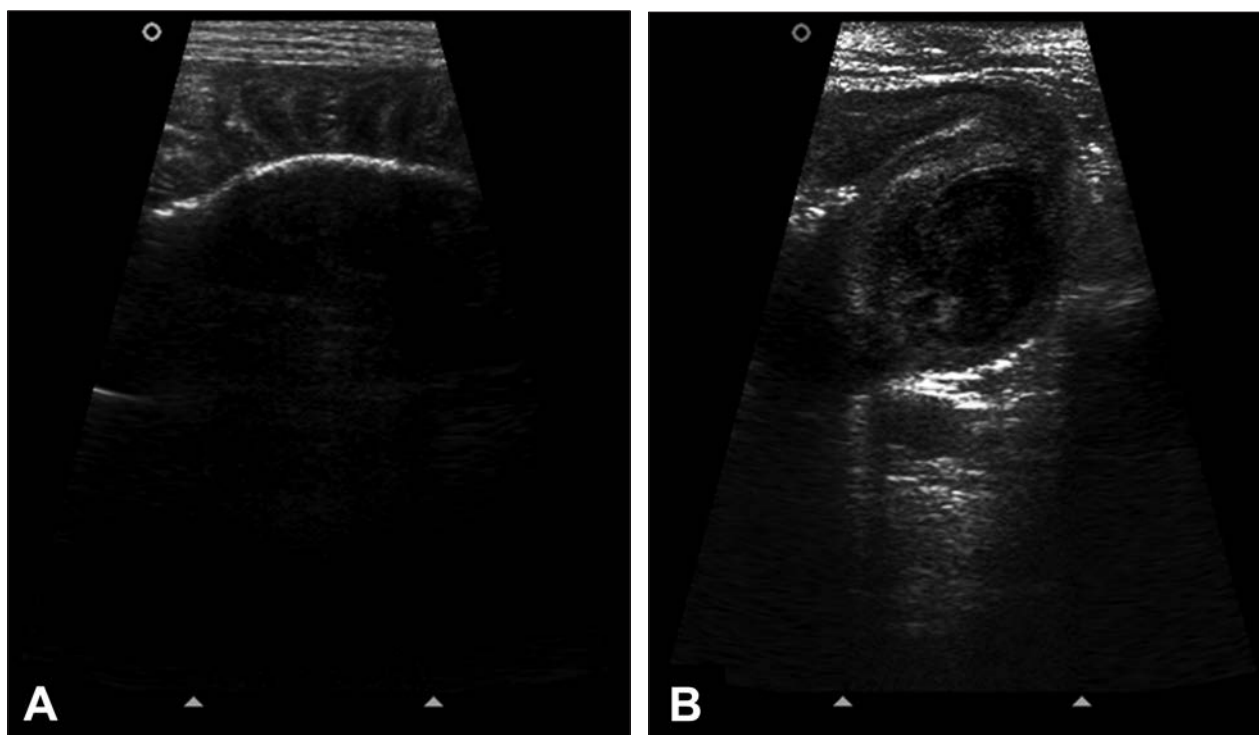


Figure 1—Longitudinal ultrasonographic images of the small intestine of a 2-year-old English Bulldog with a 4-day history of inappetence and vomiting. Images were obtained via a transabdominal approach with a 10-MHz linear transducer.

History

A 2-year-old 18-kg (39.6-lb) sexually intact male English Bulldog was evaluated because of a 4-day history of inappetence and vomiting. The owner reported the dog to be a frequent scavenger; hence, the possibility of foreign body ingestion could not be ruled out. The dog was mildly dehydrated (6%), had congested mucous membranes, and had apparent signs of pain on abdominal palpation. Abdominal ultrasonography was performed (Figure 1).

Determine whether additional imaging studies are required, or make your diagnosis from Figure 1—then turn the page →

This report was submitted by Daniel Capucho de Oliveira, DVM, MSc; Carlos Henrique do Amaral, DVM, MSc; and Tilde Rodrigues Froes, DVM, PhD; from the Department of Veterinary Medicine, Federal University of Paraná, Cabral, Curitiba, PR 80035-050, Brazil. The authors thank Dr. Denise de Oliveira and Dr. César Augusto Ranzani for assistance in case management. Address correspondence to Dr. Capucho de Oliveira (danielcapucho@gmail.com).

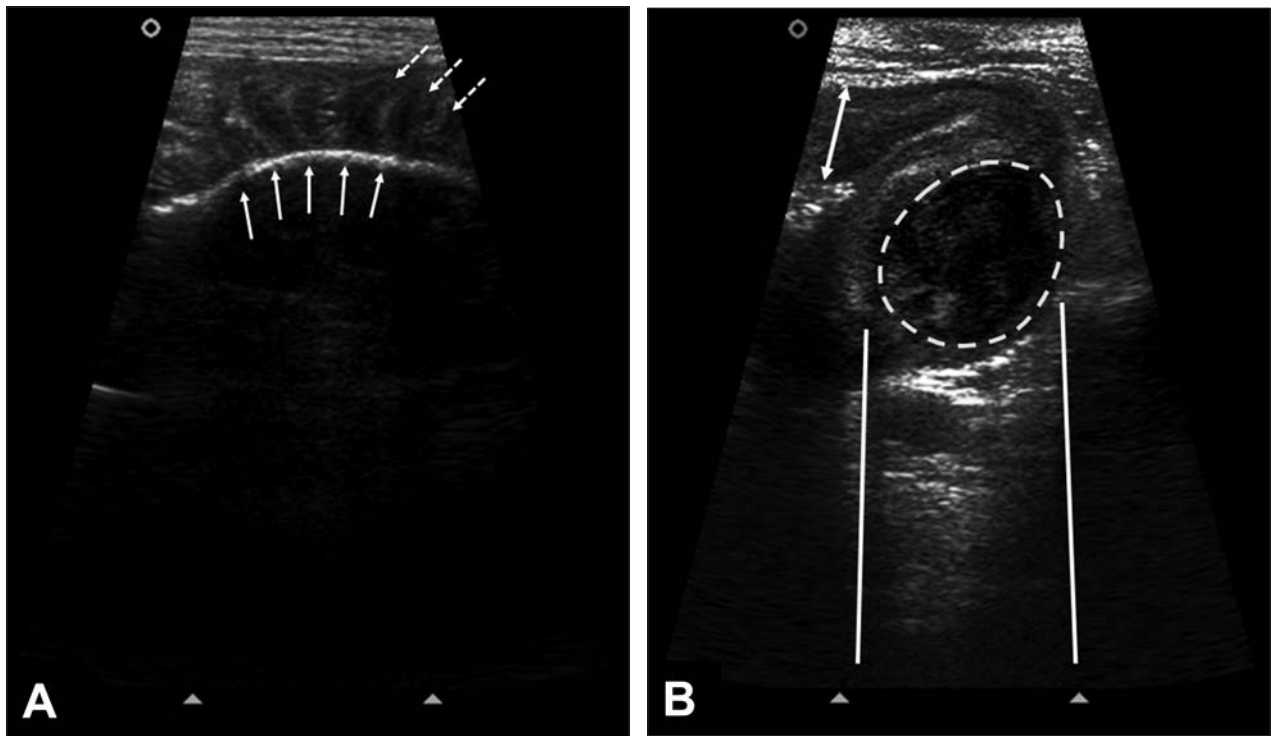


Figure 2—Same ultrasonographic images as in Figure 1. A—There is a linear hyperechoic interface in the intestinal lumen (solid arrows) casting an acoustic shadow, and intestinal plication is evident (dashed arrows). B—Notice that the intestinal wall is thick (double arrow). A hypoechoic heterogeneous circular structure (dashed line), associated with distal acoustic enhancement (solid lines), is evident and is located in the muscularis layer of the intestine.

Diagnostic Imaging Findings and Interpretation

On ultrasonographic images, there is a long hyperechoic structure casting a strong acoustic shadow (Figure 2) and some parts of the duodenum and jejunum appear dilated. Small intestinal plication is also present. In the small intestine, there is a round hypoechoic structure, approximately 2.2 cm in diameter, originating from the muscularis intestinal layer. This structure appears mildly heterogeneous, slightly hyperechoic to the muscularis layer, and hypoechoic to the submucosa. The mesentery adjacent to the intestinal lesion is hyperechoic.

No vascularization of the structure was visible on color flow Doppler ultrasonography. The main differential diagnosis was intestinal obstruction caused by a linear foreign body with the formation of an intramural intestinal abscess or hematoma and mild focal peritonitis.

Abdominal radiography was performed to further investigate the suspected intestinal obstruction (Figure 3). In addition to radiographic signs of a linear intestinal foreign body, a heterogeneous soft tissue structure filled the stomach, and therefore a concomitant gastric foreign body was also considered likely. A small, cylindrical, radiopaque intestinal foreign body measuring 2.6 × 2.2 cm was evident. The foreign body was located in a small intestinal segment in the caudoventral aspect of the abdomen, close to the urinary bladder.

Treatment and Outcome

Exploratory laparotomy was performed, and a linear foreign body (piece of cloth) was found in the

stomach, duodenum, and proximal portion of the jejunum with a small perforation and intramural abscess in the jejunum. Mild focal peritonitis was associated with the intramural abscess. The linear foreign body was removed by gastrotomy, and the perforated intestine and associated abscess were removed by enterectomy. A cylindrical foreign body (rubber toy) was also found in the distal portion of the jejunum and removed by enterotomy. The dog recovered well and was discharged from the hospital on the fourth day after surgery.

Comments

The formation of intestinal-related abscesses is a rare phenomenon, and in humans, it can occur as a consequence of intestinal perforation by peptic ulcers or foreign bodies.^{1,2} Intramural intestinal abscesses are described in patients with intestinal ulcerations or chronic inflammatory bowel disease.^{1,3} To our knowledge, there is only 1 report⁴ of an intra-abdominal abscess in a dog, which was located external to the serosa of the jejunum and caused intestinal obstruction.

It is not always possible to differentiate an abscess from a hematoma on ultrasonography because they have similar ultrasonographic appearances.⁵ Depending on the ultrasonographic characteristics of the lesion, a diagnosis of neoplasia may also need to be considered.⁵ In the dog of the present report, the diagnosis of neoplasia was excluded because of the age of the dog and signs of foreign body obstruction on imaging. Radiographic examination identified intestinal plication and a radiopaque foreign body.

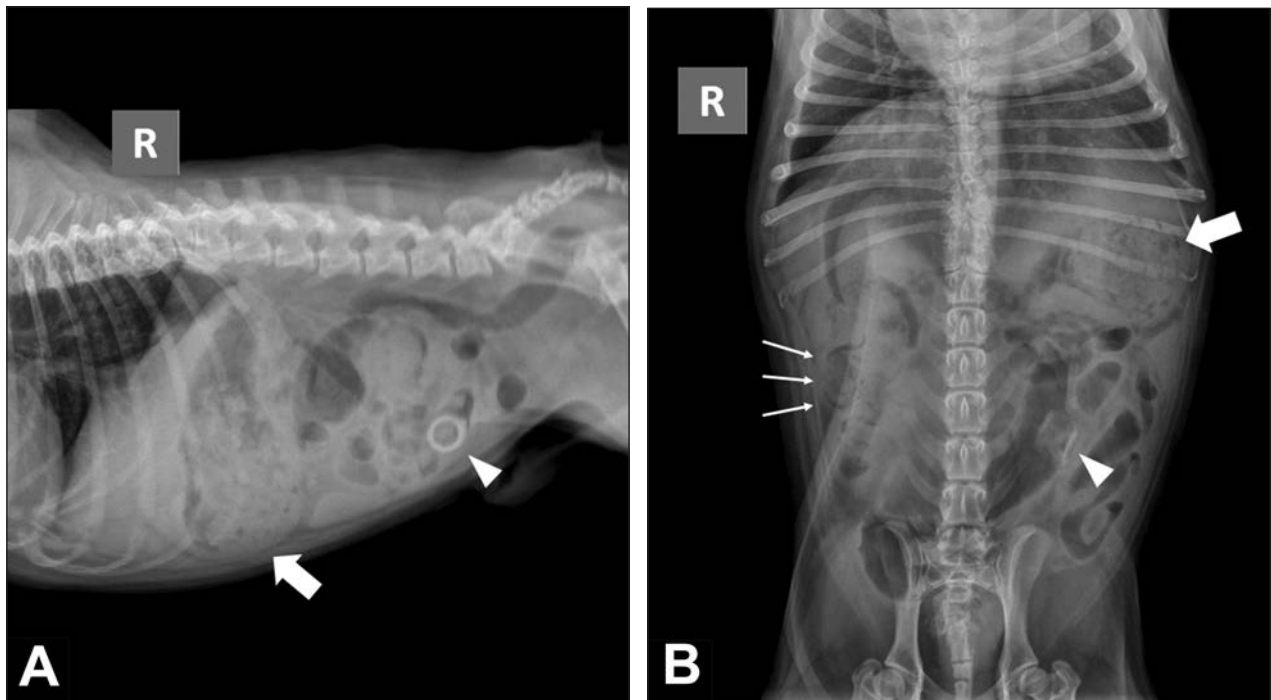


Figure 3—Right lateral (A) and ventrodorsal (B) radiographic views of the abdomen of the dog of Figure 1. A heterogeneous soft tissue structure fills the stomach (large arrow). A small, cylindrical, radiopaque intestinal foreign body is located in a small-intestinal segment located in the left caudal portion of the abdomen (arrowhead). There is also an area of intestinal plication seen on the ventrodorsal projection (small arrows).

We opted to start the imaging evaluation with an ultrasonographic examination. This choice is supported by the recent literature, which states that ultrasonography is more accurate than survey abdominal radiography for diagnosing small-intestinal foreign bodies, especially radiolucent ones.^{6,7} The ultrasonographic identification of gastrointestinal foreign bodies, however, can be difficult as a result of the presence of intraluminal intestinal gas.⁶ Also, operator experience may impact the ability to recognize foreign bodies ultrasonographically.⁶

Abdominal radiography is an accurate imaging modality in the identification of small-intestinal mechanical obstruction in vomiting dogs, but it does not detect the cause of the obstruction in most instances, except with radiopaque foreign bodies.⁶ In the dog of the present report, the radiopaque foreign body was identified only in the radiographic examination, demonstrating the importance of complementing ultrasonographic examination with survey radiography. The detection of the radiopaque foreign body changed the surgical planning but did not affect the management of the patient.

To our knowledge, the only previous report² of an abscess related to a foreign body was the result of accidental ingestion of a toothpick by a person, which caused intestinal injury and led to intra-abdominal ab-

cess formation. Any perforating lesion in the intestine can result in abscess formation, given that the intestinal lumen contains numerous bacteria, which can be carried to the deeper layers of the intestine or to the peritoneum.⁸ The intramural intestinal abscess in the dog of the present report was likely the result of mucosal perforation caused by the linear foreign body.

1. Albu E, Moreira D, Faltous A, et al. Intramural abscess of the duodenum resulting from perforated peptic ulcer. *South Med J* 1995;88:1078–1080.
2. Su Y-J, Lai Y-C, Chen C-C, et al. Intra-abdominal abscess caused by toothpick injury. *Int J Infect Dis* 2009;13:e264–e266.
3. Valette P-J, Rioux M, Pilleul F, et al. Ultrasonography of chronic inflammatory bowel diseases. *Eur Radiol* 2001;11:1859–1866.
4. Wolfe DA, Meyer CW. Obstructing intestinal abscess in a dog. *J Am Vet Med Assoc* 1975;166:518–519.
5. Heng HG, Huang A, Baird DK, et al. Imaging diagnosis—spontaneous intramural canine duodenal hematoma. *Vet Radiol Ultrasound* 2010;51:178–181.
6. Tyrrell D, Beck C. Survey of the use of radiography vs. ultrasonography in the investigation of gastrointestinal foreign bodies in small animals. *Vet Radiol Ultrasound* 2006;47:404–408.
7. Garcia DAA, Froes TR, Vilani RGDOC, et al. Ultrasonography of small intestinal obstructions: a contemporary approach. *J Small Anim Pract* 2011;52:484–490.
8. Longo DL, Kasper DL, Jameson JL, et al, eds. *Harrison's principles of internal medicine*. 18th ed. New York: McGraw-Hill Professional, 2011.