

Laparoscopic inguinal hernioplasty in a ram

Alexander J. Daniel, DVM, MS; Jeremiah T. Easley, DVM; Timothy N. Holt, DVM;
John C. Huhn, DVM, MS; Eileen S. Hackett, DVM, PhD

Case Description—A 4-month-old Hampshire ram underwent open right inguinal herniorrhaphy and unilateral castration following herniation that developed after a kick injury. Seven months later, the ram was reevaluated because of scrotal swelling of 1 month's duration as well as suspected left inguinal hernia.

Clinical Findings—The ram had marked scrotal swelling. Palpation of the left testicle revealed no abnormalities. Ultrasonographic examination revealed heterogenous tissue within the cranial and medial portions of the scrotum with pronounced accumulation of hypochoic fluid at the scrotal apex. Examination findings indicated left-sided indirect inguinal herniation of omentum.

Treatment and Outcome—To preserve fertility, left inguinal hernioplasty without castration was performed. The ram was anesthetized and placed in dorsal recumbency, and laparoscopic abdominal evaluation revealed omental entrapment within the left inguinal ring. The omentum was removed, and a polypropylene mesh was secured over the internal inguinal ring with an articulating hernia stapler. Following mesh placement, a dorsally based peritoneal flap was elevated and secured over the mesh repair. The ram recovered well from surgery; there was no repeated herniation following the surgical correction, and the ram was able to breed successfully without complication.

Clinical Relevance—Laparoscopic mesh hernioplasty can be successful in rams with inguinal hernias when preservation of fertility is preferred. (*J Am Vet Med Assoc* 2015;246:1118–1121)

A 4-month-old 53-kg (117-lb) Hampshire ram was evaluated at the Colorado State University Veterinary Teaching Hospital because of right-sided scrotal swelling that developed following a kick injury 1 week prior. Palpation and ultrasonography of the scrotum were performed both with the ram standing and under anesthesia. Results indicated the presence of a scrotal hematoma, and the ram was treated medically with cold hydrotherapy and administration of NSAIDs and antimicrobials. One month after initial evaluation, the ram was returned to the hospital because of persistent right-sided scrotal swelling. Palpation and ultrasonography of the scrotum were repeated and revealed right-sided omental herniation, which was treated with unilateral open herniorrhaphy with orchiectomy under anesthesia as has been described previously.¹ The omentum was partially resected at the time of orchiectomy because of adhesions to the testicle, and the remaining omentum was then reduced prior to herniorrhaphy. Careful palpation of the left inguinal ring and scrotal compartment was performed, and no abnormalities were detected. Ultrasonographic examination of the left inguinal ring was not performed. No postsurgical complications were observed, and the ram successfully bred after surgery.

At 11 months of age (weight, 98 kg [216 lb]), the ram was reevaluated because of intermittent left-sided scrotal swelling of approximately 1 month's duration. The site of the previous surgery had healed, and the right inguinal ring was closed. Palpation of the enlarged left scrotal compartment revealed an apparently normal testicle. Ultrasonography revealed heterogenous tissue present on the medial and cranial aspects of the scrotum that obscured the underlying testicle and some hypochoic fluid that had accumulated at the scrotal apex. The primary differential diagnosis was left-sided indirect inguinal herniation of omentum. After discussion with the owner, which included ethics of repair in light of the heritable potential of the condition, a laparoscopic hernioplasty without orchiectomy was authorized.

Results of presurgical hematologic and serum biochemical analyses indicated mild anemia (Hct, 31% [reference interval, 40% to 45%]; RBC count, 10.1×10^6 RBCs/L [reference interval, 11.5×10^6 RBCs/L to 17.5×10^6 RBCs/L]; and hemoglobin concentration, 11.9 g/dL [reference interval, 13.0 to 15.8 g/dL]) and mildly high creatine kinase activity (404 U/L; reference interval, 100 to 300 U/L). The clinicopathologic abnormalities identified were mild and did not imply serious underlying disease, although mild anemia could have been consistent with chronic inflammation and decreased erythrocyte production from bone marrow.

Prior to surgery, food was withheld from the ram for 48 hours and water was withheld for 12 hours. On the morning of surgery, a jugular venous catheter was placed and the ram was administered flunixin meglumine (1.1 mg/kg [0.5 mg/lb], IV) and tulathromycin (2.5 mg/kg [1.1 mg/lb], SC). Anesthesia was induced

From the Department of Clinical Sciences, College of Veterinary Medicine and Biomedical Sciences, Colorado State University, Fort Collins, CO 80523 (Daniel, Easley, Holt, Hackett); and Covidien Animal Health, 555 Long Wharf Dr, New Haven, CT (Huhn).

Supported in part by the Colorado State University Critical Care Education and Research Fund.

Address correspondence to Dr. Hackett (Eileen.Hackett@colostate.edu).

with diazepam (0.1 mg/kg [0.045 mg/lb], IV) and ketamine hydrochloride (4.0 mg/kg [1.8 mg/lb], IV) and maintained with sevoflurane (2% to 4%) in oxygen via an orotracheal tube. During anesthesia, a constant rate infusion of ketamine (20 µg/kg/min [9.1 µg/lb/min])

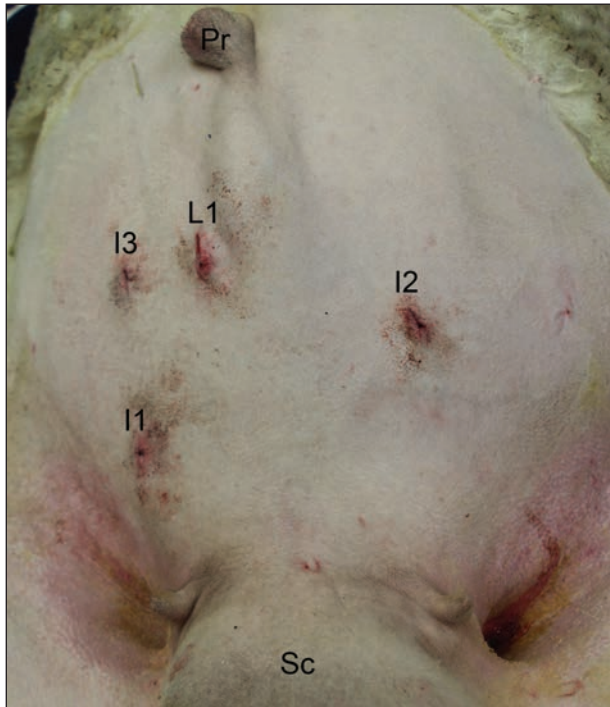


Figure 1—Photograph of the shaved ventrum of an 11-month-old Hampshire ram that was evaluated because of intermittent left-sided scrotal swelling of approximately 1 month's duration. The ram had undergone open right inguinal herniorrhaphy and unilateral castration following traumatic herniation that developed following a kick injury 7 months prior. The primary differential diagnosis at this time was left-sided indirect inguinal herniation of omentum. After discussion with the owner regarding ethical considerations of repair without castration in light of the heritable potential of the condition, a laparoscopic hernioplasty without orchiectomy was performed. In this view, the locations of the laparoscopic (L1) and instrument (I1, I2, and I3) portals are shown. Cranial is to the top of the image; the prepuce (Pr) and affected left scrotal compartment (Sc) are visible.

and lidocaine (20 µg/kg/min [9.1 µg/lb/min]) was administered. Anesthetic monitoring included ECG, pulse oximetry, capnography, arterial blood gas analyses, and both direct and indirect blood pressure measurements. Intermittent positive pressure ventilation was started prior to surgical incision and continued until the end of surgery. The ram was placed in dorsal recumbency and secured to a surgical table with ability to tilt the animal into Trendelenburg position. Hair was clipped from the xiphoid process to the pubis and lateral to the flank. The left testicle was carefully retracted caudad and secured to prevent contamination of the surgical field. Aseptic surgical site preparation (alternating scrubs of 7.5% povidone-iodine solution and alcohol) was performed prior to draping.

The prepuce was retracted to the left side, and a No. 15 blade was used to make a stab incision through the skin and external sheath of the rectus abdominis muscle, 15 cm caudal to the umbilicus. A teat cannula was inserted through the peritoneum, and insufflation with CO₂ performed to a pressure of 10 to 12 mm Hg. The incision was enlarged to allow insertion of an 11-mm threaded cannula^a into the abdomen (laparoscope portal). A 10-mm, 30°, 33-cm rigid laparoscope^b was inserted through this cannula, and the ram was tilted into Trendelenburg position with the table at approximately 15°. Based on triangulation, 2 instrument portals were created in identical fashion (Figure 1) for additional 11-mm threaded cannulas. A third instrument portal was created for passage of a 12-mm laparoscopic cannula.^c The left inguinal ring was identified, and omentum was evident passing through the ring (Figure 2). By use of 2 laparoscopic Babcock forceps placed in the instrument portals, the omentum was carefully removed from the inguinal ring until the underlying vas deferens and pampiniform plexus could be visualized. A laparoscopic fan retractor^d was used to retract the omentum away from the inguinal ring during the remainder of the surgical procedure. It was inserted alternately through the first and second instrument portals to facilitate retraction. A 3 × 2-inch section of polypropylene mesh^e was then rolled up and passed through the second instrument portal with the Babcock forceps. It was secured over the internal inguinal

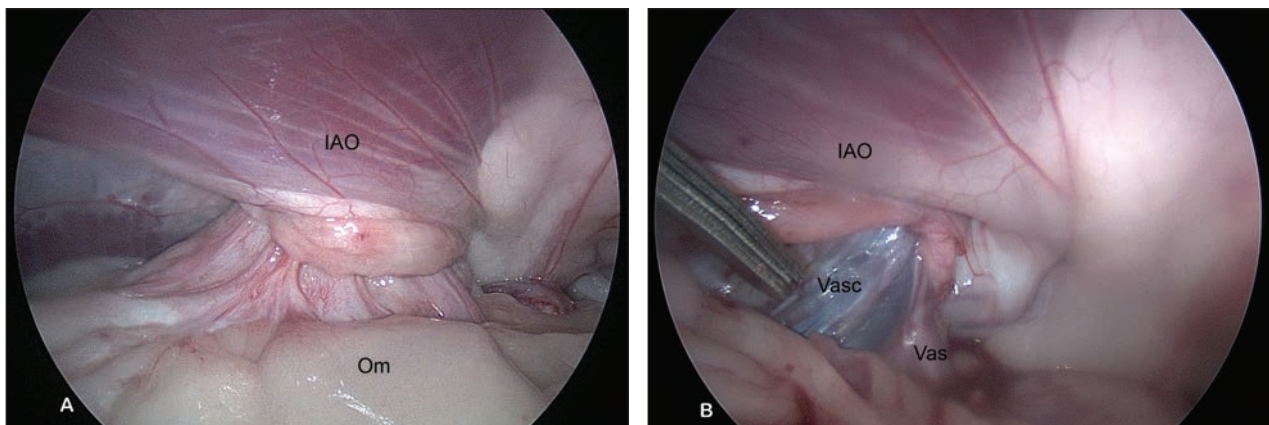


Figure 2—Laparoscopic images obtained during surgery in the ram in Figure 1. A—Laparoscopic view of the left internal inguinal ring. The internal abdominal oblique muscle (IAO) is visible with omentum (Om) passing through the opening of the internal inguinal ring. B—Laparoscopic view after removal of omentum from the inguinal ring with Babcock forceps. The pampiniform plexus (Vasc) and vas deferens (Vas) can be seen.

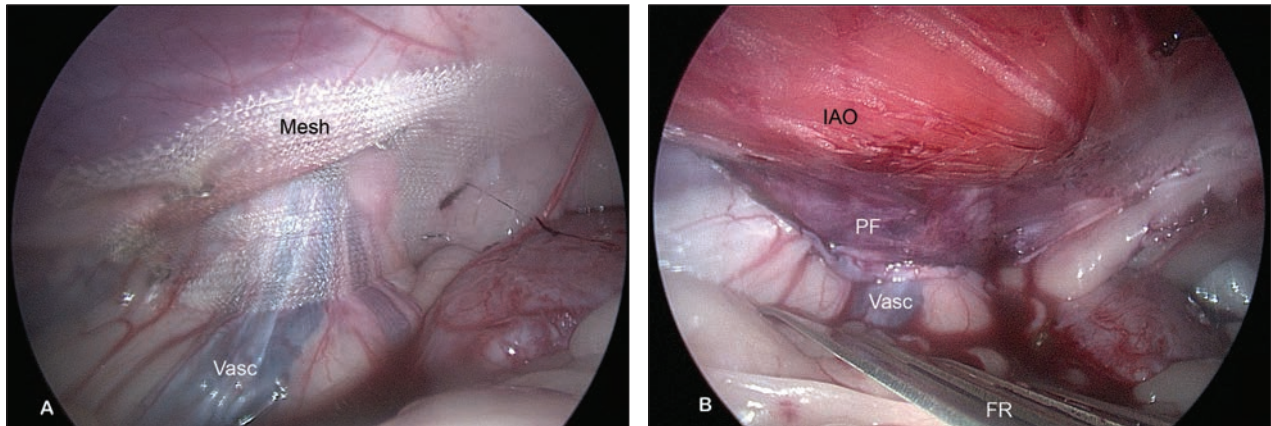


Figure 3—Additional laparoscopic images obtained during surgery in the ram in Figure 1. A—A polypropylene mesh (2 X 3 inches) has been introduced and stapled over the internal inguinal ring. The pampiniform plexus (Vasc) can be seen underneath the mesh. B—A peritoneal flap (PF) was dissected free with its base oriented dorsally exposing the underlying internal abdominal oblique muscle (IAO). This was then stapled over the polypropylene mesh. A fan retractor (FR) was used to retract the omentum away from the inguinal ring during the surgical procedure.

ring with a 12-mm laparoscopic stapler^f passed through the third instrument portal (Figure 3). A section of peritoneum extending 2 cm cranial and 2 cm caudal to the inguinal ring with its base oriented dorsally was created with laparoscopic scissors. After careful dissection, the peritoneal flap was then secured over the polypropylene mesh to the cranial, craniodorsal, caudodorsal, and caudal margins of the internal inguinal ring with the laparoscopic stapler.^f The ram was returned to normal dorsal recumbency, and gas was expressed from the abdomen before cannula removal. The abdominal incisions were closed with size 0 glycolide-lactide copolymer braided absorbable multifilament suture^g in the external sheath of the rectus abdominis muscle with cruciate sutures and intradermal sutures were placed with 2-0 glycolide-dioxanone-trimethylene carbonate monofilament absorbable suture.^h

The ram recovered uneventfully from anesthesia. The day after surgery, the left testicle seemed normal on palpation and the scrotum was markedly reduced in size. Ultrasonography of the scrotum revealed a small amount of hypoechoic fluid and no evidence of herniated tissue. The left testicle appeared normal, and the medial or cranial aspects (which had been previously obscured by the herniated tissue) were visible and without abnormalities. A breeding soundness examination was performed 5 months after surgery; spermatozoa count and motility were adequate, and the ram returned to breeding. The incision sites had healed well, and there was no recurrence of the scrotal hernia.

Discussion

Indirect inguinal hernia formation in rams, a condition often referred to as scrotal hernia, accounts for up to 7% of congenital disorders² and up to 15% of all hernias in sheep.³ Proposed causes include a genetic trait,⁴ trauma,^{3,5,6} and old age.⁷ The ram described in the present report was initially kicked, suggesting trauma as the sole cause of the right-sided herniation; however, the development of left-sided herniation after herniorrhaphy and orchietomy on the right side could indicate

a heritable component. Heritability of this condition is poorly understood.⁵ Congenital scrotal hernias are much more rare than those acquired via trauma, where injury during mounting behavior is often implicated in affected rams.^{3,5} As a routine measure, frank discussions between veterinarians and owners are critical to ensure ethics are considered prior to surgical repair of a potentially heritable condition in a breeding animal.

Surgical correction of scrotal hernias in rams has typically been achieved by means of herniotomy, herniorrhaphy, and unilateral orchietomy.^{1,3-5,8-12} Attempts to perform herniorrhaphy by suturing the inguinal ring without orchietomy on the affected side can cause narrowing of the inguinal ring and, in rams, has resulted in ischemia of the testis on the affected side.³ Because orchietomy is not always desired by owners, laparoscopic inguinal hernioplasty without orchietomy to prevent inguinal herniation in other species has been described with reported use of cyanoacrylate glue,¹³ polypropylene mesh,^{14,15} intracorporeal sutures,¹⁶ or peritoneal flaps.^{17,18} The success rates of those approaches are high, with no apparent effect on fertility. A combination of these techniques was adopted in the case described here by combining both polypropylene mesh and peritoneal hernioplasty. Use of polypropylene mesh results in repair strength superior to tissue reconstruction, with resulting lower recurrence rates.¹⁹ Peritoneal overlay prevents visceral mesh contact and provides additional security to the hernioplasty procedure. It is possible that use of just one of these techniques and not both may have been sufficient for the clinical syndrome described in this report, although it is our experience that peritoneal hernioplasty has been associated with failures when used in livestock animals.

The omentum was herniated at the time of both surgeries in the ram of this report. During the first surgery (open herniotomy), the omentum was partially resected at the time of orchietomy because of adhesions to the testicle, and the remaining omentum was then reduced prior to herniorrhaphy. Fortunately, during the second surgery, no adhesions were present between the omentum and scrotal tissues and the omentum was re-

moved from the scrotum and inguinal ring with laparoscopic instruments alone. In humans and horses, due to risks of damage to tissues when applying traction with laparoscopic instruments, a hand-assisted laparoscopic surgery can be performed.^{20–24} The improved tactile sensation and dexterity afforded by a hand-assisted technique helps reduce damage to tissues. This was considered as a possible alternative during surgical planning in the case described in this report; however, it must be considered that a specialized portal is required to maintain insufflation.²⁰

Results of a previous study²⁵ in horses indicated that Trendelenburg positioning for laparoscopy with abdominal insufflation increases PaCO₂, decreases PaO₂, decreases arterial blood pH, and increases mean arterial blood pressure. During the surgical planning of the second surgery in the ram of the present report, these complications were anticipated because of the positioning and necessitated the ability to provide positive pressure ventilation to the patient. This was unlike some previously reported cases where rams with scrotal hernia were treated with tranquilization and local anesthesia.³ There were no complications related to anesthesia for the ram of the present report.

The specialized surgical equipment required may preclude the widespread use of this technique in rams due to associated costs. However, to the authors' knowledge, this is the first report of successful laparoscopic hernioplasty in a ram. Although larger case numbers would be required to evaluate long-term effectiveness, based on success rates in other species, laparoscopic hernioplasty should be considered as an alternative to herniorrhaphy with orchietomy in rams.

- a. Storz Endo Tip Cannula, Karl Storz, Tuttlingen, Germany.
- b. Forward-Oblique Telescope 30°, Karl Storz, Tuttlingen, Germany.
- c. Endopath XCEL TROCAR 12 mm, Ethicon, Somerville, NJ.
- d. Laparoscopic Fan Retractor, Surgical Direct, DeLand, Fla.
- e. Surgipro Flat Sheet mesh SPM-149, Covidien, Mansfield, Mass.
- f. Endo universal, 4.0 mm, 65°, 12 mm diameter, Covidien, Mansfield, Mass.
- g. Polysorb, Covidien Animal Health, Mansfield, Mass.
- h. Biosyn, Covidien Animal Health, Mansfield, Mass.

References

1. Radišić B, Capak D, Matičić D, et al. Surgical treatment of a unilateral scrotal hernia in a ram—a case report. *Veterinarski Arh* 2010;80:145–154.
2. Greber D, Doherr M, Drogemuller C, et al. Occurrence of congenital disorders in Swiss sheep. *Acta Vet Scand* 2013;55:27.
3. Al-Sobayil FA, Ahmed AF. Surgical treatment for different forms of hernias in sheep and goats. *J Vet Sci* 2007;8:185–191.
4. Roberts SJ. Scrotal hernia in rams. *Cornell Vet* 1988;78:351–352.
5. Braun WF, Cole WJ. Unilateral scrotal hernia repair in a ram lamb. *J Am Vet Med Assoc* 1985;187:500.
6. Orr AE. Inguinal hernia in sheep. *Vet Rec* 1956;68:2–4.
7. St Jean G. Male reproductive surgery. *Vet Clin North Am Food Anim Pract* 1995;11:55–93.
8. Capak D, Radišić B, Vnuk D, et al. Unilateral scrotal hernia in ram, in *Proceedings. XVI Cong Mediterr Fed Health Prod Rumin* 2008;313–316.
9. Chaudhry NI. Scrotal hernia in rams. *Pak Vet J* 1981;1:124–126.
10. Prasad B, Singh J, Kohli RN. Scrotal hernia in a Corriedale ram. *Indian Vet J* 1978;55:68–69.
11. Ramakrishna O, Rao KV. Scrotal hernia in a Corriedale ram. *Indian J Anim Health* 1982;21:135–136.
12. Singh J, Prasad B, Rathor SS. Oscheocele in a ram. *Haryana Vet* 1975;14:105–106.
13. Rossignol F, Mespoulhes-Riviere C, Vitte A, et al. Standing laparoscopic inguinal hernioplasty using cyanoacrylate for preventing recurrence of acquired strangulated inguinal herniation in 10 stallions. *Vet Surg* 2014;43:6–11.
14. Caron JP, Mehler SJ. Laparoscopic mesh incisional hernioplasty in five horses. *Vet Surg* 2009;38:318–325.
15. Mariën T. Standing laparoscopic herniorrhaphy in stallions using cylindrical polypropylene mesh prosthesis. *Equine Vet J* 2001;33:91–96.
16. Caron JP, Brakenhoff J. Intracorporeal suture closure of the internal inguinal and vaginal rings in foals and horses. *Vet Surg* 2008;37:126–131.
17. Wilderjans H, Meulyzer M, Simon O. Standing laparoscopic peritoneal flap hernioplasty technique for preventing recurrence of acquired strangulating inguinal herniation in stallions. *Vet Surg* 2012;41:292–299.
18. Rossignol F, Perrin R, Boening KJ. Laparoscopic hernioplasty in recumbent horses using transposition of a peritoneal flap. *Vet Surg* 2007;36:557–562.
19. Pott PP, Schwarz ML, Gundling R, et al. Mechanical properties of mesh materials used for hernia repair and soft tissue augmentation. *PLoS One* 2012;7:e46978.
20. Targarona EM, Gracia E, Rodriguez M, et al. Hand-assisted laparoscopic surgery. *Arch Surg* 2003;138:133–141.
21. Witte TH, Wilke M, Stahl C, et al. Use of a hand-assisted laparoscopic surgical technique for closure of an extensive mesojejunal rent in a horse. *J Am Vet Med Assoc* 2013;243:1166–1169.
22. Muñoz J, Bussy C. Standing hand-assisted laparoscopic treatment of left dorsal displacement of the large colon and closure of the nephrosplenic space. *Vet Surg* 2013;42:595–599.
23. Goodin JT, Rodgerson DH, Gomez JH. Standing hand-assisted laparoscopic ovariectomy in 65 mares. *Vet Surg* 2011;40:90–92.
24. Keoughan CG, Rodgerson DH, Brown MP. Hand-assisted laparoscopic left nephrectomy in standing horses. *Vet Surg* 2003;32:206–212.
25. Hofmeister E, Peroni JF, Fisher AT. Effects of carbon dioxide insufflation and body position on blood gas values in horses anesthetized for laparoscopy. *J Equine Vet Sci* 2008;28:549–553.