

Acute compartment syndrome in the pelvic limb of a cow following biopsy of a skeletal muscle–associated hemangiosarcoma

Susan R. Vogel, DVM; André Desrochers, DVM, DACVS; Isabelle Lanthier, DVM, DACVP;
Marion Strina, DVM; Marie Babkine, DVM

Case Description—A 6-year-old Holstein cow was examined because of chronic lameness and swelling near the stifle joint of the left pelvic limb.

Clinical Findings—A mass was palpated in the soft tissues lateral to the proximal aspect of the left tibia. Multiple attempts to obtain a biopsy specimen of the mass resulted in acute compartment syndrome of the femoral compartment (tensor fasciae latae and biceps femoris muscles) and lateral tibial compartment (cranial tibial and peroneus tertius muscles) with associated sciatic nerve paralysis.

Treatment and Outcome—Surgical decompression via tensor fasciae latae and biceps femoris incision resolved the sciatic nerve paralysis. On the fifth day following surgery, the cow began to develop signs of increased respiratory effort. Thoracic radiography revealed a pulmonary metastatic micronodular pattern. The cow was euthanized because its condition deteriorated. Metastatic hemangiosarcoma was confirmed at necropsy, and the primary tumor was the mass that was lateral to the tibia and within the biceps femoris muscle.

Clinical Relevance—Hemangiosarcoma should be considered a differential diagnosis for lameness in cattle when no orthopedic cause can be identified. Close patient surveillance is strongly recommended in the event that a vascular tumor is present because catastrophic consequences are possible. To our knowledge, this is the first report of acute compartment syndrome in a pelvic limb of a bovine patient and the only report of hemangiosarcoma in the skeletal muscle of cattle. (*J Am Vet Med Assoc* 2012;240:454–458)

A 6-year-old Holstein cow was evaluated at the teaching hospital because of lameness of the left pelvic limb of 2 months' duration. The owner first noticed a swelling near the lateral aspect of the stifle joint of that limb 3 months previously, and the lameness ensued thereafter. The cow had been treated on the farm with penicillin and flunixin meglumine administered IM, with minimal improvement of the lameness or size of the mass. The cow was referred after the swelling noticeably increased in size and failed again to respond to medical treatment.

On evaluation, the cow's body condition was adequate. It weighed approximately 700 kg (1,540 lb) and consistently had a lordotic stance. On physical examination, the cow was tachycardic and tachypneic with a heart rate of 100 beats/min and respiratory rate of 80 breaths/min. In association with the tachypnea, frequent bronchovesicular sounds were auscultated in all lung fields. The cow had subclinical mastitis in its front left quarter (positive California mastitis test score of 3 [range of test, 0 to 3]). The rumen was motile, and on rectal palpation, the cow was estimated to be 5 months pregnant. There was a mass on the left pelvic

limb just lateral and distal to the stifle joint measuring 30 × 15 × 6 cm. The mass was firm with softer pockets and well associated with the surrounding muscular and cutaneous tissues on palpation but did not appear to be painful to the cow. There was mild atrophy of the semitendinosus and semimembranosus muscles, but the cow was weight bearing on its left pelvic limb. Peroneal nerve paresis was noted as evidenced by knuckling at the metatarsophalangeal joint (fetlock joint). At a walk, the lameness was graded 2 of 5, where 1 is normal, 2 is an asymmetric gait, and 5 is non-weight-bearing lame.¹

On the day of evaluation, the following diagnostic tests were performed: routine bacterial culture of milk from all mammary glands; radiography of the left stifle joint; ultrasonography, cytologic examination, and bacterial culture of synovial fluid of the left stifle joint; and ultrasonography, biopsy, cytologic examination, and routine bacterial culture of the mass. On the radiographs, a well-defined soft tissue swelling cranial and lateral to the stifle joint was evident outside of the ligamentous and adipose tissues associated with the joint. There was no evidence of bony or joint involvement (Figure 1). Cytologic examination of the synovial fluid yielded a finding of blood contamination. On ultrasonographic examination, the stifle joint was mildly distended and the synovial fluid had a normal echogenicity. The mass was within the biceps femoris muscle, appeared heterogeneous, had poorly defined borders, and contained irregularly shaped pockets of fluid with a mixed echogenicity. The mass was considered

From the Departments of Clinical Sciences (Vogel, Desrochers, Strina, Babkine) and Pathology and Microbiology (Lanthier), Faculté de Médecine Vétérinaire, Université de Montréal, Saint-Hyacinthe, QC J2S 7C6, Canada. Dr. Vogel's present address is MED Institute Incorporated, 1 Geddes Way, West Lafayette, IN 47906. Dr. Strina's present address is Department of Clinical Sciences, VetAgro Sup, Veterinary Campus, Marcy-l'Étoile, France. Address correspondence to Dr. Vogel (svogel@medinst.com).

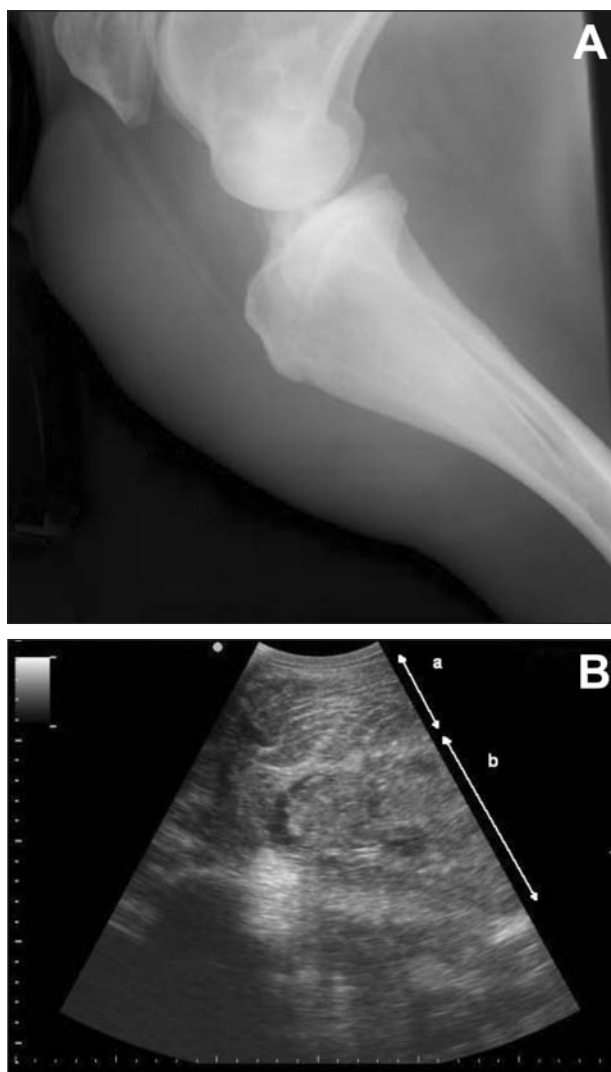

Figure 1—Diagnostic images obtained from a 6-year-old Holstein cow examined because of chronic lameness and swelling near the stifle joint of the left pelvic limb. A—Lateromedial radiographic view of the left stifle joint. There is marked thickening of the soft tissue cranial to the stifle joint and proximal to the tibia of uniform opacity. The thickening is well-defined proximally and more poorly defined distally. It is outside of the ligaments and adipose tissue of the stifle joint. No bony abnormalities are visible. B—Longitudinal ultrasonographic image of the mass (3.5-MHz curvilinear probe). The mass that is within the biceps femoris muscle is moderately heterogenic and visible lateral to the proximal aspect of the tibia and stifle joint. a = Normal skeletal muscle tissue. b = Mass within the skeletal muscle. Irregularly shaped pockets of fluid with a mixed echogenicity are visible within the mass.

consistent with a neoplasm or hematoma. Without sedation but following local infiltration of lidocaine with the cow in the standing position, multiple ultrasound-guided biopsy^a specimens were obtained. More than 1 biopsy was performed because of the poor quality and hemorrhagic contents obtained. Cytologic examination of an impression smear of a biopsy specimen was suggestive of a sarcoma because of the presence of individual fusiform cells with ill-defined cytoplasmic borders, basophilic cytoplasm, and nuclei containing fine, granular chromatin with prominent nucleoli. There were some binucleated cells present as well. Histologic examination

of the biopsy specimen revealed nonspecific necrotic and hemorrhagic tissue; no neoplastic cells were seen.

The day after initial evaluation, the cow appeared calm and alert. The swelling on the left pelvic limb was mildly increased, and there were some signs of pain associated with palpation of the mass. The cow was treated with cold hydrotherapy of the mass, application of ice packs, and administration of acetylsalicylic acid (25 mg/kg [11.4 mg/lb], PO, once).

On the morning of the second day after initial evaluation, the cow was unable to stand, even with assistance. The area around the mass appeared markedly more distended. A second large, fluctuant mass was palpable proximal to the original mass extending on the lateral thigh from the stifle joint to the level of the head of the femur. An area of dark blue to purple discoloration measuring 1.5 cm in height and 10 cm in width on the lateral aspect of the middle third of the left tibial area was noticed on the unpigmented skin. Within 90 minutes, the discolored area had increased proximally to > 15 cm in height and was evident on the cranial, lateral, and caudal aspects of the limb. The cow had no reaction to noxious stimuli on the lateral or caudal aspects of that limb from the level of the hip joint to the digits. A diagnosis of acute femoral compartment syndrome, involving the tensor fasciae latae and biceps femoris muscles, and lateral tibial compartment syndrome, involving the cranial tibial and peroneus tertius muscles and fascia of the biceps femoris muscles, with associated sciatic nerve paralysis, was made. Surgery was performed immediately.

An ultrasonographic examination was performed during preparation of the cow for surgery and placement of a jugular catheter.^b Marked subcutaneous edema was evident on ultrasonographic examination. The mass had an appearance similar to that on initial evaluation, but there was an increase in the number of fluid pockets around the mass and in the surrounding cranial tibial and peroneus tertius muscles. Preoperatively, the cow received ampicillin (10 mg/kg [4.5 mg/lb], IV, q 8 h). With the cow in right lateral recumbency on a tilt table, the left pelvic limb was aseptically prepared for surgery. The cow was calm and did not resist lateral recumbency; therefore, no sedation was given as it was deemed unnecessary. Because of sciatic nerve paralysis and absence of any signs of pain in response to noxious stimuli on the lateral or caudal aspects of the limb from the level of the hip joint to the digits, no local or epidural anesthesia was administered before surgery. During the procedure, nasal oxygen was administered at a rate of 15 L/min, and the cow was transfused with 6 L of fresh blood, which was collected from a bovine leukosis virus-negative donor from our teaching herd. No blood-matching tests were performed between the donor and the recipient. The transfusion was begun at a rate of 200 mL/h and was increased to 1,080 mL/h after no adverse reaction was noted during the first 20 minutes of transfusion. Vital signs (heart rate and rhythm, respiratory rate, body temperature, and oxygen saturation as measured by pulse oximetry) were monitored continuously and recorded every 5 minutes for the duration of the surgery, including the transfusion.

A 25-cm vertical incision was made on the lateral aspect of the left pelvic limb with a No. 21 scalpel blade

through the skin, biceps femoris, and tensor fasciae lata for decompression. There was an excessive amount of bleeding from the area around the mass, and > 5 L of clotted blood was removed from a dissecting hematoma that created the fluctuant swelling noted proximal to the mass earlier the same day. A firm mass (20 × 12 × 8 cm) was easily removed from the surrounding soft tissues at the lateral aspect of the tibia with blunt, digital dissection. The mass grossly resembled necrotic skeletal muscle. Numerous small (diameter, < 3 mm), tubular cavities within the mass and the surrounding tissues were present. These tubular cavities were releasing a steady, rapid flow of blood that constantly obstructed the surgical field. As ligatures were placed in an attempt to control the hemorrhage, other tubular cavities began bleeding heavily. Sterile towels were packed into the cavity, the soft tissues were not closed, and 3 simple interrupted skin sutures were placed to oppose skin edges, keeping the towels in place and permitting drainage. The cow was returned to its box stall, and the transfusion was finished with surveillance of vital signs every 30 minutes.

The cow was monitored closely following surgical decompression of the femoral and lateral tibial compartments of the left pelvic limb. The cow's appetite and attitude improved dramatically, and the ecchymoses improved markedly. The towels packing the surgical site were changed each day; mild continued bleeding, blood clots, and fibrin accumulation were noted with each dressing change. The cow's Hct (18%) and total protein concentration (70 g/L) were monitored daily and remained stable. The cow was given penicillin G procaine (22,000 U/kg [10,000 U/lb], IM, q 12 h). Although there were no signs of active hemorrhage or abomasal ulcers, no corticosteroids or NSAIDs were administered to avoid an increase in clotting times or creation or worsening of abomasal ulcers, given the stress of recent events and repeated NSAID administration on the farm before evaluation. Histologic evaluation of the mass was again unrewarding. The sections examined revealed only hemorrhage and necrosis and no confirmation of a neoplastic process.

On the fourth day after surgery, the cow was able to stand without assistance. Bacteriologic culture results from samples obtained on the days of initial evaluation and surgery were available. *Streptococcus dysgalactia* was cultured from milk from the left front mammary gland. There was no bacterial growth in the synovial fluid aspirated from the stifle joint. No growth was obtained from routine bacterial culture of the biopsy specimens or from the mass removed during surgery.

On the fifth day following surgery, the cow began to develop signs of increased respiratory effort and thoracic auscultation revealed a considerable increase in frequency of bronchovesicular sounds from initial evaluation. Ultrasonographic examination of the pleura showed a global irregularity to the pleural surface with comet tails and circular masses < 1 cm in diameter visible in all lung fields. Thoracic radiographs were obtained. The lungs had a severe, diffuse miliary pattern throughout all the lobes, confirming metastatic pulmonary disease (Figure 2). The following day, after discussion with the owner, the cow was euthanized by IV

administration of an overdose of pentobarbital sodium and submitted for necropsy.

Grossly, on necropsy, there was a hematoma of the left pelvic limb extending from the lateral surface of the stifle joint to the hip joint. The lung contained a myriad of 0.5- to 1-cm soft, hemorrhagic masses distributed randomly in all lung lobes. Numerous coalescing masses were also protruding on the visceral pleura surface, and some of the larger ones were adhered to the parietal pleura. The left pelvic limb contained multifocal areas of hemorrhage similar to but larger than the masses seen in the lung. Areas of necrosis were distributed multifocally in the peroneus tertius and cranial tibial muscles of the left lateral pelvic limb. There was no gross or microscopic involvement of other organs or muscles. Histopathologically, the lung masses were poorly delineated and composed of large, fusiform to plump cells forming vascular channels of variable diameter (Figure 3).

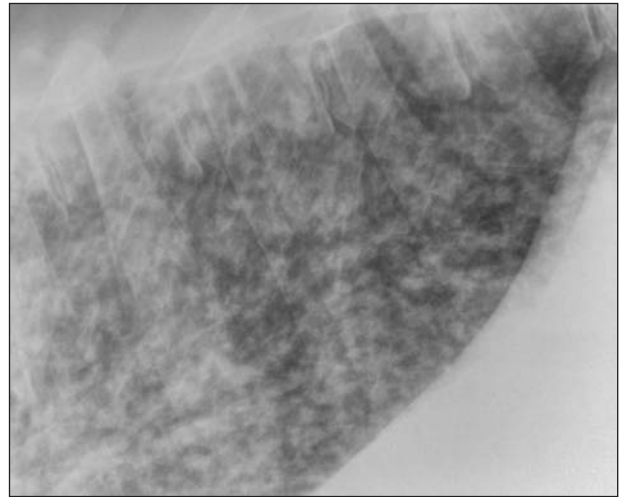


Figure 2—Right lateral radiographic view of the caudal portion of the thorax of the same cow as in Figure 1. The thoracic radiograph was obtained while the cow was standing. A structured, diffuse interstitial pattern is visible throughout the lung and is associated with the presence of multiple circular and poorly defined soft tissue opacities.

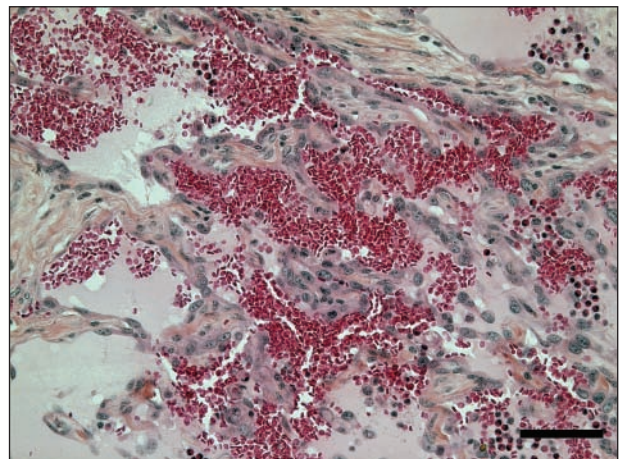


Figure 3—Photomicrograph of a section of affected lung tissue obtained at necropsy from the cow of Figure 1. Notice that the pulmonary mass is composed of irregular vascular channels lined by large, plump endothelial cells with moderate anisokaryosis and anisocytosis. H&E-saffron stain; bar = 100 µm.

Anisocytosis and anisokaryosis were severe; mitotic figures ranged from 4 to 7/hpf. Nuclei contained finely stippled chromatin with up to 3 prominent nucleoli. There were numerous pulmonary vessels partially or completely obliterated by fibrous tissue. Multifocal interstitial fibrosis and multiple hemosiderophages were noted. From the pelvic limb, 2 foci with histopathologic lesions similar to those of the lung were identified. A final diagnosis of metastatic hemangiosarcoma was confirmed.

Discussion

The cow of the present report represents a unique case of acute compartment syndrome in the limb of an adult cow following tumor biopsy. To our knowledge, this is also the only report of hemangiosarcoma in a bovine patient with the primary tumor being muscular in origin. Multiple attempts to obtain a biopsy specimen of the highly vascular neoplasm created the hemorrhage that caused the acute compartment syndrome. The posture of the cow in right sternal recumbency with the left stifle joint flexed and elevated above the pelvis after the biopsy specimens were obtained permitted the hemorrhage to dissect proximally into the femoral compartment as well as distally into the lateral tibial compartment.

Hemangiosarcoma is a neoplasm originating from vascular endothelium, which usually affects visceral organs, but other primary sites are possible because blood vessels are ubiquitous. Pulmonary tissue is the most common site for metastasis.² It is an infrequently reported neoplastic process in cattle, and within the scope of veterinary medicine, it most commonly occurs in dogs.³ Reports of hemangiosarcomas in cattle include primary tumors found, usually at necropsy, in the spinal cord,⁴ heart,³ bone,⁵⁻⁷ urinary bladder,⁸ and external naris.⁹ The cow with hemangiosarcoma of the external naris underwent 2 surgical débridements and was sold 13 months after the second surgery with no recurrence. In horses with hemangiosarcoma, musculoskeletal problems, usually lameness, are the second most common clinical sign after respiratory problems.¹⁰

The patient in this report received only 1 dose of acetylsalicylic acid. It was monitored closely for signs of pain and discomfort including changes in appetite, heart rate, respiratory rate, and reaction to digital palpation. While no indication of severe pain was noted after decompression, we were prepared to administer rescue analgesia as necessary. If needed, the cow would have received morphine via caudal epidural (0.05 to 0.1 mg/kg [0.023 to 0.05 mg/lb] in 20 mL of sterile saline [0.9% NaCl] solution, q 12 h). In our teaching hospital, we have seen favorable results with this protocol, especially when an adult cow receives at least 50 mg of morphine.

Compartment syndrome occurs when pressure within a closed osteofascial space increases; the circulation and tissue function become compromised by the increased pressure within that space.¹¹ In humans with acute compartment syndrome, the most commonly affected compartments are the anterior and lateral compartments of the tibia following fracture, blunt trauma, and reperfusion after acute arterial obstruction.¹² Surgical decompression is the only effective treatment. The deficits occurring from compartment syndrome result

from ischemia of muscles and nerves with higher pressures causing severe damage faster than lower pressures.¹³ Prolonged exposure to increased pressure or delays in decompression result in increased functional loss in the affected limb. Pressures measuring > 30 mm Hg warrant surgical decompression.^{11,13} Intracompartmental pressure was not measured in the cow of the present, and compartmental anatomy was extrapolated from reports^{11,12,14-16} on cattle and other species. Although compartment syndrome is commonly discussed in cattle, this diagnosis is rarely confirmed.¹⁶

Acute compartment syndrome has rarely been reported in veterinary literature and never reported in cattle to our knowledge. There is 1 reported instance of acute compartment syndrome in a horse that resulted from unknown trauma to the forelimb, and the horse recovered rapidly after surgical decompression.¹⁷ Its antebrachial flexor compartment pressure before surgery was approximately 70 mm Hg.¹⁷ In the small animal literature, there are 2 reports^{14,15} of dogs with hemangiosarcoma of the semimembranosus and vastus lateralis muscles with acute compartment syndrome. Their clinical signs were similar to those of the cow in the present report, with swelling of a pelvic limb with signs of pain; treatment included surgical decompression and tumor debridement. In both animals, tumor recurrence occurred and both were subsequently euthanized within 12 weeks after surgery. In the present report of acute compartment syndrome following hemangiosarcoma biopsy in a cow, immediate surgical decompression was effective in preventing permanent neurovascular damage as demonstrated by the cow's ability to stand 4 days after surgery. The prognosis for hemangiosarcoma is grave regardless of the species. Although hemangiosarcomas are notorious for bleeding potential after biopsy, our search yielded no reports of such catastrophic results following a biopsy in the veterinary literature.

- a. Tru-Cut, 14 gauge, 15 cm, Cardinal Health, McGraw Park, Ill.
b. Angiocath, 14 gauge, 5.25 in (2.1 × 133 mm), BD, Sandy, Utah.

References

- Bicalho RC, Cheong SH, Cramer G, et al. Association between a visual and an automated locomotion score in lactating Holstein cows. *J Dairy Sci* 2007;90:3294-3300.
- Pulley LT, Stannard AA. Skin and soft tissues. In: Moulton JE, ed. *Tumors in domestic animals*. 3rd ed. Berkeley, Calif: University of California Press, 1990;47-48.
- Schultheiss PC. A retrospective study of visceral and nonvisceral hemangiosarcoma and hemangiomas in domestic animals. *J Vet Diagn Invest* 2004;16:522-526.
- Sutton RH, McLennan MW. Hemangiosarcoma in a cow. *Vet Pathol* 1982;19:456-458.
- Zachary JF, Mesfin MG, Wolff WA. Multicentric osseous hemangiosarcoma in a Chianina-Angus steer. *Vet Pathol* 1981;18:266-269.
- Poulsen KP, McSloy AC, Perrier M, et al. Primary mandibular hemangiosarcoma in a bull. *Can Vet J* 2008;49:901-903.
- Guard C, Wilkinson JE. Hemangiosarcoma in a cow. *J Am Vet Med Assoc* 1984;185:789-790.
- Pires I, Silva F, Queiroga FL, et al. Epithelioid hemangiosarcomas of the bovine urinary bladder: a histologic, immunohistochemical, and ultrastructural examination of four tumors. *J Vet Diagn Invest* 2010;22:116-119.
- Queen WG, Masterson MA, Weisbrode SE. Hemangiosarcoma of the external naris in a cow. *J Am Vet Med Assoc* 1992;201:1411-1412.

10. Southwood LL, Schott HC II, Henry CJ, et al. Disseminated hemangiosarcoma in the horse: 35 cases. *J Vet Intern Med* 2000;14:105–109.
11. Basinger RR, Aron DN, Crowe DT, et al. Osteofascial compartment syndrome in the dog. *Vet Surg* 1987;16:427–434.
12. Heemskerk J, Kitslaar P. Acute compartment syndrome of the lower leg: retrospective study on prevalence, technique, and outcome of fasciotomies. *World J Surg* 2003;27:744–747.
13. Murbarak SJ, Owen CA. Double-incision fasciotomy of the leg for decompression in compartment syndromes. *J Bone Joint Surg Am* 1977;59:184–187.
14. Bar-Am Y, Anug AM, Shahar R. Femoral compartment syndrome due to haemangiosarcoma in the semimembranosus muscle in a dog. *J Small Anim Pract* 2006;47:286–289.
15. Radke H, Spreng D, Sigrist N, et al. Acute compartment syndrome complicating an intramuscular hemangiosarcoma in a dog. *J Small Anim Pract* 2006;47:281–284.
16. Wessels ME, Greenwood J. Gastrocnemius myopathy in yearling beef cattle. *Vet Rec* 2007;160:666–667.
17. Wallace MA, Pleasant RS, Sysel A. Compartment syndrome in a mare. *Equine Pract Orthop* 1996;18:11–14.



From this month's *AJVR*

Evaluation of horizontal transmission of bovine viral diarrhea virus type 1a from experimentally infected white-tailed deer fawns (*Odocoileus virginianus*) to colostrum-deprived calves

María E. Negrón et al

Objective—To assess the transmission of bovine viral diarrhea virus (BVDV) from experimentally infected white-tailed deer fawns to colostrum-deprived calves by use of a BVDV strain isolated from hunter-harvested white-tailed deer.

Animals—5 white-tailed deer fawns (*Odocoileus virginianus*) and 6 colostrum-deprived calves.

Procedures—Fawns were inoculated intranasally with a noncytopathic BVDV-1a isolate (2 mL containing $10^{6.7}$ TCID₅₀/mL), and 2 days after inoculation, animals were commingled until the end of the study. Blood and serum samples were obtained on days –6, 0, 7, 14, and 21 after inoculation for reverse transcriptase PCR assay, virus neutralization, and BVDV-specific antibody ELISA. Nasal, oral, and rectal swab specimens were collected on days 0, 3, 7, 14, 17, and 21 for reverse transcriptase PCR testing. By 21 days after inoculation, all animals were euthanized and necropsied and tissues were collected for histologic evaluation, immunohistochemical analysis, and virus isolation.

Results—All fawns became infected and shed the virus for up to 18 days as determined on the basis of reverse transcriptase PCR testing and virus isolation results. Evidence of BVDV infection as a result of cohabitation with acutely infected fawns was detected in 4 of the 6 calves by means of reverse transcriptase PCR testing and virus isolation.

Conclusions and Clinical Relevance—On the basis of these findings, BVDV transmission from acutely infected fawns to colostrum-deprived calves appeared possible. (*Am J Vet Res* 2012;73:257–262)



See the midmonth issues
of *JAVMA*
for the expanded table of
contents
for the *AJVR*
or log on to
avmajournals.avma.org
for access
to all the abstracts.