

# Alcohol-facilitated ankylosis of the distal intertarsal and tarsometatarsal joints in horses with osteoarthritis

James L. Carmalt, MA, VetMB, MVetSc, DABVP, DACVS; Chris D. Bell, DVM, MVetSc, DACVS; Luca Panizzi, DVM, MVetSc, DACVS; Ryan R. E. Wolker, DVM, MVetSc, DACVS; Joel L. Lanovaz, PhD; José L. Bracamonte, DVM, DVSc, DACVS; David G. Wilson, DVM, DACVS

**Objective**—To assess the safety and efficacy of alcohol-facilitated ankylosis of the distal intertarsal (DIT) and tarsometatarsal (TMT) joints in horses with osteoarthritis (bone spavin).

**Design**—Prospective clinical trial.

**Animals**—21 horses with DIT or TMT joint-associated hind limb lameness and 5 nonlame horses.

**Procedures**—11 horses (group 1) underwent lameness, force-plate, and radiographic examinations; following intra-articular analgesia, lameness and force-plate examinations were repeated. Nonlame horses were used for force-plate data acquisition only. Following localization of lameness to the DIT and TMT joints, contrast arthrographic evaluation was performed; when communication with the tibiotarsal joint was not evident or suspected, 70% ethyl alcohol (3 mL) was injected. Group 1 horses underwent lameness, force-plate, and radiographic examinations every 3 months for 1 year. Ten other horses (group 2) underwent lameness and radiographic examinations followed by joint injection with alcohol; follow-up information was obtained from owners or via clinical examination.

**Results**—Significant postinjection reduction in lameness (after 3 days to 3 months) was evident for all treated horses. Twelve months after injection, 10 of 11 group 1 horses were not lame; lameness grade was 0.5 in 1 horse. Follow-up information was available for 9 of 10 group 2 horses; 7 were not lame, and 2 remained mildly lame (1 had a concurrent problem in the injected limb, and the other had DIT joint collapse that precluded needle entry).

**Conclusions and Clinical Relevance**—Intra-articular alcohol injection in horses with bone spavin resulted in a rapid (usually within 3 months) reduction in lameness and joint space collapse. (*J Am Vet Med Assoc* 2012;240:199–204)

Osteoarthritis of the distal tarsal joints (bone spavin) is one of the most common causes of lameness and the most common cause of hind limb lameness in performance horses.<sup>1,2</sup> Initial treatment recommendations usually include systemic administration of NSAID drugs and intra-articular treatment with corticosteroids together with corrective shoeing or extracorporeal shockwave therapy; however, most horses require repeated courses of treatment.<sup>3</sup> Arthrodesis (surgical fusion) or facilitated ankylosis (medical fusion) of the affected joints can be a long-term solution. Current surgical techniques include drilling or firing a laser fiber within the affected joints or the use of compression plating techniques.<sup>3–5</sup> The single reported medical technique is the use of intra-articular injections of sodium monoiodoacetate.<sup>6,7,a</sup> Considerable morbidity is associated with this technique, and severe signs of pain typically develop in treated horses. All of the aforementioned methods can be successful, but horses can be lame for a protracted period.<sup>3</sup>

From the Department of Large Animal Clinical Sciences, Western College of Veterinary Medicine (Carmalt, Bell, Panizzi, Wolker, Bracamonte, Wilson), and College of Kinesiology (Lanovaz), University of Saskatchewan, Saskatoon, SK S7N 5B4, Canada.  
Address correspondence to Dr. Carmalt (carmalt\_vet@hotmail.com).

## ABBREVIATIONS

ASI	Asymmetry index
DIT	Distal intertarsal
TMT	Tarsometatarsal

Ethyl alcohol has neurolytic properties and causes articular cartilage damage. Recently, TMT joint fusion was achieved by use of intra-articular injection of either 70% or 95% ethyl alcohol in 15 of 16 horses without lameness or radiographic evidence of tarsal joint osteoarthritis.<sup>8</sup> None of the horses were lame after injection, and joint fusion was complete by 8 months. The purpose of the study reported here was to assess the safety and efficacy of alcohol-facilitated ankylosis of the DIT and TMT joints in horses with osteoarthritis. The hypothesis was that ethyl alcohol would result in a significant reduction of lameness (and pain) following intra-articular injection and that the treated joint would collapse and fusion would occur over time.

## Materials and Methods

**Horses**—The study was conducted with 2 groups of horses. Group 1 was composed of 11 horses with a history of hind limb lameness and 5 nonlame horses. The

nonlame horses were used for force-plate data acquisition only. Lame horses in group 1 underwent a complete lameness examination, and force-plate data were acquired; radiographic examinations of the tarsal joints were subsequently performed to determine the joints affected. Following intra-articular analgesia, lameness and force-plate examinations were repeated. On the basis of contrast arthrographic findings, joints were or were not injected with alcohol. Group 2 was composed of another 10 horses with a history of hind limb lameness. These horses underwent the procedure for alcohol-facilitated joint ankylosis after an initial lameness and radiographic examination (including intra-articular analgesia) and contrast arthrographic evaluation without initial force-plate examination and serial radiographic examinations. Treatment assessment for group 2 horses included information collected via telephone conversations with owners ( $n = 3$ ) and reports of follow-up examinations performed by either the primary author (JLC) or veterinarians in practices where the primary author had performed the technique (7). The study was approved by an institutional animal care committee, and owners also completed an informed consent form prior to enrolling their horses in the study.

**Lameness examination**—The American Association of Equine Practitioners' lameness scale from 0 to 5 (in which 0 is nonlame [sound] and 5 is non-weight bearing) was used during assessment of all horses. The use of scores in increments of 0.5 within the American Association of Equine Practitioners' framework was allowed when the examining clinician thought that severity of the lameness was intermediate between 2 ordinal scores. This type of subdivision provides greater flexibility<sup>2</sup> and has been previously reported in the peer-reviewed veterinary medical literature.<sup>9,10</sup>

**Force-plate data acquisition and radiographic examination**—Subsequent to the lameness examination, a quantitative gait analysis of each horse in group 1 was performed with an in-ground stationary force plate<sup>b</sup> embedded in a 20 × 3-m runway. The data acquisition rate was set at 1,000 Hz. The force plate and runway were covered by mats to prevent horses from slipping. Each horse was led over the force plate at a consistent speed (1.8 to 2.2 m/s), which was confirmed via 2 photoelectric switches that were placed 5 m apart on either side of the force plate. Five valid repetitions were recorded to ensure precision. A valid foot strike was defined as one in which the hoof fully contacted the plate and landed within a 10-cm square boundary from the edges of the force plate within the speed range. For each horse, the mean of the 5 valid measurements per limb per time point were calculated and reported as Newtons per kilogram of body weight.

The lame horses were then restrained, and a complete series of tarsal radiographic views was obtained (4 standard views). The horses were subsequently placed in stocks, and the skin over the DIT and TMT joints of the affected limb (or bilaterally if necessary, as determined from results of the radiographic investigation) was aseptically prepared. A lip-twitch was applied, and intra-articular analgesia was achieved via injection of 3 mL of mepivacaine hydrochloride<sup>c</sup> into each joint by

use of a routine approach to arthrocentesis. In some instances, joints could not be accessed because of the severity of disease. After 20 minutes, the lameness and force-plate examinations were repeated.

**Contrast arthrographic evaluation and joint injection with alcohol**—Having localized the source of the lameness to the distal tarsal joints (by detection of a decrease in ASI calculated from force-plate data), the lame horses in both groups were sedated and a contrast arthrographic evaluation of the TMT or DIT (or both, based on radiographic evidence of disease) joint was performed following injection with 3 mL of iohexol 52% radiographic contrast material.<sup>d</sup> Needles remained in situ during the interpretation of the contrast arthrographic findings. If there was no communication with the proximal intertarsal or the tibiotarsal joint, 3 mL of 70% ethyl alcohol (prepared in-house from 95% laboratory-grade ethyl alcohol)<sup>e</sup> was immediately injected via the needles used for arthrographic evaluation. If there was suspicion or overt evidence of joint communication, needles were withdrawn without injection of alcohol. All horses received 2 g of phenylbutazone<sup>f</sup> IV after joint injection. All owners continued using their horses as if no treatment had been given.

**Postinjection assessments**—Owners were instructed to observe their horses closely for 48 hours and to contact the primary investigator within 7 days to report on their progress. The lame group 1 horses were reexamined at 3, 6, 9, and 12 months after alcohol treatment, and at each time point, lameness, force-plate, and radiographic examinations were performed. Follow-up information for group 2 horses was obtained via reexamination by either the primary author or an experienced equine veterinarian at the practice where the horse had been treated (or failing that, through telephone conversation with owners at 1 year after treatment). No other treatments for bone spavin (eg, corrective shoeing or administration of NSAIDs or other analgesic agents) were permitted in either group.

**Force-plate data analysis**—The following data from the force-plate examination were used for analysis. For unilaterally lame horses, the peak vertical forces in the hind limb were used to calculate an ASI ( $ASI-F_{zHPeak}$ ) with the method created by Weishaupt et al.<sup>11</sup> The ASI is calculated as the difference between the peak vertical force of the left and right limbs divided by the sum of the peak vertical forces of the left and right limbs (results are expressed as a percentage). Thus, symmetric peak forces yield an ASI value of zero, whereas a higher peak force in either the left or right limb yields a positive or negative ASI value. In nonlame horses, the absolute force ASIs are generally < 5%.<sup>11,12</sup> For horses with bilateral hind limb disease, a force-based ASI was not considered appropriate because both lame limbs generally had the same loading patterns. Due to the nature of hind limb bilateral lameness, peak forces and impulses in the hind limbs of these horses were generally unchanged over the course of the study; therefore, no force-plate data from these horses were used to assess lameness.

**Statistical analysis**—Statistical analysis was performed with a commercial software package,<sup>g</sup> with the

level of significance set at a value of  $P < 0.05$ . Descriptive statistics were applied to the data, which were also examined for normality of variance. A repeated-measures ANOVA (controlling for horse) was used to examine the mean  $ASI-F_{zHPeak}$  over time, and if time was a significant factor, multiple  $t$  tests were subsequently used to determine the time point at which this occurred. A Kruskal-Wallis nonparametric ANOVA was used to determine whether there was a significant difference in  $ASI-F_{zHPeak}$  between the various modified lameness grades. A  $\kappa$  statistic was subsequently applied to a number of subjective  $ASI-F_{zHPeak}$  cutoff points for the distinction of lame versus nonlame states to determine the  $ASI-F_{zHPeak}$  value at which observers could reliably state that horses were not lame.

## Results

**Group 1 horses**—None of the 5 horses used for force-plate validation were subjectively determined to be lame (all grade 0), a finding that was further substantiated by use of data acquired from the force plate. In these horses, hind limb  $ASI-F_{zHPeak}$  ranged from 0.13% to 3.85%, indicating that either complete symmetry was not a prerequisite for a diagnosis of a nonlame horse or that a subclinical lameness was present.

Of the 11 lame horses in group 1, 8 were castrated males, 2 were females, and 1 was a stallion (Table 1). The mean  $\pm$  SD age was  $8.23 \pm 3.96$  years (range, 1.5 to 13 years). Median lameness score at the start of the study was 3.0 (range, 3.0 to 4.0; interquartile range [25% to 75% percentiles], 3.0 to 3.0). On the basis of clinical and force-plate

data, 7 horses were unilaterally lame (Figure 1) and 4 were bilaterally lame. However, radiographic examination indicated that 3 of the unilaterally lame horses had evidence of bilateral osteoarthritis. These horses were analyzed as unilaterally lame horses for the purposes of force-plate data examination despite having joints of both hind limbs treated intra-articularly with alcohol.

Thirty joints (17 TMT and 13 DIT joints) in 11 horses had radiographic evidence of osteoarthritis. Contrast arthrographic evaluation was attempted in all joints. All 17

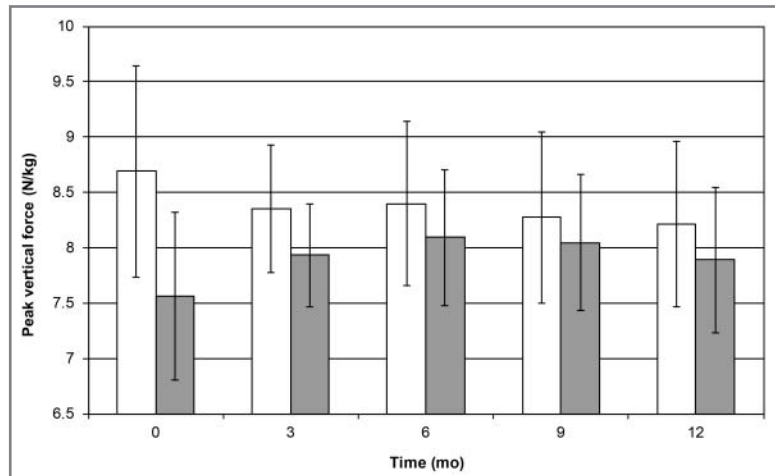


Figure 1—Mean  $\pm$  SD peak hind limb vertical ground reaction forces for the affected lame hind limb (gray boxes) and unaffected hind limb (white boxes) in 7 horses with unilateral lameness referable to the DIT joint, TMT joint, or both joints before (0 months) and after injection of the affected joint with 3 mL of 70% ethyl alcohol. Three of these group 1 horses appeared unilaterally lame but had radiographic evidence of osteoarthritis in those joints bilaterally. Peak vertical ground reaction forces changed in both the affected and unaffected hind limbs in the unilaterally lame horses during the study, with a gradual increase in force in the affected hind limb and a gradual decrease in force in the unaffected hind limb. Peak vertical ground reaction forces in affected and unaffected hind limbs differed significantly ( $P < 0.05$ ) at months 0, 3, and 9.

Table 1—Initial clinical and radiographic findings, joint treatments, and outcome for 11 horses (group 1) with unilateral or bilateral lameness referable to the DIT joint, TMT joint, or both joints that received intra-articular injections of 70% ethyl alcohol (3 mL/injection; 1 injection/joint).

Horse No.	Clinically affected limb (radiographic findings)	Concurrent abnormalities	Joints with radiographic evidence of osteoarthritis	Joints treated (joints in which treatment was attempted)	Outcome at 12 months after treatment
1	Right	No	TMT and DIT	TMT and DIT	Not lame
2	Left	No	DIT	DIT	Not lame
3	Right	No	TMT and DIT	TMT and DIT	Not lame
4	Bilateral	No	Left TMT Right TMT	Left TMT Right TMT	Not lame
5	Bilateral	No	Left TMT Right TMT	Left TMT Right TMT	Not lame
6	Bilateral	No	Left TMT and DIT Right TMT and DIT	Left TMT (DIT*) Right TMT and DIT	Not lame
7	Bilateral	No	Left TMT and DIT Right TMT and DIT	Left TMT (DIT*) Right TMT (DIT†)	Not lame
8	Left (bilateral)	No	Left TMT and DIT Right TMT and DIT	Left TMT (DIT†) Right TMT (DIT*)	Not lame
9	Right (bilateral)	No	Left TMT and DIT Right TMT and DIT	Left TMT (DIT†) Right TMT (DIT†)	Not lame
10	Right (bilateral)	Right third tarsal bone fracture	Left TMT and DIT Right TMT and DIT	Left TMT (DIT*) Right TMT and DIT	Not lame
11	Left	No	TMT	TMT	Lame (grade, 0.5/5‡)

\*DIT joint communication with proximal intertarsal joint was detected; affected joint was not injected with alcohol. †Joint could not be entered because of presence of severe osseous reaction. ‡American Association of Equine Practitioners' lameness scale from 0 to 5 (where 0 = nonlame [sound] and 5 = non-weight bearing) was used; use of scores in increments of 0.5 within the American Association of Equine Practitioners' framework was allowed when the examining clinician thought that severity of the lameness was intermediate between 2 ordinal scores.

TMT joints were accessed, and none indicated a communication with either the DIT or the tibiotarsal joints. Of the 13 DIT joints undergoing contrast arthrographic evaluation, 4 could not be entered because of the degree of periarticular new bone. Of the remaining 9 DIT joints, 5 had no evidence of proximal joint communication and 4 had evidence of communication with the proximal intertarsal and tibiotarsal joints.

One horse was reported by the owner to have developed edema surrounding the injection site (TMT joint). No other complications were noted in this or any other horse in either of the 2 distinct study populations.

All of the horses in group 1 had a significant ( $P = 0.002$ ) reduction in lameness after injection with alcohol. Peak vertical ground reaction forces changed in both the affected and unaffected hind limbs in the unilaterally lame horses during the study (Figure 1), with a gradual increase in force in the affected hind limb and a gradual decrease in force in the unaffected hind limb. Results of a repeated-measures ANOVA (controlling for the unilaterally lame horses) indicated that there was a significant ( $P < 0.001$ ) reduction in mean  $ASI-F_{zHPeak}$  over time (Figure 2). The period determining this significance was between initial examination and 3 months after alcohol injection ( $P = 0.02$ ). Owners were contacted via telephone follow-up within 7 days after injection, and most indicated that an improvement in lameness had been detected within 48 hours following treatment. At 12 months, 10 of 11 horses were free of lameness and 1 was mildly lame (lameness grade, 0.5; Figure 3).

There was a highly significant ( $P < 0.001$ ) association between modified lameness grade and mean  $ASI-F_{zHPeak}$ , indicating that subjective assessment was reflected in the objective determination of lameness as indicated by the force-plate data. When  $\kappa$  statistics were applied to a subjective determination of either a lame or nonlame state by use of arbitrary  $ASI-F_{zHPeak}$  cutoff values of 3.5%, 4%, and 5%, results were 0.417, 0.541, and 0.608, respectively, indicating moderate agreement in the first 2 instances and substantial agreement in the latter.<sup>13</sup>

Radiographically, there was a substantial subjective reduction in the width of the joint space of alcohol-injected joints over time. Although treated joints in all group 1 horses were deemed fused, there was evidence of a joint space remnant in at least 1 standard radiographic view obtained from each horse at each time point.

**Group 2 horses**—Of the horses in group 2, 3 were stallions, 6 were geldings, and 1 was a mare (Table 2). Follow-up clinical examinations ( $n = 7$ ) or telephone conversations with owners (3) of the horses were performed a mean interval after treatment of 11 months

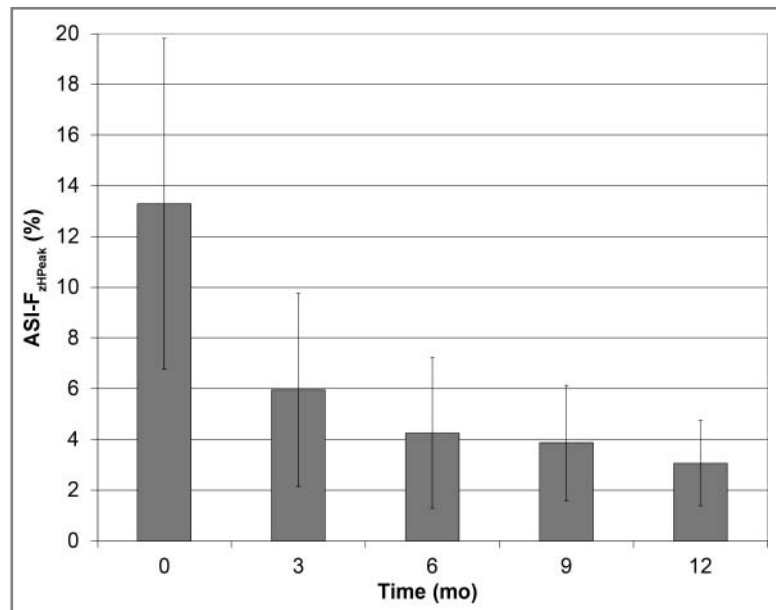


Figure 2—Mean  $\pm$  SD ASI values (calculated on the basis of force-plate data) for the 7 horses in Figure 1 with unilateral lameness referable to the DIT joint, TMT joint, or both joints before (0 months) and after injection of the affected joint with 3 mL of 70% ethyl alcohol. Results of a repeated-measures ANOVA (controlling for the unilaterally lame horses) indicated that there was a significant ( $P < 0.001$ ) reduction in the mean  $ASI-F_{zHPeak}$  over time; the period determining this significance was between initial examination and 3 months after alcohol injection ( $P = 0.02$ ).

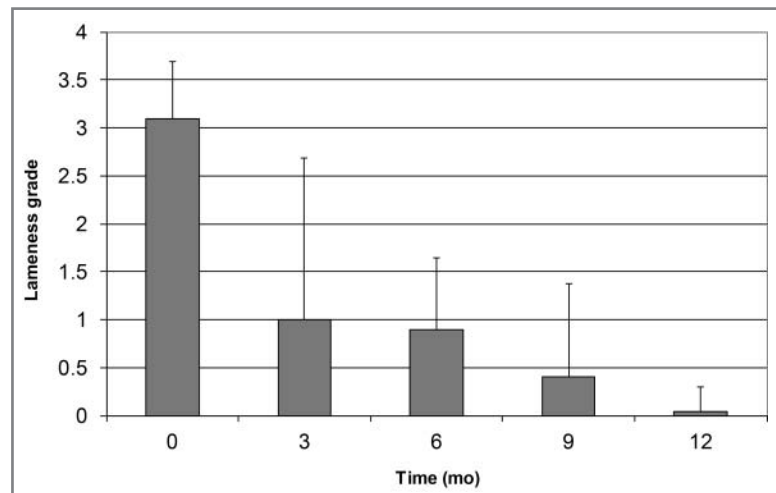


Figure 3—Mean lameness grade among 11 horses (group 1) with unilateral or bilateral lameness referable to the DIT joint, TMT joint, or both joints before (0 months) and after injection of the affected joint with 3 mL of 70% ethyl alcohol. Lameness was assessed by use of the American Association of Equine Practitioners' lameness scale from 0 to 5 (where 0 is nonlame [sound] and 5 is non-weight bearing); use of scores in increments of 0.5 within the American Association of Equine Practitioners' framework was allowed when the examining clinician thought that the severity of lameness was intermediate between 2 ordinal scores. Error bars denote maximum values. Mean lameness grade at 0 months differed significantly ( $P < 0.05$ ) from the value at each other time point. Mean lameness grades at 3 and 6 months did not differ from each other, but both were significantly different from the value at each other time point. Mean lameness grades at 6 and 9 months did not differ from each other, but both were significantly different from the value at each other time point.

(range, 2 to 24 months). One horse was being overwintered and could not be returned for follow-up examination. Seven of the remaining 9 horses were not lame, and 2 horses remained mildly lame. One of the lame horses had a concurrent upward fixation of the pa-



Table 2—Initial clinical and radiographic findings, joint treatments, and outcome for 10 horses (group 2) with unilateral or bilateral lameness referable to the DIT joint, TMT joint, or both joints that received intra-articular injections of 70% ethyl alcohol (3 mL/injection; 1 injection/joint).

Horse No.	Clinically affected limb (radiographic findings, when different)	Concurrent abnormalities	Joints with radiographic evidence of osteoarthritis	Joints treated (joints in which treatment was attempted)	Follow-up period (mo)	Outcome at time of follow-up report
1	Left	Third tarsal bone fracture	DIT and TMT	DIT (TMT†)	24	Not lame
2	Right (bilateral)	No	Left TMT and DIT Right TMT and DIT	Left TMT (DIT*) Right TMT and DIT	20	Not lame, sold
3	Bilateral	No	Left TMT and DIT Right TMT and DIT	Left TMT (DIT†) Right TMT and DIT	19	Not lame (R), lame (L)
4	Bilateral	No	Left TMT Right TMT and DIT	Left TMT Right TMT and DIT	17	Not lame
5	Bilateral	No	Left TMT Right TMT	Left TMT Right TMT	2	Paddock rest during winter
6	Bilateral	No	Left TMT Right TMT	Left TMT Right TMT	2	Not lame
7	Bilateral	No	Left TMT Right TMT	Left TMT Right TMT	14	Not lame
8	Right	Upward fixation	Right TMT	Right TMT	5	Lame (grade 1 when circling to the right)
9	Right	No	Right TMT	Right TMT	6	Not lame
10	Bilateral	No	Left TMT Right TMT	Left TMT Right TMT	2	Not lame

See Table 1 for key.

tella in the injected limb, which was treated with medial patella ligament splitting; the other had severe pathological changes in a DIT joint (not previously injected or treated by the authors), which could not be injected because the periarticular bone prevented needle access.

## Discussion

In the present study, joint injection of alcohol in horses with lameness attributable to arthritis of the distal tarsal joints resulted in a rapid reduction in lameness, such that horses could return to their intended use. Lameness resolved in 18 of the 21 treated horses, and 3 remained mildly lame. Up to the last update, (approx 18 months after the first horse entered the study), none of the horses had required joint reinjection for the purposes of pain resolution. Although 1 horse developed some edema surrounding the site of injection, no treatment was necessary. This was the only complication noted during the study.

Contrary to results of an experimental study by Shoemaker et al,<sup>8</sup> the horses that underwent alcohol-facilitated ankylosis did not develop the degree of joint fusion expected. There are, however, 3 fundamental differences between the previous experimental study and the clinical trial reported here. In the former protocol, none of the horses underwent contrast arthrographic evaluation, they were all 3 to 4 years of age, and none had clinical disease. Explanations for the disparity in results may be as follows: there was a possible interaction between the alcohol and the contrast agent (either chemical or spatial) following joint injection; the younger horses in the experimental study<sup>8</sup> had fundamentally different cartilage or subchondral bone plate characteristics, compared with those of the older horses, as described by Murray et al<sup>14</sup>; or there was an undetermined difference in the action of ethyl alcohol in osteoarthritic versus normal joints.

It has also been reported<sup>8</sup> that radiographic evidence of joint fusion underestimates the true prevalence of ankylosis or fusion at 12 months, compared with results of

postmortem examination. Initial protocols for the present study intended that horses would undergo a computed tomographic examination at the end of the 12-month study period in an attempt to correlate the extents of joint fusion determined via radiographic evaluation and computed tomographic imaging. Unfortunately, but not unexpectedly, most clients were unwilling to subject their horses to the risks of general anesthesia, especially because they were no longer lame at that time.

The significant association between subjective lameness score and mean ASI was welcomed by the authors, as it reinforced our ability to assign a modified lameness grade to the horses that was reflected in the objective assessment. This has repercussions separate from the present study, with potential application in clinical practice. We further determined that a mean ASI cutoff value between 4% and 5% was useful in the determination of a lame versus nonlame state in horses, a value previously supported by information in the veterinary medical literature.<sup>11,12</sup>

Although the results of the present study suggested that a single intra-articular injection of alcohol results in rapid and sustained reduction in lameness, the treated horses in group 1 were followed up for only 12 months. However, a group 1 horse had been monitored for 18 months and continued to be free of lameness attributable to the distal tarsal joints, and treated horses in group 2 were followed up for as long as 24 months with no return of lameness.

Undoubtedly, results of the present study could create a bias toward intra-articular injection of ethyl alcohol as a first-line treatment when osteoarthritis of the DIT or TMT joint is confirmed. Although this treatment may seem encouraging, the authors suggest caution. In discussions with an investigator involved in 2 studies<sup>6,a</sup> of joint fusion via intra-articular injection of sodium monoiodoacetate, it was indicated that several of the treated horses that had negative contrast arthrographic findings (ie, no evidence of communication of the DIT or TMT joint with the tibiotarsal joint) developed osteoarthritis of the tibiotarsal joint 5 to 10 years

after treatment.<sup>h</sup> Possible conclusions were that a small interjoint communication was overlooked during review of the contrast arthrograms, the treatment could have stimulated an inflammatory response that triggered osteoarthritis in the tibiotarsal joint, or restricting movement of the DIT and TMT joints resulted in abnormal loading of the tibiotarsal joint such that osteoarthritis developed. The latter argument is not robust because there is no evidence in the veterinary medical literature that arthritis in proximal joints develops after horses undergo fusion (surgical or chemical) of the distal tarsal joints; however, long-term follow-up reports are lacking. Clearly, if the degree of pathological change is refractory to medications that are routinely injected intra-articularly, then injection of ethyl alcohol may be the only noninvasive option remaining, but care should be exercised in case selection.

Similarly, if only one of the distal tarsal joints (either the DIT or TMT joint) had clinical evidence of disease, the debate would be whether to treat the affected joint only or to simultaneously treat the affected joint and the ipsilateral nonaffected joint with ethyl alcohol (assuming the contrast arthrogram did not indicate communication with the tibiotarsal joint). It is our opinion (although not practiced with the horses included in the study of this report) that when a horse with clinical evidence of disease in only one of the distal tarsal joints participates in sports that predispose to the development of osteoarthritis of the tarsal joints (eg, reining and cutting), then both the DIT and TMT joints of the affected limb should be treated at the same time.

Of the 13 affected DIT joints in the present study, only 5 were injected (4 could not be entered because of interference from new bone deposits, and 4 communicated with the proximal intertarsal joint). Despite the inability to medicate those affected joints, lameness ultimately resolved in all 8 horses. When both joints (DIT and TMT) had radiographic evidence of osteoarthritis initially, then diagnostic intra-articular analgesia was performed on both joints simultaneously (prior to completing the second force-plate data acquisition) in an effort to expedite the examination process. Thus, the pain contribution from each joint could not be assessed independently. The reason for the resolution of lameness in horses in which affected joints were not injected remains speculative. Possible explanations are that the pain component was primarily from the TMT joint; therefore, when ankylosis was achieved in these joints, the horses appeared nonlame. Alternatively, there may have been a communication between DIT and TMT joints that was inapparent via contrast arthrographic evaluation such that alcohol entered the DIT joint and effected ankylosis. One mechanism of action, namely that therapeutic concentrations of ethyl alcohol diffused into the DIT joint following TMT joint injection as has been detected following methylprednisolone injection of TMT joints,<sup>13</sup> is unlikely. The drug causes nonspecific protein denaturation and cell protoplasm precipitation with dehydration, all of which occur at the drug-tissue interface. In addition to this, if clinical concentrations of ethyl alcohol were to diffuse out of the injected joint, then evidence of proximal intertarsal or tibiotarsal joint changes might have been observed (subsequent to injection)

in the horses of the present study and those in the study by Shoemaker et al,<sup>8</sup> which was not the case.

The results of this investigation of alcohol-facilitated ankylosis indicated that in contrast to current treatments, horses receiving an intra-articular injection of alcohol undergo a rapid and sustained reduction in lameness such that they can be trained (ie, brought into work) or compete within days following treatment. In the present study, owners were satisfied with the outcome of the horses' treatment, and within the initial 18-month period after treatment, we have had to administer only 1 injection.

- a. Bohanon TC. Chemical fusion of the distal intertarsal joints with sodium monoiodoacetate in 38 horses clinically affected with bone spavin (abstr). *Vet Surg* 1995;24:421
- b. AMTI BP400600, Waterton, Mass.
- c. Carbocaine 2%, Hospira Health Care Corp, Montreal, QC, Canada.
- d. Omnipaque, GE HealthCare Canada Inc, Mississauga, ON, Canada.
- e. 95% ethyl alcohol (MSDS 1001), Commercial Alcohols Inc, Brampton, ON, Canada.
- f. Butequine, Bioniche Animal Health Canada, Belleville, ON, Canada.
- g. Statistix, version 8, Analytical Software, Tallahassee, Fla.
- h. Bohanon TC, Glenwood Veterinary Clinic, Glenwood Springs, Colo: Personal communication, 2009 and 2010.

## References

1. Sullins KE. The tarsus. In: Stashak TE, ed. *Adams' lameness in horses*. 5th ed. Baltimore: Lippincott Williams & Wilkins, 2002;930–987.
2. Ross MW, Dyson SJ. *Diagnosis and management of lameness in the horse*. St Louis: Saunders Elsevier, 2003.
3. Auer JA. The tarsus. In: Auer JA, Stick J, eds. *Equine surgery*. 3rd ed. Philadelphia: WB Saunders Co, 2006;1288–1307.
4. Barber SM. Arthrodesis of the distal intertarsal and tarsometatarsal joints in the horse. *Vet Surg* 1984;13:227–235.
5. Hague B, Guccione A. Laser-facilitated arthrodesis of the distal intertarsal joints. *Clin Tech Equine Pract* 2002;1:32–35.
6. Bohanon TC, Schneider RK, Weisbrode SE. Fusion of the distal intertarsal and tarsometatarsal joints in the horse using intra-articular sodium monoiodoacetate. *Equine Vet J* 1991;23:289–295.
7. Dowling BA, Dart AJ, Matthews SM. Chemical arthrodesis of the distal tarsal joints using sodium monoiodoacetate in 104 horses. *Aust Vet J* 2004;82:38–42.
8. Shoemaker RW, Allan AL, Richardson CE, et al. Use of intra-articular administration of ethyl alcohol for arthrodesis of the tarsometatarsal joint in healthy horses. *Am J Vet Res* 2006;67:850–857.
9. Erkert RS, MacAllister CG, Payton ME, et al. Use of force plate analysis to compare the analgesic effects of intravenous administration of phenylbutazone and flunixin meglumine in horses with navicular syndrome. *Am J Vet Res* 2005;66:284–288.
10. Ishihara A, Bertone AL, Rajala-Schultz PJ. Association between subjective lameness grade and kinetic parameters in horses with experimentally induced forelimb lameness. *Am J Vet Res* 2005;66:1805–1815.
11. Weishaupt MA, Weistner T, Hogg HP, et al. Compensatory load redistribution of horses with induced weightbearing hindlimb lameness trotting on a treadmill. *Equine Vet J* 2004;36:727–733.
12. Weishaupt MA. Adaptation strategies of horses with lameness. *Vet Clin Equine* 2008;24:79–100.
13. Dohoo I, Martin W, Stryhn H. In: *Veterinary epidemiologic research*. Charlottetown, PEI, Canada: University of Prince Edward Island, 2003;92.
14. Murray RC, Blunden TS, Branch MV, et al. Evaluation of age-related changes in the structure of the equine tarsometatarsal osteochondral unit. *Am J Vet Res* 2009;70:30–36.
15. Serena A, Schumacher J, Schramme MC, et al. Concentration of methylprednisolone in the centrodistal joint after administration of methylprednisolone acetate in the tarsometatarsal joint. *Equine Vet J* 2005;37:172–174.