

Diagnosis and management of cranial and caudal nuchal bursitis in four horses

José M. García-López, VMD, DACVS; Thomas Jenei, DVM, DACVS; Kate Chope, VMD; Kirstin A. Bubeck, Dr Med Vet

Case Description—4 horses with a history of neck pain, abnormal head carriage, and related inability to perform were examined. Cranial nuchal bursitis was diagnosed in 2 horses, and caudal nuchal bursitis was diagnosed in the other 2.

Clinical Findings—All 4 horses had prominent swelling in the region between the frontal bone and temporal fossa (ie, the poll) and abnormal head carriage. Ultrasonographic examination revealed fluid distention and synovial thickening of the cranial or caudal nuchal bursa in all 4 horses. Ultrasonography-guided aspiration of the affected region was performed successfully in 3 horses. Radiography revealed bony remodeling and mineralization over the dorsal aspect of the atlas in 1 horse and a radiolucency at the axis in another. Nuclear scintigraphy revealed an increase in radioisotope uptake at the level of C2 in 1 horse. Although a septic process was considered among the differential diagnoses in all horses, a septic process could only be confirmed in 1 horse.

Treatment and Outcome—All horses were refractory to conservative management consisting of intrabursal injection of anti-inflammatory medications. Bursoscopic debridement and lavage of the affected bursae resulted in resolution of the clinical signs in all horses, and they all returned to their intended use.

Clinical Relevance—Cranial and caudal nuchal bursitis, of nonseptic or septic origin, should be considered as a differential diagnosis in horses with head and neck pain. Horses undergoing surgical intervention consisting of nuchal bursoscopy have the opportunity to return to their original degree of exercise. (*J Am Vet Med Assoc* 2010;237:823–829)

A 14-year-old 693-kg (1,525-lb) Thoroughbred gelding (horse 1) was brought to the Hospital for Large Animals at Tufts University Cummings School of Veterinary Medicine for a 6-week history of sensitivity to manipulation of the neck and abnormally low head carriage when ridden. Physical examination revealed mild asymmetry with obvious swelling over the left side of the region between the frontal bone and temporal fossa (ie, the poll). The gelding was resistant to having its head elevated and manipulated in a side-to-side direction. Results of neurologic evaluation were unremarkable.

Radiographs of the cervical aspect of the vertebral column were obtained, revealing changes consistent with bony remodeling and soft tissue mineralization over the dorsal aspect of the atlas (C1; **Figure 1**). Ultrasonographic evaluation of the cranial nuchal bursa overlying C1 revealed severe synovial thickening (1 to 2 cm) that appeared predominantly homogeneous, with scattered hyperechoic densities. The appearance of these densities was most consistent with mineralization and corresponded with the mineralization seen on the radiographs. The bursa was distended with anechoic to hypoechoic fluid and was visible from both sides of midline. These findings were considered consistent with a chronic bursitis, possibly of septic origin.

Via sonographic guidance, an aspirate of the swelling at the cranial nuchal bursa was obtained (**Figure 2**).

From the Department of Clinical Sciences, Cummings School of Veterinary Medicine, Tufts University, North Grafton, MA 01536. The authors thank Beth Mellor for technical assistance with line drawings. Address correspondence to Dr. García-López (jose.garcia-lopez@tufts.edu).

ABBREVIATION

LRS Lactated Ringer's solution

Fluid analysis of the aspirate from the bursa revealed a total nucleated cell count of 10,200 cells/ μ L, total protein concentration of 7.4 g/dL, and a predominance of nondegenerative and nontoxic neutrophils (95%). No microorganisms were identified cytologically, and a sample of the fluid that was submitted for bacterial culture failed to yield any organisms. Bursoscopy and debridement were recommended to the owner because of the possibility that sepsis was the underlying cause of inflammation in the bursa. The owner declined bursoscopy at that time and requested that anti-inflammatory treatment be used instead. At the owner's request, the bursa was injected with a combination of 20 mg of hyaluronic acid^a and 40 mg of methylprednisolone acetate.^b The horse was discharged with instructions to the owner to administer phenylbutazone (2.2 mg/kg [1 mg/lb], PO, q 12 h) for 7 days and the recommendation of 3 days of stall rest followed by 1 week of small paddock turnout before resuming exercise.

Despite a short-lived response to treatment, the horse continued to have similar clinical signs even after a second bursal treatment 4 weeks later. Given the lack of response to conservative management in the 12 weeks following the original visit, the owner agreed to proceed with general anesthesia and surgical bursoscopic debridement.

Results of a CBC and serum biochemical analysis were within reference ranges. Perioperatively, the horse

received ceftiofur (2.2 mg/kg, IV, q 12 h), gentamicin (6.6 mg/kg [3 mg/lb], IV, q 24 h), and phenylbutazone (2.2 mg/kg, PO, q 12 h). Following sedation with xylazine (0.5 mg/kg [0.23 mg/lb], IV), anesthesia was induced with a combination of ketamine (2.2 mg/kg, IV) and midazolam (0.1 mg/kg [0.05 mg/lb], IV). Anesthesia was subsequently maintained with isoflurane in oxygen in a semiclosed circle anesthetic system. The horse was positioned in right lateral recumbency, and the area over the cranial nuchal bursa was prepared aseptically for surgery.

The bursa was distended with 60 mL of sterile LRS with an 18-gauge, 6-inch spinal needle via ultrasonographic guidance. Subsequently, two 0.5-cm skin incisions were made over the cranial and caudal aspect of the cranial nuchal bursa at the left side of the neck to serve as ipsilateral portals for the arthroscope and instrumentation, respectively. A 4-mm, 30° forward-viewing arthroscope was inserted into the bursa

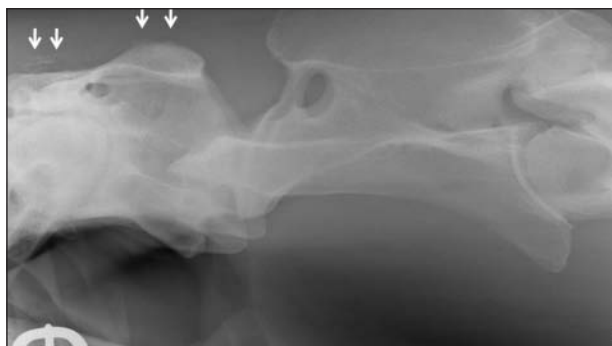

Figure 1—Lateral radiographic view of the proximal cervical region in a 14-year-old Thoroughbred gelding with cranial nuchal bursitis. Several mineral densities (arrows) are visible dorsal to C1.

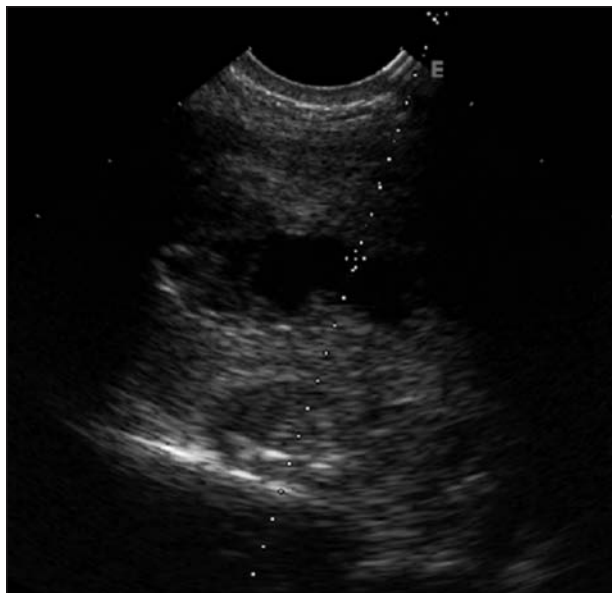


Figure 2—Ultrasonogram of the cranial nuchal bursa over C1 in the horse in Figure 1, obtained during ultrasonography-guided aspiration of fluid from swelling in that region. Fluid distention and synovial thickening are present. Depth of the nuchal bursa from the skin surface was 1.58 cm. The diagonal dotted line represents the needle trajectory during fluid aspiration. The scan was performed at a displayed depth of 6.4 cm. E = Abaxial aspect of the transducer.

via ultrasonographic guidance. Upon insertion of the arthroscopic sleeve into the bursa, a large volume of purulent material was expelled. A sample of expelled material was Gram stained and examined microscopically, but no bacteria were identified. Samples of this material were submitted for bacterial culture and antimicrobial susceptibility testing, but no etiologic agents could be isolated.

Visual evaluation of the bursa confirmed the synovium was markedly thickened and proliferative (Figure 3). The bursa was explored and debrided by use of a motorized synovial resector.^c Afterward, the bursa was copiously lavaged with 20 L of sterile LRS. Bursoscopic guidance was used to introduce a constant rate infusion antimicrobial delivery system^d into the cranial nuchal bursa. Both incisions were closed routinely with a simple interrupted cruciate pattern. A sterile bandage was placed for recovery from anesthesia.

Following surgery, treatment with ceftiofur and gentamicin was continued for 4 days, after which time the systemic antimicrobials were changed to trimethoprim-sulfadiazine (30 mg/kg [13.6 mg/lb], PO, q 12 h). In addition, a constant rate intrathecal infusion of ticarcillin-clavulanate (100 mg/h) into the bursa was maintained for 8 days following surgery. The horse was discharged from the hospital 8 days after surgery with instructions to the owner to continue oral antimicrobial administration for 3 days and phenylbutazone administration for 7 days. In addition, it was recommended the horse be provided with stall rest and hand walking for 4 to 6 weeks, followed by 2 weeks of small-paddock turnout.

At the time of reevaluation 8 weeks after hospital discharge, the owner indicated that horse 1's signs of stiffness had resolved. The owner also reported she had resumed riding the gelding using a saddle and that the horse's head carriage was no longer abnormal. Physical examination revealed a healthy range of motion of the head and neck, although a mild amount of swelling still existed over the region of the cranial nuchal bursa. Subsequent follow-up information obtained by telephone 10 months after surgery revealed the gelding had returned to its previous degree of athletic work as a 3-day event horse.

A 10-year-old 373-kg (821-lb) female Tennessee Walking Horse that was used for pleasure riding (horse 2) was admitted to the teaching hospital for evaluation of signs attributed to neck pain. Signs included a limited range of flexion of the neck to the right and left as

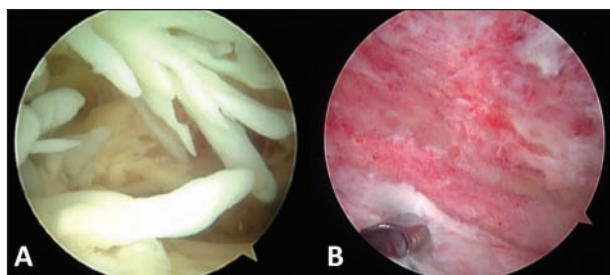


Figure 3—Bursoscopic image of the cranial nuchal bursa in the horse in Figure 1 before (A) and after (B) debridement of the bursa with a motorized synovial resector. In panel A, notice the thickened and extremely proliferative synovium within the bursa before debridement.

well as atypical and frequent lowering of the head with extension of the neck. At the time the signs were first noticed, the mare had been regularly turned out with other horses but no known trauma had occurred.

Physical examination at the time horse 2 was admitted confirmed the presence of a restricted range of motion when the head and neck were turned to the right and left. No other physical abnormalities were detected. A neurologic evaluation revealed mild deficits in the right (grade 1/5, with 0 = no gait deficits and 5 = recumbent patient) and left (grade 2) hind limb, but findings were otherwise unremarkable.¹ Radiography of the cervical aspect of the vertebral column revealed a 14-mm-diameter radiolucent area with surrounding sclerotic rim at the spinous process of C2 (Figure 4). Because of the proximity of the radiolucent area to the subarachnoid space and the mare's clinical (neurologic) signs, myelography and atlanto-occipital CSF collection were performed while the horse was anesthetized. Dynamic myelography of the cervical aspect of the vertebral column was performed, revealing no evidence of spinal cord compression or contrast material^e within the previously detected lucency of C2. The mare recovered from anesthesia without complications.

Analysis of the CSF sample yielded unremarkable findings. A western blot test to detect antibodies against *Sarcocystis neurona* revealed an intermediate concentration of antibodies, suggesting an active infection with the organism in combination with the clinical neurologic signs.

Ultrasonographic evaluation of the C2 region revealed a prominent caudal nuchal bursa, with severe thickening (2 to 3 cm) of the synovial lining and moderate effusion that was somewhat heterogeneous (Figure 5). The fluid communicated directly with a 9.8 × 8.1 × 6-mm cortical defect of the left dorsolateral aspect of C2. The adjacent bony surfaces of C2 appeared more irregular than is typical. Amorphous echoes were visualized deep to the concavity, further suggesting a lytic process corresponding to the region identified radiographically. Fine-needle aspiration of the fluid was performed under ultrasonographic guidance, and a thick exudate was collected.

Cytologic evaluation of a direct smear of the aspirated fluid revealed a predominance of degenerative neutrophils. Fluid samples were also submitted for bacterial culture and antimicrobial susceptibility testing, resulting in isolation of coagulase-negative *Staphylococcus* spp sensitive to enrofloxacin and trimethoprim-sulfadiazine. These results all confirmed the initial suspicion of septic caudal nuchal bursitis with osteomyelitis of C2 on the basis of radiographic and ultrasonographic findings. Bursoscopic exploration and surgical debridement of the caudal nuchal bursa were consequently suggested to horse 2's owner, but this was declined. The mare was discharged from the hospital with instructions to the owner to administer trimethoprim-sulfadiazine (30 mg/kg, PO, q 12 h) and pyrimethamine (1 mg/kg [0.45 mg/lb], PO, q 24 h) to treat for equine protozoal myeloencephalitis. Enrofloxacin (7.5 mg/kg [3.4 mg/lb], PO, q 24 h for 14 days) was added for better antimicrobial penetration at the osteomyelitis site, in addition to phenylbutazone (2.2 mg/kg, PO, q 12 h for 5 days).

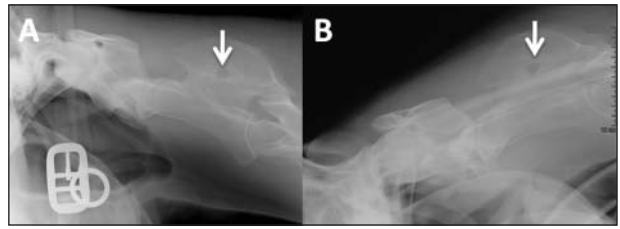


Figure 4—Lateral radiographic (A) and myelographic (B) views of the proximal cervical region in a 10-year-old Tennessee Walking Horse used for pleasure riding. A—A lucent defect with a sclerotic halo (arrow) is visible at the level of the spinous process of C2. The item in the bottom left corner is a halter buckle. B—No evidence of spinal cord compression or contrast material was evident within the aforementioned bony defect (arrow) when myelography was performed.

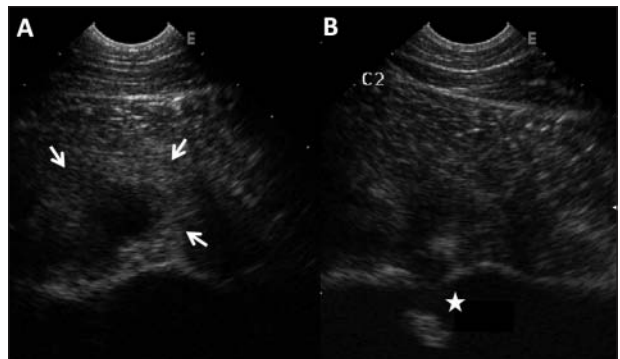


Figure 5—Ultrasonograms of the caudal nuchal bursa of the same horse in Figure 2. A—Fluid distention and synovial thickening of the bursa are evident (white arrows). B—A discrete concavity is visible on the hyperechoic bony surface on the left dorsal lateral aspect of C2 (star). The scan was performed at a displayed depth of 8.4 cm. E = Abaxial aspect of the transducer.

The mare was returned for reevaluation 3 weeks later with no evidence of improvement in clinical signs. At that time, the owner agreed to proceed with surgical endoscopic debridement with the horse anesthetized. Results of preoperative hematologic analyses were within reference ranges. Perioperatively, the horse received enrofloxacin (5 mg/kg [2.3 mg/lb], IV, q 24 h), trimethoprim-sulfadiazine (30 mg/kg, PO, q 12 h), and phenylbutazone (2.2 mg/kg, PO, q 12 h). The anesthesia protocol was identical to that in horse 1. The arthroscope was inserted into the caudal nuchal bursa via sonographic guidance as described for horse 1.

Inspection of the caudal nuchal bursa revealed hyperemic and proliferative synovium, which was debrided by use of a motorized synovial resector. The lytic lesion previously detected on radiographs and ultrasonograms was identified and judiciously debrided under endoscopic guidance with curettage. No other abnormalities were detected, and the bursa was copiously lavaged with sterile LRS. Skin incisions were closed routinely, and the mare recovered from anesthesia without complications. Twenty-four and 48 hours after surgery, 500 mg of amikacin sulfate was injected into the caudal nuchal bursa by use of ultrasonographic guidance. The mare was discharged from the hospital 4 days after surgery with instructions to the owner to administer trimethoprim-sulfadiazine and pyrimethamine for 4 weeks and enrofloxacin for 14 days. In addition, the mare was to be provided with stall rest and hand walking for 4 weeks before being returned for reevaluation.

When horse 2 was reevaluated 4 weeks after surgery, the owner reported that the signs previously attributed to neck pain had resolved and the mare was considerably brighter and more active than before. Physical examination revealed full range of motion of the head and neck. The surgical incisions had healed without complications. Neurologic evaluation revealed partial improvement, although the mare continued to have deficits in the right (grade 1) and left (grade 1) hind limbs, which was attributed to the infection. The mare was discharged with recommendations of continuing stall rest with hand-walking exercise for 4 to 6 additional weeks before allowing small-paddock turnout. Subsequent follow-up information obtained by telephone 11 months following surgery indicated the mare had continued to do well with no recurrence of the atypical behavior originally reported and was again being used for pleasure riding.

A 13-year-old 485-kg (1,067-lb) Standardbred gelding was evaluated for acutely decreased range of motion in the neck (horse 3), and a diagnosis of non-septic caudal nuchal bursitis was ultimately made. Ultrasonography at the time of diagnosis revealed the left lobe of the funicular portion of the nuchal ligament had an axially located region of decreased echogenicity and decreased fiber density, consistent with nuchal desmitis. The right lobe had typical echogenicity and fiber alignment. Ultrasonography-guided synoviocentesis was unsuccessful. The owner originally elected to proceed with conservative management (treatment of the bursa with anti-inflammatories as in horse 1), which resulted in a short-lived improvement (3 weeks) of the clinical signs. Afterward, the owner agreed to exploratory bursoscopy. Perioperative IV antimicrobial and anti-inflammatory treatments as well as the anesthesia protocol and surgical technique were identical to that described for horse 1.

Evaluation of the bursa confirmed the synovium was markedly thickened. After mechanized debridement, the bursa was copiously lavaged and the incisions were closed routinely. The horse was discharged from the hospital the day after surgery with instructions to the owner to administer trimethoprim-sulfadiazine and phenylbutazone for 5 days. Rest and controlled exercise recommendations were identical to those of horse 2.

When horse 3 was reevaluated 4 weeks after the surgery, the owner reported that the signs of stiffness had resolved. Reexamination confirmed resolution of clinical signs. An ultrasonographic evaluation was performed 6 weeks after surgery, and healing of the caudal nuchal bursa was evident. By 18 months after surgery, the gelding had returned to its previous degree of athletic activity as a competitive trail horse with no recurrence of the previously reported signs.

A 9-year-old 608-kg (1,338-lb) Hanoverian mare (horse 4) was evaluated for a 3-week history of acute neck pain followed by a 2-week history of a prominent swelling in the poll region. The ultimate diagnosis was nonseptic cranial nuchal bursitis. This horse also underwent cranial nuchal bursoscopy. Marked proliferation of the lining of the bursal wall as well as a large amount of free-floating fibrinous material were evident. A total synovectomy was performed by use of a mo-

torized synovial resector, and the bursa was thoroughly lavaged with LRS to remove all debris and fibrinous material. Immediately after routine closure of the surgical incisions, the bursa was injected with 500 mg of amikacin sulfate.

Following an unremarkable recovery from anesthesia, the mare remained hospitalized for 5 days. Although horse 4 was still sensitive to palpation of the poll region, she had full range of motion and unremarkable head carriage. Discharge recommendations to the owner included administration of trimethoprim-sulfadiazine (30 mg/kg, PO, q 12 h) and phenylbutazone (2.2 mg/kg, PO, q 12 h) for 5 days.

Four weeks after discharge from the hospital, horse 4 was reexamined. At that time, moderate swelling, albeit significantly less swelling than originally detected, was evident in the right side of the poll. The mare did not show sensitivity to palpation of the poll region and had full range of neck motion. Ultrasonography of the region revealed moderate effusion of the bursa with anechoic fluid. The bursal wall, although still thickened, had improved from the initial examination. On the basis of these results, the cranial nuchal bursa was injected with 20 mg of hyaluronic acid.^a In addition, a recommendation was made to have the referring veterinarian repeat the hyaluronic acid injection 1 month later. By 8 months after surgery, the mare had reportedly returned to its previous degree of athletic activity as a jumper, with no recurrence of the clinical signs.

Discussion

Neck pain or stiffness in horses limits their athletic potential and can result from various secondary causes such as trauma, fractures of the cervical vertebrae,^{2,3} diskospondylitis,⁴ neurologic deficits,^{5,6} osteoarthritis associated with cervical facets,^{7,8} and supraspinous bursitis.⁹⁻¹¹ Definitive diagnosis can be difficult because of the variability in clinical signs and the common presence of concurrent lameness.^{8,10} The nuchal bursa is located above the dorsal arch of the atlas and beneath the funicular aspect of the ligamentum nuchae. Sepsis of the supraspinous and cranial nuchal bursa is reportedly a cause of neck pain in horses.⁹⁻¹⁴ To our knowledge, use of bursoscopy for treatment of septic or nonseptic bursitis affecting the cranial and caudal nuchal bursae has not been reported to date.

Three bursae are associated with the nuchal ligament and underlying spinous processes, including the atlantal or cranial nuchal bursa (bursa subligamentosa nuchalis cranialis), the caudal nuchal bursa (bursa subligamentosa nuchalis caudalis), and the supraspinous bursa (bursa subligamentosa supraspinalis).¹⁵ The cranial nuchal bursa is located dorsal to the atlas (C1) and ventral to the funicular portion of the nuchal ligament.¹⁵ The caudal nuchal bursa lies between the spinous process of the axis (C2) and the funicular portion of the nuchal ligament.¹⁵ A caudal nuchal bursa may or may not exist in any given horse, as anatomic studies^{15,f} have confirmed.^{15,f} Past postmortem examination of 25 horses revealed that cranial and caudal nuchal bursae were not always present, and no association between bursal presence and age or training

status could be found.^f Because of inconsistent bursal presence, other authors have assumed that these 2 bursae could potentially be acquired through an increase in training level.¹⁵

The clinical signs associated with cranial or caudal nuchal bursitis include signs of swelling or pain when the poll and cranial neck regions are palpated but can potentially be missed in mildly affected horses, thus creating a diagnostic challenge for equine practitioners. When the pathological process associated with the cranial or caudal nuchal bursa extends into or causes inflammation in the underlying bone, radiography or nuclear scintigraphic evaluation may be useful, as it was in evaluating horses 1 to 3. However, ultrasonography has the advantage of providing a more definitive diagnosis in most affected horses because this imaging modality allows for assessment of the soft tissue structures associated with the specific nuchal bursa as well as the surface of the underlying vertebral spinous process. Horses in this report were all evaluated with a 7.5- to 13-MHz linear transducer^f and a 5.5- to 8.5-MHz curvilinear transducer.^g The region of hair from the external occipital protuberance to C3, including the mane, was clipped dorsally and to 6 to 8 cm on each side of dorsal midline (at least to the protuberance of the transverse processes) to maximize image quality. The region from the occipital crest to the third cervical vertebrae was evaluated from midline to the transverse processes of the cervical vertebrae on each side in transverse and sagittal planes. The origin and body of the nuchal ligament; dorsal aspects, transverse processes, and dorsal articular facet joints of C1 through C3; and the overlying musculature were identified and evaluated.

The cranial and caudal bursae are a potential space and are therefore not typically identified on ultrasonograms when nondiseased, as can be the situation with other bursae.^{16,17} In the horses of this report, the nuchal bursae had evidence of synovial thickening and a central fluid pocket, located dorsal to the bony echo of the dorsum of C1 or C2 and deep to the nuchal ligament. During examination, these bursae were evident to a much larger degree on one side of the neck than another and, when sufficiently inflamed, could be detected several centimeters to the right or left of midline. Bursal fluid echogenicity in horses 1, 2, and 4 was suggestive of an increase in cellularity, total protein concentration, or gas or mineral accumulation.¹⁸ Mineral densities were present in association with the cervical vertebral bodies or within the bursa. Nuchal ligament desmitis, which was detected in horse 3, may be a cause of or consequence of bursal inflammation. Additionally, ultrasonography was useful to identify the proximity of the margins of the cranial nuchal bursa to the atlanto-occipital synovial space, which was helpful information during the surgical procedure.

Anechoic effusion and homogeneous synovium with a variable degree of thickening are most consistent with findings in nonseptic synovitis and bursitis, as was suspected in horse 3; because no bursal fluid could be obtained, this could not be confirmed. Cellular fluid or heterogeneous fluid and heterogeneous synovia are most consistent with findings in septic synovitis or bursitis, such as in horses 1 (sepsis suspected but not

confirmed) and 2 (sepsis confirmed). However, a mild increase in echogenicity of synovial fluid and a thickened synovium may also have been attributable to the increased total cell count or high synovial protein concentration characteristic of an inflammatory process¹⁸ and may not represent septic changes. These findings can be difficult to interpret (as in horse 4, which was suspected nonseptic). Ultrasonographic evaluation can be a useful adjunct in distinguishing septic from nonseptic processes prior to cytologic evaluation and bacterial culture of samples. However, in some situations, it can be difficult to distinguish septic from nonseptic findings, particularly when chronicity of the condition is taken into account.

Septic bursitis of the cranial nuchal bursa (also known as poll evil) and supraspinous bursa (also known as fistulous withers) has been described.^{10,11,19} Management recommendations for such conditions, particularly for supraspinous bursitis, have typically included open surgical debridement with the horse standing or anesthetized and long-term antimicrobial administration.⁹⁻¹¹ This treatment approach offers the benefit of being able to view the affected structures and surgically access them for debridement. The drawbacks include the need for frequent wound treatment postoperatively and a reported recurrence rate of up to 30%.^{10,11} Most associated infections in other studies were identified as caused by *Brucella abortus*,¹¹⁻¹⁴ but *Streptococcus* sp.^{9,10} and *Staphylococcus* sp.¹¹ were also isolated. With the initiation of a cooperative state-federal brucellosis eradication program in the United States in 1934, the number of infected cattle herds was reduced from 124,000 in 1956 to 6 in 2000.²⁰ As of 2008, *B abortus* only remains in a population of mainly elk within the Greater Yellowstone Area,²¹ so *B abortus* infection in horses has been eliminated.¹¹ In the present report, only bursal fluid from horse 2 yielded positive results of bacterial culture (*Staphylococcus* spp), and the other available fluid samples from horses 1 and 4 failed to yield any growth.

The horses of this report were treated with intrabursal anti-inflammatory medications such as corticosteroids and hyaluronic acid, but only a short-lived response was achieved. Although possible, we did not attempt other nonsurgical treatments such as open lavage and antimicrobial treatment. Because of the persistence of the clinical signs such as poll swelling and inability to raise or bend the neck despite aggressive medical treatment, the decision to explore the bursae via bursoscopy was made, ultimately resulting in a resolution of the clinical signs in all horses. This management decision and its results are not dissimilar to reports²²⁻²⁴ of successful management of septic and nonseptic bursitis in locations such as the calcanean, navicular, and bicapital bursae through endoscopic techniques such as the one reported here.

The advantages of bursoscopy, compared with traditional open surgical techniques, are similar to those achieved through arthroscopy and include better visibility of the entire structure, more thorough debridement, copious lavage, and excellent cosmetic appearance (because of the small nature of the incisions).²⁵ In our experience, good visibility of the cranial or caudal

nuchal bursa was obtained in each horse. The major drawback of this approach is that ultrasonographic guidance is needed for initial distention of the bursa and, depending on the amount of soft tissue thickening, during insertion of the arthroscopic sleeve. This is due to the variable location of these bursae and a lack of palpable landmarks. However, once the bursae were properly identified and distended, placement of the bursoscope and instrument portals was straightforward, with ipsilateral triangulation between portals easy to maintain.

The origin of the bursitis in the horses of this report was unclear. None of the horses had evidence of external trauma or a penetrating wound. This lack of wounds is not dissimilar to that in a report²² of calcaneal bursitis, in which focal swelling or effusion was one of the predominant examination findings, with no evidence of an obvious wound or draining tract.²² In the horses of that report, thorough lavage of the bursae endoscopically or through needles was used to varying degrees of success. In our horses, lavage through needles was not considered because of the thickness of the synovial capsule and degree of synovial proliferation, which would have complicated lavage with a large volume of fluid. We believe that in addition to effective lavage during bursoscopy, debridement of the proliferative tissue within the bursae is important to minimize the probability of recurrence of the condition.

A constant rate infusion balloon pump system with a delivery rate of 0.5 mL/h was used postoperatively in horse 1 because of the purulent fluid obtained from the bursa at the time of surgery. The use of such pump systems in treating septic synovial structures in horses has been reported.²⁶ To our knowledge, however, the only antimicrobial evaluated with regard to intra-articular concentration after constant rate infusion is gentamicin.²⁷ In that study, investigators were able to achieve between 3 to 125 times the minimal inhibitory concentration for common pathogens in various healthy tarsocrural synovial and joint tissues using a pump delivery system. Rather than using a concentration-dependent antimicrobial such as those in the aminoglycoside family, we made an empirical decision to use the time-dependent antimicrobial ticarcillin-clavulanate of the β -lactam family with the constant rate infusion system. This system would be expected to deliver this antimicrobial at a rate of 100 mg/h into the bursa, which would be anticipated to exceed the minimal inhibitory concentration of common equine pathogens.²⁸ Although the pharmacokinetics of ticarcillin-clavulanate administered into synovial structures via such delivery systems has not been described, this drug has been used effectively by the authors at this dose and rate for the last 3 years without clinically noticeable adverse effects other than focal cellulitis at the site of catheter entry. The decision to not use a similar system in horse 2, from which coagulase-negative *Staphylococcus* spp were recovered, was mainly due to surgeon preference and the overall appearance of the bursa and the bony defect after debridement.

One challenge veterinarians can face is differentiating between a septic and nonseptic inflammatory process. Only in 1 horse reported here did bacterial culture yield results, and in no horses were bacteria identified

cytologically. Definitive diagnosis of a septic process requires identification of bacteria cytologically or by bacterial culture.²⁹ In addition, septic joints can have variable total protein concentrations and total WBC counts.^{29,30} No consensus exists with respect to the joint protein concentration that is diagnostic for infection, and various upper reference limits have been suggested, ranging from 3.5 to 4 g/dL.²⁹ Several authors have suggested that total WBC counts > 10,000 or 30,000 cells/ μ L are indicative of sepsis.^{29,30} Although a septic process should always be considered in any situation in which inflammation of an unknown etiology exists in a synovial structure, obtaining a definitive diagnosis of a septic process is difficult. In the horses, a septic process could only be definitively identified in 1 horse (horse 2) but was strongly suspected in another (horse 1).

- a. Hylartin V Injection, Pharmacia & Upjohn Co, New York, NY.
- b. Depo-Medrol, Pharmacia & Upjohn Co, New York, NY.
- c. Dyonics Arthroscopic Synovial Resector, Smith & Nephew Inc, Andover, Mass.
- d. Joint Infusion System (Elastomeric Pump), Mila International Inc, Erlanger, Ky.
- e. Omnipaque Injection, GE Healthcare Inc, Princeton, NJ.
- f. Wagner WD. *Anatomical examination of the cranial and caudal nuchal subligamentous bursa of the horse using panorama ultrasonography and magnetic resonance imaging* [in German]. Dr med vet thesis, Department of Veterinary Surgery, Ludwig-Maximilians-University Munich, Munich, Germany, 2002.
- g. Technos MPX Biosound Esaote, Universal Ultrasound, Bedford Hills, NY.

References

1. Delahunta A. The neurologic examination. In: Delahunta A, Glass EN, eds. *Veterinary neuroanatomy and clinical neurology*. Philadelphia: WB Saunders Co, 2008;487–501.
2. Lopez MJ, Nordberg C, Trostle S. Fracture of the 7th cervical and 1st thoracic vertebrae presenting as radial nerve paralysis in a horse. *Can Vet J* 1997;38:112.
3. Sysel AM, Moll HD, Carrig CB, et al. What is your diagnosis? *J Am Vet Med Assoc* 1998;213:607–608.
4. Adams SB, Steckel R, Blevins W. Diskospondylitis in five horses. *J Am Vet Med Assoc* 1985;186:270–272.
5. McKelvey WA, Owen RR. Acquired torticollis in eleven horses. *J Am Vet Med Assoc* 1979;175:295–297.
6. Marks D. Cervical nerve root impingement in a horse, treated by epidural injection of corticosteroids. *J Equine Vet Sci* 1999;19:399–401.
7. Dyson SJ. The cervical spine and soft tissues of the neck. In: Ross MW, Dyson SJ, eds. *Diagnosis and management of lameness in the horse*. Philadelphia: WB Saunders Co, 2003;522–531.
8. Ricardi G, Dyson SJ. Forelimb lameness associated with radiographic abnormalities of the cervical vertebrae. *Equine Vet J* 1993;25:422–426.
9. Hawkins JF, Fessler JF. Treatment of supraspinous bursitis by use of debridement in standing horses: 10 cases (1968–1999). *J Am Vet Med Assoc* 2000;217:74–78.
10. Gaughan EM, Fubini SL, Dietze A. Fistulous withers in horses: 14 cases (1978–1987). *J Am Vet Med Assoc* 1988;193:964–966.
11. Cohen ND, Carter GK, McMullan WC. Fistulous withers in horses: 24 cases (1984–1990). *J Am Vet Med Assoc* 1992;201:121–124.
12. Roderick LM, Kimball A, McLeod WM, et al. A study of equine fistulous withers and poll evil. *Am J Vet Res* 1948;9:5–10.
13. Guard W. Fistula of the withers. *North Am Vet* 1932;13:19–23.
14. Duff H. Fistulous withers and poll-evil due to *Brucella abortus*. *Vet Rec* 1936;16:175–181.
15. Sisson S. Equine syndesmology. In: Getty R, ed. *Sisson and Grossman's the anatomy of the domestic animals*. 5th ed. Philadelphia: WB Saunders Co, 1975;349–352.

16. Reef VB. Musculoskeletal ultrasonography. In: Reef VB, ed. *Equine diagnostic ultrasound*. Philadelphia: WB Saunders Co, 1998;68–70.
17. Whitcomb MB, le Jeune SS, MacDonald MM, et al. Disorders of the infraspinatus tendon and bursa in three horses. *J Am Vet Med Assoc* 2006;229:549–556.
18. Reef VB. Musculoskeletal ultrasonography. In: Reef VB, ed. *Equine diagnostic ultrasound*. Philadelphia: WB Saunders Co, 1998;154–166.
19. Dixon P. Swellings of the head region in the horse. In *Pract* 1991;13:257–263.
20. APHIS. Facts about brucellosis. Available at: www.aphis.usda.gov/animal_health/animal_diseases/brucellosis/downloads/bruc-facts.pdf. Accessed Aug 11, 2009.
21. APHIS. Status Report—Fiscal Year 2008 Cooperative State-Federal Brucellosis Eradication Program. Available at: www.aphis.usda.gov/animal_health/animal_diseases/brucellosis/downloads/yearly_rpt.pdf. Accessed Aug 11, 2009.
22. Bassage LH II, Garcia-Lopez J, Currid EM. Osteolytic lesions of the tuber calcanei in two horses. *J Am Vet Med Assoc* 2000;217:710–716.
23. Wright IM, Phillips TJ, Walmsley JP. Endoscopy of the navicular bursa: a new technique for the treatment of contaminated and septic bursae. *Equine Vet J* 1999;31:5–11.
24. Tudor RA, Bowman KF, Redding WR, et al. Endoscopic treatment of suspected infectious intertubercular bursitis in a horse. *J Am Vet Med Assoc* 1998;213:1584–1585.
25. McIlwraith CW, Nixon AJ, Wright IM, et al. Bursoscopy. In: McIlwraith CW, ed. *Diagnostic and surgical arthroscopy in the horse*. 3rd ed. Philadelphia: Mosby Elsevier, 2005;409–426.
26. Meagher DT, Latimer FG, Sutter WW, et al. Evaluation of a balloon constant rate infusion system for treatment of septic arthritis, septic tenosynovitis, and contaminated synovial wounds: 23 cases (2002–2005). *J Am Vet Med Assoc* 2006;228:1930–1934.
27. Lescun TB, Ward MP, Adams SB. Gentamicin concentrations in synovial fluid and joint tissues during intravenous administration or continuous intra-articular infusion of the tarsocrural joint of clinically normal horses. *Am J Vet Res* 2006;67:409–416.
28. Sparks SE, Jones RL, Kilgore WR. In vitro susceptibility of bacteria to a ticarcillin-clavulanic acid combination. *Am J Vet Res* 1988;49:2038–2040.
29. Lugo J, Gaughan EM. Septic arthritis, tenosynovitis, and infection of hoof structures. *Vet Clin North Am Equine Pract* 2006;22:363–388.
30. Schneider RK. Synovial and osseous infections. In: Auer JA, Stick JA, eds. *Equine surgery*. 3rd ed. St Louis: Saunders, 2006;1121–1129.



From this month's *AJVR*

Pharmacokinetics of metformin after enteral administration in insulin-resistant ponies

Kellie D. Tinworth et al

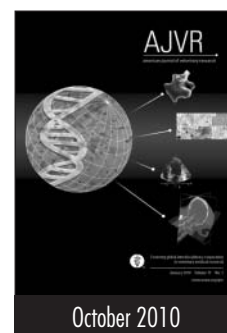
Objective—To determine pharmacokinetics and plasma steady-state kinetics of metformin after oral or nasogastric administration in insulin-resistant (IR) ponies.

Animals—8 IR ponies.

Procedures—Metformin (30 mg/kg) was administered to 8 ponies via nasogastric tube. Blood samples were collected at intervals for 24 hours. Plasma concentrations of metformin were measured via liquid chromatography–electrospray tandem mass spectroscopy. Pharmacokinetic variables were determined via noncompartmental analysis. Metformin (15 mg/kg, PO, twice daily [8 AM and 5 PM]) was administered to 4 ponies for an additional 20 days, and blood samples were obtained daily. Plasma concentration at steady state (C_{ss}) was determined.

Results—Mean \pm SD elimination half-life ($t_{1/2}$) of metformin was 11.7 ± 5.2 hours, maximal plasma concentration was 748 ± 269 ng/mL at 54 ± 32 minutes, mean area under the curve was 355 ± 92 $\mu\text{g} \cdot \text{h/mL}$, and apparent clearance was 90.6 ± 28.1 mL/min/kg. The C_{ss} was 122 ± 22 ng/mL.

Conclusions and Clinical Relevance—Metformin reportedly enhances insulin sensitivity of peripheral tissues without stimulating insulin secretion, but bioavailability in horses is low. The $t_{1/2}$ of metformin in IR ponies was similar to that in humans. Actual clearance of metformin adjusted for bioavailability in IR ponies was similar to that in humans; however, during chronic oral administration at dosages reported in efficacy studies, the C_{ss} of metformin was less than values associated with therapeutic efficacy in humans. The apparent lack of long-term efficacy of metformin in horses is likely attributable to low bioavailability, rather than to rapid clearance. (*Am J Vet Res* 2010;71:1201–1206)



See the midmonth issues
of *JAVMA*
for the expanded table of
contents
for the *AJVR*
or log on to
avmajournals.avma.org
for access
to all the abstracts.