

# Wooden, metallic, hair, bone, and plant foreign bodies in horses: 37 cases (1990–2005)

Amanda C. Farr, DVM; Jan F. Hawkins, DVM, DACVS;  
Debra K. Baird, DVM, PhD, DACVR; George E. Moore, DVM, PhD, DACPM, DACVIM

**Objective**—To characterize features of diagnosis, treatment, and outcome in horses with foreign bodies, exclusive of enteric, inhaled, and foot-penetrating foreign bodies.

**Design**—Retrospective case series.

**Animals**—37 horses with foreign bodies.

**Procedures**—The incidence of equine foreign bodies from 1990 through 2005 was determined by review of data from veterinary schools participating in the Veterinary Medical Database (VMDB). Medical records of horses with foreign bodies at Purdue University were reviewed, and the following information was retrieved: clinical history; signalment; results of physical, radiographic, and ultrasonographic examinations; results of microbial culture of the draining tract or foreign body material; surgical findings; antimicrobial and anti-inflammatory treatments; and complications of the surgical procedure. Long-term follow-up information was obtained from owners or referring veterinarians.

**Results**—The incidence of foreign bodies in horses with records in the VMDB was 17.30/10,000 horse admissions. A preoperative diagnosis of foreign bodies was confirmed via ultrasonography in most horses examined (15/17 horses) and with plain film radiography in a quarter of horses examined (7/24 horses). Wood foreign bodies were the most common (59%; 22/37), followed by metal (24%; 9/37), hair (8%; 3/37), nonsequestrum bone (5%; 2/37), and plant material (3%; 1/37). Postoperative complications associated with the foreign body were more likely to develop with wood foreign bodies (3/22) than with other types of foreign bodies (1/15).

**Conclusions and Clinical Relevance**—Wood was the most common penetrating foreign body in the horses in our study and was the type associated with the highest incidence of complications. Ultrasonography was more effective in locating foreign bodies than was radiography (plain and contrast) and should be performed in all horses with suspected foreign bodies. (*J Am Vet Med Assoc* 2010;237:1173–1179)

Foreign body penetration secondary to self-inflicted trauma is a common means by which horses become wounded. Various foreign materials causing wounds, draining tracts, and focal swelling have been described.<sup>1–3</sup> These include wood, plant material, metal, glass, hair, bone, plastic, gravel, and teeth.<sup>2</sup> Reported sites of foreign body penetration include the head, trachea, trunk, thoracic cavity, abdomen, and soft tissues and synovial structures of the limbs.<sup>1–4</sup>

In some horses, foreign bodies are grossly visible during an initial physical examination, making diagnosis prompt. When foreign bodies are not readily visible, typical clinical signs of penetration include focal swelling, a nonhealing wound, a draining tract, or lameness.<sup>3–5</sup> Owners commonly do not observe the traumatic injury, or they neglect to mention that a traumatic incident may have occurred several months to years prior to the time their horses receive veterinary attention. Although there are reports<sup>4,6</sup> of foreign bod-

## ABBREVIATIONS

CI	Confidence interval
VMDB	Veterinary Medical Database

ies in specific locations and of specific foreign body materials, to our knowledge there have been no retrospective studies designed to characterize the clinical signs and management of a large group of horses with various foreign body types and locations. The purpose of the study reported here was to characterize features of the diagnosis, treatment, and outcome for horses with foreign bodies, exclusive of enteric, inhaled, and foot-penetrating foreign bodies.

## Materials and Methods

**Case selection**—Purdue University medical records of horses with a diagnosis of foreign body from January 1990 through December 2005 were retrieved by use of the VMDB,<sup>a</sup> which is a database containing patient data from participating veterinary teaching hospitals across North America. Foreign bodies related to penetrating injuries of the foot were excluded, as were foreign bodies associated with the bronchial structures and lungs and gastrointestinal foreign bodies arising from ingestion. Bone fragments located in the soft

From the Veterinary Teaching Hospital (Farr) and the Departments of Veterinary Clinical Sciences (Hawkins, Baird) and Comparative Pathobiology (Moore), School of Veterinary Medicine, Purdue University, West Lafayette, IN 47907.

Use of data from the Veterinary Medical Database does not imply the organization's approval of the subject of the report or study.

Address correspondence to Dr. Farr (farrvet@yahoo.com).

tissues but not associated with a bone involucrum or cloacae were included (eg, not a sequestrum associated with periosteal disruption).

**Medical records review**—Information obtained from the records included clinical history; signalment; results of physical, radiographic, and ultrasonographic examinations; microbial culture of the draining tract or foreign body material; surgical findings; antimicrobial and anti-inflammatory treatments; and complications of the surgical procedure. To establish the reported incidence of equine foreign bodies, from the same period as our study (1990 to 2005), records of the veterinary hospitals belonging to the VMDB were searched. Equine foreign body counts reported to the VMDB were totaled per institution and compared with the total cases of foreign bodies in horses reported to the VMDB per institution. The total incidence of foreign body cases for all participating institutions was compared with the incidence for Purdue University.

Clinical history included the history of the trauma, duration of the complaint, and type of treatment performed prior to referral to the veterinary teaching hospital at Purdue University. All horses received a complete physical examination, combined with a lameness examination whenever lameness was the complaint for which a horse was initially evaluated. The presence or absence of a draining tract was recorded. In most horses with a draining tract, a malleable probe<sup>b</sup> was used to determine the depth, direction, and extent of the draining tract.

**Diagnostic imaging**—At least 2 radiographic views/horse were obtained to aid in the detection of radiopaque foreign bodies. Digital radiography was not used in any horse. When a radiopaque foreign body was not observed, contrast radiography was used in some horses to determine the extent of the draining tract or detect filling defects compatible with foreign bodies. In general, contrast radiography was performed after the insertion of a Foley catheter into the draining tract or after direct instillation of contrast media into the draining tract with a syringe. Ten to 20 mL of iodinated contrast material<sup>c</sup> was injected into the tract. When contrast radiography was not used, a malleable metallic probe was placed into the draining tract, followed by plain film radiography to determine the extent of the draining tract.

Ultrasonography was also used to identify foreign bodies not visible with radiography. Following routine preparation of the skin, including clipping and scrubbing with an antiseptic soap solution, the area surrounding the draining tract was examined via ultrasonography. Probe frequencies ranged from 3.5 to 10 MHz. All draining tracts were examined in planes cross-sectional and longitudinal to their terminus. An abnormal hyperechoic area, acoustic shadowing, presence of a hypoechoic rim of fluid, and reverberation artifacts were compatible with the presence of a foreign body.<sup>7</sup>

The type of surgery performed (horse standing and sedated or horse recumbent and anesthetized), surgery duration (from incision to closure), and type of foreign body removed were retrieved from the medical records. Surgery-associated complications were also recorded.

Microbial culture of material from draining tracts or foreign bodies included aerobic culture and, in 1 instance, anaerobic culture. Antimicrobial susceptibility testing was performed on all microbial isolates recovered.

Follow-up information was collected from owners or referring veterinarians via telephone interview or e-mail survey. Respondents were asked whether the site of the foreign body had healed without complications after discharge from the veterinary teaching hospital, whether any lameness associated with the foreign body had resolved, whether the horse returned to its prior or expected degree of work, whether the owner was satisfied with the treatment received at the teaching hospital, and whether the owner still owned the horse.

**Statistical analysis**—Findings were summarized as percentages of affected horses and 95% CIs. The incidence of foreign bodies was calculated as the number of horses affected divided by the total number of horses admitted to all veterinary hospitals in the VMDB database or to the study hospital alone. The Cohen  $\kappa$  statistic was calculated to evaluate agreement between radiography and ultrasonography for detection of foreign bodies. A  $\chi^2$  test was used to compare the proportion of foreign bodies detected via ultrasonography with the proportion detected via radiography. A value of  $P < 0.05$  was considered significant.

## Results

**Foreign body incidence**—Review of records from all 18 veterinary teaching hospitals participating in the VMDB revealed that a diagnosis of foreign body was made in 322 horses of 186,102 total horse admissions. Therefore, the incidence of foreign body penetration in participating veterinary schools was 17.30/10,000 admissions. The median incidence was 18.88/10,000 admissions (range, 3.84 to 32.46/10,000 cases). The reported incidence for the study institution was 14.79/10,000 admissions.

**Signalment**—Thirty-seven horses fulfilled the criteria for inclusion in the study. The median age was 6 years (range, 1 to 25 years). There were 20 mares, 16 geldings, and 1 sexually intact male. Breeds represented included Quarter Horse ( $n = 17$ ), Thoroughbred (4), Paint (3), Standardbred (3), Tennessee Walking Horse (2), and 1 each of Appaloosa, Arabian, and Haflinger. There were 5 other horses comprising breeds not recognized by the hospital information system. The horses' athletic discipline or type of work was not available in the medical record.

**Clinical history and abnormal physical examination findings**—Twenty-three horses had historical evidence of trauma, which was recent (within 12 hours before evaluation at the hospital) in 4 horses. Fence-related accidents were the most common causes of known trauma (7); only 3 horses were injured while being worked. A draining tract was present in 24 of 37 horses (65%; 95% CI, 48% to 80%), with duration of drainage ranging from 3 to 730 days. Other clinical signs evident at evaluation included a visible foreign body ( $n = 3$  horses), ptyalism (3), dyspnea and inspiratory wheezing (2), recent puncture wound (2), lameness following removal of a nail from the tarsus (1), inguinal and limb swelling (1), and carpal joint swelling (1).

**Clinicopathologic analyses**—A CBC and serum biochemical analysis were performed in 8 horses, and a CBC alone was performed in 5 horses. Abnormal CBC findings included a stress leukogram ( $n = 11$  horses) and hyperfibrinogenemia (5). Serum biochemical abnormalities included altered acid-base status (8), hyperglycemia (6), and electrolyte imbalances (5).

**Diagnostic imaging**—Plain film radiography (digital imaging was not available at the time of the study) was performed in 24 horses. Thirteen horses were not radiographed. Reasons for failure to obtain radiographs included foreign bodies in the proximal portion of the limb or axial skeleton ( $n = 9$  horses), obvious foreign bodies not requiring imaging (3), and death prior to radiography (1). No radiographic abnormalities were detected in 8 horses. Fistulograms were obtained in 3 horses and were successfully used to identify foreign bodies in 2 (Figure 1). Filling defects were present in 2 horses with wood foreign

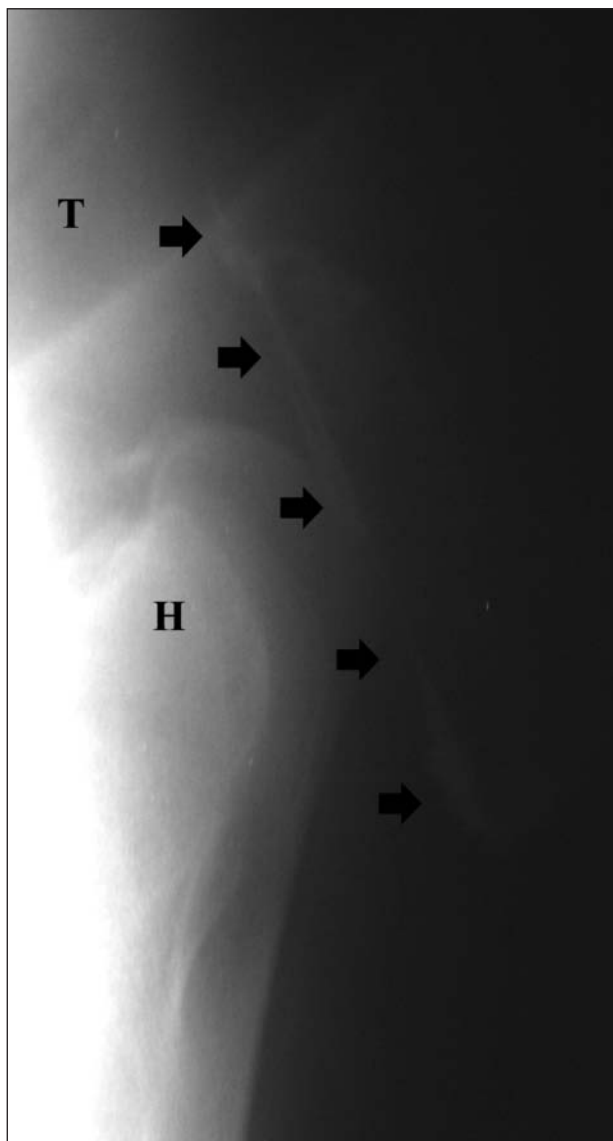


Figure 1—Lateral radiographic view (lateromedial beam orientation) of the shoulder region of a 13-year-old Quarter Horse with a wood foreign body (arrows) identified via contrast radiography. H = Humerus. T = Trachea.

bodies, and examination of the fistulogram in the other horse with hair as a foreign body yielded negative results. Abnormal radiographic findings included gas in the soft tissue ( $n = 6$  horses), dystrophic mineralization (3), bone lysis (1), soft tissue swelling (1), and poorly defined radiopacity within the soft tissue (1). Plain film radiography enabled detection of all (6) metal foreign bodies and 1 bone foreign body (29%; 7/24). It did not aid in detection of any wood, hair, or plant foreign bodies.

Ultrasonography was performed in 17 horses, with a foreign body visible in 15 (88%; 95% CI, 64% to 99%). The most common ultrasonographic finding was the presence of an obvious foreign body; additionally, changes in echogenicity within associated tracts and acoustic shadowing were recorded. For the 2 horses in which a foreign body was not identified, 1 initially had a fibrous tract detected with no foreign body, but ultrasonography repeated 2 days later led to detection of a wood foreign body. The second horse had a foreign body in another location detected during postmortem examination. Foreign bodies successfully identified with ultrasonography included wood (7/9), metal (6/6), and hair (2/3).

In 13 horses, both radiography and ultrasonography were used to locate a foreign body. Ultrasonography was used in 9 of these horses, 4 of which had radiographic findings suggestive of a foreign body. In 3 horses, the foreign body was visible with both diagnostic methods. In 1 horse, the foreign body was not detected with either method. Foreign bodies were located with either plain film radiography or ultrasonography in 21 of 27 (78%) horses. In the 13 horses in which both imaging methods were used, there was poor agreement between the 2 modalities ( $\kappa = 0.045$ ;  $P = 0.284$ ). Although there were 4 horses with identical findings (3 positive and 1 negative), 9 horses had identifiable foreign bodies only on ultrasonography (ie, negative on radiography). Thus, overall, ultrasonography was significantly ( $P < 0.001$ ) more sensitive than radiography in identifying foreign bodies. Ultrasonography was used to detect foreign material in 15 of 17 horses (88%; 95% CI, 64% to 99%), whereas radiography only identified foreign bodies in 7 of 24 horses (29%; 95% CI, 13% to 51%).

Of 37 horses, a foreign body was identified in 24 (65%) with either diagnostic imaging ( $n = 21$  horses) or physical examination (3) prior to surgery. A foreign body was diagnosed in the remaining 13 horses during surgery.

**Surgery**—Of 37 horses with a foreign body, 34 were surgically treated. Of the 3 horses that did not undergo surgery, 1 horse was euthanized shortly after initial evaluation because secondary septic pleuritis and peritonitis had developed. Necropsic evaluation of the euthanized horse revealed a 30 × 4-cm tree branch embedded in the right dorsal colon; the branch had apparently entered the thorax at the eighth intercostal space and penetrated the right caudal lung lobe and the right crus of the diaphragm. A second horse died during attempts to relieve severe respiratory distress due to severe retropharyngeal swelling. Necropsic evaluation of that horse revealed a wood fragment embedded in the tongue and was treated conservatively with a successful outcome. Data from the 2 horses that died were not included in summarized surgical data.



General anesthesia was performed in 24 horses. Ten horses had the foreign body removed while standing with chemical restraint and local anesthesia (lidocaine or mepivacaine). For surgical procedures in standing horses, sedation included xylazine hydrochloride (0.5 to 1.1 mg/kg [0.2 to 0.5 mg/lb], IV) or detomidine hydrochloride (0.02 to 0.04 mg/kg [0.009 to 0.02 mg/lb], IV) and butorphanol tartrate (0.2 to 0.4 mg/kg [0.09 to 0.2 mg/lb], IV). Surgery duration ranged from 35 to 145 minutes.

In 13 horses, intraoperative location of the foreign body was aided by the use of probes (including malleable probes, hemostats, digital palpation, and a spinal needle). Malleable probes were used successfully in 5 of 8 horses with foreign body penetration (4 wood and 1 bone). For the 3 unsuccessful cases, 2 were wood foreign bodies that were surgically identified at a depth greater than the probe's length, and the third was a wire foreign body that could not be located with a probe but was identified via ultrasonography. Hemostats were used successfully in 2 horses with wood foreign bodies. When a probe was used, the skin and subcutaneous tissues were incised over it to access the foreign body and tract. Digital palpation was successfully used to locate foreign bodies in 2 horses (1 metal and 1 wood). A spinal needle was used in combination with intraoperative ultrasonography in 1 horse to locate a metallic foreign body. Methylene blue was instilled into the draining tract via a Foley catheter inserted into the draining tract in 4 horses, and in all instances, the foreign body (2 bone and 2 wood) was located and completely removed. When a probe was not used, the draining tract was incised from the skin wound until the foreign body was encountered. Among the 13 horses with no draining tract, ultrasonography was used successfully in 1 to guide the surgical incision. In another horse, a malleable probe and fluoroscopy were used to determine the position of the metallic foreign bodies (air rifle pellets), and in another horse, fluoroscopy was performed successfully to ensure all foreign body fragments (wire) had been removed.

Following location and removal of the foreign body, the pyogenic membrane and any necrotic material were sharply excised until healthy-appearing tissue remained; then, wound lavage was performed. Primary wound closure was performed in 21 horses with a portion of the incision left open ventrally in 8 horses. Twelve wounds were left open to heal by second intention. Penrose drains were placed in 4 horses, and a cast was placed 2 days postoperatively on 1 horse to immobilize it and thereby prevent further excessive movement at the incision site.

**Foreign bodies**—Foreign bodies removed included wood (n = 22 horses), metal (9), hair (3), non-sequestrum-type bone (2), and plant material (1). Wood foreign bodies ranged in size from multiple small splinters (up to 100 in 1 horse) to a 30 × 40-cm tree branch embedded in the abdomen. One horse from which 3 pieces of wood were removed from the inguinal area died in recovery as a result of septic or endotoxic shock following exploratory surgery. Metal foreign bodies included wire (n = 4 horses), air rifle pellets (2), a metal pin (1), and a farrier's shoeing stand (1). The horse in which the shoeing stand was present (in the paracostal region) was

euthanized during surgery because of cecal penetration and fulminant peritonitis. Foreign body locations, irrespective of type, included the shoulder area (n = 6 horses), oropharynx (6), radius (3), pectoral region (3), stifle area (3), abdomen (2), elbow area (2), proximal phalangeal (pastern) area (2), coronary band (1), gluteal muscles (1), heel bulb (1), tarsus (1), infraorbital area (1), inguinal region (1), poll (1), caudal aspect of the thigh (1), thorax (1), and withers (1). Nonsequestrum bone was located in the midthigh in 1 horse and in the caudal portion of the antebrachium in another. There was no discernible pattern to predict type of foreign body and its location within the horse.

**Antimicrobial and analgesic treatment**—Antimicrobials were used in 24 horses, and a combination of antimicrobials was used in 7 of these. Antimicrobials used included trimethoprim-sulfamethoxazole (15 to 30 mg/kg [7 to 14 mg/lb], PO, q 12 h), penicillin G procaine (10,000 to 40,000 U/kg [5,000 to 20,000 mg/lb], IM, q 12 h), gentamicin sulfate (6.6 mg/kg [3 mg/lb], IV, q 24 h), penicillin G potassium (22,000 to 44,000 U/kg [10,000 to 20,000 mg/lb], IV, q 6 h), and metronidazole (10 to 25 mg/kg [5 to 12 mg/lb], PO, q 6 to 12 h).

Nonsteroidal anti-inflammatory medications were used in 21 horses. These medications included phenylbutazone (4.4 to 8.8 mg/kg [2 to 4 mg/lb], IV or PO, q 12 to 24 h), flunixin meglumine (1.1 mg/kg [0.5 mg/lb], IV or PO, q 12 h), and dimethyl sulfoxide (1 g/kg [0.5 mg/lb] as a 10% to 20% solution, IV, q 24 h). Dexamethasone (5 to 20 mg, IV, q 24 h) was used in 1 horse.

**Microbiology**—Microbial culture and antimicrobial susceptibility testing were performed in 7 horses, and organisms were isolated from samples obtained from 5 horses. Polymicrobial infections were identified in 2 horses. Bacterial species in monomicrobial infections included group C  $\beta$ -hemolytic *Streptococcus* sp, *Staphylococcus epidermidis*, and *Enterococcus* sp. Bacterial species involved in the polymicrobial infections included *Enterococcus* sp; group B  $\beta$ -hemolytic *Streptococcus* sp with *Klebsiella pneumoniae*; and group C  $\beta$ -hemolytic *Streptococcus* sp with *Escherichia coli*.

**Outcomes**—Complete surgical removal of the foreign body was ultimately successful in 33 of the 34 (97%) surgically treated horses. Complete surgical removal was achieved at the initial surgery in 32 horses, and 2 horses required > 1 surgical procedure to remove foreign material.

Seven of the 34 (21%) horses were brought to the hospital on multiple occasions. Two of these horses had multiple surgical procedures to remove additional wood fragments. Clinical signs successfully resolved in 1 horse following the second procedure, and the other horse continued to have active draining tracts. Following the second surgical procedure to address the persistent draining tracts (23 months after the first), the wound continued to drain even though additional wood fragments were removed. Foreign bodies had been diagnosed in 3 horses at the initial evaluation but the horses were returned 2 months to 1 year later for surgical removal of the foreign bodies (wire, air rifle pellet, and wood). One horse was brought in twice on the same day: the foreign body was not detected during the initial visit, and the horse was returned later after

the owner palpated the wood foreign body below the skin and to the side of the wound. In that horse, the site healed with no complications. One horse had 2 air rifle pellets removed from the stifle and returned 1 year later because of a new draining tract in the shoulder, from which a third pellet was removed.

**Complications**—Postoperative complications were recorded for 8 horses and included temporary radial nerve paralysis, laminitis, septic flexor tenosynovitis, repeated esophageal obstruction, delayed healing, and long-term incisional drainage. One horse developed temporary radial nerve paralysis following anesthesia, which resolved within 48 hours. In another horse, laminitis developed postoperatively in all feet following removal of a wood foreign body in the shoulder region. Following discharge from the hospital, the clinical signs of laminitis worsened and that horse was euthanized. Septic flexor tenosynovitis developed in 1 horse following the removal of a wood foreign body in the pastern area of the flexor tendon sheath. It eventually healed without additional complications. One horse developed recurrent esophageal obstruction after removal of a wood foreign body from the soft palate. Delayed healing (between 6 and 9 months) occurred in 1 horse after the removal of hair from its heel bulb.

Three horses had long-term drainage following the removal of wood foreign bodies, which resolved in 1 horse after a month. For the second horse, the referring veterinarian removed another piece of wood approximately 1 year after the initial visit to the teaching hospital. The third horse was lost to long-term follow-up but reportedly had not healed after several years.

**Follow-up**—Thirty-three horses were discharged from the hospital (89%; 95% CI, 75% to 97%). Two horses were reexamined at the teaching hospital. Both returned within 2 weeks after discharge, and in both horses, the surgical sites were healing well; no lameness was evident at that time. Neither horse was available for long-term follow-up. Three additional horses were lost to follow-up.

Long-term follow-up (median, 7.7 years; range, 12 days to 11.75 years) was available for 28 horses. Owners were questioned regarding the appearance of the foreign body site following object removal. Twenty-five (89%; 95% CI, 72% to 98%) owners reported that the foreign body site healed with no complications, and 4 reported continued wound drainage. For the 4 horses with continued wound drainage, 2 wounds ultimately resolved. In one of these horses (hair foreign body in the medial heel bulb), drainage resolved over 9 months without additional treatment. In the other, drainage resolved 9 months after hospital admission, when the referring veterinarian removed another piece of wood from the draining tract. For the 2 horses with continued drainage, 1 horse was evaluated 3 times over a 33-month period. At each visit, a wood fragment was removed from the draining tract. The owners sold the horse after the third visit because the drainage and lameness never resolved and the horse could not return to race training. The second horse had continued drainage with severe secondary laminitis and was euthanized because of the laminitis. In all 7 horses admitted to the hospital for lameness, the

lameness reportedly resolved after foreign body removal. Twenty horses returned to their expected or previous degree of work; of the 8 that did not, 2 were prevented from doing so because of problems unrelated to the foreign body. All 28 owners were satisfied with the treatment and long-term outcome.

## Discussion

The most common clinical sign of an indwelling foreign body is persistent wound drainage or a nonhealing wound. Foreign bodies can result in chronic wound infection secondary to bacterial production of biofilms.<sup>8</sup> Bacterial biofilms result when certain bacteria colonize and adhere to a substrate and permanently attach. In most instances, wound drainage will not resolve until the foreign material has been removed because the biofilm protects the bacteria from antimicrobials and host defense mechanisms.<sup>8,9</sup> Therefore, when wound drainage continues following surgical or antimicrobial treatment, foreign material is most likely remaining within the wound. In the study reported here, microbial culture and identification yielded no useful information regarding antimicrobial choice and wound healing.

Foreign bodies in horses are a diagnostic challenge because they may not be readily identified following physical examination and diagnostic imaging. When possible, establishment of the presence of a foreign body and determination of the type and location of foreign material prior to surgical exploration are helpful. As was apparent in our study, plain film radiography was not as effective as ultrasonography in confirming the location of the foreign body. Plain film radiography led to the accurate detection of metallic foreign bodies; all diagnoses were confirmed prior to surgery. On the other hand, plain film radiography did not detect any of the wood, hair, or plant material foreign bodies. Use of contrast fistulograms was beneficial in 2 of 3 horses for confirming the presence of a foreign body and should be considered as a diagnostic aid whenever possible. Because many foreign bodies are radiolucent (ie, wood, hair, or plant material), a contrast fistulogram may provide additional information in the form of a filling defect.<sup>7,10</sup>

The other limitation of plain film radiography is the difficulty in obtaining diagnostic images of the trunk and axial skeleton. In our study, foreign body location did not affect the sensitivity of plain film radiography; only metallic foreign bodies were visible regardless of location. Recently, digital radiography has been made available to veterinary referral centers and private practices and may increase the diagnostic usefulness of radiographic identification and confirmation of foreign bodies. In humans, computed radiography at a computer workstation is more effective than plain film radiography or hard film computed radiography in helping to diagnose radiolucent foreign bodies.<sup>11</sup>

In the study horses, ultrasonographic examination was more effective than plain film radiography in confirming the presence of a foreign body. This finding is supported by the results of other studies<sup>11-13</sup> in other species including dogs and people. Ultrasonography provides a dynamic image, which allows determina-

tion of the direction of the tract and the depth of the foreign body.<sup>4</sup> In the hands of an experienced operator, ultrasonography can identify all types of foreign bodies, including those with a radiopacity similar to soft tissue (ie, wood, hair, and plant material). Acoustic shadowing and reverberation artifacts are commonly visible deep to the foreign body and may aid in detection. In addition, the inflammatory response around the foreign body can create a hypoechoic rim, which can improve the sensitivity and specificity of ultrasonography for identifying foreign bodies.<sup>7</sup> Ultrasonography also allows examination of structures surrounding the foreign body prior to surgery and can aid in determination of location and depth of the foreign body.<sup>7,12</sup>

Limitations to ultrasonographic examination include operator inexperience, a false-positive diagnosis of a foreign body due to air or gas in the tract, and limited detection of foreign bodies adjacent to bone or within deep tissues given the lack of reverberation or shadowing artifacts.<sup>7,14</sup> In the present study, ultrasonography was not performed in all horses for various reasons, including clinician preference, clinical impression at the initial evaluation, and failure to believe ultrasonography would be useful diagnostically. In 88% of horses that were so examined, however, ultrasonography was successful in detecting foreign bodies, regardless of their location within the body. Furthermore, all types of foreign bodies, including metal, wood, and hair, were detectable. Another benefit of ultrasonography relative to radiography is that ultrasonography can be used percutaneously to identify foreign bodies within the axial skeleton and the appendicular skeleton that are inaccessible to radiography. It can also be used within the wound intraoperatively and intraorally.<sup>6</sup>

Surgical removal of foreign bodies comes with unique challenges because the presence of a foreign body cannot always be confirmed prior to surgery. This leaves the surgeon with a decision as to how to best approach exploration of the draining tract and how vigorously to search for a foreign body. Insertion of metallic probes into the draining tract was the most commonly used technique in the present study. Metallic probes are easy to use, but they do not always allow for complete identification and removal of the draining tract because it is easy to lose or disrupt the tract leading to the foreign body during surgical dissection. To better identify the draining tract during surgical dissection, instillation of a dye such as methylene blue should be considered. Methylene blue is widely used in humans for the exploration of draining tracts associated with the skin and gastrointestinal and urogenital tracts.<sup>15-17</sup> Methylene blue stains the entire length of the draining tract and the foreign body itself, facilitating complete removal of all foreign material. The authors have not identified any complications secondary to the use of methylene blue. In fact, in humans, the introduction of methylene blue into a pilonidal sinus prior to surgery can lead to halving of the recurrence rate.<sup>16</sup>

The final intraoperative aid that may be useful is diagnostic ultrasonography. By this method, the foreign body is identified via ultrasonography, and then needles or other metallic markers are used to pinpoint the location of the foreign body. Again, a limitation to

intraoperative ultrasonography is that the presence of air within the draining tract can inhibit visualization of a foreign body or lead to a false-positive diagnosis. Use of intraoperative ultrasonography should also be considered following removal of foreign material to ensure complete surgical removal. Intraoperative ultrasonography was used in only 1 horse in our study (with a metallic foreign body), but it would appear wise to use it in all situations in which a wood foreign body is encountered to aid in the location and removal of any additional fragments.

Wood was the most common type of foreign body in our study and was associated with the highest postoperative complication rate. Diagnosis of wood foreign bodies prior to surgical intervention is challenging because most cannot be identified with plain film radiography. This finding has also been reported for dogs and humans with wood foreign bodies.<sup>11,12,14,18</sup> Fortunately, ultrasonography was useful in locating wood foreign bodies prior to surgical exploration of the wound. Therefore, in all horses with suspected wood foreign bodies, ultrasonography and contrast radiography should be considered.

In many study horses, wood foreign bodies were composed of multiple splinters or fragments, making complete surgical removal difficult. Wood foreign bodies were associated with most of the postoperative complications and unscheduled repeated visits. Incomplete foreign body removal was the main cause of complications, including continued wound drainage, laminitis in all 4 feet with continued wound drainage, and septic flexor tenosynovitis. Postoperative care, including bandaging, antimicrobials, and anti-inflammatories, did not affect the complication rate.

Metallic foreign bodies were the second most common type of foreign body. These were readily diagnosed with plain film radiography, so preoperative diagnosis was not as challenging as for nonradiopaque foreign bodies. Despite this, surgical removal of metallic foreign bodies can be difficult because of the blending of the metal with the soft tissues and the uncertain orientation of the metal within the draining tract. As for other types of foreign bodies, staining of the draining tract with methylene blue and intraoperative ultrasonography are useful. Intraoperative ultrasonography can also be used to aid in triangulation of the foreign body with ultrasound-guided needle placement, as has been demonstrated in another study.<sup>6</sup> An incision is then made along the path of the needle to remove the foreign body.

Hair has been recognized as a cause of sinus formation in human hairdressers and of prostatic granuloma formation following needle core biopsy of the prostate<sup>19-22</sup> but not as a cause of fistulous wound drainage in horses. In the horses of the present study, hair was most likely pushed into the wound through external trauma. Once under the skin and embedded in the soft tissue, the hair would serve as a foreign body. Wound drainage resolved following surgical removal of hair from affected horses. Interestingly, hair foreign bodies have been detected in infected synovial structures (eg, joints and tendon sheaths) secondary to external wounding from endoscopic examination of these structures in horses.<sup>23</sup> Hair foreign bodies can also be diagnosed with ultrasonography.



In the past, bone foreign bodies had not been identified in horses. However, 2 study horses had bone fragments located within the soft tissues of the thigh region and antebrachium in the absence of an origin for the bone fragments (ie, there was no radiographic evidence of an involucrum or cloacae from the surrounding bones). Therefore, the source for these bone fragments was not evident preoperatively or during surgery. Nonetheless, bone fragments not associated with bone sequestration should be considered as a cause of chronic wound drainage in some horses. The identification and removal of these bone fragments was readily accomplished following the staining of the draining tract with methylene blue.

The findings of our study suggested that ultrasonography as a diagnostic tool is significantly more sensitive than plain film radiography in locating and ensuring complete removal of foreign bodies. Use of methylene blue to stain the draining tract associated with the wound tract also helped in detecting both the foreign body and additional deep tracts and foreign body fragments. Long-term prognosis regardless of postsurgical treatment was good in most study horses, provided that all foreign material was removed. This was particularly important in horses with wood foreign bodies, in which multiple splinters could be present within the tract and surrounding tissue.

The VMDB incidence data suggested that foreign bodies in horses are not common. The incidence of foreign bodies diagnosed in horses at our institution was comparable to other veterinary schools participating in the VMDB. Therefore, the authors believe that the diagnostic and treatment methods described in this report should be applicable to other horses evaluated at North American veterinary clinics for clinical signs suggestive of foreign body penetration.

- a. Veterinary Medical Database [database online]. Urbana, Ill: Association of Veterinary Medical Data Program Participants. Available at: [www.vmdb.org/](http://www.vmdb.org/). Accessed between July 31, 2005 and March 29, 2009.
- b. Metallic probe, Catalog No.10-12-NS, Miltex, York, Pa.
- c. Ultravist (Iopromide), 300 mg/mL, Bayer Healthcare, Pittsburgh, Pa.

## References

1. Rademacher N, Furst A, Kaser-Hotz B. Ultrasonographic detection of a wooden foreign body in a horse. *Vet Rec* 2006;158:739–740.
2. Shah ZR, Crass JR, Oravec DC, et al. Ultrasonographic detection of foreign bodies in soft tissue using turkey muscle as a model. *Vet Radiol Ultrasound* 1992;33:94–100.
3. Boyse TD, Fessell DP, Jacobson JA, et al. US of soft-tissue foreign bodies and associated complications with surgical correlation. *Radiographics* 2001;21:1251–1256.
4. Kiper ML, Wrigley R, Traub-Dargatz J, et al. Metallic foreign bodies in the mouth or pharynx of horses: seven cases (1983–1989). *J Am Vet Med Assoc* 1992;200:91–93.
5. Stick JA. Management of sinus tracts and fistulas. In: Auer, JA, Stick JA, eds. *Equine surgery*. 3rd ed. St Louis: WB Saunders Co, 2006;305–308.
6. Pusterla N, Latson KM, Wilson D, et al. Metallic foreign bodies in the tongues of 16 horses. *Vet Rec* 2006;159:485–488.
7. Reef VB. Ultrasonographic evaluation of small parts. In: *Equine diagnostic ultrasound*. Philadelphia: WB Saunders Co, 1998;480–544.
8. James GA, Swogger E, Wolcott R, et al. Biofilms in chronic wounds. *Wound Repair Regen* 2008;16:37–44.
9. Bjarnsholt T, Kirketerp-Moller K, Jensen PO, et al. Why chronic wounds will not heal: a novel hypothesis. *Wound Repair Regen* 2008;16:2–10.
10. Wallack ST. Fistulography—dog and cat. In: *The handbook of veterinary contrast radiology*. Solana Beach, Calif: San Diego Veterinary Imaging Inc, 2003.
11. Reiner B, Siegel E, McLaurin T. Evaluation of soft-tissue foreign bodies: comparing conventional plain film radiography, computed radiography printed on film, and computed radiography displayed on a computer workstation. *AJR Am J Roentgenol* 1996;167:141–144.
12. Jacobson JA, Powell A, Craig JG, et al. Wooden foreign bodies in soft tissue: detection at US. *Radiology* 1998;206:45–48.
13. Staudte KL, Hopper BJ, Gibson NR, et al. Use of ultrasonography to facilitate surgical removal of non-enteric foreign bodies in 17 dogs. *J Small Anim Pract* 2004;45:395–400.
14. Cartee RE, Rumph PF. Ultrasonographic detection of fistulous tracts and foreign objects in muscles of horses. *J Am Vet Med Assoc* 1984;184:1127–1132.
15. Sharma N, Huston TL, Simmons RM. Intraoperative intraductal injection of methylene blue dye to assist in major duct excision. *Am J Surg* 2006;191:553–554.
16. Doll D, Novotny A, Rothe R, et al. Methylene blue halves the long-term recurrence rate in acute pilonidal sinus disease. *Int J Colorectal Dis* 2008;23:181–187.
17. Obermeyer RJ, Knauer EM, Millie MP, et al. Intravenous methylene blue as an aid to intraoperative localization and removal of the adrenal glands during laparoscopic adrenalectomy. *Am J Surg* 2003;186:531–534.
18. Armbrust LJ, Biller DS, Radlinsky MG, et al. Ultrasonographic diagnosis of foreign bodies associated with chronic draining tracts and abscesses in dogs. *Vet Radiol Ultrasound* 2003;44:66–70.
19. Patel MR, Bassini L, Nashad R, et al. Barber's interdigital pilonidal sinus of the hand: a foreign body hair granuloma. *J Hand Surg [Am]* 1990;15:652–655.
20. Schroder CM, Merk HF, Frank J. Barber's hair sinus in a female hairdresser: uncommon manifestation of an occupational dermatosis. *J Eur Acad Dermatol Venereol* 2006;20:209–211.
21. Day DS, Carpenter HD Jr, Allsbrook WC Jr. Hair granuloma of the prostate. *Hum Pathol* 1996;27:196–197.
22. Ventura L, Martini E, Di Nicola G, et al. Hair granuloma of the prostate. A clinically silent, under-recognized complication of needle core biopsy. *Histopathology* 2006;49:654–656.
23. Wright IM, Smith MWR, Humphrey DJ, et al. Endoscopic surgery in the treatment of contaminated and infected synovial cavities. *Equine Vet J* 2003;35:613–619.