

# Outcomes of podotrochlear (navicular) bursa injections for signs of foot pain in horses evaluated via magnetic resonance imaging: 23 cases (2005–2007)

Chris D. Bell, DVM; Rick D. Howard, DVM, PhD, DACVS; D. Scott Taylor, DVM, DACVS; Ed D. Voss, DVM, DACVIM; Natasha M. Werpy, DVM, DACVR

**Objective**—To determine clinical outcome following intrathecal injection of the podotrochlear (navicular) bursa for signs of foot pain in horses evaluated via magnetic resonance imaging (MRI) and evaluate efficacy of corticosteroids administered with or without hyaluronate.

**Design**—Retrospective case series.

**Animals**—23 horses.

**Procedures**—Data collected included signalment, history, intended use, duration and severity of lameness, results of diagnostic anesthesia, radiographic abnormalities, MRI abnormalities, and outcomes for return to use.

**Results**—MRI was conducted on 23 horses with lameness localized to the foot. Thirteen horses had bilateral forelimb lameness, and 10 had unilateral forelimb lameness. Mean duration of lameness was 10.5 months. Seventeen of 23 (74%) horses had excellent outcomes and returned to intended use within 2 to 4 weeks after navicular bursa injection. Hyaluronate treatment was not associated with outcome; however, horses receiving < 10 mg of trimacilone had significantly worse outcomes than those treated with hyaluronate. Among horses with excellent outcomes, mean duration of soundness was 7.3 months. Seven of 8 horses with erosive lesions of the flexor surface of the distal sesamoid (navicular) bone diagnosed via MRI had a poor outcome. Horses with navicular bursitis responded optimally to injection, compared with horses with other problems.

**Conclusions and Clinical Relevance**—Results suggested that intrathecal injection of corticosteroid in horses with erosions of the flexor surface of the navicular bone associated with deep digital flexor tendon adhesions yielded a poor response. Treatment of horses with navicular bursitis via injection of the navicular bursa should be highly effective in alleviating lameness. (*J Am Vet Med Assoc* 2009;234:920–925)

Recent technologic advancements have increased access to MRI for characterization, diagnosis, and treatment of many of the lameness conditions that originate in the feet of horses. Traditional diagnostic methods, including diagnostic anesthesia, radiography, nuclear scintigraphy, and diagnostic ultrasonography, may provide inconclusive results because of a lack of specificity and sensitivity for the characterization of the soft tissues and bony structures in the foot.<sup>1–4</sup> Some commonly used methods of treatment for horses with lameness localized to the foot include systemic nonsteroidal anti-inflammatory drugs, corrective shoeing, intra-articular injection of the DIP with corticosteroids or hyaluronate, palmar digital neurectomy, and corticosteroid or hyaluronate injections of the navicular bursa.<sup>5,6</sup> When response to treatment is inadequate, the reason

From Arizona Equine Medical and Surgical Center, 1685 S Gilbert Rd, Gilbert, AZ 85296 (Bell, Howard, Taylor, Voss); and Equine Orthopedic Research Laboratory, College of Veterinary Medicine and Biomedical Sciences, Colorado State University, Fort Collins, CO 80523 (Werpy). Dr. Bell's present address is Department of Large Animal Clinical Sciences, Western College of Veterinary Medicine, University of Saskatchewan, Saskatoon, SK S7N 5B4, Canada. The authors thank Jennifer Zawacky, Julie Martin, and David Barth for technical assistance. Address correspondence to Dr. Bell.

## ABBREVIATIONS

DDFT	Deep digital flexor tendon
DIP	Distal interphalangeal joint
MRI	Magnetic resonance imaging

for failure is often unknown because of a lack of information regarding the specific lesion or abnormality causing the lameness.

Magnetic resonance imaging provides the clinician with detailed information about soft tissue and bony injuries that may not be evident via radiography, nuclear scintigraphy, or ultrasonography. Diagnostic ultrasonography and nuclear scintigraphy have limitations in the diagnosis of the causes of foot pain.<sup>7–10</sup> Recent reports<sup>11,12</sup> indicate a correlation between MRI and nuclear scintigraphy for identification of clinically important distal sesamoid (navicular) bone and soft tissue lesions in horses with signs of foot pain. Presently, radiography remains essential in diagnosing causes of lameness localized to the foot. The use of MRI, when available, has become an adjunctive diagnostic tool when obvious bony changes, such as fractures and osteoarthritis, are not evident radiographically. Through the use of advanced diagnostic imaging, detailed information about the soft tissue and bony structures of the foot not ap-

preciable with traditional modalities is available to aid in precise diagnoses and targeted treatments.<sup>1-4,8,13,14</sup>

Intrathecal injection of the podotrochlear (navicular) bursa with corticosteroids, hyaluronate, and amikacin (or various combinations of these drugs) has substantial promise for treatment of horses with lameness of the foot. Among horses treated with such injections in a recent study,<sup>5</sup> 80% were sound and returned to their intended use by 2 weeks, and mean duration of soundness was 4.6 months.

The purpose of the study reported here was to determine clinical outcome following intrathecal injection of the navicular bursa for signs of foot pain in horses evaluated via MRI and evaluate efficacy of corticosteroids administered with or without hyaluronic acid. Our hypotheses were that horses with erosion of the flexor surface of the navicular bone would respond poorly to navicular bursa injection, compared with horses with other lesions, and that horses treated with triamcinolone in combination with hyaluronate would have better responses than those treated with corticosteroid alone.

## Materials and Methods

**Criteria for selection of cases**—Medical records of all horses examined at Arizona Equine Medical and Surgical Center between 2005 and 2007 because of lameness localized to the foot and that underwent MRI were reviewed. Horses included in the study had undergone intrathecal injection of the navicular bursa with triamcinolone and amikacin with or without hyaluronate, for lesions associated with signs of foot pain identified via MRI. Horses were excluded from the study if there was radiographic or MRI evidence of laminitis, osteoarthritis of the DIP joint, or fractures.

**Procedures**—Medical records were reviewed to determine signalment, clinical history, performance discipline, clinical examination findings, severity and duration of lameness, response to diagnostic perineural anesthesia, radiographic findings, treatment, and outcome following treatment. Lameness was assessed while the horse moved in a straight line and in a circle on a firm surface and scored on a scale from 0 to 5.<sup>15</sup> The anatomic source of lameness was localized to the foot by use of palmar digital anesthesia following perineural injection of 2% mepivacaine hydrochloride. Horses were subjectively evaluated for clinical improvement in lameness following perineural anesthesia. Radiographic evaluation of the feet consisted of a weight-bearing lateromedial view, a 60° dorsoproximal-palmarodistal oblique view, and a 65° palmaroproximal-palmarodistal oblique view of the navicular bone.

Magnetic resonance imaging of the forefeet was performed with the horses standing and sedated with romifidine (0.03 mg/kg [0.014 mg/lb], IV), butorphanol (0.01 mg/kg [0.005 mg/lb], IV), and acepromazine (0.02 mg/kg [0.009 mg/lb], IV). Images were obtained by use of a 0.27-T superconducting magnet.<sup>a</sup> The foot was placed within a receiver coil to maximize radiofrequency signal capture. Images were obtained in 3-dimensional gradient echo T1 sagittal, frontal, and transverse planes; 3-dimensional gradient echo T2 sagittal plane; fast spin

echo T2-weighted transverse planes; and short tau inversion recovery-weighted sagittal, transverse, and frontal planes in 8- to 24-slice sequences centered at the navicular bone. The images were interpreted by a board-certified radiologist (NMW), and abnormalities were identified and categorized by severity.

Injection of the navicular bursa was performed by use of a described technique.<sup>5</sup> Intrathecal injection was confirmed via radiographic imaging of the contrast dye in the navicular bursa. After injection, the heel was wrapped with gauze in a sterile manner and secured with elastic tape for 24 hours. No difficulties in technique were encountered during the injections. All horses received an adequate injection with minimal repositioning of the needle, even horses with adhesions of the DDFT.

All horses were given phenylbutazone (2.2 mg/kg [1 mg/lb], IV) following the injection and began a regimen of 3 days of phenylbutazone (4.4 mg/kg [2 mg/lb], PO) administration and stall rest for 4 days. Therapeutic shoeing for all horses consisted of a wide webbed shoe that fit full in the quarters and extended a quarter of an inch beyond the heel to support the bony column of the limb. The toes were rolled or squared, and the shoe was set back 1/16 to 1/8 of an inch from the toe to provide early breakover.

Follow-up information was obtained a minimum of 4 months after navicular bursa injection. This was achieved with a standardized telephone survey with the owner or trainer. The outcomes were categorized as excellent (horse returned to full athletic function without recurrent lameness for at least 3 months); moderate (horse was sound, but in light work only); or poor (lameness persisted, or horse was euthanized because of lameness).<sup>2</sup>

**Statistical analysis**—Descriptive statistical analysis was performed for all data. Inferential statistics were performed on outcomes following navicular bursa injection for treatment of lesions characterized via MRI and radiography by use of the Fisher exact test of independence. A 2-sample *t* test was used to compare concentration of triamcinolone administered with outcomes, and a Kruskal-Wallis test was used to compare concentration of hyaluronate administered with outcomes. A logistic regression analysis was performed for correlation of outcomes in horses with MRI and radiographic findings. Differences were considered significant at  $P \leq 0.05$ . Data were analyzed by use of computerized statistical software.

## Results

**Signalment and history**—Twenty-three horses met the inclusion criteria; 17 were geldings and 6 were mares. Mean age was 9.7 years (median, 9 years; range, 3.5 to 15 years). There were 16 Quarter Horses, 6 Warmbloods (2 Westphalians, 2 Hannovarians, 1 Oldenburg, and 1 unknown), and 1 Thoroughbred. Mean duration of lameness was 10.5 months (median, 8 months; range, 2 to 66 months). The horses participated in a variety of disciplines; 8 were used for English performance (hunter-jumper), 5 were used for barrel

racing, 4 were used as reining horses, 2 were used as roping horses, 2 were used as pleasure horses, 1 was used for performance cattle penning, and 1 was used for military cavalry charge.

**Clinical findings and diagnostic tests**—Thirteen horses had bilateral forelimb lameness, and 10 had unilateral forelimb lameness. Mean lameness grade at the initial examination was 2.4, with a range of grade 2 to 4. Neither the degree nor duration of lameness was a significant indicator of outcome. Thirteen horses had lameness in the contralateral forelimb following alleviation of the lameness by use of diagnostic anesthesia. The lameness in the opposite limb was less severe, and significant improvement resulted with palmar digital anesthesia. Hind limb lameness was not observed in any of the 23 horses. No response to hoof testers was recorded in 12 of 23 horses. Nine horses reacted to hoof testers applied to the frog and heel region, and 2 horses reacted to hoof testers applied to the sole. None of the horses had any known history of diagnostic DIP joint blocks or therapeutic DIP injections of corticosteroids prior to initial examination. Fifteen of 23 horses had a history of corrective shoeing specific for signs of foot pain; shoeing regimens were variable but predominantly included a full-fitting shoe or egg-bar shoe with a 1° or 2° wedge and rolling of the toe to ease breakover.

**Diagnostic imaging**—Radiography of the feet ( $n = 36$ ; bilateral for 13 horses and unilateral for 10 horses) was performed on all of the horses. Radiographic evaluation revealed no important bony abnormalities in 23 of 36 (64%) feet. Ten feet had enlarged synovial invaginations in the navicular bone, 9 feet had mild to moderate medullary cavity sclerosis and loss of definition of the navicular bone corticomedullary junction, 7 feet had lucency of the sagittal ridge of the flexor surface of the navicular bone, 3 feet had a cystic structure  $> 5$  mm in diameter in the dorsopalmar view, and 3 feet had enthesiopathy of the attachment of the suspensory ligament of the navicular bone. A partial avulsion fragment associated with the impar ligament was observed radiographically in 1 foot. Magnetic resonance imaging was performed on 35 of the 36 feet examined radiographically. Enlarged synovial invaginations were evident in the navicular bone of 18 (51%) feet. Navicular bone flexor surface erosion was observed in 8 feet, and focal cortical bone loss or thinning of the distal margins of the navicular bone was observed in 7 feet. Fluid within the navicular bone was diagnosed on short tau inversion recovery images in 16 feet. Adhesions were observed between the navicular bone and DDFT in 22 (63%) feet, between the navicular bone and navicular bursa in 17 (49%) feet, between the DDFT and the impar ligament in 8 feet, and between the DDFT and suspensory ligament of the navicular bone in 12 feet. Synovial proliferation and excessive fluid in the navicular bursa were observed in 13 feet. Some degree of fiber disruption or degeneration was observed in the DDFT in 21 (60%) feet. Desmopathy of a collateral ligament of the DIP was observed in 19 (54%) feet.

**Treatment**—In all horses, the navicular bursa of the affected limb received an injection of triamcinolone and amikacin as well as a small volume of contrast medium for radiographic confirmation of intrathecal delivery. Hyal-

uronate was administered intrathecally to 18 of 35 horses in combination with triamcinolone. Mean  $\pm$  SD dose of triamcinolone was  $12.9 \pm 5.0$  mg (median, 15 mg; range, 4 to 25 mg). Mean  $\pm$  SD dose of hyaluronate was  $11.0 \pm 3.2$  mg (median, 10 mg; range, 10 to 20 mg). Mean  $\pm$  SD amount of amikacin was  $93.5 \pm 31.0$  mg (median, 64 mg; range, 64 to 125 mg). Mean  $\pm$  SD amount of contrast medium used for each injection was  $0.4 \pm 0.2$  mL (median, 0.5 mL; range, 0.25 to 1 mL). The amount of each component was determined by clinician preference. Hyaluronate treatment had no significant effect on outcome ( $P = 0.46$ ). Triamcinolone treatment did have a significant effect on outcome, with horses receiving  $< 10$  mg having moderate or poor outcomes ( $P = 0.05$ ). There were no complications or adverse reactions in any of the horses following bursa injection. Multiple treatments were administered in 5 horses, 4 of which had 2 injections over the course of 1 year and 1 of which had 3 injections over the course of 2 years. Corrective shoeing recommendations were made for all horses following injection.

**Outcomes**—Seventeen of 23 (74%) horses had an excellent short-term outcome. Lameness resolved within 2 to 4 weeks following navicular bursa injection, and the horses returned to their intended use. Of the 17 horses with an excellent outcome, mean duration of soundness was 7.3 months (median, 6 months; range, 4 to 16 months). No horses were lost to follow-up. The outcome in 4 horses was poor, and the outcome in 2 horses was moderate. Among horses with erosion of the flexor surface of the navicular bone, significantly ( $P = 0.001$ ) more feet ( $n = 7$ ) were in horses with poor or moderate outcomes than feet (1) in horses with excellent outcome. Among horses with adhesions between the DDFT and the navicular bone, the lesion occurred significantly ( $P \leq 0.05$ ) more frequently in 5 of 6 horses' feet ( $n = 9$ ) with poor or moderate outcomes than in 8 of 25 horses' feet (13) with excellent outcome (Table 1).

Table 1—Outcomes of podotrochlear (navicular) bursa injection in the feet of horses with a specific MRI diagnosis.

MRI diagnosis	No. of feet		P value
	Returned to intended use (n = 25)	Did not return to intended use (n = 10)	
Enlarged synovial invaginations	14	4	0.47
Flexor surface erosions	1	7	0.001
Focal cortical bone loss at distal margin of navicular bone	7	0	0.09
Edema in navicular bone	11	5	0.75
Adhesions between DDFT and navicular bone	13	9	0.05
Adhesion between impar ligament of navicular bone and DDFT	6	2	1.00
Adhesion between suspensory ligament of navicular bone and DDFT	7	5	0.25
Adhesion between navicular bursa and navicular bone	10	7	0.14
Bursitis or excess fluid in navicular bursa	12	1	0.05
Desmopathy of the DIP collateral ligament	15	4	0.45
DDFT tear	14	7	0.70

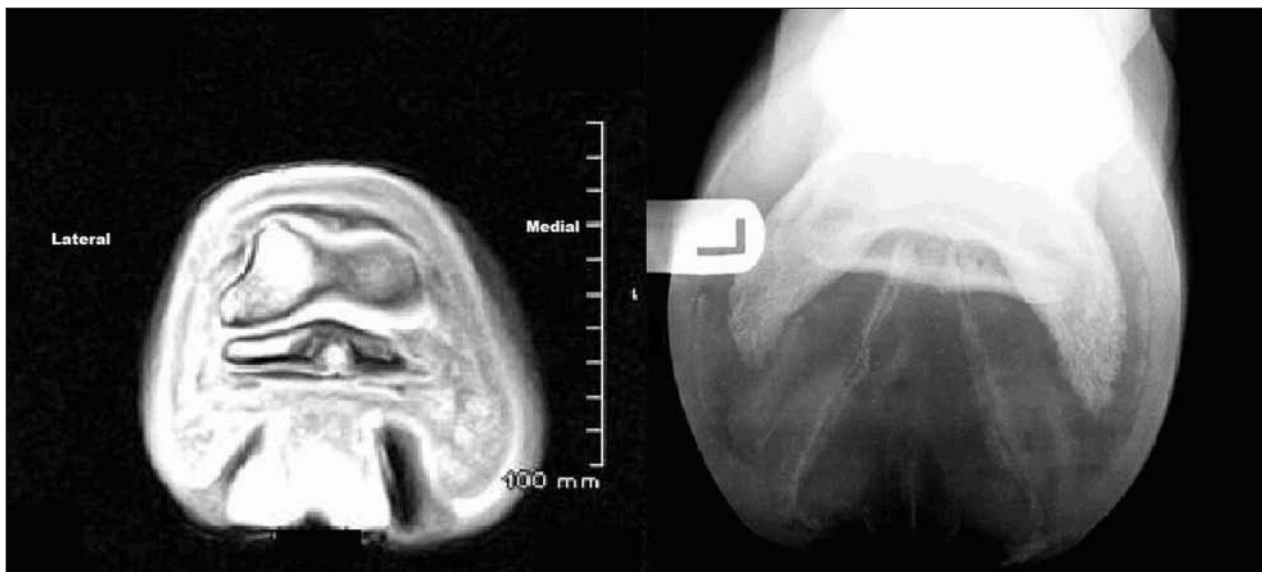


Figure 1—Magnetic resonance imaging view (left image) of a transverse section of the foot of a horse. Notice the area of increased signal at the point of flexor surface erosion of the distal sesamoid (navicular) bone and a low signal adhesion of the DDFT. In the radiographic view (right image) of the same horse's foot, notice lucency of the sagittal ridge of the navicular bone corresponding to the lesion detected via MRI.

Logistic regression analysis revealed that within the moderate- and poor-outcome groups, horses' feet ( $n = 7$ ) with erosion of the flexor surface of the navicular bone evident via MRI correlated with horses' feet (5) that had evidence of sagittal ridge lucency of the flexor surface of the navicular bone on the  $65^\circ$  palmaroproximal-palmarodistal oblique projection ( $P = 0.02$ ; Figure 1). Of the 23 feet with MRI abnormalities and no radiographic lesions, 19 were in horses with excellent outcomes, compared with 4 feet in horses with moderate or poor outcomes ( $P = 0.04$ ). Other radiographic findings were not found to be significant when comparing feet of horses with moderate or poor outcomes with feet of horses with excellent outcomes (Table 1). Two of the 6 horses with poor outcomes following navicular bursa injection were euthanatized; 1 was euthanatized because of a cervical vertebral fracture, and 1 was euthanatized because of the navicular apparatus-related lesions detected via MRI. Both were among the 5 horses that received multiple navicular bursa injections. Of those horses that received  $> 1$  navicular bursa injection, only 2 horses had excellent outcomes. Interval between injections was a mean of 4 months for the 5 horses. No horses achieved excellent outcome following the second injection.

In the group of horses with an excellent outcome following navicular bursa injection, 7 of 35 feet improved if there was an area of focal cortical bone loss of the distal margin of the navicular bone; however, the results were not significant ( $P = 0.09$ ), compared with the other outcome groups. Horses with navicular bursitis diagnosed via MRI had significant improvement (12/13 feet), compared with the poor- and moderate-outcome groups.

## Discussion

Lameness localized to the foot or navicular region should no longer be considered a single disease under

the catch-all phrase navicular syndrome. With advancements in diagnostic imaging, the accuracy of diagnosis has increased dramatically during the past 10 years. Previous studies<sup>1-4,13,16,17</sup> of MRI findings of horses with navicular syndrome-associated lameness revealed multiple soft tissue and bony abnormalities. Results of the present study indicated that 60% of the feet examined had deep digital flexor tendonitis characterized by fiber disruption or degeneration, as interpreted with MRI. This was similar to the results of 2 larger imaging studies that found 59%<sup>2</sup> and 61%<sup>4</sup> of the study population had tendonitis of the distal portion of the DDFT. Many horses in those studies also had a combination of additional soft tissue lesions. Results of our study indicated that 54% of the feet examined had evidence of DIP collateral ligament desmopathy and associated injuries. These findings were similar to those of a larger study<sup>2</sup> that indicated that 47% of horses examined had DIP collateral ligament desmitis (31%) or DIP collateral ligament desmitis in conjunction with other injuries (16%). Our study also identified a number of bony changes associated with the navicular bone that were not detected radiographically. The ability of MRI to thoroughly characterize pathologic changes of the navicular bone that cannot be identified radiographically has been well established.<sup>1-4,8,12-14</sup> Flexor surface erosion of the navicular bone was observed in 8 of 35 feet examined with MRI in our study, and 7 of the 35 feet had flexor surface cortical bone loss or thinning of the distal margin of the navicular bone on MRI, consistent with previous reports.<sup>2,13,14,17,18</sup> Results indicated that 16 of 35 (46%) feet examined had fluid consistent with edema or contusion in combination with other findings. This was also in agreement with previous study findings.<sup>2,12,13,16-18</sup> The importance of the contribution of these lesions to lameness in horses with signs of foot pain has not been fully elucidated in the literature. It is reasonable to suspect that as the number of horses

that undergo MRI for signs of foot pain increases, so will understanding of the lesions involved as they relate to lameness. Deep digital flexor tendonitis has been clearly characterized as an important cause of signs of foot pain,<sup>2-4,7,11-14,19-22</sup> as has DIP collateral ligament desmitis-desmopathy.<sup>1-4,11,13,14,17,18,23</sup>

In the present study, 17 of 23 (74%) horses with injuries localized to the foot treated with navicular bursa injections returned to their intended use within 2 to 4 weeks and remained sound for a mean of 7.3 months. These results were consistent with a previous report<sup>5</sup> indicating that 80% of horses treated with navicular bursa injection are sound and return to intended use within 2 weeks and remain sound for 4.6 months, as well as another study<sup>6</sup> indicating that 60% of horses treated with corticosteroid alone return to serviceable soundness for > 2 months. The reason for the difference in duration of soundness following injection is unknown, but may be attributable to level of training, intended use, location of injury, length of follow-up, and subjectivity of observer to report the degree of lameness on the follow-up survey. As with previous studies, most horses in the present study were middle-aged Quarter Horse geldings used for western performance competitions.<sup>5,24</sup> The mean amount of triamcinolone used in the present study was 12.9 mg with a mean of 93.5 mg of amikacin sulfate. In horses that received hyaluronate, the mean dose was 11.0 mg. This was comparable to the previous study<sup>5</sup> that cited use of 6 mg of triamcinolone, 10 mg of sodium hyaluronate, and 125 mg of amikacin sulfate. Our clinical results were similar to the previous study; however, our results suggested that doses of triamcinolone < 10 mg may not provide optimal outcome. The lower doses in moderate- and poor-outcome groups of horses may not have been sufficient to alleviate the inflammation in the navicular region and thus did not result in improvement to return to intended use. Results of the present study also indicated that hyaluronate was not significantly associated with outcome. This finding was based on results for 18 feet treated by use of injection during the study. Because this was a retrospective case series, clinicians were not masked with regard to identity of treatment groups, which limited the strength of the statistical analysis. The affected feet were nearly evenly allocated into 18 feet that received hyaluronate and 17 that did not receive hyaluronate. Horses that received hyaluronate were randomly chosen by a clinician on admission to the hospital, and hyaluronate treatment was not related to severity of lesions as judged by use of MRI. A prospective, controlled study would be required to more thoroughly identify the magnitude of dose-dependent effects for triamcinolone and hyaluronate. All horses were given corrective shoeing recommendations and a postinjection anti-inflammatory regimen of phenylbutazone. Shoeing changes alone can provide improvement in horses with signs of foot pain.<sup>25</sup> Therefore, the positive outcomes of our horses to navicular bursa injections cannot be attributable to injections alone and must be considered in the context of shoeing recommendations, navicular bursa injection, and anti-inflammatory drugs. A shoe with a 2° wedge pad may also improve lameness in horses with signs of foot pain.<sup>26</sup> In the present study, a wedge was not

recommended as a routine part of the treatment plan, which was based on clinician preference. Incorporating a 2° wedge into our shoeing recommendation may have improved success in horses with moderate or poor outcomes in returning to intended use.

Six horses (with 10 affected feet) did not return to intended use following navicular bursa injection in our study. Among these, use of MRI enabled a diagnosis of adhesions between the DDFT tendon and the navicular bone, and erosion of the flexor surface of the navicular bone was the only finding significantly associated with outcome. Results of a previous study<sup>5</sup> of navicular bursa injection suggested that horses with radiographic evidence of mild erosive lesions, observed as sagittal ridge lucency, along the flexor surface of the navicular bone suggestive of DDFT adhesions may be candidates for injection and that only horses with severe erosive flexor surface lesions are poor candidates. Results of our study suggested that horses with flexor surface erosions in association with DDFT adhesions of any severity should be expected to respond poorly to navicular bursa injection. We concluded that horses with erosion of the flexor surface of the navicular bone had a poor prognosis because of the degeneration and exposure of subchondral bone and subsequent or concurrent adhesions with the DDFT. Horses with other DDFT lesions proximal to the navicular bone such as sagittal fiber disruptions did not differ significantly in outcome, compared with horses with DDFT adhesions between the navicular bone and the DDFT.

Horses with bursitis responded significantly better to navicular bursa injections in our study, compared with horses with other MRI findings; 12 of 13 horses had an excellent outcome, although a reason for the difference was not apparent. Bursitis was diagnosed by the presence of effusion and synovial hyperplasia in the navicular bursa, and response was likely favorable because of the anti-inflammatory effect of the corticosteroid on the irritated synovium and resultant reduction of effusion. Seven of the 13 horses also received hyaluronate, but this was not significantly associated with outcome. The underlying cause of the synovial inflammation was likely not eliminated by treatment because many of the horses became lame again; however, the horses did return to intended use following injection.

In horses with DIP collateral ligament desmopathy, response to navicular bursa injection likely occurs because of the low degree of severity of the lesions. The low degree of severity often results from overinterpretation of the desmopathy because of magic angle effect with the standing magnet.<sup>27</sup> Good response may also be associated with diffusion of the corticosteroid from the navicular bursa to the DIP joint and associated structures,<sup>28</sup> and concurrent lesions in the navicular region that respond to the treatment.

Two horses were euthanatized in the group of 6 horses that did not return to intended use, 1 because of traumatic fracture of a cervical vertebra and 1 because of forelimb lameness that progressively increased despite bilateral navicular bursa injections. Postmortem examination revealed chondromalacia and eburnation of the flexor surface fibrocartilage and medullary malacia in both forelimb navicular bones. Radiography had

revealed no substantial bony changes in either foot, which reinforces the observation that radiographic findings do not always correlate with pathologic bony changes in horses with signs of foot pain.

a. Hallmarq Veterinary Imaging, Guildford, Surrey, England.

## References

1. Dyson S, Murray R, Schramme M, et al. Magnetic resonance imaging of the equine foot: 15 horses. *Equine Vet J* 2003;35:18–26.
2. Dyson SJ, Murray R, Schramme MC. Lameness associated with foot pain: results of magnetic resonance imaging in 199 horses (January 2001–December 2003) and response to treatment. *Equine Vet J* 2005;37:113–121.
3. Dyson S, Murray R. Magnetic resonance imaging evaluation of 264 horses with foot pain: the podotrochlear apparatus, deep digital flexor tendon, and collateral ligaments of the distal interphalangeal joint. *Equine Vet J* 2007;39:340–343.
4. Dyson S, Murray R, Schramme M, et al. Lameness in 46 horses associated with deep digital flexor tendonitis in the digit: diagnosis confirmed with magnetic resonance imaging. *Equine Vet J* 2003;35:681–690.
5. Dabareiner RM, Carter GK, Honnas CM. Injection of corticosteroids, hyaluronate, and amikacin into the navicular bursa in horses with signs of navicular area pain unresponsive to other treatments: 25 cases (1999–2002). *J Am Vet Med Assoc* 2003;223:1469–1474.
6. Verschooten F, Desmet P, Peremans K, et al. Navicular disease in the horse: the effect of controlled intrabursal corticoid injection. *J Equine Vet Sci* 1990;10:316–320.
7. Dyson SJ. Subjective and quantitative scintigraphic assessment of the equine foot and its relationship with foot pain. *Equine Vet J* 2002;34:164–170.
8. Barber MJ, Sampson SN, Schneider RK, et al. Use of magnetic resonance imaging to diagnose distal sesamoid bone injury in a horse. *J Am Vet Med Assoc* 2006;229:717–720.
9. Martinelli M, Rantanen N. Relationship between nuclear scintigraphy and standing MRI in 30 horses with lameness of the foot, in *Proceedings*. 51st Annu Conv Am Assoc Equine Pract 2005;359–365.
10. Bolen G, Busoni V, Jacqmot O, et al. Sonographic anatomy of the palmarodistal aspect of the equine digit. *Vet Radiol Ultrasound* 2007;48:270–275.
11. Dyson S, Murray R. Verification of scintigraphic imaging for diagnosis in 264 horses with foot pain. *Equine Vet J* 2007;39:350–355.
12. Dyson S, Murray R. Use of concurrent scintigraphic and magnetic resonance imaging evaluation to improve understanding of the pathogenesis of injury of the podotrochlear apparatus. *Equine Vet J* 2007;39:365–369.
13. Widmer WR, Buckwalter KA, Fessler JF, et al. Use of radiography, computed tomography and magnetic resonance imaging for evaluation of navicular syndrome in the horse. *Vet Radiol Ultrasound* 2000;41:108–116.
14. Dyson SJ. Navicular disease and other soft tissue causes of palmar foot pain. In: Ross MW, Dyson SJ, eds. *Diagnosis and management of lameness in the horse*. Philadelphia: WB Saunders Co, 2003;286–299.
15. American Association of Equine Practitioners. Definition and classification of lameness. In: *Guide for veterinary service and judging of equestrian events*. Lexington, Ky: American Association of Equine Practitioners, 1991.
16. Schramme M, Murray R, Blunden A, et al. A comparison between magnetic resonance imaging, pathology, and radiology in 34 limbs with navicular syndrome and 25 control limbs, in *Proceedings*. 51st Annu Conv Am Assoc Equine Pract 2005;348–358.
17. Sherlock CE, Kinns J, Mair TS. Evaluation of foot pain in the standing horse by magnetic resonance imaging. *Vet Rec* 2007;161:739–744.
18. Smith MR, Wright IM, Smith RK. Endoscopic assessment and treatment of lesions of the deep digital flexor tendon in the navicular bursae of 20 lame horses. *Equine Vet J* 2007;39:18–24.
19. Blunden A, Dyson S, Murray R, et al. Histopathology in horses with chronic palmar foot pain and age-matched controls. Part 1: navicular bone and related structures. *Equine Vet J* 2006;38:15–22.
20. Blunden A, Dyson S, Murray R, et al. Histopathology in horses with chronic palmar foot pain and age-matched controls. Part 2: the deep digital flexor tendon. *Equine Vet J* 2006;38:23–27.
21. Smith M, Wright I, Smith R. Bursoscopy and tenoscopy of deep digital flexor tendonitis, in *Proceedings*. Annu Symp Am Coll Vet Surg 2007;99–103.
22. Mahar O, Synder J, Symm W, et al. Deep digital flexor tendon injuries in the equine foot, in *Proceedings*. Annu Symp Am Coll Vet Surg 2007;92–93.
23. Martinelli M, Schramme M. Collateral desmitis of the distal interphalangeal joint, in *Proceedings*. Annu Symp Am Coll Vet Surg 2007;94–98.
24. Jackman BR, Baxter GM, Doran RE, et al. Palmar digital neurectomy in horses: 57 cases (1984–1990). *Vet Surg* 1993;22:285–288.
25. Debareiner RM, Carter GK. Diagnosis, treatment, and farriery for horses with chronic heel pain. *Vet Clin North Am Equine Pract* 2003;19:417–441.
26. Willemsen MA, Savelberg HH, Barneveld A. The effects of orthopaedic shoeing on the force exerted by the deep digital flexor tendon on the navicular bone in horses. *Equine Vet J* 1999;31:25–30.
27. Spriet M, Mai W, McKnight A. Asymmetric signal intensity in normal collateral ligaments of the distal interphalangeal joint in horses with a low-field MRI system due to magic angle effect. *Vet Radiol Ultrasound* 2007;48:95–100.
28. Pauwels FE, Schumacher J, Castro FA, et al. Evaluation of the diffusion of corticosteroids between the distal interphalangeal joint and navicular bursa in horses. *Am J Vet Res* 2008;69:611–616.