

Comparison of three dorsal techniques for arthrocentesis of the distal interphalangeal joint in horses

Marco Gandini, DMV

Objective—To compare 3 dorsal techniques for arthrocentesis of the distal interphalangeal joint in horses with regard to ease of performing the technique and to determine the role of operator experience in ease of performing these techniques.

Design—Observational study.

Sample Population—Forelimbs from 17 equine cadavers and 12 horses (16 joints) undergoing arthrocentesis for therapeutic or diagnostic purposes.

Procedures—In both forelimbs from 7 of the equine cadavers, 3 arthrocentesis techniques (dorsal perpendicular, dorsolateral, and dorsal inclined) were performed in random order by a single experienced individual, and number of attempts needed to successfully insert the needle into the joint was recorded. For the forelimbs from the remaining 10 cadavers, veterinary students without experience in arthrocentesis performed each of the 3 arthrocentesis techniques (2 limbs/student) in random order, and number of attempts was recorded. In the clinical patients, arthrocentesis was performed by means of the dorsal inclined technique.

Results—For both the experienced individual and the veterinary students, number of attempts needed was significantly lower with the dorsal inclined technique than with the dorsal perpendicular or dorsolateral technique. Arthrocentesis was successful with the dorsal inclined technique in all 16 joints in the clinical patients; synovial fluid was recovered from 14 of the 16 joints. The procedure was well tolerated in all horses, except one that reacted to needle insertion.

Conclusions and Clinical Relevance—Results suggested that the dorsal inclined technique for arthrocentesis of the distal interphalangeal joint was easier to perform than was the dorsal perpendicular or dorsolateral technique, regardless of experience level of the operator. (*J Am Vet Med Assoc* 2007;231:254–258)

In horses, arthrocentesis of the distal interphalangeal joint is commonly performed for diagnostic and therapeutic purposes. Although various techniques for arthrocentesis of this joint have been described,^{1–11} the importance of choosing a technique that not only is easy to perform and well tolerated but also reliably results in advancement of the needle into the distal interphalangeal joint should not be underestimated. Controversy exists concerning the structures that are desensitized following diagnostic anesthesia of the distal interphalangeal joint,^{12–16} and further confusion can arise if the technique results in injection of other structures.⁶

The most commonly described techniques for arthrocentesis of the distal interphalangeal joint in horses are the dorsal perpendicular and dorsolateral approaches. With the dorsal perpendicular approach, the needle is inserted in the median plane perpendicular to the bearing surface of the foot, whereas with the dorsolateral approach, the needle is inserted just lateral to the extensor tendon and aimed toward the extensor process of the third phalanx.^{1–6} A lateral approach and palmar or plantar approaches have also been described.^{6,8,9} With the lateral approach, the needle is inserted in a depression bounded by the palmar border

of the proximal phalanx and the proximal border of the ungular cartilage and advanced in a palmaroproximolateral to dorsodistomedial direction. However, this technique appears to be less reliable than the dorsolateral approach, frequently resulting in inadvertent injection into the navicular bursa or tendon sheath.^{6,7} With the palmar or plantar approach, the needle is inserted slightly proximal to the deepest part of the fossa above the bulbs of the heels and directed cranial and distad.^{8,9} This technique is considered particularly useful in horses with periosteal proliferation involving the dorsal margin of the joint.⁸ Modified dorsal approaches with the needle inserted parallel to the bearing surface of the foot (dorsal parallel)^{7,10,11,17} or slightly distal from parallel to the bearing surface of the foot (dorsal inclined)¹⁸ have also been described and claimed to be easier to perform,⁷ although the veracity of this claim has not been fully evaluated.

The ease with which a procedure such as arthrocentesis can be performed is determined to a large extent by anatomic factors, such as location of surrounding structures and size of the joint space. Other factors, however, also have a role, including pathologic factors such as exostoses, intrinsic difficulties such as operator position relative to the patient, and, last but not least, experience of the operator. This latter factor is probably underestimated when suggesting the use of arthrocentesis or teaching arthrocentesis techniques.

From the Facoltà di Medicina Veterinaria di Torino, Dipartimento di Patologia Animale, Università di Torino, 10095 Grugliasco, Torino, Italy.

The purposes of the study reported here were to compare 3 techniques for arthrocentesis of the distal interphalangeal joint in horses with regard to ease of performing the technique (ie, number of attempts needed to successfully insert the needle into the joint) and to determine the role of operator experience in the ease of performing these techniques.

Materials and Methods

Comparison of arthrocentesis techniques—In vitro and in vivo methods were used to evaluate the ease with which 3 techniques for arthrocentesis of the distal interphalangeal joint in horses could be performed. For the in vitro evaluations, both forelimbs were collected from 7 horses within 1 hour after death. All 7 horses were determined to be free from forelimb orthopedic disease on the basis of clinical examination. Hair was clipped from the limbs, and 3 techniques for distal interphalangeal joint arthrocentesis were performed on each limb by the author.

The 3 techniques examined included the dorsal perpendicular, dorsolateral, and dorsal inclined techniques. The dorsal perpendicular and dorsal lateral techniques were performed as described.^{1-3,6} Briefly, a 20-gauge, 1.5-inch needle was inserted 1 to 2 cm proximal to the coronary border on the sagittal plane (dorsal perpendicular technique) or 1.5 to 2 cm lateral to the sagittal plane (dorsolateral technique) and directed perpendicular to the bearing surface of the hoof, aiming behind the extensor process of the third phalanx (Figures 1 and 2). The dor-

sal inclined technique was also performed as described.¹⁸ Briefly, a 20-gauge, 1-inch needle was inserted 1 cm proximal to the coronary border on the sagittal plane and directed perpendicular to the skin surface (Figure 3).

For all 3 techniques, the limb was held by the assistant as if the horse were standing squarely. The 3 techniques were performed on each limb in random order, with order determined by a simple draw before the first technique was performed.

As each technique was performed, the number of attempts needed to reach the joint space with the needle was recorded. Any redirection of the needle was considered an attempt, even if the needle was not completely removed from the limb. The needle was considered to have been inserted into the joint space if injection of 5 mL of saline (0.9% NaCl) solution resulted in visible distention of the joint and fluid could be retrieved following injection. After each successful attempt to enter the joint space, a 10-mL syringe was used to aspirate as much fluid as possible from the joint space before the needle was withdrawn.

In 3 limbs, the success of arthrocentesis was also determined by means of arthrography. In these instances, 5 mL of iopamidol^a diluted in 5 mL of saline solution was injected into the joint, and radiographs were obtained with a digital system.^b

For the in vivo evaluation, arthrocentesis of 16 distal interphalangeal joints in 12 lame horses was performed by the author for diagnostic or therapeutic purposes. The horses consisted of 8 Standardbreds, 3 warmbloods,




Figure 1—Frontal (a) and lateral (b) views of needle placement for the dorsal perpendicular technique for arthrocentesis of the distal interphalangeal joint in horses.




Figure 2—Frontal (a) and lateral (b) views of needle placement for the dorsolateral technique for arthrocentesis of the distal interphalangeal joint in horses.

and 1 Thoroughbred between 2 and 15 years old; mean approximate weight was 450 kg (990 lb).

For all 16 joints, the dorsal inclined technique was used. After routine clipping and sterile preparation of the injection site, horses were restrained with a nose twitch, and the contralateral limb was held off the ground by an assistant. No sedation or local anesthesia was used. Five milliliters of local anesthetic or 3 mL of hyaluronic acid was injected into the joint after needle insertion. Distension of the joint before and after the injection, number of attempts needed to insert the needle in the joint space, and retrieval of synovial fluid after needle insertion were recorded, as well as patient tolerance of the procedure.

Role of operator experience—Ten veterinary students from the third, fourth, and fifth years of study were used to determine the role of operator experience in ease of performing distal interphalangeal joint arthrocentesis. None of the students had previously performed arthrocentesis on live horses or cadaver limbs.

For the present study, students were briefed concerning the 3 arthrocentesis techniques and provided diagrams of each technique. In addition, each technique was demonstrated once by the author on a cadaver limb. After the briefing, students proceeded directly to the laboratory to perform arthrocentesis on cadaver limbs.

Each student was provided 2 cadaver limbs (right and left forelimbs) and asked to perform the 3 arthrocentesis techniques on each limb. Forelimbs had been collected from 10 horses within 1 hour after death, and all 10 horses had been determined to be free from forelimb

orthopedic disease on the basis of clinical examination. Hair was clipped from the limbs prior to arthrocentesis. The 3 arthrocentesis techniques examined were the dorsal perpendicular, dorsolateral, and dorsal inclined techniques. The 3 techniques were performed on each limb in random order, with order determined by a simple draw before the first technique was performed.

As each technique was performed, the number of attempts needed to reach the joint space with the needle was recorded. Any redirection of the needle was considered an attempt, even if the needle was not completely removed from the limb. A maximum of 5 attempts was allowed for each technique. The needle was considered to have been inserted into the joint space if injection of 5 mL of saline solution resulted in visible distention of the joint and fluid could be retrieved following injection. After each successful attempt to enter the joint space, a 10-mL syringe was used to aspirate as much fluid as possible from the joint space before the needle was withdrawn.

Statistical analysis—Ease of performing each arthrocentesis technique was determined on the basis of success rate and number of attempts needed to insert the needle in the joint space. For each technique, mean number of attempts was calculated. The Shapiro-Wilk technique was used to determine whether data were normally distributed, and mean values were compared between techniques by use of the Wilcoxon rank sum test. Data are reported as mean \pm SD number of attempts. All analyses were performed with standard software.^c Values of $P \leq 0.05$ were considered significant.




Figure 3—Frontal (a) and lateral (b) views of needle placement for the dorsal inclined technique for arthrocentesis of the distal interphalangeal joint in horses.

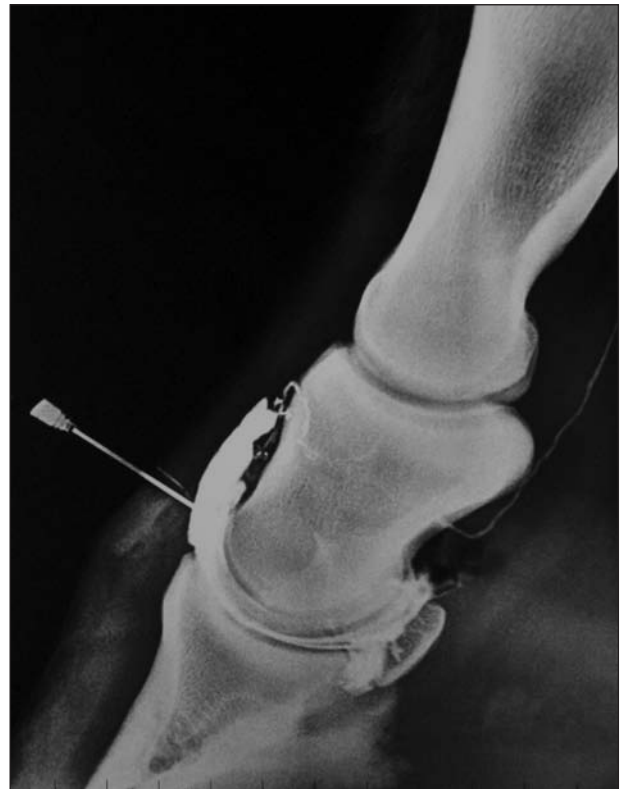


Figure 4—Lateral radiographic view of the distal portion of the limb of a horse obtained following injection of contrast material by means of the dorsal inclined technique for arthrocentesis of the distal interphalangeal joint in horses.

Results

Comparison of arthrocentesis techniques—For the 14 cadaver limbs from 7 horses, mean \pm SD number of attempts needed to insert the needle in the joint space when arthrocentesis was performed by the author was 2.85 ± 1.51 (median, 2.5; range, 1 to 5) for the dorsal perpendicular technique, 2.57 ± 1.15 (median, 2; range, 1 to 5) for the dorsolateral technique, and 1.14 ± 0.36 (median, 1; range, 1 to 2) for the dorsal inclined technique. Number of attempts needed was not significantly ($P = 0.704$) different between the dorsal perpendicular and dorsolateral techniques. However, number of attempts needed was significantly ($P < 0.001$) lower for the dorsal inclined technique than for the dorsal perpendicular or dorsolateral technique. Mean number of attempts was not significantly different between left and right forelimbs. Arthrography confirmed that arthrocentesis was successful in 3 instances (Figure 4).

Ten of the 16 joints examined in lame horses were grossly distended prior to arthrocentesis. Synovial fluid was recovered from all 10 distended joints and from 4 of the 6 joints without gross evidence of distension. Arthrocentesis was successful in all 16 joints, with distension of the joint evident after injection. Mean \pm SD number of attempts needed to insert the needle in the joint space was 1.12 ± 0.34 (median, 1; range, 1 to 2).

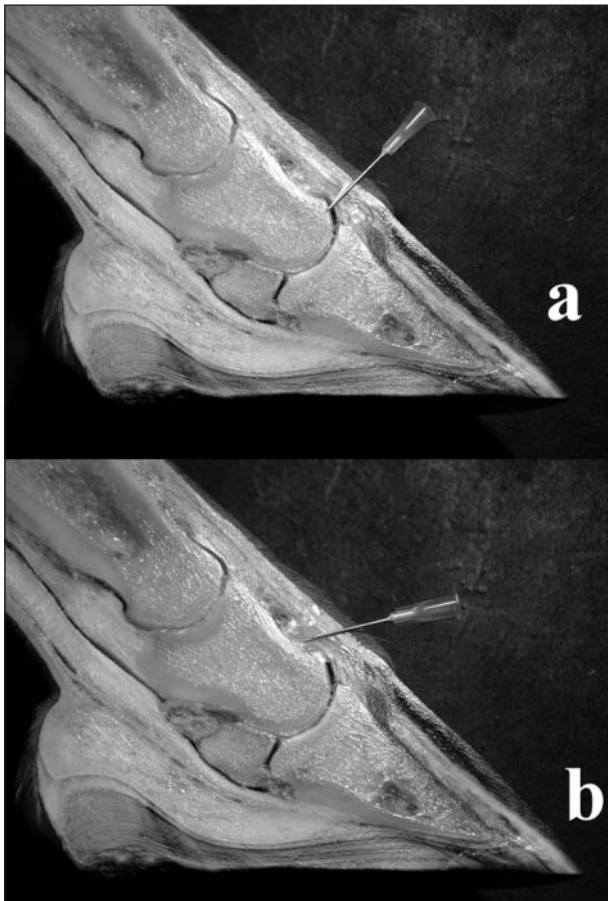


Figure 5—Photographs of a sagittal section of the distal limb of a horse illustrating needle placement with the dorsal inclined (a) and dorsal perpendicular (b) techniques for arthrocentesis of the distal interphalangeal joint in horses.

Mean number of attempts was not significantly different between left and right limbs. The procedure was well tolerated in all horses, except 1 that reacted to needle insertion. Slight blood contamination of synovial fluid was detected in 3 instances.

Role of operator experience—Mean \pm SD number of attempts needed to insert the needle in the joint space when arthrocentesis was performed by the veterinary students was 4.5 ± 0.68 (median, 5; range, 3 to 5) for the dorsal perpendicular technique, 2.55 ± 1.23 (median, 2; range, 1 to 5) for the dorsolateral technique; and 1.3 ± 0.47 (median, 1; range, 1 to 2) for the dorsal inclined technique. Number of attempts needed was significantly lower for the dorsolateral technique than for the dorsal perpendicular technique, for the dorsal inclined technique than for the dorsolateral technique, and for the dorsal inclined technique than for the dorsal perpendicular technique. Number of attempts needed was not significantly different between left and right forelimbs.

Discussion

The dorsal inclined technique for arthrocentesis of the distal interphalangeal joint used in the present study differs from other techniques in regard to angle of needle insertion. Some authors have suggested that inserting the needle parallel, rather than perpendicular, to the bearing surface of the foot allows consistent injection of the distal interphalangeal joint.^{7,10,11} For the dorsal inclined technique used in the present study, the needle was inserted perpendicular to the skin surface of the dorsal pastern region, rather than parallel to the bearing surface of the foot, as it was thought that this would compensate for different foot shapes and positions (Figure 5). Furthermore, inserting the needle parallel to the skin avoids insertion too close to the coronary band. Inserting the needle parallel to the bearing surface of the foot may lead to positioning of the needle tip in the soft tissues proximal to the joint, particularly when the hoof has an upright conformation or when the dorsal pouch of the joint does not extend very far dorsally. Inserting the needle parallel to the skin surface will allow consistent placement even with different hoof conformations and different hoof-pastern region angles. In some horses, the dorsal pouch of the joint loses contact with the underlying bone (Figure 4), and inadvertent placement of the needle tip in this area could lead to unsuccessful injection. If the needle tip is placed beneath the extensor tendon, injection can still be quite easy because the injected fluid will make a space for itself by lifting the tendon.

When performed by the author on cadaver limbs, the dorsal inclined technique required fewer attempts to insert the needle in the joint space than did the dorsal perpendicular or dorsolateral technique. For the inexperienced students, the dorsolateral and dorsal inclined techniques were relatively easy, with some students being successful at their first attempts with these techniques, whereas none of the students were successful at their first attempts with the dorsal perpendicular technique. Importantly, number of attempts needed by the students was significantly lower for the dorsal in-

clined technique than for the dorsolateral or dorsal perpendicular technique. Thus, the dorsal inclined technique could provide inexperienced operators with an easy method for performing arthrocentesis of the distal interphalangeal joint in horses.

When performed *in vivo* by the author, the dorsal inclined technique was well tolerated by patients. Care must be taken not to insert the needle too close to the coronary band, as this is a highly vascular and highly innervated area. In the present study, only a single horse reacted to insertion of the needle, and none of the horses required sedation or local anesthesia. Furthermore, synovial fluid was routinely collected, even from joints that were not grossly distended prior to arthrocentesis.

Inserting the needle through the extensor tendon, instead of medially or laterally as described for the dorsolateral technique, has not been reported to be a problem in clinical practice, although extensor tendon calcification has been described after the dorsal perpendicular technique.⁸ In the present study, we found that after injection of contrast material in the distal interphalangeal joint, some contrast material leaked back through the needle hole. This could be a potential issue when injecting corticosteroids into the joint, as leakage could potentially lead to calcified formations between tendon fibers. This could be avoided by flushing the needle with saline solution after injecting corticosteroids or by injecting hyaluronic acid after injecting corticosteroids.

-
- a. Iopamiro injectable solution (370 mg/mL), Bracco S.P.A., Milan, Italy.
 - b. Agfa Mimosa Vips 1206, Agfa-Gevaert N.V/S.A 96, Munich, Germany.
 - c. R software, version 2.1.0, R Foundation for Statistical Computing, Vienna, Austria.
-

References

1. Stashak T. Examination for lameness. In: Stashak T, ed. *Adams' lameness in the horse*. 5th ed. Philadelphia: Lippincott Williams & Wilkins, 2002;113–184.
2. Van Kruiningen HJ. Practical techniques for making injections into the joints and bursae of the horse. *J Am Vet Med Assoc* 1963; 43:1079–1083.
3. Moyer W, Carter GK. Techniques to facilitate intra-articular injections of equine joints, in *Proceedings. 42nd Annu Meet Am Assoc Equine Pract* 1996;42:48–54.
4. Wheat JD, Jones K. Selected techniques of regional analgesia. *Vet Clin North Am Equine Pract* 1981;3:223–246.
5. Schmotzer WB, Timm KI. Local anesthetic techniques for the diagnosis of lameness. *Vet Clin North Am Equine Pract* 1990;6: 705–728.
6. Vasquez de Mercado R, Stover SM, Taylor KT, et al. Lateral approach for arthrocentesis of the distal interphalangeal joint in horses. *J Am Vet Med Assoc* 1998;212:1413–1418.
7. Bassage LH, Ross MW. Diagnostic analgesia. In: Ross MW, Dyson SJ, eds. *Diagnosis and management of lameness in the horse*. St Louis: WB Saunders Co, 2003;93–124.
8. McIlwraith CW, Goodman NL. Conditions of the interphalangeal joints. *Vet Clin North Am Equine Pract* 1989;5:173–177.
9. Goodman NL, Baker BK. Lameness diagnosis and treatment. *Vet Clin North Am Equine Pract* 1990;6:86–88.
10. Schumacher J, Schumacher J, Schramme MC, et al. Diagnostic analgesia of the equine forefoot. *Equine Vet Educ* 2004;16:159–165.
11. Piccot-Crezollet C, Casamatta JM, Lepage OM. Anesthésies semiologiques digitales chez le cheval: technique et éléments d'interprétation. *Can Vet J* 2005;46:807–813.
12. Schumacher J, Schumacher J, de Graves F, et al. A comparison of the effects of two volumes of local analgesic solution in the distal interphalangeal joint of horses with lameness caused by solar toe or solar heel pain. *Equine Vet J* 2001;33:265–268.
13. Schumacher J, Steiger R, Schumacher J, et al. Effects of analgesia of the distal interphalangeal joint or palmar digital nerves on lameness caused by solar pain in horses. *Vet Surg* 2000;29:54–58.
14. Pleasant RS, Moll HD, Ley WB, et al. Intra-articular anesthesia of the distal interphalangeal joint alleviates lameness associated with the navicular bursa in the horse. *Vet Surg* 1997;26: 137–140.
15. Bowker RM, Rockershouser SJ, Vex KB, et al. Immunocytochemical and dye distribution studies of nerves potentially desensitized by injections into the distal interphalangeal joint or the navicular bursa of horses. *J Am Vet Med Assoc* 1993;203:1708–1714.
16. Dyson SJ, Kidd L. A comparison of responses to analgesia of the navicular bursa and intra-articular analgesia of the distal interphalangeal joint in 59 horses. *Equine Vet J* 1993;25:93–98.
17. Moyer W, Schumacher J. *A guide to equine joint injection*. Yardley, Pa: Veterinary Learning Systems, 2002;9.
18. Kaneps AJ. Diagnosis of lameness. In: Hinchcliffe KW, Kaneps AJ, Geor RJ, eds. *Equine sports medicine and surgery*. Philadelphia: WB Saunders Co, 2004;143–201.