



# What Is Your Diagnosis?

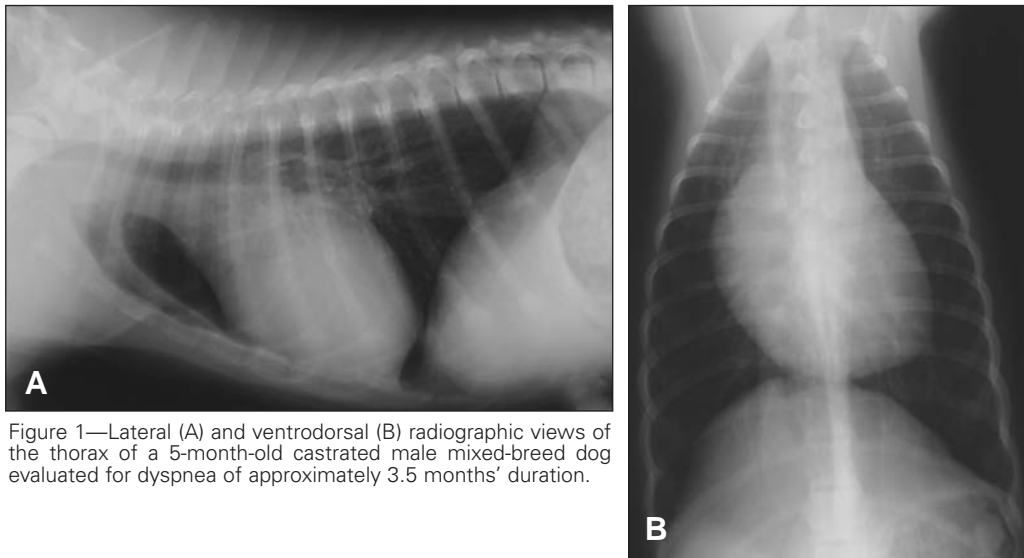


Figure 1—Lateral (A) and ventrodorsal (B) radiographic views of the thorax of a 5-month-old castrated male mixed-breed dog evaluated for dyspnea of approximately 3.5 months' duration.

## History

A 5-month-old 12.5-kg (27.5-lb) castrated male mixed-breed dog was evaluated because of dyspnea of 3.5 months' duration. Bronchitis had been diagnosed in the dog when it was 5.5 weeks old. A heart murmur was detected at that time. The dog was treated for bronchitis and the cough resolved; however, dyspnea, exercise intolerance, and the heart murmur persisted.

On physical examination, the dog was lethargic, was moderately dyspneic, and had frequent bouts of moist, productive coughing. The strength of peripheral pulses was fair to weak. The heart rate was within reference range (200 beats/min; reference range, 70 to 220 beats/min), and rhythm was regular. A grade 4/6 systolic murmur was detected during auscultation of the thorax, with the point of maximum intensity at the left heart base. Results of CBC indicated a mild increase in RBCs ( $9.40 \times 10^{12}$  cells/L; reference range,  $5.5$  to  $8.5 \times 10^{12}$  cells/L); however, Hct (0.52 L/L; reference range, 0.37 to 0.55 L/L) and total protein concentration (69 g/L; reference range, 51 to 72 g/L) were within reference ranges. Radiographs of the thorax were obtained (Figure 1).

**Determine whether additional imaging studies are required, or make your diagnosis from Figure 1—then turn the page ▶**

---

This report was submitted by Cynthia L. Collins, DVM; Patricia L. Rose, DVM, MS, DACVS, DACVR; and Etienne Côté, DVM, DACVIM; from the Department of Companion Animals, Atlantic Veterinary College, University of Prince Edward Island, Charlottetown, PE, C1A 4P3 Canada. Dr. Collins' present address is Veterinary Referral & Emergency Center, 123 W Cedar St, Norwalk, CT 06854. Dr. Collins was a 4th-year veterinary student at the time of manuscript submission. Address correspondence to Dr. Collins.

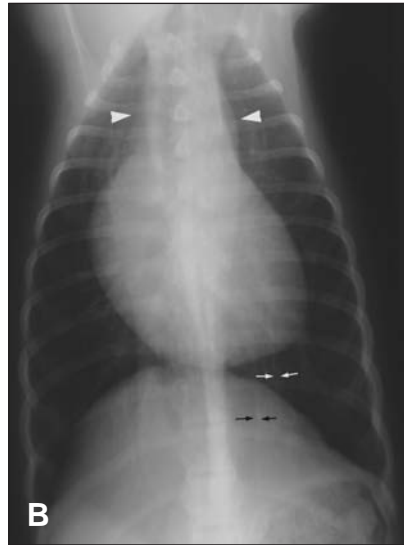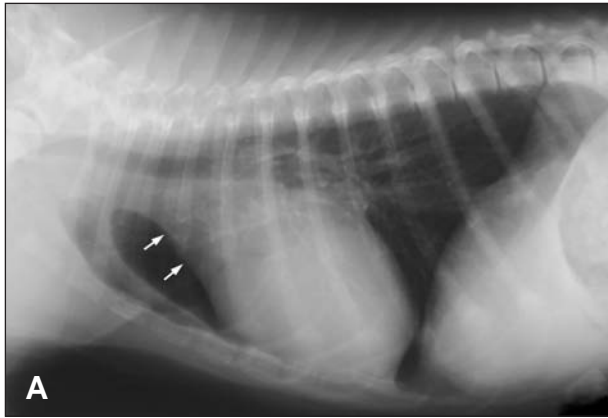


Figure 2—Same radiographic views as in Figure 1. On the lateral (A) radiographic view, notice loss of the cranial cardiac waist caused by an enlarged aortic arch (white arrows). Elevation of the trachea is caused by mild generalized cardiac enlargement and is accentuated by rotation. Increased width of the heart is evidence of right-sided heart enlargement. On the ventrodorsal view (B), increased width of the cranial mediastinum (arrowheads) is evident. Notice the small left caudal pulmonary artery (white arrows) and vein (black arrows).

### Radiographic Findings and Interpretation

On the lateral radiographic view, the cardiac silhouette is large and increased in width with a vertebral heart sum of 10.8 vertebrae (reference range,  $9.7 \pm 0.5$  vertebrae<sup>1</sup>; Figure 2). On the ventrodorsal view, the cardiac silhouette measures approximately 66% of the thoracic width (reference limit,  $< 65\%$ ), and there is shifting of the cardiac apex to the left, which is typically caused by enlargement of the right ventricle.<sup>2</sup> Additionally, there is loss of the cranial cardiac waist and widening of the mediastinum immediately cranial to the heart. The size and number of pulmonary vessels are reduced, indicating pulmonary undercirculation, and the thorax appears hyperexpanded. Differential diagnoses in a normovolemic patient for anomalies that decrease the size of pulmonary arteries and veins include right-to-left shunts and severe pulmonic stenosis.<sup>3</sup> This combination of radiographic abnormalities is typical of tetralogy of Fallot (ToF).

### Comments

The defining anatomic features of ToF are pulmonic stenosis, secondary right ventricular hypertrophy, a membranous ventricular septal defect, and dextroaorta. Radiography most commonly reveals evidence of right-sided heart enlargement without signs of involvement of the left side of the heart. Dextroaorta causes loss of the cranial waist of the cardiac silhouette on the lateral radiographic view.<sup>4</sup> Considerable right-to-left shunting may occur, resulting in hypoperfusion of the lungs.<sup>5</sup> The lung fields may have hyperlucency and caudal displacement of the diaphragm caused by hyperinflation.<sup>4</sup> The classic radiographic appearance of ToF is a boot-shaped heart on the ventrodorsal view; this shape is secondary to right ventricular hypertrophy and hypoplasia of the main pulmonary artery.<sup>6</sup> The consequence of these anatomic defects is hypoxemia. Resulting renal hypoxia stimulates erythropoietin release, which induces secondary polycythemia and eventual hyperviscosity.<sup>7</sup>

In the dog reported here, echocardiography confirmed the suspected abnormalities. A membranous ventricular septal defect and dextroaorta were detected. Evaluation of the right ventricle revealed marked concentric hypertrophy. The pulmonic valve was markedly narrower in diameter (9.7 mm) than the aortic valve (21.9 mm). Pulmonic stenosis

was confirmed with spectral Doppler echocardiography; right ventricular outflow tract velocity measured 4.8 m/s (reference range,  $0.84 \pm 0.17$  m/s), corresponding to a calculated right ventricular-to-pulmonary artery pressure gradient of 92 mm Hg.<sup>7</sup> Some degree of subaortic stenosis was suspected on the basis of a left ventricular outflow velocity of 4.1 m/s (reference range,  $1.06 \pm 0.21$  m/s) and corresponding calculated left ventricular-to-aortic pressure gradient of 67 mm Hg.<sup>7</sup> During the examination, the dog had marked central cyanosis that was disproportionate to the mild degree of dyspnea detected. The clinical condition of the dog abruptly deteriorated 1 week after diagnosis, and the dog was euthanized.

Congenital cardiac anomalies frequently result in enlargement of 1 or more cardiac chambers without signs of congestive heart failure. To avoid placing unwarranted emphasis on the perceived size or shape of the cardiac silhouette alone, radiographic findings should be considered as only 1 part of the clinical assessment and should be routinely reconciled with clinical signs and results of other forms of diagnostic imaging such as echocardiography.<sup>8</sup>

1. Buchanan JW, Bucheler J. Vertebral scale system to measure canine heart size in radiographs. *J Am Vet Med Assoc* 1995;206:194-199.

2. Hamlin RL. Analysis of the cardiac silhouette in dorsoventral radiographs from dogs with heart disease. *J Am Vet Med Assoc* 1968;153:1446-1460.

3. Losonsky JM. The pulmonary vasculature. In: Thrall DE. *Textbook of veterinary diagnostic radiology*. 4th ed. Philadelphia: WB Saunders Co, 2002;420-430.

4. Suter PF, Lord PF. *Thoracic radiography: a text atlas of thoracic diseases of the dog and cat*. Wettswil, Switzerland: Peter F Suter, 1984;111-112, 452-507.

5. Orton EC, Mama K, Hellyer P, et al. Open surgical repair of tetralogy of Fallot in dogs. *J Am Vet Med Assoc* 2001;219:1089-1093.

6. Goodwin JK, Lombard CW. The electrocardiographic and radiographic features of common congenital heart defects. *Vet Med* 1990;85:48-62.

7. Oyama MA, Sisson DD, Thomas WP, et al. Congenital heart disease. In: Ettinger SJ, Feldman EC, eds. *Textbook of veterinary internal medicine: diseases of the dog and cat*. 6th ed. St Louis: WB Saunders Co, 2005;975-1017.

8. Lamb CR, Boswood A, Volkman A, et al. Assessment of survey radiography as a method for diagnosis of congenital cardiac disease in dogs. *J Small Anim Pract* 2001;42:541-545.