

## What Is Your Diagnosis?

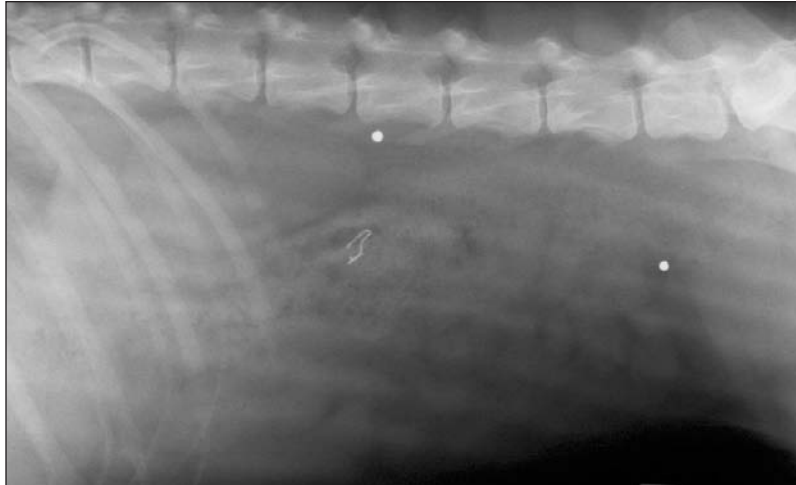


Figure 1—Left lateral radiographic view of the abdomen of a dog evaluated for fever of unknown origin and signs of lumbar pain.

### History

An approximately 1-year-old spayed female mixed-breed dog was referred for evaluation of fever of unknown origin. During the 2 months prior to examination, the owner reported that the dog's rectal temperature ranged from 39° to 40.5°C (102.2° to 105.0°F) and that the dog had been lethargic, reluctant to move, and had bilateral mucopurulent ocular discharge. The referring veterinarian had treated the dog with various antimicrobials (doxycycline, enrofloxacin, and clindamycin) without controlling the pyrexia; however, some of the clinical signs had improved after intermittent administration of carprofen, aspirin, or prednisone.

On initial physical examination, the dog had mild pyrexia (39.1°C [102.5°F]). Results of a CBC indicated that the WBC count was 26,000 cells/ $\mu$ L (reference range, 6 to 17,000 cells/ $\mu$ L) with a mature neutrophilia and eosinophilia. Results of serum biochemical analyses indicated that the activities of alkaline phosphatase and alanine aminotransferase were 116 U/L (reference range, 19 to 50 U/L) and 68 U/L (reference range, 17 to 66 U/L), respectively, and the concentrations of BUN and glucose were 10 mg/dL (reference range, 10 to 25 mg/dL) and 72 mg/dL (reference range, 80 to 100 mg/dL), respectively. The dog was hospitalized, and the following day, the physical examination findings included pyrexia (40.6°C [105.1°F]), bilateral mucopurulent ocular discharge, stiff gait, hyperesthesia along the epaxial musculature of the lumbar portion of the vertebral column, anorexia, and lethargy. A radiograph of the abdomen was obtained (Figure 1).

Determine whether additional imaging studies are required, or make your diagnosis from Figure 1—then turn the page ▶

---

This report was submitted by Rachel L. Keller, DVM, and Jill Lurye, DVM, MS; from the Department of Small Animal Clinical Sciences, College of Veterinary Medicine, University of Tennessee, Knoxville, TN 37996-4550 (Keller), and the Department of Clinical Sciences, College of Veterinary Medicine, Auburn University, Auburn, AL 36849 (Lurye).  
Address correspondence to Dr. Keller.

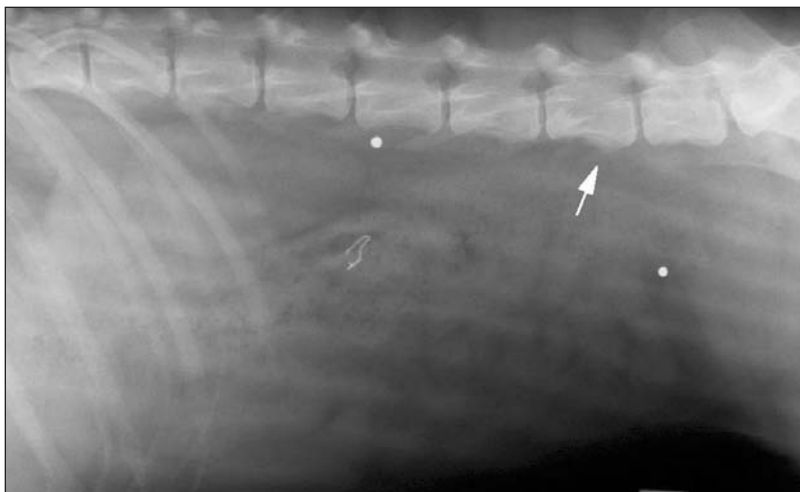


Figure 2—Same radiographic view as Figure 1. Notice irregular periosteal bone formation along the ventral aspect of several lumbar vertebral bodies. Several metallic foreign bodies can also be seen within the abdomen and are considered as an incidental finding.

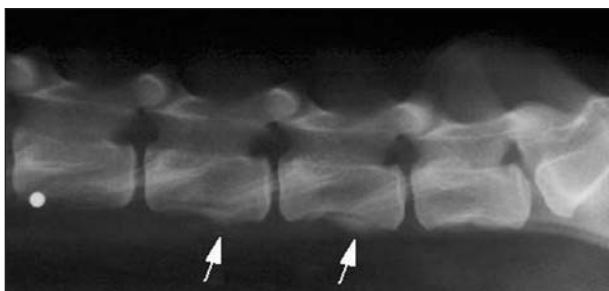


Figure 3—Left lateral radiographic view of the lumbar portion of the vertebral column of the dog in Figure 1. Notice there is irregular, periosteal, new bone formation on the ventral aspects of the vertebral bodies.

## Diagnosis

**Radiographic diagnosis**—There is a mild amount of irregular, periosteal, new bone formation along the ventral aspects of several lumbar vertebral bodies (Figure 2). Several round, metal opacities resembling gunshot pellets are superimposed on the abdomen and lumbar portion of the vertebral column.

## Comments

The history, physical examination, and radiographic findings were attributed to hepatozoonosis. The gunshot pellets were considered incidental findings. Radiography of the lumbar portion of the vertebral column revealed similar bone lesions (Figure 3). Results of radiography of the thorax were unremarkable. No growth was detected on bacteriologic cultures of urine and blood. Histologic examination of a biopsy specimen of the semitendinosus muscle revealed myositis with numerous lightly basophilic, vacuolated, laminated cysts containing an eosinophilic nucleus surrounded by mixed inflammatory cells consistent with intralesional hepatozoon cysts. The dog was treated with clindamycin (10 mg/kg [4.5 mg/lb], PO, q 8 h), trimethoprim-sulfadiazine (15 mg/kg [6.8 mg/lb], PO, q 12 h), and pyrimethamine (0.25 mg/kg [0.1 mg/lb], PO, q 24 h) for 2 weeks, after which treatment with decoquinatate (15 mg/kg, PO, q 12 h) was initiated for the life of the dog.

Hepatozoonosis in dogs in the United States is a tick-borne, protozoal disease caused by *Hepatozoon americanum*.<sup>1</sup> This disease was first reported in the United States in 1978 and is considered more virulent with an increased risk of causing fatal disease, compared with that seen with *Hepatozoon canis*.<sup>2</sup> *Hepatozoon americanum* is believed to be transmitted solely by the Gulf Coast Tick, *Amblyomma maculatum*.<sup>3</sup> Transmission occurs after ingestion of an infected tick.<sup>3</sup> Typically, affected dogs have pyrexia, with rectal temperatures as high as 41.1°C (106.0°F), weight loss, mucopurulent ocular discharge, hyperesthesia, guarding of the cervical region, evidence of lumbar pain, and gait abnormalities. Clinical signs may be episodic and may not respond to antimicrobial treatment alone.<sup>4</sup> Clinical signs develop in association with the pyogranulomatous inflammation

induced by release of merozoite cysts in muscle. Periosteal proliferation develops in response to underlying myositis and may be detected on long bones, vertebrae, or pelvis at the sites of muscle attachment.<sup>4,5</sup> A histologic diagnosis of hepatozoonosis is made by examining biopsy specimens of skeletal muscle. Recently, an indirect ELISA has been developed that is highly sensitive and specific, compared with histologic examination of muscle biopsy specimens, and may be used for noninvasive detection of the disease in affected dogs.<sup>6</sup>

Presently available treatments for American canine hepatozoonosis are not curative. However, substantial improvement and clinical remission may be achieved by use of combination treatment with clindamycin, trimethoprim-sulfadiazine, and pyrimethamine for 2 weeks followed by decoquinatate, which is a coccidiostat. This treatment regimen prolongs remission in affected dogs, although 20% of affected dogs will have spontaneous remission.<sup>5</sup> Additional treatment with nonsteroidal anti-inflammatory drugs may be palliative. Despite treatment, in most dogs, the disease relapses in 2 to 6 months and the mean reported survival time ranges from 10 to 12 months.<sup>5</sup> Complications include glomerulonephritis caused by chronic antigenic stimulation, nephritic syndrome, and hypercoagulability.<sup>4</sup>

1. Craig TM. Hepatozoonosis. In: Greene CE, ed. *Infectious diseases of the dog and cat*. 2nd ed. Philadelphia: WB Saunders Co, 1998;458–465.

2. Vincent-Johnson NA, Macintire DK, Lindsay DS, et al. A new *Hepatozoon* species from dogs: description of the causative agent of canine hepatozoonosis in North America. *J Parasitol* 1997;83:1165–1172.

3. Ewing SA, Mathew JS, Panciera RJ. Transmission of *Hepatozoon americanum* (Apicomplexa: Adeleorina) by ixodids (Acari: Ixodidae). *J Med Entomol* 2002;39:631–634.

4. Vincent-Johnson N, Macintire DK, Baneth G. Canine hepatozoonosis: pathophysiology, diagnosis, and treatment. *Compend Contin Educ Pract Vet* 1997;19:51–65.

5. Macintire DK, Vincent-Johnson N. Canine hepatozoonosis. In: Bonagura JD, ed. *Kirk's current veterinary therapy XIII*. Philadelphia: WB Saunders Co, 2000;310–312.

6. Mathew JS, Saliki JT, Ewing SA, et al. An indirect enzyme-linked immunosorbent assay for the diagnosis of American canine hepatozoonosis. *J Vet Diagn Invest* 2001;13:17–21.