

Nodular immunocyte-derived (AL) amyloidosis in the trachea of a dog

M. Faulkner Besancon, DVM; Brian A. Stacy, DVM; Andrew E. Kyles, BVMS, PhD, DACVS;
Peter F. Moore, BVSc, PhD, DACVP; William Vernau, BVMS, DVSc, PhD, DACVP;
Sean D. Smarick, VMD; Liberty A. Rasor, DVM

- ▶ Amyloidosis is a generic term for a heterogeneous group of disease processes characterized by deposition of insoluble fibrillar proteins in various organs and tissues of the body.
- ▶ Immunocyte-derived (AL) amyloidosis is uncommon in animals and most frequently associated with plasma cell neoplasia.
- ▶ In humans, immunocyte-derived (AL) amyloidosis is most often generalized in distribution, although localized forms do occur.
- ▶ Nodular immunocyte-derived (AL) tracheobronchial amyloidosis is most frequently a slowly progressive disease in humans in which the distribution of amyloid deposits and degree of airway compromise determine clinical signs.

A 7-year-old castrated male Miniature Schnauzer was examined on an emergency basis at the University of California, Davis, Veterinary Medical Teaching Hospital with an 11-day history of labored breathing. Concurrent medical problems included diabetes mellitus of 2 years' duration. The owner reported episodes of exaggerated breathing and whole body stiffness that would last for 2 to 3 minutes, after which the dog would immediately return to its normal state. The dog had been examined by its regular veterinarian shortly after these episodes had started; however, no abnormalities were found, and the owner declined diagnostic testing at that time. Episodes occurred intermittently over the next week. Ten days after the initial episode and 1 day prior to examination at the veterinary teaching hospital, however, the owner saw 2 episodes of respiratory distress that progressed to collapse. In each of these episodes, the dog developed labored breathing while standing, collapsed for 30 to 60 seconds, and then attempted to right itself. The owner reported no evidence of urination, defecation, or loss of consciousness during these episodes.

The dog was reexamined by the referring veterinarian at this time, who reported that the dog was eupneic and did not have any physical examination abnormalities. Results of a CBC and serum biochemical profile

were within reference ranges other than hyperglycemia (317 mg/dL; reference range, 60 to 125 mg/dL); high alkaline phosphatase (971 U/L; reference range, 10 to 150 U/L), alanine aminotransferase (430 U/L; reference range, 5 to 60 U/L), and aspartate aminotransferase (149 U/L; reference range, 5 to 55 U/L) activities; and hypercholesterolemia (485 mg/dL; reference range, 112 to 328 mg/dL). While the dog was being evaluated by the referring veterinarian, it had a third episode of dyspnea that progressed to collapse. At this time, the dog was referred to the veterinary teaching hospital for further monitoring and diagnostic evaluation.

At the time of initial examination at the veterinary teaching hospital, results of a physical examination were unremarkable. No cardiac murmurs or arrhythmias were auscultated, femoral pulses were adequate, and breath sounds in all lung fields were clear. The dog was admitted to the intensive care unit, and an ECG was monitored continuously overnight. The dog maintained a normal sinus rhythm throughout the night. Blood glucose concentration was measured every 2 hours overnight, and the dog did not develop hypoglycemia.

The following morning, several collapsing episodes were observed while the dog was being monitored in the intensive care unit. During each episode, the dog would become dyspneic, progressing to cyanotic, and would then collapse. Oxygen was administered each time, and the dog recovered within 4 to 5 minutes. Throughout all episodes, blood glucose concentrations and blood pressure were within reference limits, and there were no ECG abnormalities.

After the dog's condition stabilized, cervical and thoracic radiographs were taken as part of the initial diagnostic evaluation. A focal soft tissue mass in the caudal cervical portion of the trachea was observed (Fig 1). The mass had a wide base dorsally, suggestive of a tracheal wall mass or foreign body. No other clinically important radiographic abnormalities were seen.

A decision was made to perform tracheoscopy, with the option to perform tracheal surgery if necessary. The dog was premedicated with morphine (0.4 mg/kg [0.18 mg/lb], IM) and glycopyrrolate (0.005 mg/kg [0.002 mg/lb], IM). Diphenhydramine (0.5 mg/kg [0.23 mg/lb], IM) and cimetidine (5 mg/kg [2.3 mg/lb], IM) were administered to counteract histamine release in case the tracheal mass was a mast cell tumor. Anesthesia was induced with thiopental (5 mg/kg, IV) and midazolam (0.25 mg/kg [0.11 mg/lb], IV). An endotracheal tube was inserted, taking care that the distal end of the tube did not extend beyond the midcervical region in an attempt to avoid disrupting the mass. Anesthesia was maintained with isoflurane in oxygen.

From the Veterinary Medical Teaching Hospital (Besancon, Stacy, Smarick, Rasor) and the Departments of Surgical and Radiological Sciences (Kyles) and Pathology, Microbiology and Immunology (Moore, Vernau), School of Veterinary Medicine, University of California, Davis, CA 95616.

The authors thank Dr. Philip Martin for assistance with postmortem examination and Diane Naydan for performing immunohistochemistry.

Address correspondence to Dr. Besancon.

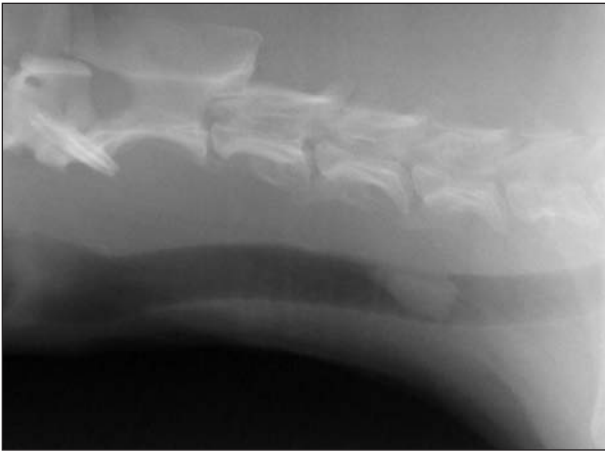


Figure 1—Lateral radiographic projection of the cervical region of a dog examined because of labored breathing. Notice the focal soft tissue mass in the caudal cervical portion of the trachea; the mass has a wide dorsal base suggestive of a tracheal wall mass or foreign body.

Tracheoscopy revealed a 1 × 1 cm, pedunculated, multinodular, pink, intraluminal mass extending from the dorsal tracheal membrane (Fig 2). The mass obstructed approximately 80% of the tracheal lumen. Biopsy specimens of the mass were obtained with grasping forceps and submitted for cytologic evaluation while the dog was prepared for surgery.

Several impression smears of the mass were examined. These smears consisted primarily of large numbers of plasmacytoid round cells with round, purple, often eccentrically placed nuclei and moderately basophilic cytoplasm. Cells had a mild degree of anisocytosis and anisokaryosis. Binucleate cells and a lack of prominent perinuclear clear zones were also common features. Moderate numbers of macrophages were seen, as were several large multinucleated giant cells, all of which contained both hemosiderin and hematoidin. On the basis of the cytologic findings, a preliminary diagnosis of plasmacytoma with moderate granulomatous inflammation was made.

At surgery, the trachea was exposed via a standard, ventral midline, cervical approach. A horizontal incision was made in the ventral aspect of the 10th tracheal ring space to allow examination of the tracheal mass. This examination indicated that tracheal resection and anastomosis would be required for complete excision of the mass with surgical margins of at least 1 cm of grossly normal tissue. A segment of trachea 4 rings in length was removed, and the remaining trachea was anastomosed with simple interrupted sutures of 3-0 polypropylene. Four tension-relieving sutures of 3-0 polypropylene were also placed.¹ The anastomosis was tested for air leakage by immersing the trachea in saline (0.9% NaCl) solution, and the incision was closed routinely. Within 12 hours after surgery, the dog was eating and drinking with no evidence of respiratory distress. The dog was discharged from the hospital the following afternoon.

Examination of the excised segment of trachea revealed an intraluminal, pedunculated, multinodular tracheal mass that extended from the dorsal tracheal membrane. The mass measured 1 × 1 × 0.4 cm and

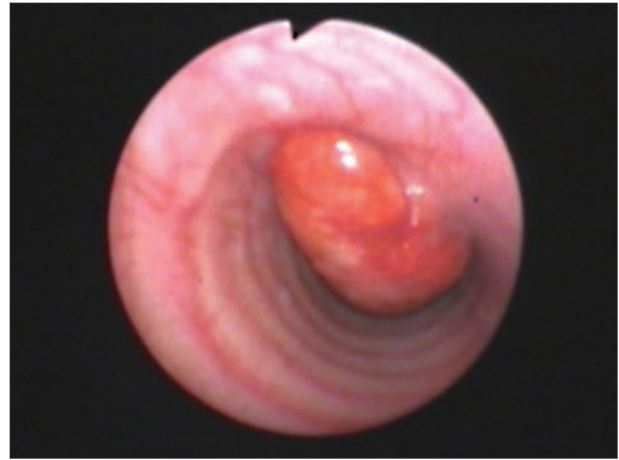

Figure 2—Tracheoscopic view of the intraluminal tracheal mass in the dog in Figure 1.

was diffusely red and friable. Histologic examination revealed a clearly demarcated mass comprised of large lakes of homogeneous, faintly fibrillar eosinophilic material (amyloid) admixed with a cellular infiltrate and covered by mildly hyperplastic respiratory epithelium (Fig 3). The cellular infiltrate consisted of moderate numbers of plasma cells and lymphocytes with fewer histiocytes and occasional clusters of neutrophils. The plasma cells had mild anisocytosis and anisokaryosis, and small numbers had a high nuclear-to-cytoplasmic ratio. Small numbers of binucleate and trinucleate plasma cells and rare mitotic figures (1/10 hpf) were seen. In addition, numerous multinucleated giant cells were seen around and within the amyloid deposits and, in many areas, had engulfed amyloid. Large numbers of reactive vessels were interspersed throughout the mass, and many of these vessels had thick, eosinophilic walls, consistent with amyloid deposition. The base of the mass was composed of abundant fibrous stroma and small islands of chondrocytes (chondroid metaplasia). The presence of amyloid was confirmed by staining with thioflavin T and Congo red stains.³ Fluorescent examination of a section stained with thioflavin T revealed intense staining of the accumulations of amyloid and numerous vessel walls (Fig 4). In sections stained with Congo red, the amyloid deposits exhibited distinctive apple-green birefringence with polarized light. These staining characteristics persisted following treatment with potassium permanganate, consistent with findings expected with immunocyte-derived (AL) amyloidosis. Immunohistochemical staining of the amyloid deposits revealed an intense reaction to antibodies against λ light chain but no reaction to antibodies against κ light chain.^b A diagnosis of nodular amyloidosis was made on the basis of the mild degree of cellular atypia exhibited by the plasma cell infiltrate and the morphologic resemblance to a similar entity in humans, including the granulomatous response to the amyloid and giant cell formation.² This diagnosis did not exclude the possibility of an early extramedullary plasmacytoma or preneoplastic lesion.

The clonality status of the plasma cell component of the mass was evaluated to determine whether the

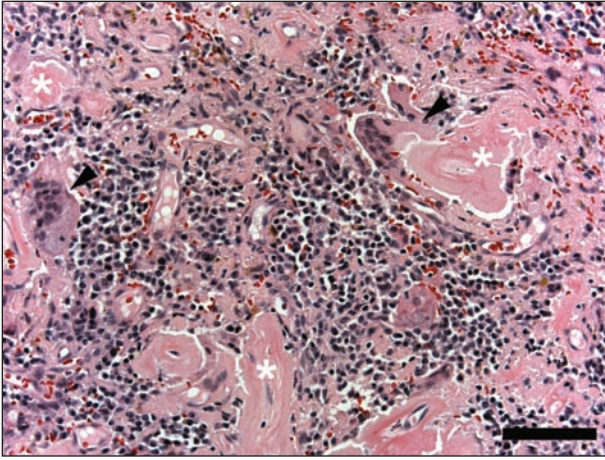


Figure 3—Photomicrograph of a section of the tracheal mass from the dog in Figure 1. The mass consisted of large deposits of amyloid (asterisks) and moderate numbers of plasma cells. Multinucleated giant cells (arrowheads) have engulfed some of the amyloid. H&E stain; bar = 100 μ m.

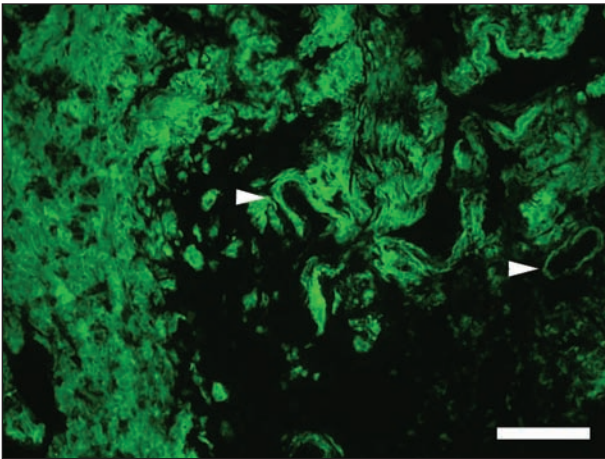


Figure 4—Photomicrograph of a section of the tracheal mass from the dog in Figure 1. There is prominent fluorescence of the large deposits of amyloid and of amyloid deposited in vessel walls (arrowheads). Thioflavin T stain; bar = 100 μ m.

mass was a monoclonal expansion, as would be expected with a plasmacytoma. Genomic DNA was isolated from paraffin-embedded sections of the tracheal lesion, and primers specific for conserved sequences in the genes for the canine immunoglobulin heavy chain variable and joining segments were used in a polymerase chain reaction to amplify the complementarity determining region 3,³ the most variable portion of the molecule. Analysis of the resulting amplification products in a high-resolution polyacrylamide gel revealed 4 discrete bands. A monoclonal expansion of plasma cells, consistent with plasmacytoma and amplified under these conditions, would be expected to result in only 1 or 2 bands, depending on whether heavy chain rearrangement was mono- or biallelic. Thus, the results were consistent with an oligoclonal population of plasma cells, and the diagnosis of a reactive lesion versus a plasmacytoma could not definitively be made.

Two weeks after being discharged from the hospital, the dog was reexamined at the veterinary teaching hospital for suture removal and further diagnostic test-

ing to rule out systemic diseases, including neoplasia (specifically, multiple myeloma and plasmacytoma) and chronic infectious and noninfectious inflammatory diseases. The owner reported that the dog had done well after surgery and had not had any other episodes of respiratory distress or collapse. A physical examination, CBC, abdominal ultrasonography, and survey radiography of the appendicular skeleton and spine were performed, and a bone marrow aspirate was submitted for cytologic examination.

Results of the CBC were unremarkable, other than nonregenerative anemia, mild lymphopenia, and low numbers of reactive lymphocytes consistent with antigenic stimulation. Abdominal ultrasonography revealed mild hepatomegaly considered to be consistent with diabetes mellitus. Results of survey radiography were unremarkable other than moderate spondylosis at the lumbosacral junction. Cytologic examination of a bone marrow aspirate revealed moderate megakaryocyte hyperplasia, mild plasma cell and macrophage hyperplasia, and moderately increased iron storage. There was no evidence of cellular atypia, and findings were consistent with results of the CBC. The increased iron storage together with the nonregenerative anemia was interpreted as being consistent with anemia of chronic disease, possibly secondary to diabetes mellitus or the tracheal mass. The plasma cell hyperplasia was consistent with a mild immunologic reaction to antigenic stimulation but was not supportive of a diagnosis of myeloma as plasma cells were < 5% of the nucleated cells.

The dog was reexamined 6 months and 1 year after surgery. Both times, the owner reported that the dog had not had any episodes of respiratory distress or collapse since surgery. Diagnostic testing at these times did not reveal any evidence of systemic disease other than the preexisting diabetes mellitus. Proteinuria was detected, but electrophoresis indicated that the proteinuria was a result of an increase in albumin concentration, and concentration of light-chain proteins was within reference limits. Radiography of the cervical region 6 months and 1 year after surgery revealed narrowing at the site of the tracheal anastomosis. One year after surgery, thickening of the caudal cervical portion of the trachea in the area of the surgical site was seen. This thickening was thought to be consistent with recurrence or fibrosis at the surgical site. Recheck tracheoscopy and biopsy were recommended but declined by the owner. Seventeen months after initial examination and surgery, the dog was examined because of a recurrence of respiratory difficulty, and a mass associated with the caudal cervical portion of the trachea was identified. Cytologic examination of a fine-needle aspirate of the mass revealed atypical plasma cells consistent with extramedullary plasmacytoma. Euthanasia was elected because of the dog's poor prognosis, and necropsy revealed a 5 \times 5 \times 8 cm plasmacytoma associated with the dorsal aspect of the trachea. Confluent with this primary mass were 2 small tan nodules that extended into the tracheal lumen. Metastases were seen in the liver and were characterized by abundant AL-type amyloid deposition. There was greater cellular atypia among the plasma cells and less inflammation,

compared with the original biopsy specimen. Clonality analysis performed on the necropsy samples revealed a monoclonal population of plasma cells consistent with a plasmacytoma, as compared with the oligoclonal population detected in the initial biopsy specimen. Thus, there was evidence that a malignant clone had emerged as the disease progressed.

Amyloidosis is a generic term for a heterogeneous group of disease processes characterized by the deposition of insoluble fibrillar proteins in various organs and tissues of the body.^{4,6} Amyloid deposits consist primarily of rigid, linear, nonbranching, aggregated protein fibrils that measure 7.5 to 10 nm in diameter and are of an indefinite length.⁶ Each fibril includes identical polypeptide chains arranged into stacked β -pleated sheets. This fibrillar organization gives amyloid distinctive physiochemical properties, including a relative resistance to proteolysis *in vivo*, characteristic apple-green birefringence after staining with Congo red, and fluorescence after staining with thioflavin T.^{4,6}

The pathologic effects of amyloid are attributed to its physical presence, which progressively disrupts tissue architecture and impairs organ function. Extracellular accumulation of deposits has a space-occupying effect that leads to pressure atrophy and necrosis from interference with normal physiologic processes. Although most cases of amyloidosis are systemic in distribution, with clinical signs related to organ insufficiency secondary to deposition of amyloid in the parenchyma and in the walls of associated blood vessels, localized forms are also recognized.

Amyloidosis is classified on the basis of the biochemical type of the constituent fibrillar proteins in amyloid deposits, with the 2 most common biochemical types being reactive systemic (AA) amyloidosis and immunocyte-derived (AL) amyloidosis. Reactive systemic (AA) amyloidosis occurs as a result of various acute, recurrent, or chronic infections; inflammatory or nonimmunocyte derived dyscrasias; or neoplastic disease processes. The condition is characterized by deposition of amyloid A protein in multiple organs and is the most common form of amyloidosis in animals.⁷ In contrast, immunocyte-derived (AL) amyloidosis is the most common form of amyloidosis in humans and occurs secondary to immunocyte dyscrasias.^{5,6,8} In humans, immunocyte-derived (AL) amyloidosis is most often generalized in distribution, although localized forms do occur. Immunocyte-derived (AL) amyloidosis occurs less frequently in domestic animals and is most commonly associated with plasma cell neoplasia.⁹⁻¹³

Amyloidosis is considered localized if it involves a single organ without evidence of systemic involvement. Localized immunocyte-derived (AL) amyloidosis may be associated with diffuse permeation of an organ or with formation of discrete nodular deposits, although the 2 forms may overlap in some cases.¹⁴ In humans with nodular immunocyte-derived (AL) amyloidosis, the respiratory and genitourinary tracts are most commonly affected.^{4,5}

Primary localized amyloidosis of the respiratory tract is uncommon in humans, but may be divided into 3 categories: tracheobronchial amyloidosis, nodular parenchymal amyloidosis, and diffuse parenchymal amy-

loidosis.¹⁵ Depending on the form, amyloid deposits may be characterized as multifocal, plaque-like, or diffuse lesions or as localized nodular masses.

Primary tracheobronchial amyloidosis is rare, with fewer than 100 cases reported in the human literature.^{8,16} Affected individuals have either submucosal plaques or distinct nodular or tumor-like masses known as amyloidomas, but whether plaques or nodules are more common varies from 1 case series to the next.¹⁷ Most patients have locally extensive disease that leads to distortion and eventual obstruction of airways. Tracheobronchial amyloidosis is most frequently a slowly progressive disease in people in which the distribution of amyloid deposits and the degree of airway compromise determine clinical signs; these patients do not develop systemic amyloidosis.

The underlying cause of localized amyloid deposition in humans is unknown, although 2 mechanisms have been postulated for lesions that include a prominent plasma cell component. One possibility is that these lesions represent a preneoplastic or localized proliferative lesion (ie, a plasma cell dyscrasia).¹⁸ The other is that lesions arise secondary to local antigenic stimulation, such as with bacterial or viral infection, or as a result of a hypersensitivity response. Some investigators have demonstrated monoclonality in nodular forms of pulmonary amyloidosis and amyloid tumors in humans.¹⁴ However, it is argued that these lesions should not be classified as plasmacytomas in humans because approximately a third of plasmacytomas develop into myelomas, whereas respiratory tract amyloid lesions do not.¹⁹ This debate may be unfounded in dogs. Although progression of extramedullary plasmacytoma to multiple myeloma is observed in dogs, this behavior appears to be less common.

In the dog described in the present report, we characterized the amyloid as AL protein and took steps to rule out plasmacytoma and plasma cell myeloma. An initial diagnosis of nodular amyloidosis was made on the basis of the localized distribution of the lesion, oligoclonality of the plasma cells, the absence of systemic disease, and the appearance of histologic features comparable to those seen with a similar entity in humans. The disease in this dog progressed to overt extramedullary plasmacytoma with hepatic metastasis. Respiratory difficulty recurred following prolonged abatement of clinical signs for 17 months; therefore, progression in this instance was relatively slow.

A single case of nodular respiratory tract amyloidosis involving a dog has been reported previously.²⁰ The dog was a 10-year-old spayed female Standard Poodle that lost the ability to bark. A mass similar in gross and histologic appearance to the mass described in the present report was found on the ventral surface of the larynx. The type of amyloid was not determined, and other tissues from the dog were not available for histologic examination; therefore, it could not be determined whether the amyloid deposition was a localized lesion or part of a systemic response. Furthermore, the diagnosis was made at necropsy; therefore, there was no information regarding long-term biological behavior.

When treating patients with localized amyloidosis, it is imperative to rule out underlying disease process-

es such as chronic infections, autoimmune disorders, neoplastic disease, multiple myeloma, and occult plasma cell dysplasia. Diagnostic evaluation of affected patients should include a CBC, serum biochemical profile (including evaluation of serum immunoglobulin and protein concentrations), serum electrophoresis, urinalysis, bone marrow evaluation, thoracic and abdominal radiography, survey radiography of the skeleton, and abdominal ultrasonography.²¹ On the basis of findings in this dog, lesions resembling nodular tracheobronchial amyloidosis in dogs should be considered potentially preneoplastic and may precede the development of extramedullary plasmacytoma.

^aSigma-Aldrich Corp, St Louis, Mo.

^bDAKO Corp, Carpinteria, Calif.

References

1. Nelson AW. Diseases of the trachea and bronchi. In: Slatter D, ed. *Textbook of small animal surgery*. 3rd ed. Philadelphia: WB Saunders Co, 2003;858–880.
2. Weiss SW, Goldblum JR. Benign soft tissue tumors and pseudotumors. In: Weiss SW, Goldblum JR, eds. *Enzinger and Weiss's soft tissue tumors*. 4th ed. St Louis, Mo: Mosby Year Book Inc, 2001; 1470–1472.
3. Burnett RC, Vernau W, Modiano JF, et al. Diagnosis of canine lymphoid neoplasia using clonal rearrangements of antigen receptor genes. *Vet Pathol* 2003;40:32–41.
4. Glenner G. Amyloid deposits and amyloidosis: the β -fibrilloses. Part 1. *N Engl J Med* 1980;302:1283–1292.
5. Glenner G. Amyloid deposits and amyloidosis: the β -fibrilloses. Part 2. *N Engl J Med* 1980;302:1333–1343.
6. Grauer G, DiBartola S. Glomerular disease. In: Ettinger S, Feldman E, eds. *Textbook of veterinary internal medicine*. 5th ed. Philadelphia: WB Saunders Co, 2002;1662–1678.
7. DiBartola S, Benson M. The pathogenesis of reactive systemic amyloidosis. *J Vet Intern Med* 1989;3:31–41.
8. O'Regan A, Fenlon H, Beamis J, et al. Tracheobronchial amyloidosis: the Boston University experience from 1984–1999. *Medicine* 2000;79:69–79.
9. van Andel AC, Gruys E, Kroneman J, et al. Amyloid in the horse: a report of nine cases. *Equine Vet J* 1988;20:277–285.
10. Carothers MA, Johnson GC, DiBartola SP, et al. Extramedullary plasmacytoma and immunoglobulin-associated amyloidosis in a cat. *J Am Vet Med Assoc* 1989;195:1593–1597.
11. Geisel O, Stiglmair-Herb M, Linke RP. Myeloma associated with immunoglobulin lambda-light chain derived amyloid in a dog. *Vet Pathol* 1990;27:374–376.
12. Schwartzman RM. Cutaneous amyloidosis associated with a monoclonal gammopathy in a dog. *J Am Vet Med Assoc* 1984;185: 102–104.
13. Platz SJ, Breur W, Geisel O, et al. Identification of lambda light chain amyloid in eight canine and two feline extramedullary plasmacytomas. *J Comp Pathol* 1997;116:45–54.
14. Thompson P, Citron K. Amyloid and the lower respiratory tract. *Thorax* 1983;38:84–87.
15. Colby TV. Miscellaneous conditions and lung diseases of unknown origin. In: Wonsiewicz MJ, Melvin S, eds. *Spencer's pathology of the lung*. 5th ed. New York: McGraw-Hill Book Co, 1996;776–783.
16. Deodhare S, Dasgupta G. Primary amyloidosis of the trachea. *J Laryngol Otol* 1975;89:645–651.
17. Capizzi SA, Betancourt E, Prakash UBS. Tracheobronchial amyloidosis. *Mayo Clin Proc* 2000;75:1148–1152.
18. Toyoda M, Ebihara Y, Kato H, et al. Tracheobronchial AL amyloidosis: histological, immunohistochemical, ultrastructural, and immunoelectron microscopic observations. *Hum Pathol* 1993; 24:970–976.
19. Chen K. Amyloidosis presenting in the respiratory tract. *Pathol Annu* 1989;1:253–273.
20. Dill G, Stookey J, Whitney G. Nodular amyloidosis in the trachea of a dog. *Vet Pathol* 1972;9:238–242.
21. Hawkins P. Diagnosis and monitoring of amyloidosis. *Baillieres Clin Rheumatol* 1994;8:635–659.