

An outbreak of virulent systemic feline calicivirus disease

Kate F. Hurley, DVM, MPVM; Patricia A. Pesavento, DVM PhD; Niels C. Pedersen, DVM PhD; Amy M. Poland, BS; Erin Wilson, DVM; Janet E. Foley, DVM, PhD

Objective—To describe clinical and epidemiologic features of an outbreak of feline calicivirus (FCV) infection caused by a unique strain of FCV and associated with a high mortality rate and systemic signs of disease, including edema of the face or limbs.

Design—Observational study.

Animals—54 cats naturally infected with a highly virulent strain of FCV.

Procedure—Information was collected on outbreak history, clinical signs, and characteristics of infected and exposed cats.

Results—A novel strain of FCV (FCV-Kaos) was identified. Transmission occurred readily via fomites. Signs included edema and sores of the face and feet. Mortality rate was 40%, and adults were more likely than kittens to have severe disease (odds ratio, 9.56). Eleven (20%) cats had only mild or no clinical signs. Many affected cats had been vaccinated against FCV. Viral shedding was documented at least 16 weeks after clinical recovery.

Conclusions and Clinical Relevance—Outbreaks of highly virulent FCV disease are increasingly common. Strains causing such outbreaks have been genetically distinct from one another but caused similar disease signs and were resistant to vaccination. All cats with suspicious signs (including upper respiratory tract infection) should be handled with strict hygienic precautions. Sodium hypochlorite solution should be used for disinfection following suspected contamination. All exposed cats should be isolated until negative viral status is confirmed. Chronic viral shedding is possible but may not be clinically important. This and similar outbreaks have been described as being caused by hemorrhagic fever-like caliciviruses, but hemorrhage is uncommonly reported. Virulent systemic FCV infection is suggested as an alternative description. (*J Am Vet Med Assoc* 2004;224:241–249)

Feline calicivirus (FCV) is a common pathogen of cats, especially those in multiple-cat environments such as shelters and catteries.^{1–4} Infection can cause a variety of clinical signs, including fever, oral ulceration, ocular and nasal discharge, conjunctivitis, and limping.^{5–7} Vaccination with attenuated-live FCV vac-

cines is widely practiced and affords moderate protection against acute disease caused by many, but not all, strains of FCV.^{8–13} Cats in populations in which FCV is endemic may shed the virus in ocular and nasal discharges, saliva, and feces without showing clinical signs of infection. Such carrier cats may serve as a source of infection for others.^{14–16}

In cats, FCV infection is not usually fatal, and individuals that do die are typically young kittens with pneumonia or severe upper respiratory tract infection. However, a more virulent form of FCV appears to be emerging. In 1998, a focal outbreak of infection with a highly virulent, vaccine-resistant strain of FCV (FCV-Ari) occurred in northern California.¹⁷ Infection in affected cats was described as a hemorrhagic-like fever, and 33% to 50% of infected cats died. The organism proved to be highly contagious, spreading via contaminated fomites despite hygienic precautions in a veterinary hospital and research colony. Distinctive clinical signs included facial and limb edema in febrile cats, hair loss and ulcerative dermatitis of the face and feet, and sudden death. The disease did not appear to spread beyond the originally affected clinic, and the reason for the sudden appearance and disappearance of this new strain could not be determined. Since the report of the 1998 outbreak, at least 4 similar outbreaks of FCV infection have been identified in Pennsylvania, Massachusetts, Tennessee, and Nevada.^{a–d}

The purposes of the present study were to describe clinical signs in cats involved in an outbreak of FCV infection caused by a unique strain of FCV, identify risk factors for infection, and characterize viral isolates from affected cats.

Materials and Methods

Data collection—The outbreak occurred between June and August 2002 and involved 3 veterinary practices and a rescue organization in the west Los Angeles area. Information on cases was collected through in-person and telephone interviews and through examination of medical records. On July 8, 2002, 1 of the authors (KFH) visited the 3 affected practices and reviewed records of all suspect cases. Information was collected on all cats hospitalized at any of the 3 practices during the outbreak, regardless of whether they had signs of FCV infection. Individuals working for the rescue organization provided written summaries of cats housed in foster homes at the time of the outbreak.

The first affected practice (practice 1) consisted of 3 suites under separate management and housed in facilities separated from one another by outdoor walkways. Suite A contained a general practice that frequently worked with cat rescue organizations, including the affected rescue organization; incomplete data were obtained from this practice. Suite B contained a referral surgery center that functioned as an emergency practice after hours and housed critical cases from

From the Center for Companion Animal Health (Hurley, Pedersen, Poland, Foley) and the Department of Medicine and Epidemiology (Pedersen, Foley), School of Veterinary Medicine, and the California Animal Health and Food Safety Laboratory System (Pesavento), University of California, Davis, CA 95616; and the California Animal Hospital, 1736 S Sepulveda Blvd, Los Angeles, CA 90025 (Wilson). Supported by Maddie's Fund, the Winn Feline Foundation, and the University of California, Davis, Center for Companion Animal Health. Address correspondence to Dr. Foley.

various day practices, including the practice housed in suite C, for overnight monitoring. Suite C contained a general practice.

The second affected practice (practice 2) was a large referral-general practice located within a quarter mile of practice 1. The third affected practice (practice 3) was a general practice located approximately 1 mile from practices 1 and 2.

The rescue organization consisted of a network of private foster homes. Kittens and cats were rescued by this organization from animal shelters and feral cat colonies in the Los Angeles area. Approximately 40 kittens and several adult cats were in the care of this organization at the time of the outbreak. Cats owned by this rescue organization were regularly examined at practices 1A and 3 and at an unrelated practice that did not have any cases of FCV-Kaos infection.

Case definition—Cases were classified as confirmed, suspect, or possible. A confirmed case was defined as a cat with a consistent exposure history (ie, exposed at an affected practice or the affected rescue organization or in contact with a cat that had been so exposed) from which the Kaos strain of FCV (FCV-Kaos) was isolated, as evidenced by results of genetic sequencing. A suspect case was defined as a cat that had been exposed to a confirmed case and within 2 weeks developed facial or limb edema or sores, alopecia, and ulceration of the face or feet in addition to other signs of FCV infection (ie, fever, oral ulceration, limping, and ocular or nasal discharge); a cat that had been exposed to a confirmed case and died suddenly within 2 weeks; or a cat that had been exposed to a confirmed case and was seropositive for antibodies against FCV-Kaos, regardless of whether the cat did or did not have clinical abnormalities. A possible case was defined as a cat that had been exposed to a confirmed case and reportedly became febrile and developed other signs of FCV infection (eg, oral ulceration, limping, and ocular or nasal discharge) but did not develop edema or die and for which results of viral culture and serologic testing were not available.

Virus isolation and genetic sequencing—Specimens submitted for virus isolation included blood samples anticoagulated with EDTA, oropharyngeal secretions collected on sterile cotton swabs, and spleen and lung specimens collected at the time of necropsy. Specimens were transported to the laboratory in sterile saline (0.9% NaCl) solution or sterile saline solution to which penicillin and amikacin (0.02 mg/mL) had been added and were cultured on a confluent monolayer of Crandall feline kidney cells. Cells were maintained at 37°C in air with 5% CO₂. The growth medium consisted of a 1:1 mixture of Liebovitz L-15 medium and Eagle's minimum essential media with 10% fetal bovine serum, 100 U of procaine penicillin G/mL, and 100 µg of streptomycin/mL. Infection was confirmed by the presence of characteristic cytopathic effects within 12 to 52 hours. Tissue culture fluid was harvested from all infected cells, and total RNA was extracted with a commercial kit.⁶ A reverse-transcription, nested, polymerase chain reaction assay was performed as described,¹⁷ and amplification products were purified.⁴ A 235-basepair portion of the hypervariable region of the viral capsid was sequenced by a commercial service,⁸ and sequences were compared with published sequences for FCV strains.

Serologic testing—Blood samples were collected from 19 cats that survived infection with FCV-Kaos and from 2 kittens that were indirectly exposed but presumed to be uninfected on the basis of an absence of clinical signs and negative viral culture results. All samples were collected between 1 and 6 weeks after the estimated time of infection or exposure of each cat. Serum virus neutralizing titers were determined. Briefly, serial 4-fold dilutions (1:4 to 1:16,384)

of test serum in tissue culture medium were created, and 50 µL of each dilution was placed in wells on 96-well culture plates. Fifty microliters of tissue culture medium containing approximately 1,000 TCID₅₀ of FCV was then added to each well, and plates were incubated for 1 to 2 hours at 37°C. The serum-virus mixture from each well was then transferred to a culture plate containing 1- to 2-day-old, just-confluent, Crandall feline kidney cells. Plates were incubated for 24 hours and examined with an inverted microscope for cytopathic effects typical of FCV. Results were considered positive if samples did not have any evidence of a cytopathic effect at a serum dilution ≥ 1:16.

Each test serum sample was tested against 3 virus isolates: FCV-F9 (vaccine strain), FCV-Kaos, and FCV-53 (an unrelated field isolate from case 53). In addition, serum from specific-pathogen-free cats vaccinated against FCV-F9 was tested against FCV-Kaos and FCV-53, and serum from a specific-pathogen-free cat that had been infected with FCV-Ari was tested against FCV-Kaos.

Histologic testing—Tissue samples were fixed in neutral-buffered 10% formal-saline. Selected tissues were embedded in paraffin and sectioned at a thickness of 4 µm. Sections were mounted on positive-charged glass slides, stained with H&E, and examined by means of light microscopy.

Statistical analyses—Data were summarized, and χ^2 contingency tests were used to determine whether infection status was associated with age (kittens < 6 months old vs cats > 1 year old), vaccination status, or sex. Possible risk factors for infection were identified by calculation of univariate odds ratios (ORs) and 95% confidence intervals (CIs). Values of $P < 0.05$ were considered significant.

Results

Description of the outbreak—A total of 54 cases of FCV-Kaos infection were documented (32 confirmed, 16 suspect, and 6 possible; Fig 1). Because of the complex set of interactions between the rescue organization, its foster homes, and the 3 affected veterinary practices, identifying specific modes of transmission between cats was difficult. In addition to direct

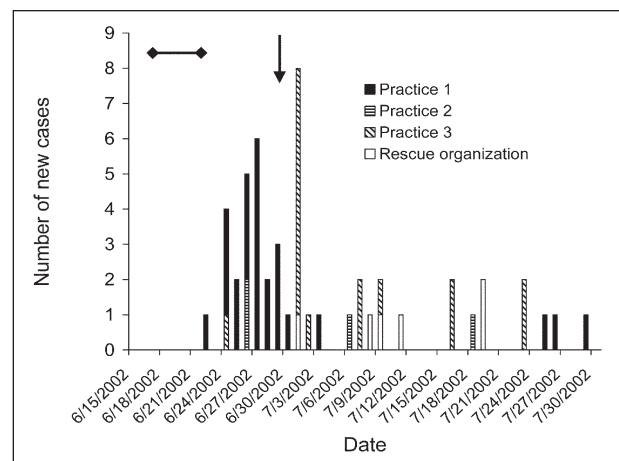


Figure 1—Epidemic curve for outbreak of feline calicivirus (FCV) infection caused by a unique strain (FCV-Kaos) in southern California between June and August 2002. The date of new cases was based on the date clinical signs of FCV infection were first noted by the owner, veterinarian, or caretaker. The horizontal bar indicates the time during which the index case was hospitalized at the first affected practice. The arrow indicates the date of an adoption event held by the rescue organization at which many cats were exposed.

cat-to-cat exposure, FCV-Kaos was spread by fomites, including between the veterinary practices and homes by fomites carried on technicians and owners. Transmission was documented through exposure to both clinically and subclinically infected cats.

The first 4 cats in which FCV-Kaos infection was identified consisted of a female cat and 3 of its kittens (cats 1 through 4), all of which were owned by the rescue organization. These 4 cats had been hospitalized at practice 1A for neutering between June 17 and 24. None of the cats were reportedly ill at the time of hospitalization, except that 1 of the kittens (cat 1) was febrile at the time of discharge. Approximately 1 week later, all 4 cats were febrile, had oral ulcers, and were reluctant to walk. In addition, cat 1 developed pustules on the pinnae and crusting on the nose. These 4 cats apparently recovered fully and were lost to follow-up. Infection was not confirmed by means of viral culture; therefore, they were classified as possible cases on the basis of clinical signs alone. None of the other cats examined at practice 1A during this time reportedly showed signs of unusual illness or upper respiratory tract infection. All cats subsequently identified as infected were directly or indirectly (via fomites) exposed to cat 1 or to a cat that had been exposed to cat 1. No signs of FCV-Kaos infection were reported for 15 kittens cared for by the rescue organization during the time of the outbreak that had not been exposed to cat 1, but 23 of 25 kittens cared for by the rescue organization that were exposed to cat 1 developed signs of FCV-Kaos infection. The percentage of exposed cats that developed infection was significantly ($P < 0.001$) higher than the percentage of nonexposed cats that did.

There was no movement of cats between practices 1A and 1B during the week that the first 4 infected cats were hospitalized. However, technicians routinely went back and forth between the 2 practices, especially at night. The first infected cat identified at practice 1B was a vaccinated, 5-year-old castrated-male, indoor-only cat (cat 5) that was hospitalized overnight on June 21 following surgery at another practice to remove an intestinal foreign body. The cat was febrile on June 22 and suffered cardiopulmonary arrest and died within 24 hours. Virus isolation and genetic sequencing later confirmed that this cat was infected with FCV-Kaos. During the next week, 12 cats hospitalized at practice 1B and 2 cats belonging to a technician employed by the practice developed signs of severe FCV infection, including high fevers, facial and limb edema, and sudden death. Five of these cats were recovering after surgery, and postsurgical complications were initially suspected as a possible cause of the clinical signs. However, 7 cats were previously healthy blood donor cats or healthy cats boarding in a separate ward, and 3 of these cats died.

Because of the development of clinical signs in blood donor cats and cats boarding at the practice, an infectious agent was suspected. On June 29, the surviving blood donor cats at practice 1B were moved to an isolation area, and the entire practice, including all rooms, cages, and instruments, was thoroughly cleaned with a 1:32 dilution of 5% sodium hypochlorite in water (prior to the outbreak, a quaternary

ammonium compound was used for routine cleaning). Instruments that couldn't be bleached were autoclaved or cold sterilized, and the practice was closed to cat admissions for a week. A critically ill cat remained in the main treatment area, along with several exposed cats that had not yet developed signs of illness. On June 30, virulent FCV infection was tentatively identified by one of the authors (JF) via telephone consultation. The diagnosis was confirmed on July 2 on the basis of positive virus isolation results for an affected cat, and all remaining exposed cats were moved to a separate area and strictly isolated.

There was no evidence of further transmission at practice 1 after this time, with the exception of a 14-year-old castrated-male domestic longhair cat hospitalized during the day at practice 1C and monitored at night at practice 1B for regulation of diabetes mellitus between June 22 and June 30. The cat was apparently healthy when discharged on June 30 and was examined at practices 1C and 1B several times between July 11 and 24 for management of the diabetes mellitus, during which time no signs of FCV infection were reported. On July 26, the cat became febrile, and on July 27, the cat developed oral ulcers and edema of the face and paws. The cat was euthanized on July 28. The only other infected cat identified at practice 1B had been hospitalized between July 24 and 26 for treatment of a fractured jaw. The cat was apparently healthy when discharged on July 26 but was reexamined 3 days later because of a fever and facial and limb edema and died on August 5. For both of these cats, infection was confirmed on the basis of results of viral culture and genetic sequencing.

The first infected cats identified at practice 2 were housemates of cat 5. These 2 cats were examined on June 26 because of fever and signs of upper respiratory tract infection. These cats had not had any direct contact with cat 5 after it had developed signs of FCV infection and were presumably exposed via fomites carried by the owners, who had visited cat 5 while it was hospitalized. The third infected cat identified at practice 2 was a cat that had been hospitalized on June 28 for diabetic regulation in the same ward where the first 2 infected cats identified in this practice had been hospitalized. The cat was apparently healthy when discharged the following day but was examined at practice 1B on July 6 because of anorexia, oral ulceration, icterus, and edema of all 4 paws and was euthanized.

The organism was apparently spread to practice 3 by cats 1 through 4. After these cats were released from practice 1A on June 24, they were returned to foster homes. They appeared healthy on June 30 and were brought to an adoption event where they had contact with at least 9 other kittens from several litters in the care of the same rescue organization. Seven of the 9 kittens exposed at this adoption event were later identified as being infected.

The day after the adoption event, cats 1 through 4 appeared to have difficulty walking, were febrile and anorectic, and had oral ulcerations. The 3 kittens were admitted to practice 3 where they were treated from July 1 through 6, and the mother cat was treated for upper respiratory tract infection as an outpatient. Four

other kittens exposed at the adoption event were also admitted and treated at practice 3 between July 1 and 18. Other infected cats examined at practice 3 consisted of 3 additional kittens from the rescue organization, 2 inpatients at practice 3, 4 outpatients at practice 3, and an adult littermate from the same household as a cat exposed as an inpatient at practice 3.

Initially, the rescue organization kittens examined at practice 3 were believed to have typical upper respiratory tract infection, and most were housed in isolation. One kitten that had less typical signs was housed in a separate ward. Standard hygienic precautions were taken, including routine cleaning with a quaternary ammonium disinfectant. On July 6, 1 of the kittens exposed at the adoption event developed facial edema and was moved to isolation. Also on July 6, clinicians from practice 3 learned of the outbreak at practice 1B. On the basis of recommendations from practice 1B, isolation precautions were increased so that only designated staff were allowed in the isolation ward; full protective clothing, including shoe covers, gowns, and caps, was mandatory in the isolation ward; and separate equipment and supplies were used in that ward. In addition, the practice was thoroughly cleaned with sodium hypochlorite solution. However, the practice did not close to cat admissions at that time, and 2 apparently healthy cats remained in the boarding ward and main treatment area.

One of the healthy inpatients at practice 3 was a 4-year-old spayed female domestic shorthair cat that boarded at the practice from June 28 through July 11. The cat was examined daily and rectal temperature was monitored, but no abnormal findings were noted and the cat never developed any signs of FCV infection. The cat was discharged on July 11, and 12 days later, the housemate developed signs of severe FCV-Kaos infection. Because practice 3 was closed to cat admissions at that time, the cat was brought to another practice and then transferred to practice 2, where it died on July 30.

Four cats apparently became infected while examined as outpatients at practice 3, even though 3 of these cats were examined after additional hygienic precautions had been established on July 6. When this was recognized on July 18, practice 3 closed to cat admissions for 1 week, and a stray cat that had been housed in the main treatment area since July 4 was examined. Although this cat had never appeared ill, small oral ulcers were observed, a mild fever was detected, and FCV-Kaos was isolated, as confirmed by genetic sequencing. This cat, along with all remaining rescue organization kittens, was released to the rescue organization. Surviving infected cats were treated as outpatients. No further infected cats were identified at practice 3 after these precautions were instituted.

The last 5 infected cats were rescue organization kittens exposed in a foster home to 1 of the surviving kittens released from practice 3. After recovering from severe illness, this kitten had been placed in a cage with 5 kittens with no apparent exposure to FCV-Kaos and with 2 kittens that may have been exposed at practice 3. Samples had been collected from all 7 of these kittens, and results of viral culture for FCV-Kaos were

negative, although a field strain FCV (FCV-53) was isolated from 1 of the kittens. None of the kittens reportedly became ill after being housed with the surviving kitten from practice 3, but all were seropositive for antibodies against FCV-Kaos, and FCV-Kaos was later cultured from 1 of the kittens.

Two owned cats survived FCV-Kaos infection and were released to homes with naive cats. While these cats were hospitalized, samples were submitted for viral culture at 1- to 2-week intervals. One of these cats was released 4 weeks after clinical signs of infection had remitted and results of a single viral culture were negative. The other had never had clinical signs of FCV infection, but had had intermittent positive viral culture results. This cat was released from the hospital 10 weeks after initial exposure. In both instances, other cats in the household remained apparently healthy after these cats returned home.

Twenty kittens owned by the rescue organization were classified as possible, suspect, or confirmed cases and survived. At least 1 oropharyngeal swab specimen was obtained from all of these cats, and results of viral culture were negative for FCV-Kaos for all but 1. As of July 30, surviving kittens were in the process of being adopted to homes that did not currently have any cats.

Clinical signs—Fever was the most commonly reported clinical sign, affecting 44 of the 54 (81%) infected cats. Median rectal temperature was 40.6°C (105.1°F; range, 39.4° to 41.4°C [103.0° to 106.5°F]). Limb or facial edema was reported in 28 of the 54 (52%) cats, with limb edema reported in 14 cats, facial edema reported in 3, and limb and facial edema reported in 11. In decreasing order of frequency, other abnormalities reported were oral ulcers (25 cats; 46%); nasal discharge (16; 30%); dyspnea (9; 17%); sores on or crusting or alopecia of the face, pinnae, or feet (9; 17%); ocular discharge or conjunctivitis (6; 11%); clinically apparent jaundice (6; 11%); pleural effusion (5; 9%); diarrhea (4; 7%); vomiting (4; 7%); and limping (3; 6%). Hemorrhage was reported in only 2 cats, 1 of which had bleeding from the nose and the other of which had bleeding from the nose and rectum.

Severity of illness ranged from no clinical signs to death. No abnormalities were observed in 3 of the 54 (6%) cats; these cats were considered infected on the basis of positive viral culture results. In 8 (15%) cats, only mild signs were observed; these were limited to oral ulcers, nasal or ocular discharge, and fever < 40°C (104°F). Moderate signs were reported in 8 (15%) cats including fever > 40°C, lethargy or inappetence for > 1 day, sores or pustules on or crusting of the skin, ocular or nasal discharge, and oral ulcers. Severe signs including edema, respiratory distress, and death were reported in 35 (65%) cats; 13 of the 35 cats with severe signs survived.

The date of first exposure could be determined for 17 cats. For these cats, median time from exposure to first observation of signs was 4 days (range, 1 to 12 days). Longer apparent incubation times were generally observed in cats secondarily exposed by another sick cat in the home. In cats exposed as inpatients, the longest time observed between exposure and observa-

tion of signs was 5 days. One cat developed signs 34 days after first probable exposure but may have been exposed a second time between 2 and 15 days prior to the onset of signs; however, no other cat exposed to the same environment during this later time period developed disease.

Results of serum biochemistry panels were available for 10 cats. Abnormalities included hyperbilirubinemia in 6 cats (range, 0.6 to 3.9 mg/dL), hypoalbuminemia in 5 (range, 1.1 to 2.1 g/dL), high aspartate aminotransferase activity in 3 (range, 103 to 223 U/L), high alanine aminotransferase activity in 2 (range, 102 to 116 U/L), and high creatine kinase activity in 5 (range, 639 to 10,930 U/L).

Results of a CBC were available for 8 cats. Three had mild neutrophilia (range, 8,549 to 11,616 cells/ μ L; reference range, 2,500 to 8,500 cells/ μ L) and 5 had mild or moderate lymphopenia (range, 180 to 1,188 cells/ μ L; reference range, 1,200 to 8,000 cells/ μ L). The Hct was slightly low in 2 cats (25%; reference range, 29% to 48%).

Pathologic findings—Necropsy results were available for 5 cats. In all 5, infection with FCV-Kaos was confirmed on the basis of results of viral culture and genetic sequencing of oropharyngeal swab specimens and tissue samples. Four of the 5 died and 1 was euthanized because of severe illness. Duration of disease from first observation of clinical signs to death ranged from 4 to 9 days. In all cats, there was abundant, bright-yellow subcutaneous edema most markedly affecting the face and limbs. In 2 cats, dependent edema extended along the thoracic wall and affected the entire inguinal and axial regions. Conjunctivae were red and swollen with crusted material adhered to the medial canthi. Ulcers were seen in all cats, although sites and extent were variable. Three cats had circumferential ulceration at the junction between the paw pads and haired skin. In 2 cats, there were 0.4-cm-diameter to coalescing ulcers of the dorsal, lateral, and ventral tongue surfaces. In 2 other cats, although the tongue appeared unaffected, there was ulceration of the septum of the nares and the haired skin overlying the nose. In all cats, there was up to 100 mL of pale red, slightly opaque fluid in the abdominal and thoracic cavities, and in 1 cat, there was extensive pericardial fluid of similar character. In 2 cats, there was minimal, multifocal omental fat necrosis. Histologic analysis revealed that ulcerations in all cats represented regions of epithelial necrosis and ulceration with minimal inflammation. The superficial dermis underlying ulcerated regions was often disrupted and expanded by edema and cell debris. The remainder of the dermis was minimally affected other than occasional extension of necrosis into the follicular epithelium. In 3 cats, massive or centrilobular, peracute hepatic necrosis was present.

Morbidity and mortality rates and risk factors for disease—The attack rate for exposed cats could not be calculated, as information regarding the total number of cats exposed as outpatients or in homes via fomites could not be obtained. The attack rate for cats hospitalized for ≥ 12 hours concurrently with an infected cat

or from the same household as a case cat was 94% (47/50). The risk of disease among cats in the care of the rescue organization that were exposed to the suspected index case (cat 1) was significantly greater than the risk among cats in the care of the rescue organization at the same time that were not exposed to the index case. The overall case fatality rate was 41% (22/54). In cats > 1 year old, the case fatality rate was 59% (19/32), and in kittens < 6 months old, it was 14% (3/22). Cats > 1 year old were significantly more likely than kittens < 6 months old to develop severe disease or die (OR, 9.56; 95% CI, 2.82 to 32.39; $P < 0.001$). Sex was not a significant risk factor for severe disease or death. Few of the cats were known to be unvaccinated; therefore, risk associated with vaccination could not be assessed. Of the kittens for which vaccine status was known, 7 had received a modified-live intranasal vaccine, and 11 had received a modified-live SC vaccine. There was no significant difference in likelihood or severity of disease between these 2 groups of vaccinated kittens. Twenty-three of the infected cats were known to be vaccinated against FCV infection, and 3 adult cats and 3 kittens were known to be unvaccinated. Vaccination status of the remaining cats was unknown.

Viral isolation and duration of shedding—A total of 77 oropharyngeal swab specimens were submitted for viral culture. Nineteen of these were from cats from which a single specimen was obtained; the remainder were from 18 cats from which 2 to 5 specimens were obtained at ≥ 1 -week intervals. All specimens were obtained between July 2 and November 15. Because the cause of the outbreak was not suspected for approximately 2 weeks, specimens were not obtained from cats affected early in the outbreak. Results of virus isolation were positive for 15 of 17 (88%) specimens collected at the peak of clinical signs. Persistent or intermittent shedding was observed in 4 of 18 cats from which specimens were obtained more than once between 1 and 16 weeks after infection. In 11 cats, serum as well as oropharyngeal swab specimens were submitted for virus isolation. In 2 of those 11 cats, results were positive for both oropharyngeal and serum specimens; in 3, results were positive for oropharyngeal specimens but negative for serum specimens; and in 6, results were negative for both specimens. Lung and spleen specimens from 5 cats were submitted for viral culture. In 3, results for both lung and spleen specimens were positive; and in 2, results for lung specimens were negative, but results for spleen specimens were positive. All positive viral culture results were confirmed by means of genetic sequencing.

Viral characterization—Nucleotide sequences of an approximately 235-base-pair portion of the hypervariable region of the capsid protein for viral isolates from clinically affected and exposed cats were compared with sequences for several field strains of FCV, the vaccine strain of FCV (FCV-F9), and FCV-Ari, an FCV strain isolated during a 1998 northern California outbreak.¹⁷ All FCV-Kaos isolates clustered within a single clade that was genetically distinct from the comparison strains (Fig 2). An isolate closely related to the

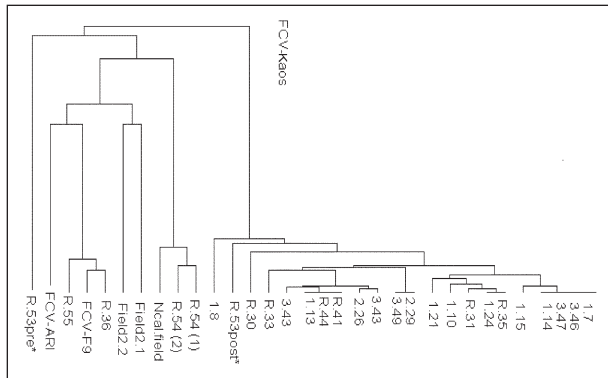


Figure 2—Dendrogram depicting the relationship of FCV-Kaos strains isolated from cats during an outbreak in southern California during 2002 to a strain causing a separate outbreak of virulent systemic FCV infection (FCV-Ari), the vaccine strain (FCV-F9), and concurrently isolated field strains. The source of the isolate is indicated to the left of the decimal point, with 1, 2, and 3 representing practice 1, 2, and 3, respectively, and R representing the rescue organization. The number to the right of the decimal point indicates the case number. Various field strains from other locations in California (Ncal.field and Scal.field) are included for comparison. The strains R.54 (1) and R.54 (2) were isolated from 2 rescue organization kittens with signs of severe hepatic disease. The strain R.53pre* was isolated from a rescue organization kitten early in the outbreak; the strain R.53post* was a FCV-Kaos strain isolated from the same kitten after it was housed with a kitten that had recently recovered from FCV-Kaos infection.

vaccine strain was obtained from 1 cat, although FCV-Kaos was obtained from the littermate of that cat. Two other distinct strains of FCV were isolated from rescue organization kittens, including 1 that had signs of severe liver disease and 1 that had mild signs of upper respiratory tract infection and fever. Homology between sequences of FCV-Kaos and FCV-F9 was 73.4%, and homology between sequences of FCV-Kaos and FCV-Ari was 76.5% (Fig 3). Although there were minor single nucleotide differences among FCV-Kaos isolates, all were characterized by a 3-base-pair deletion not observed in the other strains.

Results of serologic testing—Nineteen of the cats from which blood samples were collected for serologic testing were either confirmed to be infected with FCV-Kaos or housed in the same cage as a cat confirmed to be infected, and all 19 were seropositive for antibodies against FCV-Kaos. All 6 cats housed in the same cage as the cat from which FCV-53 was isolated were seropositive for antibodies against FCV-53, as were 2 cats without any history of exposure to this cat. Of the 19 cats seropositive for antibodies against FCV-Kaos, 15 were also seropositive for antibodies against FCV-F9, which was consistent with their vaccination history.

The 2 cats from which blood samples were collected for serologic testing that were indirectly exposed to FCV-Kaos but presumed to be uninfected on the basis of an absence of clinical signs and negative viral culture results were seronegative for antibodies against FCV-Kaos and FCV-53.

Cytopathic effects were observed at a dilution of < 1:4 when serum from specific-pathogen-free cats vaccinated with FCV-F9 was reacted with FCV-Kaos or FCV-53, indicating that antibodies generated by vaccination did not neutralize these viral strains. Cytopathic

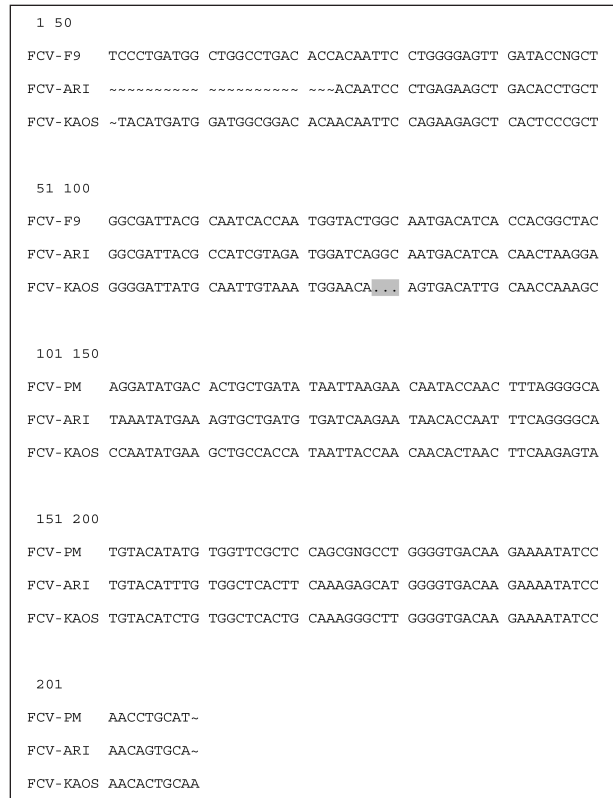


Figure 3—Alignment of the nucleotide sequences of a portion of the hypervariable region of the viral capsid for FCV-Kaos, FCV-Ari, and FCV-F9. The characteristic 3-base-pair deletion found in all FCV-Kaos strains is highlighted (nucleotide positions 78 through 80).

effects were also observed at a dilution of < 1:4 when serum with antibodies against FCV-Ari was reacted against FCV-Kaos virus, indicating that antibodies against FCV-Ari did not neutralize FCV-Kaos.

Discussion

Like other members of the family Caliciviridae, FCV is a positive-strand RNA virus prone to high mutation rates and minimal repair.^{18,20} Strains with wide-ranging virulence have been documented.^{7,14,20,21} The ability of a calicivirus to mutate and produce a devastating epidemic has been demonstrated by the emergence of **rabbit hemorrhagic disease (RHD)**. This disease, unknown before 1984, has since spread worldwide, causing the death of tens of millions of rabbits.²² Like the highly virulent FCV strain described in the present study, the causative organism of RHD spreads readily, is associated with high mortality rates, results in more severe disease in adults than in juveniles, and causes lesions suggestive of vascular damage.

In the first reported outbreak of FCV associated with high mortality rates, edema, and multiorgan involvement, 2 cats developed signs of **disseminated intravascular coagulation (DIC)**, and this was confirmed histologically as the cause of death in 1 of these cats.¹⁷ Because of the observation of DIC in these cats and the similarities to RHD, viruses from this and similar outbreaks have been called hemorrhagic FCVs. However, hemorrhage has been infrequently reported

in subsequent outbreaks, and FCV infection in the cat in which DIC was confirmed may have been complicated by concurrent *Aspergillus* infection. Evidence of DIC was not reported clinically or seen histologically in any of the cats in the present study infected with FCV-Kaos. Therefore, we suggest that outbreaks with this and similar FCV strains might better be described as virulent systemic FCV disease.

Outbreaks of virulent systemic FCV disease have been reported with increasing frequency. This may be attributable to increased recognition following the identification of FCV-Ari in 1998 but may also reflect a true increase in the occurrence of such outbreaks. Because of the devastating effects of this disease for infected cats and affected practices, it is crucial to understand how it arises and disappears and what measures can be taken to control its impact.

The FCV-Ari and FCV-Kaos outbreaks, along with suspected or confirmed outbreaks of virulent systemic FCV disease in Pennsylvania, Massachusetts, Tennessee, and Nevada, share several important features.^{a-d,17} For instance, in 5 of the 6 outbreaks, a suspect index case could be identified, and in all 5, the index case was a shelter or rescue cat. In all 6 outbreaks, otherwise healthy, adult, vaccinated cats were prominently affected; the disease spread readily, including via fomites, to cats belonging to employees or clients; spread of the disease was limited to the affected practices or shelter with no evidence of spread to the community; and the outbreak resolved in approximately 2 months.

Several factors may account for the fact that the index case in this and other outbreaks has been a shelter cat or kitten. Antigenic change, presumably sometimes reflecting changes in pathogenicity, occurs during persistent infection with FCV,^{15,18} and persistent infection is more common in multiple-cat environments, such as shelters and catteries.^{13,23} Kittens born to persistently infected mothers may shed virulent FCV but develop only minimal clinical signs themselves,²⁴ and infected kittens in the present study typically had less severe signs than did adult cats. Either of these could account for the relatively mild clinical signs observed in the apparent index case in the present outbreak. The high proportion of kittens, high population turnover, and constant influx of susceptible animals common in shelters and rescue organizations would be expected to increase the opportunity for viral spread, replication, and mutation.

Methods of spread observed in this and other outbreaks have implications for control methods. Mildly affected animals can play an important role in disease transmission, as may have occurred when cats 1 through 4 in the present study were taken to the adoption event or when an apparently healthy cat was discharged from the hospital and its housemate developed fatal disease. Similarly, RHD has been spread by movement of subclinically infected animals.²⁵ Thus, during an outbreak of FCV infection, all exposed cats should be considered potentially contagious, regardless of clinical signs, until results of virus culture of at least 2 oropharyngeal swab specimens obtained at weekly intervals are negative.

In the present study, we found that FCV-Kaos was easily transmitted through fomites, with spread of the disease facilitated by client and technician traffic between practices. Recognition of the infectious nature of the disease may have been delayed because the index case was not seen at the practice where disease first spread, and the disease was subsequently spread to other practices when clients took cats infected at 1 practice to another practice for treatment. This highlights the need for clear and rapid communication between practices when an outbreak is suspected. Aerosol transmission of FCV is not thought to play an important role in spreading infection over distances > 4 ft,²⁶ and careful attention to preventing fomite transmission appeared adequate to prevent spread of FCV-Kaos. Cats admitted to contaminated areas that had been thoroughly cleaned with sodium hypochlorite solution were not infected, and sodium hypochlorite is more effective for disinfecting areas contaminated with FCV than are quaternary ammonium compounds.²⁷⁻²⁹ Feline calicivirus can persist in the environment in a dried state at room temperature (20°C) for up to 28 days,²⁹ and the calicivirus that causes RHD remains infective in a dried state on cloth (such as protective clothing) at room temperature for 105 days.³⁰ This may have played a role in the seemingly delayed transmission of infection in 1 cat, which developed clinical signs 26 days after thorough cleaning and removal of infected cats from practice 1B.

In the present study, cats of all ages were susceptible to infection with FCV-Kaos, but adults were significantly more likely than kittens to develop severe disease and die. Similar findings have been reported in studies of RHD.^{22,25} One explanation for this may be that the immune system response is associated with disease severity. It was not possible to eliminate confounding associated with age and vaccination status in the present study because almost all adult cats were vaccinated or had unknown vaccination status. However, vaccinated cats have been prominently affected in all known outbreaks. Several explanations for these findings are plausible. One possibility is that there is a bias toward detection of vaccine-resistant FCV strains that cause virulent systemic FCV disease because vaccine-susceptible strains would likely fail to persist in populations in which most cats were vaccinated. A second possibility is that mutations that produce strains associated with virulent systemic FCV disease may change the structure of major protective antigens and confer vaccine resistance. Finally, there may be an immune-mediated component to the disease pathogenesis, such that vaccinated animals are actually more susceptible to severe sequelae.

The pathophysiology of virulent systemic FCV disease is unknown. In the case of RHD, lesions have been attributed to direct viral cytotoxic effects and to systemic vascular effects secondary to monocyte invasion.^{31,32} Given the severe edema, the histologic appearance of the ulcers, and the variable effects of the disease, lesions seen with FCV-Kaos infection were most consistent with systemic vascular damage.

Viral culture with genetic sequencing and serologic testing of many exposed cats in the present study

allowed recognition of a wider range of clinical manifestations than has been reported in other outbreaks of virulent systemic FCV disease, including mild and sub-clinical infection in some cats. Reliance on a case definition based on clinical signs rather than results of virus isolation would have substantially overestimated mortality rate and underestimated morbidity rate associated with FCV-Kaos infections, especially in kittens. This may have been a problem in previous outbreaks, in which less intensive follow-up was possible.

Use of viral culture and a polymerase chain reaction assay to isolate the virus from oropharyngeal swab specimens proved to be a sensitive method of diagnosing disease when specimens were obtained during acute infection or at necropsy. Positive culture results were obtained soon after exposure, even from cats that were not yet showing clinical signs. However, the sensitivity of viral isolation decreased as the disease progressed, and a negative result for a single swab specimen could not be used to rule out low level excretion of the virus.¹⁵ Serologic testing was useful in confirming a history of exposure, and results for cats in the present study suggested that it was sensitive and specific in that the 2 cats that were believed to have not been exposed to FCV-Kaos were seronegative, and all 19 cats that were exposed were seropositive.

All isolates of FCV-Kaos in the present study were closely related to one another but were not closely related to FCV-Ari, another strain that causes virulent systemic FCV disease.¹⁷ Only a short portion of the FCV-genome was sequenced and compared, and the mutation responsible for increased virulence may not be included in this portion of the genome, or there may be multiple mutations that can lead to this manifestation of disease. Other studies have failed to identify a correlation between genetic or antigenic type and disease manifestation in FCV infection.²⁰ Because FCV is commonly isolated from the oral cavity of clinically healthy cats and cats with upper respiratory tract infection,¹⁻³ positive viral culture results for a cat with signs suggestive of virulent systemic FCV infection should not be considered diagnostic without the support of results of genetic sequencing demonstrating a distinct strain in > 1 affected cat. Mutations conferring this phenotype and the range of genotypes associated with virulent systemic FCV disease are an important area for further research.

There was concern that some of the cats in the present study that survived FCV-Kaos infection would become chronic carriers, as commonly occurs with other strains of FCV.^{14,15,33} Cats infected with FCV-Ari still had positive viral culture results up to 10 weeks after infection,¹⁷ and shedding of FCV-Kaos was demonstrated to persist at least 16 weeks in some cats. Although it has not been reported in any outbreak, it seems possible that chronic carriers could transmit the virus to other cats long after recovery from clinical signs. However, in the present study, at least 1 cat was released to a home containing naïve cats 1 week after a positive viral culture result was obtained, and the other cats did not become ill. It has been suggested that cats with fluctuating viral culture results represent low-level shedders that are less likely to pose an infectious threat to other cats.¹⁵

Ultimately, the reason for the apparent disappearance of FCV-Kaos could not be determined in the present study. Widespread susceptibility to infection was observed regardless of age, health status, or vaccination status, so it seems unlikely that the virus simply ran out of susceptible hosts. A highly virulent infection may kill off its hosts faster than the disease can spread; however, in this outbreak at least 32 cats survived and some were documented to continue shedding virus indistinguishable from virulent FCV-Kaos. If the virus retained the same virulence and ease of spread observed early in the outbreak, one would expect that sporadic cases, or even additional outbreaks, would arise from this potential reservoir of infected cats. There was widespread awareness of virulent systemic FCV disease in the veterinary community in the area, as evidenced by many reports of possible cases (ruled out on the basis of results of viral culture and genetic sequencing) in the weeks and months following the outbreak, so reporting bias is unlikely. It may be that the mutation that led to FCV-Kaos reverted during passage to yield a less virulent strain. Variant strains arise in persistently infected cats, possibly as a result of immune pressure.¹⁹ Evidence of ongoing mutation may have been seen in the variation among isolates obtained within the FCV-Kaos clade, although a minimal amount of variability may have been attributable to polymerase-associated sequencing infidelity. The fact that all outbreaks of virulent systemic FCV disease thus far reported have been self-limiting in the face of strict but not absolute control procedures indicates that outbreaks occur only when a number of virologic, environmental, and host factors converge. In the absence of 1 or more of these essential factors, virulent systemic disease either does not occur or cannot be sustained to the point of a significant outbreak. The role of shelters in these infections should not be overlooked, and studies of FCV behavior in these environments may provide useful information.

Calicivirus infection causing virulent systemic FCV disease remains rare, despite being recognized with increasing frequency. In the absence of a protective vaccine, however, rapid recognition and implementation of control measures is the best defense against a severe outbreak, and clinicians should be alert for signs of the disease, especially in cats with a recent history of exposure to a multiple-cat environment. Even mildly ill cats from high-risk environments should be handled with suitable precautions, and contaminated fomites should be cleaned with a disinfectant proven effective against caliciviruses. The self-limiting nature of this and previous outbreaks provide hope but should not allow for complacency. A future strain may not be so confined and, like RHD, pose a serious risk for the general cat population.

^aRichards JR, Department of Population Medicine and Diagnostic Sciences, Cornell University, Ithaca, NY: Personal communication, 2002.

^bDinnage J, Massachusetts Society for Prevention of Cruelty to Animals, Boston, Mass: Personal communication, 2002.

^cKennedy M, Department of Comparative Medicine, University of Tennessee, Knoxville, Tenn: Personal communication, 2002.

^dAnderson S, Feline Medical Center, Reno, Nev: Personal communication, 2002.

^cQiagen tissue kit, Qiagen, Chatsworth, Mass.

^dMicrocon-50 column, Millipore Corp, Bedford, Mass.

^eDavis Sequencing, Davis, Calif.

References

1. Harbour DA, Howard PE, Gaskell RM. Isolation of feline calicivirus and feline herpesvirus from domestic cats 1980 to 1989. *Vet Rec* 1991;128:77–80.
2. Coutts AJ, Dawson S, Willoughby K, et al. Isolation of feline respiratory viruses from clinically healthy cats at UK cat shows. *Vet Rec* 1994;135:555–556.
3. Binns SH, Dawson S, Speakman AJ, et al. A study of feline upper respiratory tract disease with reference to prevalence and risk factors for infection with feline calicivirus and feline herpesvirus. *J Feline Med Surg* 2000;2:123–133.
4. Pedersen NC. Common infectious diseases of the multiple cat environment. In: Pratt P, ed. *Feline husbandry: diseases and management in the multiple cat environment*. Goleta, Calif: American Veterinary Publications, 1991;163–289.
5. Dawson S, Bennett D, Carter SD, et al. Acute arthritis of cats associated with feline calicivirus infection. *Res Vet Sci* 1994;56:133–143.
6. Reubel GH, Hoffmann DE, Pedersen NC. Acute and chronic faucitis of domestic cats. A feline calicivirus-induced disease. *Vet Clin North Am Small Anim Pract* 1992;22:1347–1360.
7. Hoover EA, Kahn DE. Experimentally induced feline calicivirus infection: clinical signs and lesions. *J Am Vet Med Assoc* 1975;166:463–468.
8. Pedersen NC, Hawkins KF. Mechanisms for persistence of acute and chronic feline calicivirus infections in the face of vaccination. *Vet Microbiol* 1995;47:141–156.
9. Hohdatsu T, Sato K, Tajima T, et al. Neutralizing feature of commercially available feline calicivirus (FCV) vaccine immune sera against FCV field isolates. *J Vet Med Sci* 1999;61:299–301.
10. Knowles JO, Dawson S, Gaskell RM, et al. Neutralisation patterns among recent British and North American feline calicivirus isolates from different clinical origins. *Vet Rec* 1990;127:125–127.
11. Dawson S, McArdle F, Bennett D, et al. Investigation of vaccine reactions and breakdowns after feline calicivirus vaccination. *Vet Rec* 1993;132:346–350.
12. Kahn DE, Hoover EA, Bittle JL. Induction of immunity to feline caliciviral disease. *Infect Immun* 1975;11:1003–1009.
13. Gaskell CJ, Gaskell RM, Dennis PE, et al. Efficacy of an inactivated feline calicivirus (FCV) vaccine against challenge with United Kingdom field strains and its interaction with the FCV carrier state. *Res Vet Sci* 1982;32:23–26.
14. Turnquist SE, Ostlund E. Calicivirus outbreak with high mortality in a Missouri feline colony. *J Vet Diagn Invest* 1997;9:195–198.
15. Wardley RC. Feline calicivirus carrier state. A study of the host/virus relationship. *Arch Virol* 1976;52:243–249.
16. Povey RC, Wardley RC, Jessen H. Feline picornavirus infection: the in vivo carrier state. *Vet Rec* 1973;92:224–229.
17. Pedersen NC, Elliott JB, Glasgow A, et al. An isolated epizootic of hemorrhagic-like fever in cats caused by a novel and highly virulent strain of feline calicivirus. *Vet Microbiol* 2000;73:281–300.
18. Johnson RP. Antigenic change in feline calicivirus during persistent infection. *Can J Vet Res* 1992;56:326–330.
19. Radford AD, Turner PC, Bennett M, et al. Quasispecies evolution of a hypervariable region of the feline calicivirus capsid gene in cell culture and in persistently infected cats. *J Gen Virol* 1998;79:1–10.
20. Geissler K, Schneider K, Platzer G, et al. Genetic and antigenic heterogeneity among feline calicivirus isolates from distinct disease manifestations. *Virus Res* 1997;48:193–206.
21. Dawson S, McArdle F, Bennett M, et al. Typing of feline calicivirus isolates from different clinical groups by virus neutralisation tests. *Vet Rec* 1993;133:13–17.
22. Mutze G, Cooke B, Alexander P. The initial impact of rabbit hemorrhagic disease on European rabbit populations in South Australia. *J Wildl Dis* 1998;34:221–227.
23. Povey RC, Johnson RH. A survey of feline viral rhinotracheitis and feline picornavirus infection in Britain. *J Small Anim Pract* 1971;12:233–247.
24. Johnson RP, Povey RC. Feline calicivirus infection in kittens borne by cats persistently infected with the virus. *Res Vet Sci* 1984;37:114–119.
25. Mitro S, Krauss H. Rabbit hemorrhagic disease: a review with special reference to its epizootiology. *Eur J Epidemiol* 1993;9:70–78.
26. Wardley RC, Povey RC. Aerosol transmission of feline caliciviruses. An assessment of its epidemiological importance. *Br Vet J* 1977;133:504–508.
27. Scott FW. Virucidal disinfectants and feline viruses. *Am J Vet Res* 1980;41:410–414.
28. Kennedy MA, Mellon VS, Caldwell G, et al. Virucidal efficacy of the newer quaternary ammonium compounds. *J Am Anim Hosp Assoc* 1995;31:254–258.
29. Doultree JC, Druce JD, Birch CJ, et al. Inactivation of feline calicivirus, a Norwalk virus surrogate. *J Hosp Infect* 1999;41:51–57.
30. Smid B, Valicek L, Rodak L, et al. Rabbit haemorrhagic disease: an investigation of some properties of the virus and evaluation of an inactivated vaccine. *Vet Microbiol* 1991;26:77–85.
31. Ramiro-Ibanez F, Martin-Alonso JM, Garcia Palencia P, et al. Macrophage tropism of rabbit hemorrhagic disease virus is associated with vascular pathology. *Virus Res* 1999;60:21–28.
32. Marcato PS, Benazzi C, Vecchi G, et al. Clinical and pathological features of viral haemorrhagic disease of rabbits and the European brown hare syndrome. *Rev Sci Tech* 1991;10:371–392.
33. Povey RC. Persistent viral infection. The carrier state. *Vet Clin North Am Small Anim Pract* 1986;16:1075–1095.