

Diagnostic quality of percutaneous kidney biopsy specimens obtained with laparoscopy versus ultrasound guidance in dogs

Clarence A. Rawlings, DVM, PhD, DACVS; Halise Diamond, DVM; Elizabeth W. Howerth, DVM, PhD, DACVP; Lisa Neuwirth, DVM, MS, DACVR; Chanda Canalis, BS

Objective—To compare diagnostic quality of percutaneous kidney biopsy specimens obtained with laparoscopy versus ultrasound guidance in dogs and compare diagnostic quality of specimens obtained with 14- versus 18-gauge biopsy needles.

Design—Prospective study.

Animals—10 healthy dogs.

Procedure—In each dog, 2 biopsy specimens were obtained from each kidney, 1 with a 14-gauge biopsy needle and 1 with an 18-gauge biopsy needle. Biopsy specimens were obtained from 1 kidney by means of ultrasound guidance and from the contralateral kidney by means of direct viewing during laparoscopy. Number of glomeruli, quality of the biopsy specimen, proportion of specimens that contained muscle tissue, and proportion of specimens with fragmentation or crushing were determined.

Results—Mean \pm SD number of glomeruli (32.6 \pm 11.0) in laparoscopic, 14-gauge biopsy specimens was significantly higher than mean number of glomeruli in ultrasound-guided, 14-gauge specimens; mean number of glomeruli in ultrasound-guided, 18-gauge specimens; and mean number of glomeruli in laparoscopic, 18-gauge specimens. All 10 laparoscopic, 14-gauge biopsy specimens were classified as excellent. The proportion of 18-gauge biopsy specimens with crushing or fragmentation was significantly higher than the proportion of 14-gauge specimens. One of the kidneys biopsied with ultrasound guidance had a large amount of hemorrhage. Hemorrhage was modest and transient following laparoscopic biopsy.

Conclusions and Clinical Relevance—Results suggest that excellent-quality renal biopsy specimens with large numbers of glomeruli can be obtained with 14-gauge, double-spring-activated biopsy needles during laparoscopy. Renal biopsy specimens obtained with 18-gauge biopsy needles frequently had few glomeruli and often were crushed or fragmented, increasing the difficulty in making an accurate diagnosis. (*J Am Vet Med Assoc* 2003;223:317–321)

Kidney biopsy is commonly performed to evaluate the type and severity of lesions in dogs suspected to have renal disease, particularly dogs suspected to have diseases primarily involving the renal cortex, such as protein-losing glomerulopathy.¹ Other indica-

tions for biopsy of the renal cortex include nephrotic syndrome without signs of systemic disease and acute renal failure for which the cause cannot be determined on the basis of history, physical examination findings, or laboratory test results.² Biopsy of the renal medulla is seldom indicated clinically and is associated with a risk of injury to the arcuate and deeper renal vessels. An absolute contraindication for kidney biopsy is coagulopathy.^{3,4} Relative contraindications include renal cysts, pyelonephritis, ureteral obstruction, and hydronephrosis.^{1,5}

Kidney biopsy can be done through a keyhole technique or percutaneously. Percutaneous kidney biopsy can be done blindly, while palpating the kidney through the abdominal wall, or with ultrasound guidance.^{3,4,6-12} Alternatively, laparoscopy would permit direct viewing of the kidney during percutaneous kidney biopsy, potentially allowing for selective sampling of renal masses or particular portions of the kidney.

To be clinically useful, renal biopsy specimens must be large enough that they contain sufficient glomeruli for a pathologist to accurately characterize any lesions that might be present. In addition, crushing and fragmentation of the specimens must be minimized. Currently available biopsy needles range in size from 14 to 18 gauge. Biopsy specimens obtained with smaller needles may contain too few glomeruli to be of diagnostic value, whereas specimens obtained with larger needles may lead to hemorrhage, which may be fatal.¹³ The purposes of the study reported here were to compare the diagnostic quality of percutaneous renal biopsy specimens obtained during laparoscopy versus ultrasound guidance and compare the diagnostic quality of specimens obtained with 14- versus 18-gauge needles.

Materials and Methods

Dogs—The study involved 10 healthy dogs that were being used to teach veterinarians laparoscopy. All dogs were anesthetized at the time of the study. Dogs had been premedicated with atropine and acepromazine; anesthesia was induced with thiopental and maintained with isoflurane. Renal biopsy specimens were obtained for the present study before other laparoscopic techniques were performed.

Experimental protocol—In each dog, 2 biopsy specimens were obtained from each kidney, 1 with a 14-gauge biopsy needle and 1 with an 18-gauge biopsy needle. New spring-fired core biopsy needles^a were used to obtain each specimen. Biopsy specimens were obtained from 1 kidney by means of ultrasound guidance; specimens were obtained from the contralateral kidney by means of direct viewing during laparoscopy. The selection was randomized, and ultra-

From the Departments of Small Animal Medicine and Surgery (Rawlings, Canalis), Anatomy and Radiology (Diamond), Pathology (Howerth), Large Animal Medicine (Neuwirth), and Physiology and Pharmacology (Rawlings), College of Veterinary Medicine, University of Georgia, Athens, GA 30602-7390.

Address correspondence to Dr. Rawlings.

sound guidance was used to obtain specimens from 4 right kidneys and 6 left kidneys. Biopsy needles were placed in a double-spring-activated biopsy device.^a Both needles were 16 cm long and had a 1.7-cm notch.

Ultrasound-guided biopsy—Prior to biopsy, the ventral aspect of the abdomen was clipped, and the kidney was imaged with a 12.5-MHz transducer^b to determine the best path for the needle. The needle path was chosen to avoid the spleen and overlying bowel. A stab incision was then made immediately adjacent to the transducer through the skin and abdominal wall with a No. 15 scalpel blade. The 18-gauge biopsy needle was advanced through the skin incision and body wall to the kidney with a free-hand technique.⁶ The needle was directed obliquely to the surface of the kidney in an attempt to sample cortical tissue only and avoid the renal medulla, renal pelvis, and hilar and arcuate arteries. Once the needle contacted the kidney capsule, the biopsy specimen was obtained by activating the biopsy device. The procedure was repeated with a 14-gauge needle. After both specimens were obtained, the kidney was reexamined for complications such as hemorrhage. Ultrasound-guided biopsies were obtained by a radiology resident (HD) working under the direct supervision of a board-certified radiologist (LN).

Laparoscopic biopsy—After ultrasound-guided biopsy specimens were obtained, laparoscopy was performed. The dog was placed in dorsal recumbency, and 2 trocar cannulas were inserted. The primary trocar cannula (10 or 12 mm) was placed on the midline, 3 cm caudal to the umbilicus, by use of the open (Hasson) technique. Traction sutures of size 0 polydioxanone were placed on both sides of the linea alba incision, and these sutures were used to maintain a tight seal around the trocar cannula. The peritoneal cavity was distended with carbon dioxide by use of an insufflator,^c and a 0°, 10-mm laparoscope^d was placed through the cannula. The laparoscope was connected to a 3-chip camera^e and xenon light source.^f The second trocar cannula (5 mm) was placed paramedian and caudal to the initial trocar. A laparoscopic forceps was placed through this cannula and used to manipulate the viscera, ensuring that the kidneys could be seen. Both kidneys were examined by rotating the dog so that the examined kidney was more superior. The kidney chosen for laparoscopic biopsy was identified and stabilized with the laparoscopic forceps, and biopsy specimens were obtained with 14- and 18-gauge needles by use of the same spring-fired biopsy device. The site for insertion of the biopsy needle was selected by gently palpating the abdominal wall near the kidney. A small skin incision was made, and the biopsy needle was watched as it was inserted through the abdominal wall and advanced toward the kidney. The biopsy needle was positioned in a tangential direction against the surface of the kidney prior to activating the spring mechanism. Laparoscopic biopsy was performed by veterinarians who were learning laparoscopic techniques under the direct supervision of a board-certified surgeon

(CAR). Following kidney biopsy, laparoscopy was used to examine the biopsy sites in both kidneys for hemorrhage.

Sample processing and examination—For processing, each specimen was placed in an individual cassette with a single foam insert. Tissues were fixed in neutral-buffered 10% formalin, processed routinely, and embedded in paraffin. Sections (4 to 6 μ m thick) were cut and stained with H&E. All specimens were examined by a board-certified pathologist (EWH). Glomeruli in each section were counted. A quality score was then assigned on the basis of whether the specimen was fragmented, appeared crushed, or was < 6 mm long. The presence of muscle throughout the specimen or constituting a part of the specimen was noted. Quality scores ranged from 0 to 4, with 4 being excellent, 3 being good (specimen was excellent except for slight crushing), 2 being fair, 1 being poor, and 0 being inadequate (specimen insufficient to obtain useful information).

Statistical analyses—Data were expressed as mean \pm SD. Paired *t* tests were used to compare, for each biopsy needle size, the number of glomeruli and quality score for ultrasound-guided versus laparoscopic biopsy specimens. Paired *t* tests also were used to compare results for specimens obtained with 18- versus 14-gauge needles for each biopsy technique and compare results for all specimens obtained with 18- versus 14-gauge needles. Proportions of specimens with crushing and fragmentation were compared between 14- and 18-gauge needles with the *z* test for proportions. For all analyses, a value of *P* < 0.05 was considered significant.

Results

Renal biopsy specimens were obtained with both the 14- and 18-gauge needles by means of ultrasound guidance and during laparoscopy, except for two 14-gauge, ultrasound-guided biopsy specimens. The mean number of glomeruli in laparoscopic, 14-gauge biopsy specimens was significantly higher than the mean number of glomeruli in ultrasound-guided, 14-gauge specimens; mean number of glomeruli in ultrasound-guided, 18-gauge specimens; and mean number of glomeruli in laparoscopic, 18-gauge specimens (Table 1). Of the 10

Table 1—Characteristics of renal biopsy specimens obtained with 14- and 18-gauge biopsy needles by means of ultrasound guidance or during laparoscopy in dogs

Variable	No. of glomeruli*	Quality score*	No. containing muscle†	No. with crushing or fragmentation‡
Ultrasound-guided				
18-gauge needle	10.9 \pm 6.1 11.5 (0–19)	2.5 \pm 1.3 3.0 (0–4)	2/10	7/10
14-gauge needle	16.0 \pm 10.2 17.0 (0–33)	3.6 \pm 0.7 4.0 (2–4)	3/10	3/8‡
Laparoscopic				
18-gauge needle	12.2 \pm 10.0 12.0 (1–35)	2.6 \pm 1.1 3.0 (1–4)	0/10	7/10 ^b
14-gauge needle	32.6 \pm 11.0 ^a 30.0 (19–59)	4.0 \pm 0 4.0 (2–4)	0/10	0/10 ^b
Either technique				
18-gauge needle	10.9 \pm 5.9 ^c 11.5 (0–35)	2.6 \pm 1.2 ^c 3.0 (0–4)	2/20	14/20 ^c
14-gauge needle	24.3 \pm 13.4 ^c 25.5 (0–59)	3.8 \pm 0.5 ^c 4.0 (2–4)	3/20	3/18 ^c

*Data are given as mean \pm SD in the top row and median (range) in the bottom row. †Data are given as number of specimens with characteristic/number of specimens examined. ‡One specimen that consisted solely of muscle, without any renal tissue, was excluded, along with 1 biopsy attempt that did not yield a specimen.

^aMean value was significantly (*P* < 0.05) different from mean values for 18-gauge, ultrasound-guided; 14-gauge, ultrasound-guided; and 18-gauge, laparoscopic specimens. ^bValues were significantly (*P* = 0.005) different. ^cValues were significantly (*P* \leq 0.003) different.

ultrasound-guided, 14-gauge renal biopsy specimens, 2 had no glomeruli, and only 1 had > 25 glomeruli. Four of the 10 ultrasound-guided, 18-gauge specimens and 4 of the 10 laparoscopic, 18-gauge specimens had < 10 glomeruli. The lowest number of glomeruli in the 10 laparoscopic, 14-gauge specimens was 19, and the next lowest was 26. The number of glomeruli in the 18-gauge biopsy specimens varied widely, with 5 of the 20 having < 5 glomeruli. When data for the 2 biopsy techniques were combined, the mean number of glomeruli in 14-gauge specimens was significantly higher than the mean number in 18-gauge specimens.

All 10 laparoscopic, 14-gauge biopsy specimens were classified as excellent (quality score, 4; Fig 1 and 2), with specimens ranging from 6 to 12 mm in length. In contrast, only 2 of 10 laparoscopic, 18-gauge specimens were classified as excellent; 7 of these 10 specimens were slightly crushed, and 2 were fragmented (Table 1). However, none of the laparoscopic biopsy specimens contained muscle, whereas 5 of the 20 ultrasound-guided specimens did. Ultrasound-guided biopsy specimens were frequently fractured and often were

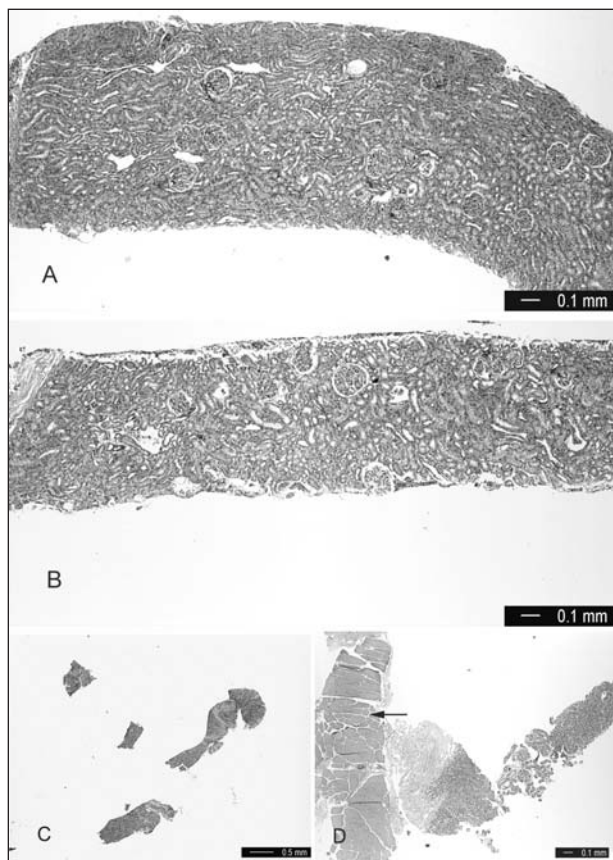


Figure 1—Photomicrographs of percutaneous renal biopsy specimens from dogs. A—Specimen obtained with a 14-gauge biopsy needle during laparoscopy. Quality of the specimen was considered excellent. H&E stain; bar = 0.1 mm. B—Specimen obtained with an 18-gauge biopsy needle during laparoscopy. Quality of the specimen was considered excellent. H&E stain; bar = 0.1 mm. C—Specimen obtained with an 18-gauge biopsy needle with ultrasound guidance. The specimen was severely fragmented. H&E stain; bar = 0.5 mm. D—Specimen obtained with an 18-gauge biopsy needle with ultrasound guidance. The specimen was severely fragmented and contained a large portion of muscle (arrow). H&E stain; bar = 0.1 mm.

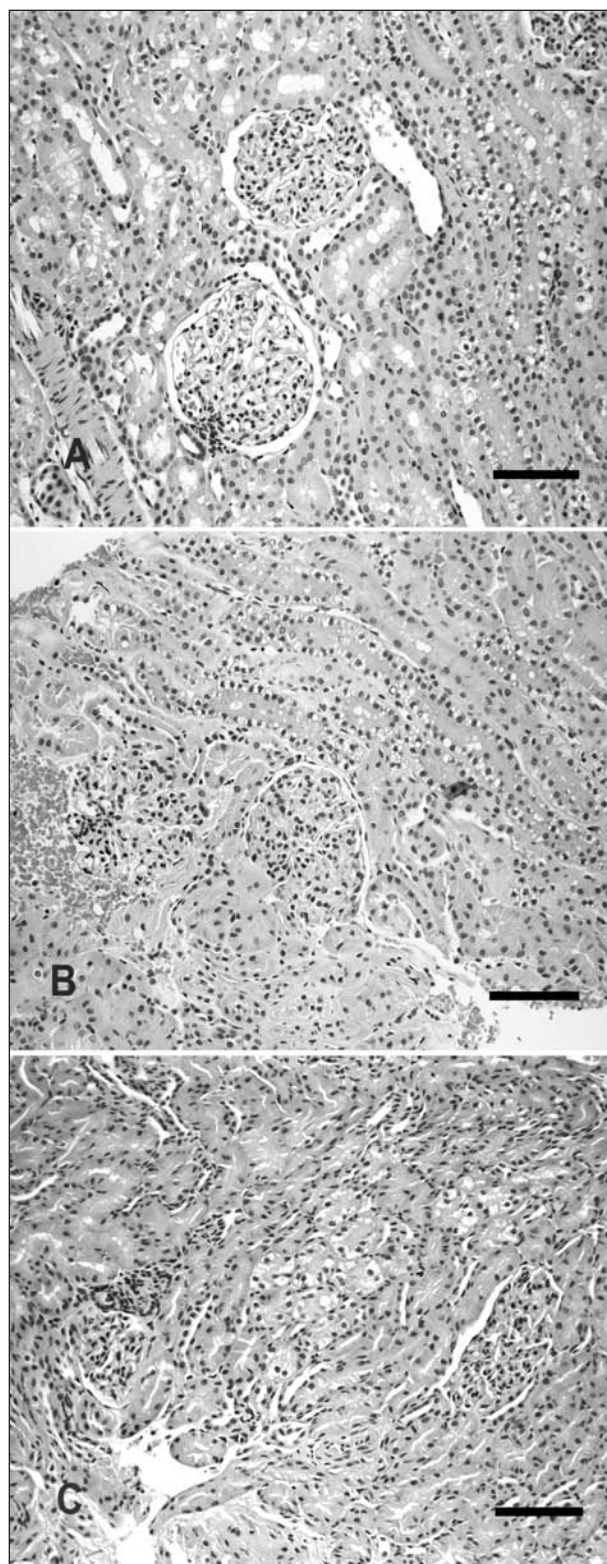


Figure 2—Photomicrographs of percutaneous renal biopsy specimens from dogs. A—Specimen obtained with a 14-gauge biopsy needle during laparoscopy. Quality of the specimen was considered excellent. H&E stain; bar = 0.1 mm. B—Specimen obtained with an 18-gauge biopsy needle during laparoscopy. Notice the slight crushing of tubules and glomeruli. H&E stain; bar = 0.1 mm. C—Specimen obtained with an 18-gauge biopsy needle during ultrasound guidance. Notice the moderate crushing of tubules and glomeruli. H&E stain; bar = 0.1 mm.

< 6 mm long. The proportion of 18-gauge biopsy specimens with crushing or fragmentation was significantly higher than the proportion of 14-gauge specimens.

One of the kidneys biopsied with ultrasound guidance had a large amount of hemorrhage. Hemorrhage was modest and transient following laparoscopic biopsy.

Discussion

In the present study, renal biopsy specimens obtained with 14-gauge biopsy needles during laparoscopy were all considered to be of excellent quality. In addition, laparoscopic, 14-gauge biopsy specimens contained more glomeruli than did specimens obtained with ultrasound guidance.

The mean number of glomeruli in biopsy specimens obtained with 14-gauge needles during laparoscopy was more than twice the mean number of glomeruli in specimens obtained with ultrasound guidance. None contained muscle, and none of the biopsy sites bled profusely following biopsy. This is noteworthy in that the veterinarians performing the laparoscopic biopsies had little or no experience in performing laparoscopy. We are not aware of any clinical studies in dogs that document the minimum number of glomeruli needed for an accurate histologic diagnosis or correlate glomeruli number in biopsy specimens with diagnostic accuracy (ie, concordance between the histologic diagnosis assigned on the basis of examination of needle biopsy specimens and the diagnosis assigned on the basis of examination of large wedge biopsy or necropsy specimens). One retrospective study¹⁴ compared renal biopsy diagnosis with necropsy diagnosis in 82 cats and 19 dogs. Biopsies were performed with a keyhole technique in dogs and a blind percutaneous technique in cats, but needle size was not described. The necropsy diagnosis was the same as the biopsy diagnosis in 80 of 82 dogs and 17 of 19 cats. Of the specimens processed for light microscopy, 101 had ≤ 10 glomeruli, 93 had > 11 glomeruli, and 3 had no glomeruli. Another retrospective study⁴ of complications after ultrasound-guided biopsy with an automated biopsy device (18 gauge) of 70 kidneys and other abdominal masses reported that an accurate diagnosis could be made in most cases. One study¹³ comparing kidney biopsy techniques considered 5 intact glomeruli with adjacent tubules to be an adequate biopsy specimen, but neither needle size nor actual glomeruli numbers were reported. Guidelines for the number of glomeruli have been developed for people, but there also have been few studies comparing glomeruli numbers with diagnostic accuracy in people. Recommendations for percutaneous biopsy specimens obtained with ultrasound guidance or computed tomography range from 5 to 10 glomeruli,^{7,8,15} with 1 international committee defining 7 glomeruli as adequate to define transplant rejection.¹⁶ These various studies used 14-, 16-, or 18-gauge needles, with 18 gauge being the most commonly reported. The common recommendation to use an 18-gauge needle for kidney biopsy in people appears to be based on the impression that larger needles markedly increase the risk of hemorrhage.^{7,9,11,15} In addition, kidney biopsy in people is frequently performed to monitor for trans-

plant rejection.^{7,11,16} In contrast, kidney biopsy in dogs is most often performed to identify the cause of proteinuria or acute renal failure,¹ and biopsy specimens must contain a sufficient number of glomeruli that generalized glomerular disease can be identified. Because 18-gauge biopsy specimens were more likely to be crushed and fragmented in the present study and contained variable numbers of glomeruli (5/20 had 0 to 4 glomeruli), their diagnostic value could be questioned. Of the 20 ultrasound-guided renal biopsy attempts, 2 did not yield any renal tissue, 5 yielded muscle, and 1 resulted in a large amount of hemorrhage.

Large blood vessels in the kidney increase the likelihood of hemorrhage after percutaneous kidney biopsy.^{17,18} For this reason, some ultrasonographers recommend restricting kidney biopsy attempts to 2.¹⁷ Coagulation studies and platelet counts should be performed before biopsy, but even with these precautions, complications developed following $> 25\%$ of ultrasound-guided biopsies performed in 310 dogs and 124 cats.³ This is similar to the complication rate reported for people undergoing kidney biopsy, in which most complications are classified as minor.⁸ Hemorrhage is more likely to occur in people undergoing percutaneous ultrasound-guided kidney biopsy when 14-gauge, rather than 18-gauge, needles are used.¹⁰ Signs of hemorrhage include ultrasonographic evidence of a fluid-filled area, hematuria, decreases in the Hct, and a need for blood transfusion.^{11,12} One study⁸ in humans concluded that ultrasonographic monitoring for hemorrhage is not necessary after 16-gauge needle biopsy and that a stable Hct for 6 hours after kidney biopsy is a good predictor that the patient can be safely discharged within a day. In addition to Hct, we monitor heart rate, blood pressure, respiratory effort, and abdominal distention as signs of renal hemorrhage in patients undergoing kidney biopsy. Other signs of hemorrhage after kidney biopsy in dogs and cats include microscopic and gross hematuria.¹⁴ The tendency for hemorrhage following kidney biopsy can be evaluated retrospectively by examining renal biopsy specimens for large vessels.¹³ Recommended evaluations prior to ultrasound-guided kidney biopsy include imaging of the kidneys to identify focal masses, cysts, ureteral obstruction, hydronephrosis, and infiltrative masses.¹³ In the present study, hemorrhage was minor and easily monitored during laparoscopic kidney biopsy, even when 14-gauge needles were used. In addition to allowing for a visual assessment of needle placement in the outer cortex, laparoscopy has the advantages of providing mildly compressive pneumoperitoneum, ability to view biopsy sites for hemorrhage, and ability to apply blunt pressure with laparoscopic forceps over the needle hole if hemorrhage is seen.

Kidney biopsy, whether ultrasound guided or laparoscopic, requires expensive equipment and special expertise. The experience of the operator is probably related to the quality of the biopsy specimens obtained. In the present study, the ultrasonographer had just completed the first year of a radiology residency and had considerable ultrasonography experience but had not previously performed ultrasound-

guided kidney biopsy. Laparoscopic kidney biopsies were performed by various veterinarians who were just learning basic laparoscopy. All procedures for both techniques were directly supervised by specialists experienced with these procedures. It was our impression that the learning curve with ultrasound-guided versus laparoscopic biopsy was such that greater ultrasonographic experience was required to safely perform renal biopsies, especially with 14-gauge needles. In particular, the ultrasonographer must be able to avoid major renal vessels and overlying intestines and spleen when performing kidney biopsy.¹⁸ In a prospective study¹⁹ of 348 ultrasound-guided kidney biopsies in monkeys, the authors confirmed the importance of experience with gray-scale and Doppler ultrasonography to safely biopsy and monitor for complications. Ultrasound-guided biopsy requires at least sedation, whereas laparoscopic biopsy requires general anesthesia and placement of at least 2 trocars. Although considered a minimally invasive surgery, laparoscopy is still more of a surgical procedure than ultrasound-guided biopsy. Ultrasound-guided biopsy of the liver and various solid masses can be done, whereas laparoscopy provides the capability to selectively obtain biopsy specimens from a variety of organs, such as the liver, pancreas, lymph nodes, and intestines. During laparoscopy, biopsy specimens can be obtained from other abdominal organs with biopsy needles or larger biopsy cup forceps. The diagnostic accuracy is negligible for liver biopsy specimens obtained with 18-gauge needles powered by a spring-fired biopsy device, including those obtained during ultrasonography.²⁰

In conclusion, renal biopsy with a 14-gauge, double-spring-activated biopsy needle during laparoscopy consistently produced excellent quality biopsy specimens with large numbers of glomeruli without tissue from other structures and did not result in clinically important hemorrhage. Laparoscopy should be considered if biopsy of other organs or both kidneys is needed. The greater likelihood of hemorrhage with 14- versus 18-gauge biopsy needles during ultrasound guidance may cause veterinarians to select 18-gauge needles when biopsying the kidney with ultrasound guidance. Unfortunately, 5 of 20 18-gauge biopsy specimens had < 5 glomeruli, and most were crushed or fragmented. If 18-gauge biopsy needles are used, careful sample handling when placing specimens onto the sponge foam in a cassette is critical to reducing specimen injury. Although obtaining multiple renal biopsy specimens with 18-gauge spring-fired biopsy needles has been shown to have minimal effects on renal function, as measured by glomerular filtration rate in healthy dogs,⁵ some ultrasonographers recommend restricting renal biopsy attempts to 2 in clinical patients.¹⁷ Other potential renal biopsy complications, especially after multiple biopsy attempts, are infrequent and include hydronephrosis, arteriovenous fistula, infection, and ureteral laceration.¹

¹Pro-Mag double-spring-activated biopsy device with ACN biopsy needles, Medical Device Technologies Inc, Gainesville, Fla.

^bHDI 5000, ATL, Bothell, Wash.

^cElectronic endoflator, Karl Storz Endoscopy American, Culver City, Calif.

^dOlympus 0° 10-mm, 29-cm telescope, Olympus, Tuttlinger, Germany.

^eTricam camera and image processor, Karl Storz Endoscopy American, Culver City, Calif.

^fZenon nova, Karl Storz Endoscopy American, Culver City, Calif.

^gGroman RP, Bahr A, Berridge BR, et al. Effects of serial renal biopsies on kidneys of healthy adolescent dogs (abstr), in *Proceedings*. 18th Meet Am Coll Vet Intern Med 2000;229.

References

- Osborne CA, Bartges JW, Polzin DJ, et al. Percutaneous biopsy of the kidney: indications, applications, techniques, and complications. *Vet Clin North Am Small Anim Pract* 1996;26:1461–1504.
- Squadrito JF, Coletta AV. Laparoscopic renal exploration and biopsy. *J Laparoendosc Surg* 1991;1:235–239.
- Bigge LA, Brown DJ, Penninck DG. Correlation between coagulation profile findings and bleeding complications after ultrasound-guided biopsies: 434 cases (1993–1996). *J Am Anim Hosp Assoc* 2001;37:228–233.
- Leveille R, Bartington BP, Biller DS, et al. Complications after ultrasound-guided biopsy of abdominal structures in dogs and cats: 246 cases (1984–1991). *J Am Vet Med Assoc* 1993;203:413–415.
- Richter KP. Laparoscopy in dogs and cats. *Vet Clin North Am Small Anim Pract* 2001;31:707–727.
- Nyland TG, Mattoon JS, Herrgesell EJ, et al. Ultrasound guided biopsy. In: Nyland TG, Mattoon JS, eds. *Small animal diagnostic ultrasound*. Philadelphia: WB Saunders Co, 2002;33–34.
- Bach D, Wirth C, Schott G, et al. Percutaneous renal biopsy: three years of experience with the biopsy gun in 71 cases—a survey of results and complications. *Int Urol Nephrol* 1999;31:15–22.
- Chan R, Common AA, Marcuzzi D. Ultrasound-guided renal biopsy: experience using an automated core biopsy system. *Can Assoc Radiol J* 2000;51:107–113.
- Hergesell O, Felten H, Andrassy K, et al. Safety of ultrasound-guided percutaneous renal biopsy—retrospective analysis of 1090 consecutive cases. *Nephrol Dial Transplant* 1998;13:975–977.
- Kim D, Heungsoo K, Shin G, et al. A randomized, prospective, comparative study of manual and automated renal biopsies. *Am J Kidney Dis* 1998;32:426–431.
- Khajejdehi R, Syed MA, Junaid MD, et al. Percutaneous renal biopsy in the 1990s: safety, value, and implications for early hospital discharge. *Am J Kidney Dis* 1999;34:92–97.
- Wood BJ, Khan MA, McGovern F, et al. Imaging guided biopsy of renal masses: indications, accuracy and impact of clinical management. *J Urol* 1999;161:1470–1474.
- Wise LA, Allen TA, Cartwright M. Comparison of renal biopsy techniques in dogs. *J Am Vet Med Assoc* 1989;195:935–939.
- Jeraj K, Osborne CA, Stevens JB. Evaluation of renal biopsy in 197 dogs and cats. *J Am Vet Med Assoc* 1982;181:367–369.
- Song JH, Cronan JJ. Percutaneous biopsy in diffuse renal disease: comparison of 18- and 14-gauge automated biopsy devices. *J Vasc Intervent Radiol* 1998;9:651–655.
- Solex K, Mihatsch MJ, Morozumi K, et al. International standardization of criteria for the histologic diagnosis of renal allograft rejection: the Banff working classification of kidney transplant pathology. *Kidney Int* 1993;44:411–422.
- Hager DA, Nyland TG, Fisher P. Ultrasound-guided biopsy of the canine liver, kidney, and prostate. *Vet Radiol* 1985;26:82–88.
- Kerr LY. Ultrasound-guided biopsy. *Calif Vet* 1988;42:9–10.
- Gaschien L, Kunkler A, Menninger K, et al. Safety of percutaneous ultrasound-guided biopsy of renal allografts in the cynomolgus monkey: results of 348 consecutive biopsies. *Vet Radiol Ultrasound* 2001;42:259–264.
- Cole TL, Center SA, Flood SN, et al. Diagnostic comparison of needle and wedge biopsy specimens of the liver in dogs and cats. *J Am Vet Med Assoc* 2002;220:1483–1490.