

## What Is Your Diagnosis?

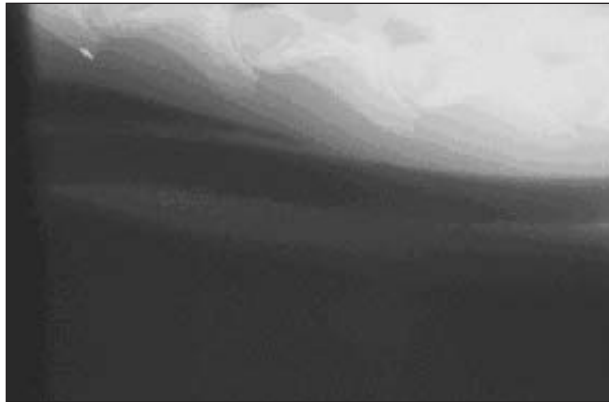


Figure 1—Lateral radiographic view of the cervical region of an 11-month-old American Quarter Horse evaluated because of recurrent esophageal obstruction.

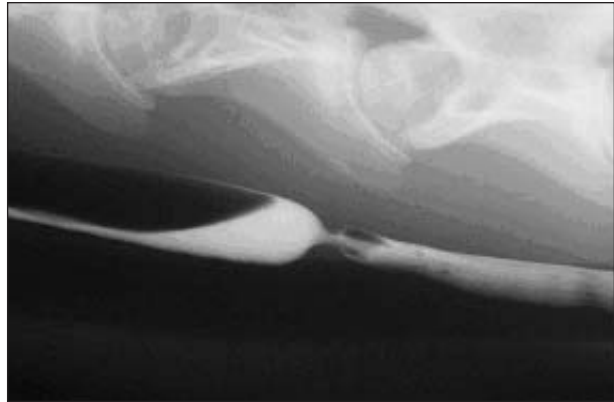

Figure 2—Contrast esophagogram, lateral view of the horse in Figure 1.

### History

An 11-month-old 218-kg (479.6-lb) American Quarter Horse filly was examined because of a 4-month history of recurrent esophageal obstruction characterized by copious nasal discharge and sialorrhea. The episodes began approximately 2 weeks after the filly entangled its head in a paddock gate. The original episodes were mild and resolved spontaneously but progressively became more frequent and more persistent, necessitating veterinary attention.

On initial examination, the horse was bright, alert, and responsive. It was thin but not emaciated, and had a rectal temperature of 38.9°C (102.1°F). The filly would cough occasionally. Wheezes were auscultable over both lung fields. There was no evidence of nasal discharge.

Serum biochemical analyses and a CBC revealed mild hyperfibrinogenemia (438 mg/dL) and mild azotemia (creatinine, 2.33 mg/dL). Esophagoscopy with a 16-mm fiberoptic endoscope revealed a circumferential area approximately 1 cm in length 65 cm caudal to the external nares that could not be dilated. No mucosal abnormalities were seen. The filly was sedated with xylazine (0.4 mg/kg [0.18 mg/lb], IV), and cervical radiographs were obtained (Fig 1). Positive-contrast esophagography was then performed by administering 200 mL of 30% barium suspension via gravity through a nasoesophageal tube into the esophagus (Fig 2).

Determine whether additional diagnostics are required or make your diagnosis from Figures 1 and 2—then turn the page ▶

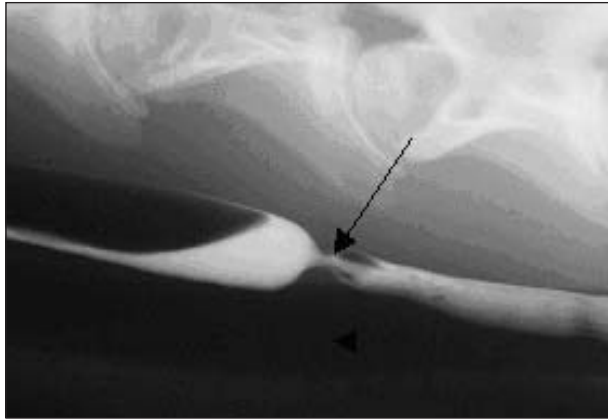

Figure 3—Same radiographic view as Figure 2. Contrast medium is seen filling the esophagus. A narrowed area (arrow) representing an esophageal stricture is seen in the mid-cervical region. There is dilatation of the esophagus proximal to the stricture. The trachea is also clearly visible (arrowhead).

### Diagnosis

**Radiographic diagnosis**—Cervical esophageal stricture (Fig 3).

### Comments

Plain radiographs obtained prior to contrast esophagography confirmed appropriate radiographic technique and eliminated radiopaque extraluminal obstruction and esophageal perforation as possible differential diagnoses. These 2 conditions may eliminate the need for esophagography. A normal esophagus is not visible radiographically. Gas dilatation proximal to the obstruction provided negative contrast that allowed identification of the esophagus oral to the stricture. The obstruction itself was not visible on plain radiographs. Positive-contrast esophagogra-

phy provides the best way to evaluate strictures and diverticula; use of this technique revealed an obvious repeatable narrowing of the contrast column. This narrowing was visible in each of the radiographs in the series, eliminating peristalsis as a cause of the narrowed contrast column and confirming a diagnosis of esophageal stricture. Coating of the esophagus with contrast medium during the study did not reveal any abnormalities in mucosal integrity. Prestenotic dilatation was also visible. A well-rounded shoulder on either side of the lesion as well as normal esophageal mucosa was suggestive of a mural lesion (ie, a lesion that involves the muscularis and adventitia) rather than an esophageal web or ring (ie, a lesion that involves mucosa or submucosa) or annular lesion (ie, a lesion that involves adventitia, muscularis, submucosa, and mucosa).<sup>1</sup> Radiographic and endoscopic findings resulted in a tentative diagnosis of chronic mural esophageal stricture resulting in recurrent esophageal obstruction. We confirmed the diagnosis via surgical exploration. Esophagomyotomy relieved the mural stricture. Postoperatively, the horse did well and was gradually returned to a normal diet. Ten months after surgery, the horse had not had any recurrence of esophageal obstruction, was gaining weight, and had started training under saddle.

1. Fubini SL, Starrak GS, Freeman DE. Esophagus. In: Auer J, ed. *Equine surgery*. 2nd ed. Philadelphia: WB Saunders Co, 1999;199–209.

This report was submitted by Beth M. Kraus, DVM; Aubrey N. Baird, DVM, MS; and Debra K. Baird, DVM, PhD, DACVR; from the Department of Clinical Sciences, New Bolton Center, University of Pennsylvania, Kennett Square, PA 19348. Drs. Baird's present address is Department of Veterinary Clinical Sciences, Purdue University, West Lafayette, IN 47907. Address correspondence to Dr. Kraus.